

UC Davis

Dermatology Online Journal

Title

Erythrasma: A report of nine men successfully managed with mupirocin 2% ointment monotherapy

Permalink

<https://escholarship.org/uc/item/9zh116s1>

Journal

Dermatology Online Journal, 23(5)

Authors

Greywal, Tanya
Cohen, Philip R

Publication Date

2017

DOI

10.5070/D3235034927

Copyright Information

Copyright 2017 by the author(s). This work is made available under the terms of a Creative Commons Attribution-NonCommercial-NoDerivatives License, available at <https://creativecommons.org/licenses/by-nc-nd/4.0/>

Peer reviewed

Erythrasma: A report of nine men successfully managed with mupirocin 2% ointment monotherapy

Tanya Greywal MD, Philip R Cohen MD

Affiliations: Department of Dermatology, University of California San Diego, San Diego, California

Corresponding Author: Tanya Greywal, MD, 9767 Alto Drive, La Mesa, CA 91941 Email: tgreywal@gmail.com, Philip R. Cohen, MD, 10991 Twinleaf Court, San Diego, CA 92131, Email: mitehead@gmail.com

Abstract

Background: Erythrasma is a benign dermatosis that typically occurs on intertriginous skin. Purpose: We describe a series of nine men with erythrasma that were successfully treated with mupirocin 2% ointment monotherapy. Methods and Materials: We reviewed PubMed for the following terms: erythrasma, mupirocin, ointment, treatment. We also reviewed papers containing these terms and their references. Results: Complete resolution of erythrasma occurred following monotherapy with twice daily application of mupirocin 2% ointment. Conclusions: Several topical and oral treatments are available to successfully manage erythrasma. Our series of patients with erythrasma experienced resolution with mupirocin 2% ointment treatment within 2 to 4 weeks of therapy. Monotherapy with mupirocin 2% ointment should be considered as a primary treatment alternative for erythrasma.

Keywords: erythrasma, mupirocin, ointment, treatment

Introduction

Erythrasma is a benign dermatosis with a characteristic clinical appearance. Systemic or topical antibiotics can be used to successfully treat this condition [1]. We describe nine men with erythrasma whose dermatoses resolved after application of mupirocin 2% ointment monotherapy.

Case Series

Erythrasma was diagnosed in nine men whose clinical characteristics are summarized in **Table 1**. The morphology of each lesion was similar and consistent with erythrasma: red and red-brown plaques with scale on skin folds. Final diagnosis was confirmed by coral red fluorescence on Wood's lamp examination. Our patients' ages ranged from 32 to 80 years, with a mean age of 58 years. Most of the lesions were located on the inguinal folds (Figures 1, 2); some extended onto the medial thighs (cases 1, 2, 4, and 8), (**Figure 2**), whereas one patient also experienced involvement of his axillae (case 7), (**Figure 3**). In addition, most of the patients had other medical conditions that were most likely a reflection of their age and not a predisposing factor to erythrasma. All of the patients were treated with mupirocin 2% ointment twice daily monotherapy with resolution of their erythrasma within 2 to 4 weeks of therapy. There was no treatment-associated folliculitis.

Case Discussion

Erythrasma is a superficial skin infection that most commonly presents in warm, moist, and occluded environments such as skin folds [2-5]. This disease is present worldwide, and is most prevalent in warm climates and during the summer months when higher humidity levels exist [2, 5]. Erythrasma does not have a predilection for any particular gender or race, but it is more common in elderly, diabetic, and obese patients [2, 4-6].

Erythrasma typically presents as discrete red-brown plaques and patches with minimal scale [2-8]. These lesions generally affect skin folds where

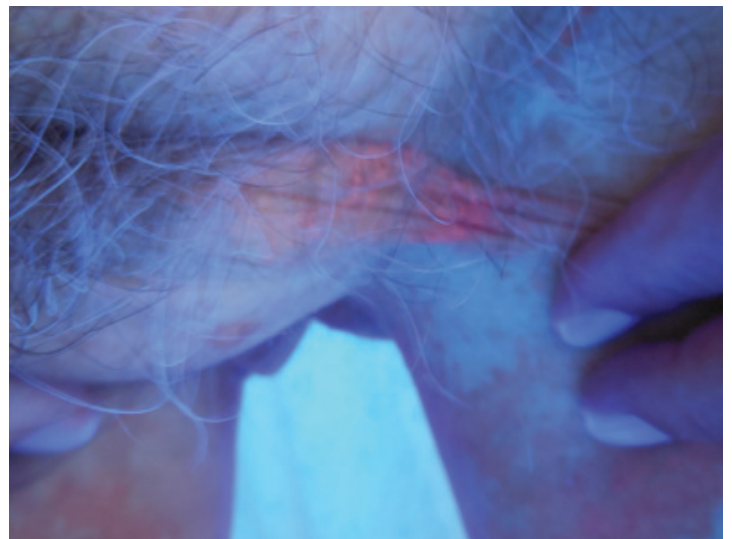
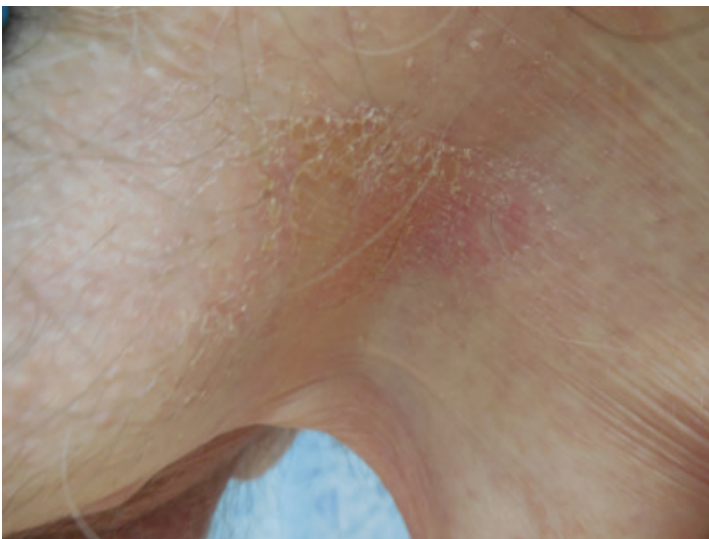


Figure 1. An 80-year-old man with erythrasma (case 9). A red plaque with scale is present on the left inguinal fold (A) with coral red fluorescence on Wood's lamp examination (B).

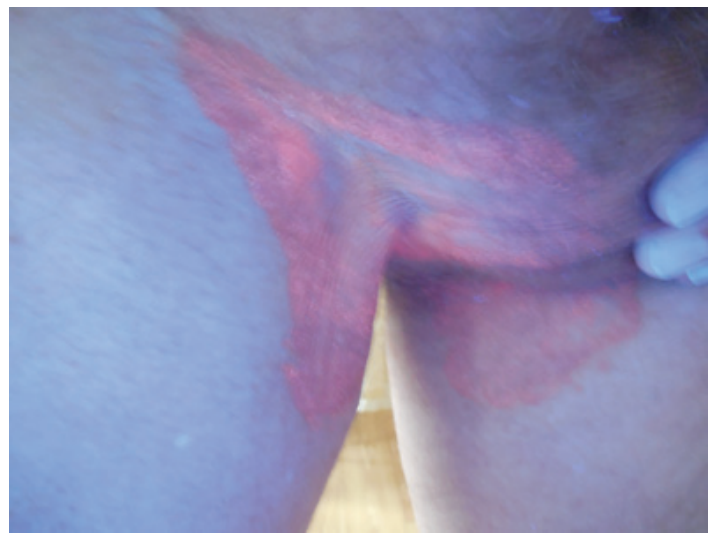
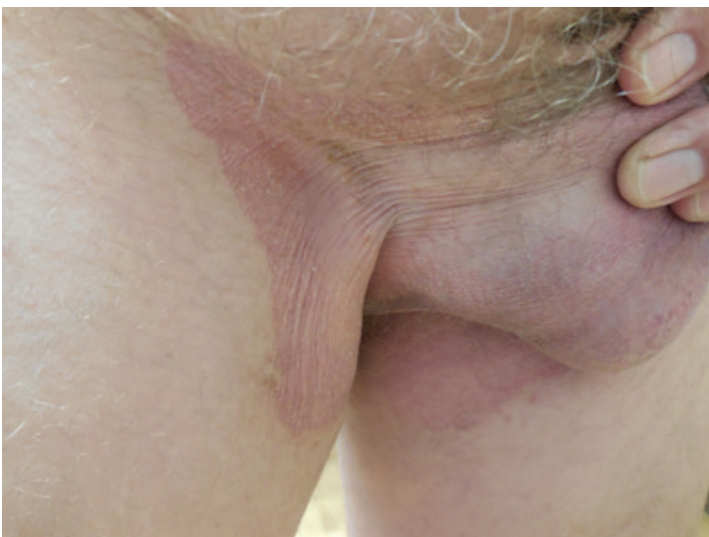

Figure 2. A 69-year-old man with erythrasma (case 8) presented with red plaques with scale on the bilateral inguinal folds and medial thighs (A). Wood's lamp showed coral red fluorescence (B).

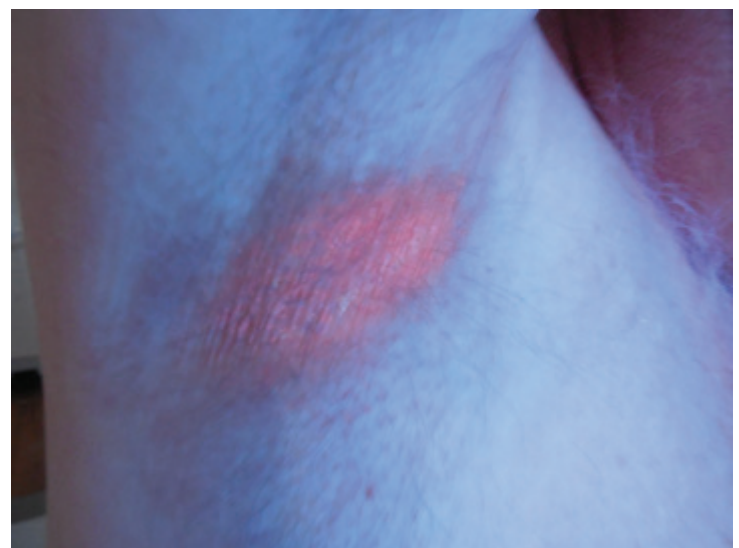
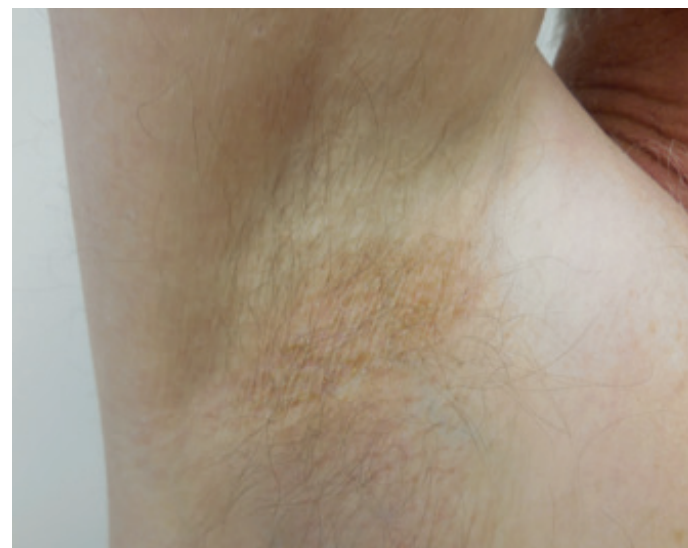
Figure 3. A 64-year-old man with erythrasma involving the bilateral inguinal folds and axillae (case 7). A red-brown plaque was present in the right axilla (A) with a positive Wood's lamp examination (B).

Table 1. Clinical characteristics of nine men with erythrasma¹.

Case	Age (years)	Location	Other Medical Conditions
1	32	Bilateral inguinal folds and medial thighs	None
2	49	Bilateral inguinal folds and medial thighs	-Trigeminal neuralgia
3	51	Bilateral inguinal folds	-Type 1 diabetes
4	54	Bilateral inguinal folds and medial thighs	-Hyperlipidemia -Benign essential tremor -Gastroesophageal reflux disease
5	60	Bilateral inguinal folds	-Hypertriglyceridemia
6	63	Bilateral inguinal folds	-Hyperlipidemia -Generalized anxiety disorder -Sciatica -Sleep apnea -Allergic rhinitis
7	64	Bilateral inguinal folds and axillae	None
8	69	Bilateral inguinal folds and medial thighs	-Arthritis -Hyperlipidemia
9	80	Bilateral inguinal folds	-Parkinson's Disease -Monoclonal gammopathy of unknown significance

¹ All the men were Caucasian. The morphology of all lesions was similar, consisting of red-brown plaques and coral red fluorescence on Wood's lamp examination.

there is occlusion and a warm, moist environment [2, 4, 5, 7, 8]. Patients may experience pruritus and lichenification secondary to scratching, but many are often asymptomatic [2, 3, 5, 7, 8].

The diagnosis of erythrasma is classically based upon clinical presentation [3]. A Wood's lamp examination is especially important since it can confirm the diagnosis; it emits ultraviolet A radiation, which reveals the coral red fluorescence of porphyrins produced by *Corynebacterium* species [2, 3, 7, 8]. Coproporphyrin III is the porphyrin that is most commonly produced in patients with erythrasma, with some reports of uroporphyrin I or other porphyrin involvement [6, 9]. However, it is important to remember that Wood's lamp examination may be negative in patients with erythrasma, particularly when the patient recently washed and temporarily cleared the porphyrins in the area of involvement [3]. In these cases, a biopsy, although not frequently performed, may yield the diagnosis. If tissue is obtained, hematoxylin-eosin stain will likely show normal-appearing skin since this infection does not produce a significant inflammatory reaction nor is the organism easily

observed in the upper layers of the epidermis [2, 3, 6]. Instead, special stains such as periodic acid-Schiff, methenamine silver, and gram stain can allow the small coccobacilli to be observed in the superficial stratum corneum [2, 3, 6]. In addition, some studies have attempted to culture erythrasma fluorescent scales, and they demonstrated that the organism had specific requirements for the culture medium [10-12]. Therefore, a bacterial swab may be able to provide sufficient organism for culture. However, it might require confirmation with the microbiology lab to make sure that the specimen is plated on appropriate medium. The differential diagnosis of erythrasma includes candidiasis, dermatophytosis, intertrigo, pityriasis (tinea) versicolor, psoriasis, and terra firma-forme dermatosis [2, 4, 13, 14].

Erythrasma is caused by a gram-positive bacterial organism: *Corynebacterium* species [1-4, 7, 8, 15]. *Corynebacterium minutissimum* is most commonly implicated, with few reports showing the involvement of other *Corynebacterium* species, such as *C. aurimucosum* and *C. jeikeium*; one study isolated *Microbacterium oxydans* (a coryneform

gram-positive rod) [1-4, 7-9, 15-17]. *Corynebacterium minutissimum* is a non-sporeforming and facultatively anaerobic bacillus that thrives in warm, moist, and occlusive environments that promote bacterial proliferation [2, 15]. In addition, *Corynebacterium* species are involved not only in pitted keratolysis of the plantar feet, but also in trichobacteriosis of the axilla (trichomycosis axillaris) [2, 18].

The treatment of erythrasma is directed by the bacterial microorganism present. Oral antibiotics or topical antibiotics or a combination of both are typically used [1-5, 7, 8]. Commonly used oral antibiotics include clarithromycin, erythromycin, and tetracycline [1, 2, 5, 7]. Topical antibiotic therapies include clindamycin, erythromycin, and sodium fusidate [2-4, 6-8].

Mupirocin is a topical antibiotic that is usually used to treat *Streptococcus* and *Staphylococcus* infections, including methicillin-resistant *Staphylococcus aureus*. To the best of our knowledge, there are no previous reports of mupirocin 2% ointment monotherapy used to treat erythrasma. However, mupirocin 2% ointment has been successfully used in the setting of pitted keratolysis, a benign dermatosis that is also caused by a *Corynebacterium* species infection [19-21].

Prompted by these observations in patients with pitted keratolysis, we elected to also treat our patients with erythrasma with mupirocin 2% ointment monotherapy. Our patients' lesions completely resolved after 2 to 4 weeks of treatment and had not recurred when they were evaluated during follow-up appointments.

Conclusion

Erythrasma presents as red-brown plaques and patches on intertriginous skin and it is associated with a *Corynebacterium* species infection. Management typically includes topical or oral antibiotics to which these gram-positive organisms are susceptible. Our patients' erythrasma resolved within 2 to 4 weeks after initiation of monotherapy with mupirocin 2% ointment. We respectfully suggest that twice daily application of mupirocin 2% ointment monotherapy be considered as first line treatment for erythrasma.

References

1. Chodkiewicz HM, Cohen PR. Erythrasma: successful treatment after single-dose clarithromycin. *Int J Dermatol*. 2013;52:516-518. [PMID: 23046434]
2. Blaise G, Nikkels AF, Hermanns-Le T, Nikkels-Tassoudji N, Pierard GE. *Corynebacterium*-associated skin infections. *Int J Dermatol*. 2008;47:884-890. [PMID: 18937649]
3. Wilson BB, Wagenseller A, Noland MB. An atypical presentation of erythrasma. *J Am Acad Dermatol*. 2012;67:217-218. [PMID: 23062922]
4. Holdiness MR. Erythrasma and common bacterial skin infections. *Am Fam Physician*. 2003;67:254. [PMID: 12562149]
5. Piergiorgio M. Effective treatment of erythrasma-associated inflammation and pruritus with isoconazole nitrate and diflucortolone valerate combination therapy. *Mycoses*. 2013;56:38-40. [PMID: 23574025]
6. Thiyanaratnam J, Cohen PR. What caused this groin plaque? (Erythrasma) [*Derm Dx*] *Skin & Aging*. 2009;17(6):54-58.
7. Laube S. Skin infections and ageing. *Ageing Res Rev*. 2004;3:69-89. [PMID: 15163103]
8. Miller SD, David-Bajar K. A brilliant case of erythrasma. *N Engl J Med*. 2004;351:1666. [PMID: 15483285]
9. Yasuma A, Ochiai T, Azuma T, Nishiyama H, Kikuchi K, Kondo M, Handa H. Exogeneous coproporphyrin III production by *Corynebacterium aurimucosum* and *Microbacterium oxydans* in erythrasma lesions. *J Med Microbiol*. 2001;60(7):1038-1042. [PMID: 21393451]
10. Holdiness MR. Management of cutaneous erythrasma. *Drugs*. 2002;62(8):1131-1141. [PMID: 12010076]
11. Montes LF, Black SH. The fine structure of diphtheroids of erythrasma. *J Invest Dermatol*. 1967;48(4):342-351. [PMID: 6022601]
12. Sarkany I, Taplin D, Blank H. Incidence and bacteriology of erythrasma. *Arch Dermatol*. 1962;85:578-582. [PMID: 14497221]
13. Cohen PR. Terra firma-forme dermatosis of the inguinal fold: Duncan's dirty dermatosis mimicking groin dermatoses. *Open J Clin Med Case Rep*. 2015;1022.
14. Greywal T, Cohen PR. Non-invasive methods to establish the diagnosis of terra firma-forme dermatosis: The SMART (Skin Modified by Alcohol Rubbing Test) evaluation and dermoscopy. *Dermatol Online J*. 2016;22(6):19. [PMID: pending]
15. Penton PK, Tyagi E, Humrighouse BW, McQuinston JR. Complete genome sequence of *Corynebacterium minutissimum*, an opportunistic pathogen and the causative agent of erythrasma. *Genome Announc*. 2015;3:e00139-15. [PMID: 25792058]
16. Takei A. A bacteriological study of fluorescent diphtheroids isolated from the lesions of erythrasma. *J Med Soc Toho University*. 1996;43:373-386.
17. Yassin AF, Steiner U, Ludwig W. *Corynebacterium aurimucosum* sp. nov. and emended description of *Corynebacterium minutissimum* Collins and Jones (1983). *Int J Syst Evol Microbiol*. 2002;52(3):1001-1005. [PMID: 12054216]
18. Falim G, Zabra MF. Trichobacteriosis: contributions of dermoscopy. *Dermatol Online J*. 2014;20(9):14. [PMID: 25244176]
19. Vazquez-Lopez F, Perez-Oliva N. Mupirocine ointment for symptomatic pitted keratolysis. *Infection*. 1996;24:55. [PMID: 8852468]
20. Argomániz EB, Castillo AT. Queratólisis plantar sulcatum. Formación medica continuada en atención primaria. 2007;14:555-556.
21. Greywal T, Cohen PR. Pitted keratolysis: successful management with mupirocin 2% ointment monotherapy. *Dermatol Online J*. 2015;21(8):17. [PMID: 26437161]