

UCSF

UC San Francisco Previously Published Works

Title

Duane retraction syndrome associated with EP300 variant of Rubinstein-Taybi syndrome.

Permalink

<https://escholarship.org/uc/item/9x163634>

Authors

Tran, Lilly

Oatts, Julius

Indaram, Maanasa


Publication Date

2024-12-01

DOI

10.1016/j.ajoc.2024.102226

Peer reviewed



Duane retraction syndrome associated with *EP300* variant of Rubinstein-Taybi syndrome

Lilly Tran^a, Julius T. Oatts^b, Maanasa Indaram^{b,*}

^a University of California, Berkeley, USA

^b University of California, San Francisco, Department of Ophthalmology, USA

ARTICLE INFO

Keywords:

Duane retraction syndrome
Rubinstein-Taybi syndrome
Strabismus

ABSTRACT

Purpose: This case report describes a child with Duane retraction syndrome (DRS) associated with genetically confirmed Type II Rubinstein-Taybi syndrome (RTS). The purpose is to better understand the ocular manifestations of RTS and further explore the possibility that the neurodevelopmental genetic abnormality in RTS may sporadically impact ocular motor nerves.

Observations: A 2-year-old male with a history of Type II RTS associated with a de novo variant of *EP300* presented for a comprehensive eye examination, which revealed a left esotropia of 20 prism diopters (PD) in primary gaze with a significant left face turn, mild globe retraction on adduction in the left eye, and abduction limitation consistent with Type 1 DRS in the left eye. He underwent two strabismus surgeries and postoperatively had a satisfactory sensorimotor outcome.

Conclusions: The association of DRS with RTS is rare with few prior reported cases. We present another case of DRS coupled with *EP300* variant Type II RTS, though this is the first with associated manifest strabismus and compensatory torticollis requiring strabismus surgery, contributing to the phenotypic variability seen in this condition.

1. Introduction

Rubinstein-Taybi syndrome (RTS) is a rare congenital developmental disorder often clinically diagnosed by distinctive craniofacial features such as downslanted palpebral fissures, high palate, grimacing smile, low-hanging columella, and talon cusp. In addition, patients with RTS can also be observed with broad and often angulated thumbs and halluces, short stature, and varying degrees of intellectual disabilities.¹ RTS is extremely rare and occurs between 1/100,000 and 1/250,000 births. Although RTS follows an autosomal dominant inheritance pattern, it more often manifests sporadically resulting from a de novo pathogenic variant.¹ Currently, two identified genes, *CREBBP* and *EP300*, are known to cause Type I and Type II RTS in 55 % and 8 % of clinically diagnosed cases, respectively.² Some of the most common ocular abnormalities seen with RTS include downslanting palpebral fissures, arched eyebrows, long eyelashes, nasolacrimal duct obstruction, colobomas of the iris and of the optic nerve head, and ametropia.^{3,4}

Duane Retraction Syndrome (DRS) is a congenital eye movement disorder characterized by horizontal duction deficits, globe retraction and narrowing of the palpebral fissure on adduction, and possible

strabismus with associated torticollis.^{5,6} DRS is primarily diagnosed clinically, though molecular genetic testing for variants in the *CHN1*, *MAFB*, or *SALL4* genes can be considered for familial cases.⁷ The association of DRS with RTS is rare with only four prior reports of DRS occurring concurrently with RTS in the scientific literature, three of which had genetically confirmed Type II DRS.⁸⁻¹⁰ In this report, we report the fourth case of DRS and Type II RTS associated with a variant in *EP300*. However, in this case, we present a patient with manifest strabismus with compensatory anomalous head posturing that required two strabismus surgeries to address.

2. Case report

A 2-year-old male with a history of Type II RTS, genetically confirmed with an *EP300* variant, presented to the pediatric ophthalmology clinic for a comprehensive eye examination. The patient was born full-term via spontaneous vaginal delivery with no significant prenatal or birth history. His past medical history was also significant for microcephaly, ventricular septal defect, and autism. His initial evaluation revealed visual acuity of 20/94 by preferential looking testing in

* Corresponding author. 490 Illinois Street, Floor 5 San Francisco, CA 94143-4081, USA.

E-mail address: Maanasa.indaram@ucsf.edu (M. Indaram).

<https://doi.org/10.1016/j.ajoc.2024.102226>

Received 7 September 2024; Received in revised form 9 November 2024; Accepted 13 November 2024

Available online 28 November 2024

2451-9936/© 2024 The Authors. Published by Elsevier Inc. This is an open access article under the CC BY-NC-ND license (<http://creativecommons.org/licenses/by-nc-nd/4.0/>).

each eye and a left esotropia of 20 prism diopters (PD) in primary gaze with a constant left face turn of 40°. Ductions in the right eye were normal but were notable for a -3 abduction deficit with full adduction and globe retraction on adduction in the left eye (Fig. 1). There were no consistent upshoots or downshoots with horizontal motility. The remainder of the structural eye examination was normal, notably with no ptosis, nasolacrimal duct obstruction, or retinal abnormalities that can be associated with RTS. External examination was significant for a wide nasal bridge and down-slanting palpebral fissures consistent with RTS.

He was determined to be a candidate for eye muscle surgery due to his manifest esotropia in primary gaze resulting in a compensatory ocular torticollis that was disruptive to his development and activities of daily living. The patient underwent 3.5mm bilateral medial rectus muscle recessions. One week after surgery, the patient was orthotropic in primary gaze with resolution of his anomalous head posture. However, he was noted to have a new -1 limitation on adduction of the left eye, a finding not previously observed. At 3 months postoperatively, the patient developed a consecutive exotropia of 25 PD in primary gaze with V-pattern and persistent mild limitation of adduction of left eye.

Given this presentation, there was concern for a slipped left medial rectus muscle, and a second strabismus surgery was recommended. Ultimately, 12 months after the initial surgery, the patient underwent surgery including exploration of the left medial rectus muscle, which confirmed its placement at the expected 9mm from the limbus, and recession of both lateral rectus muscles 8.0 mm on adjustable sutures. At 2 months postoperatively, the patient was orthotropic in primary gaze at distance and near with resolution of any anomalous head posturing. However, he continued to demonstrate -1 limitation of adduction in the left eye. At his most recent visit, now 4 years following the second surgery, the patient demonstrates a well-controlled intermittent exotropia of 15 PD in primary gaze with no abnormal head posture.

3. Discussion

Although the specific pathophysiological mechanism for the diverse clinical manifestations seen in RTS is largely unknown, two genes are responsible for RTS, which is subdivided into two categories. Type I RTS is associated with the *CREBBP* variants and is responsible for 55–75 % of cases. Type II RTS is associated with *EP300* variants and is seen in 8–11 % of cases.² These genes are ubiquitously expressed and encode acetyltransferases involving histone acetylation and chromatin remodeling affecting neuronal plasticity and cognition.¹¹ *EP300* variants cause phenotypes that resemble *CREBBP* variants but in a much milder form. Most facial characteristics are less marked, excluding low-hanging columella. They share similar limb anomalies, and those with Type II RTS have milder intellectual disabilities but increased rates of microcephaly.¹²

There is a wide variety of ocular anomalies seen in patients with RTS; however, there has been no definitive phenotype-genotype relationship between these eye findings and *CREBBP* versus *EP300* variants.^{13,14} This case report is consistent with three of the four prior reported cases of DRS and RTS concurrency in that this patient, too, had a variant in *EP300* associated specifically with Type II RTS.^{9,10} The fourth did not

report any genetic confirmation of RTS.⁸ Additionally, similar to the patient presented here, all four of previously reported cases described patients who had Type I DRS with limited abduction in the affected eye, with three of the four having the pathology in the left eye while one had it in the right eye.^{8–10} Only one of the four prior reported cases also described a manifest esotropia in primary gaze though outcomes of any strabismus surgery were not reported.⁹ Unique to these prior cases, we present a child with Type II RTS and Type I DRS associated with a significant abduction deficit, a manifest esotropia in primary gaze, and compensatory ocular torticollis requiring more than one strabismus surgery to achieve satisfactory sensorimotor outcomes though with persistent ocular dysmotility in both adduction and abduction.^{8–10}

There have been various theories proposed to explain the etiology of DRS, some of which include mechanical, innervational, and central nervous system anomalies.⁶ However, many investigators concur that the clinical manifestations of DRS result from paradoxical innervation of lateral rectus muscle causing the horizontal rectus muscles to contract simultaneously.⁵ DRS is now accepted as an ocular congenital cranial dysinnervation disorder (CCDD). Research suggests that the reduced function of transcription factors regulating abducens motor neurons, such as MAFB or missense mutations in *CHN1*, that encodes the Rac-GAP GTPase which controls the cytoskeletal dynamics, is responsible for the misinnervation of the lateral rectus secondary to the absence of abducens nerve.¹⁵

The pathophysiology of RTS and specifically how DRS manifests with underlying RTS is still unknown; however, this case study highlights their potential relationship in that both can be caused as a result of mutational errors involving transcription factors.

CRedit authorship contribution statement

Lilly Tran: Writing – original draft, Data curation. **Julius T. Oatts:** Writing – review & editing, Supervision, Funding acquisition. **Maanasa Indaram:** Writing – review & editing, Supervision, Resources, Methodology, Data curation, Conceptualization.

4. Patient consent

Signed consent was obtained by the patient's parent for publication of images and other clinical information relating to the patient's case in the *American Journal of Ophthalmology Case Reports (AJO Case Reports)*.

Authorship

All authors attest that they meet the current ICMJE criteria for Authorship.

Funding

NEI K23EY034893.

Declaration of competing interest

The authors declare that they have no known competing financial

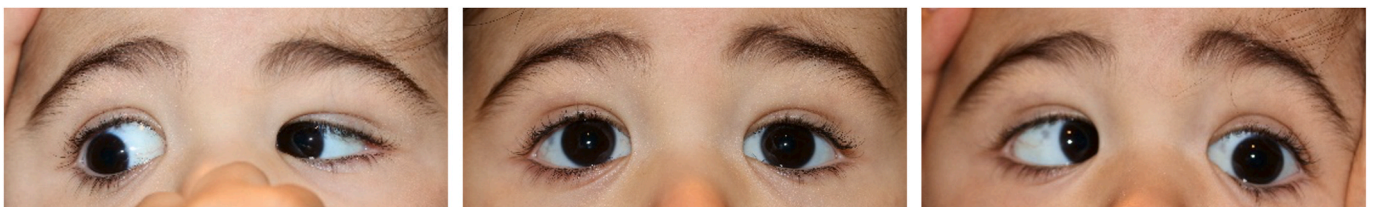

Fig. 1. External ocular motility photographs demonstrating a marked limitation of abduction of the left eye. Adduction was full but was associated with mild globe retraction in the left eye. Ocular motility was full in the right eye. These findings are consistent with the diagnosis of Type 1 Duane Retraction Syndrome (DRS).

interests or personal relationships that could have appeared to influence the work reported in this paper.

Acknowledgements

None.

References

1. Stevens CA. Rubinstein-taybi syndrome. In: Adam MP, Feldman J, Mirzaa GM, et al., eds. *GeneReviews* [Internet]. Seattle (WA): University of Washington, Seattle; 2002 Aug 30:1993–2024 [updated 2023 Nov 9].
2. Van Gils J, Magdinier F, Fergelot P, Lacombe D. Rubinstein-taybi syndrome: a model of epigenetic disorder. *Genes*. 2021 Jun 24;12(7):968. <https://doi.org/10.3390/genes12070968>.
3. Bogdănici C, Neamțu N, Rusu C. Semne oculare în sindromul Rubinstein-Taybi [Ocular signs in Rubinstein-Taybi's syndrome]. *Oftalmologia*. 2001;53(3):26–30. Romanian. PMID: 11915686.
4. Online Mendelian Inheritance in Man, OMIM®. Johns Hopkins University, Baltimore, MD. MIM Number: {613684}; {04/01/2024}: World Wide Web URL: <https://www.omim.org/entry/613684#references>.
5. DeRespinis PA, Caputo AR, Wagner RS, Guo S. Duane's retraction syndrome. *Surv Ophthalmol*. 1993 Nov-Dec;38(3):257–288. [https://doi.org/10.1016/0039-6257\(93\)90077-k](https://doi.org/10.1016/0039-6257(93)90077-k).
6. Kekunnaya R, Negalur M. Duane retraction syndrome: causes, effects and management strategies. *Clin Ophthalmol*. 2017 Oct 30;11:1917–1930. <https://doi.org/10.2147/OPHT.S127481>.
7. Barry BJ, Whitman MC, Hunter DG, et al. Duane syndrome. In: Adam MP, Feldman J, Mirzaa GM, et al., eds. *GeneReviews*® [Internet]. Seattle (WA): University of Washington, Seattle; 2007 May 25:1993–2024 [Updated 2019 Aug 29] <https://www.ncbi.nlm.nih.gov/books/NBK1190/>.
8. Cruz OA, Mason DM, Eswara MS, Lueder GT. Duane retraction syndrome associated with Rubinstein-Taybi syndrome. *Ophthalmic Genet*. 1995 Dec;16(4):171–175. <https://doi.org/10.3109/13816819509057859>.
9. Cohen JL, Schrier Vergano SA, Mazzola S, et al. EP300-related Rubinstein-Taybi syndrome: highlighted rare phenotypic findings and a genotype-phenotype meta-analysis of 74 patients. *Am J Med Genet*. 2020 Dec;182(12):2926–2938. <https://doi.org/10.1002/ajmg.a.61883>.
10. Sharma A, Suraneni S, Bitrian E, McKeown CA. Duane syndrome associated with Rubinstein-Taybi syndrome type II. *J AAPOS*. 2024 Aug;23, 103990. <https://doi.org/10.1016/j.jaapos.2024.103990>. Epub ahead of print.
11. Van Gils J, Magdinier F, Fergelot P, Lacombe D. Rubinstein-taybi syndrome: a model of epigenetic disorder. *Genes*. 2021 Jun 24;12(7):968. <https://doi.org/10.3390/genes12070968>.
12. Fergelot P, Van Belzen M, Van Gils J, et al. Phenotype and genotype in 52 patients with Rubinstein-Taybi syndrome caused by EP300 mutations. *Am J Med Genet*. 2016 Dec;170(12):3069–3082. <https://doi.org/10.1002/ajmg.a.37940>.
13. Jin E, Le H, Jewell A, Couser NL. Genotype-phenotype analysis of ocular findings in Rubinstein-Taybi syndrome - a case report and review of literature. *Ophthalmic Genet*. 2024 Feb;45(1):51–58. <https://doi.org/10.1080/13816810.2023.2196341>.
14. Yang SH, Liu HR, Li JY, et al. [Clinical and genetic characteristics of 21 children with Rubinstein-Taybi syndrome]. *Zhonghua Er Ke Za Zhi*. 2024 Mar 25;62(4):351–356. <https://doi.org/10.3760/cma.j.cn112140-20230822-00122>. Chinese.
15. Whitman MC, Engle EC. Ocular congenital cranial dysinnervation disorders (CCDDs): insights into axon growth and guidance. *Hum Mol Genet*. 2017 Aug 1;26 (R1):R37–R44. <https://doi.org/10.1093/hmg/ddx168>.