

UC Irvine

UC Irvine Previously Published Works

Title

Application of nonpenetrating titanium clips for primary spinal dural closure following intradural tethered cord release in pediatric tethered cord syndrome: Profile of safety, efficacy, efficiency, and complications.

Permalink

<https://escholarship.org/uc/item/9tc4v45q>

Authors

ONeill, Brannan

Godil, Jamila

Brown, Nolan

et al.

Publication Date

2024-04-01

DOI

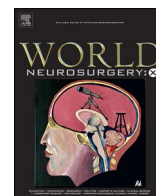
10.1016/j.wnsx.2024.100348

Copyright Information

This work is made available under the terms of a Creative Commons Attribution-NonCommercial-NoDerivatives License, available at

<https://creativecommons.org/licenses/by-nc-nd/4.0/>

Peer reviewed



Application of nonpenetrating titanium clips for primary spinal dural closure following intradural tethered cord release in pediatric tethered cord syndrome: Profile of safety, efficacy, efficiency, and complications[☆]

Brannan E. O'Neill^a, Jamila A. Godil^a, Nolan J. Brown^b, Joshua Loya^a, Ana Silva^a, Jesse Winer^{a,*}

^a Department of Neurological Surgery, Oregon Health & Science University, Portland, OR, USA

^b School of Medicine, University of California, Irvine, Orange, CA, USA

ARTICLE INFO

Keywords:

Tethered cord release
Tethered cord syndrome
Filum lysis
Anastoclclip
Complications
Operative duration
Cerebrospinal fluid leak

ABSTRACT

Introduction: Surgical treatment for tethered cord syndrome (TCS) involves a laminotomy for intradural lysis of filum terminale (LFT), with the goal of releasing excess tension on the conus medullaris by dividing the filum terminale. While LFT alleviates clinical symptoms, it is associated with risks and complications, including cerebrospinal fluid (CSF) leak and infection, either superficial or deep. Some risks and complications of LFT relate to efficiency and quality of primary dural closure and its downstream effects. We sought to assess the utility of nonpenetrating titanium clips (TC) for primary dural closure with a particular focus on operative duration, associated costs, and complication profiles in a series of pediatric patients undergoing LFT, hypothesizing that TC utilization leads to more efficient closure and therefore potentially lower costs and potentially associated anesthetic length and risks.

Methods: A 4-surgeon, single institution series of 28 pediatric patients underwent LFT with subsequent dural closure performed with either the AnastoClip® nonpenetrating titanium clips or traditional suture technique between July 2022 and May 2023. In order to compare the safety, efficacy, and cost-effectiveness between the two dural closure techniques, relevant data were collected including patient demographics and rates of CSF leak, infection at three-month follow-up, and reoperation. Operative durations and times from beginning to end of dural closure were recorded.

Results: A total of 28 pediatric patients (mean age: 5.9 years, 43% female, range: 0.71–17 years) with TCS underwent LFT. All patients underwent procedures involving intradural surgery of the lumbar region. Dural closure was performed using traditional suturing in 19 patients (67.9%) and TC in 9 (32.1%). With respect to duration of dural closure, the average time to closure using traditional suturing techniques was 1271 s (or 21 min and 11 s), while the average time for TC was 265 s (or 4 min and 25 s). At three-month follow-up, one case of cerebrospinal fluid (CSF) leak or infection was observed in the suture cohort and required reoperation.

Conclusion: Clinical outcomes in the TC group were excellent, consistent with previous reports; our findings further suggest that TCs result in more efficient dural closure than traditional suturing techniques. Our findings suggest that TC may be a safe, efficacious, and more efficient alternative to traditional suture for achieving dural closure in pediatric patients with TCS undergoing LFT surgery.

Abbreviations: LFT, lysis of filum terminale; TCS, tethered cord syndrome; TC, titanium clips.

[☆] Previous presentations: This work was presented as an abstract at the 2023 New England Neurosurgical Society Annual Meeting June 22–24, 2023 at the Chatham Bars Inn, Chatham, MA.

* Corresponding author. Department of Neurological Surgery Oregon Health & Science University Mail Code CH8N 3303 South Bond Avenue, Portland, OR, 97239, USA.

E-mail address: winer@ohsu.edu (J. Winer).

<https://doi.org/10.1016/j.wnsx.2024.100348>

Received 27 June 2023; Received in revised form 4 December 2023; Accepted 21 February 2024

Available online 28 February 2024

2590-1397/© 2024 Published by Elsevier Inc. This is an open access article under the CC BY-NC-ND license (<http://creativecommons.org/licenses/by-nc-nd/4.0/>).

1. Introduction

For pediatric spinal procedures involving intradural pathology, for which durotomy is indicated, and for instances of incidental durotomy, achieving a watertight dural closure is necessary for optimizing patient outcomes and reducing morbidity and mortality. Consistent and efficient dural closure is essential to prevent cerebrospinal fluid (CSF) leak and its associated complications – such as intracranial hypotension and infection of the leptomeninges (see Table 1, Figs. 1–3).

At present, an accepted treatment for tethered cord syndrome (TCS) is lysis of filum terminale (LFT), which involves sectioning the filum terminale to release the excess tension associated with aberrant spinal cord attachments.^{1,2} While LFT has proven effective for alleviating clinical symptoms of TCS, it is associated with significant risks and complications, including CSF leak and retethering resulting from intradural scar formation.^{3–5} Because some of the risks and complications of LFT center on the quality of primary dural closure, achieving a watertight seal and preventing CSF leak are critical steps toward reducing morbidity and mortality in this patient population.⁶

A previous study assessed the novel application of a sutureless dural closure system consisting of nonpenetrating titanium clips (TC) (AnastoClip® Vessel Closure System, LeMaitre Vascular, Inc. Burlington, MA) for procedures involving lumbar durotomy in a single surgeon series of 152 pediatric patients.⁷ Although these clips are traditionally used in securing vascular anastomoses for 1–3 mm vessels, the investigators assessed their safety and feasibility for thecal sac reconstruction in pediatric patients with TCS⁸ following LFT. Their goal was to achieve precise, non-penetrating approximation of the spinal dura mater. The study concluded with lower rates of CSF leak and postoperative infection at an average 57.0 month follow-up than has been previously reported in the literature. The benefit of TC not only revolves around its excellent performance in achieving watertight dural closure, but extends to being more facile and easier to apply while maintaining precision through the narrow operative corridors encountered in pediatric spinal surgery.

We seek to investigate the utility of TC as a safe and efficient tool to achieve primary dural closure following LFT, when compared to the

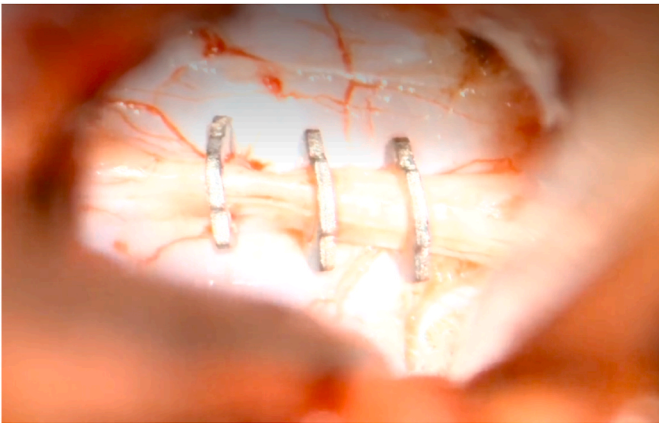


Fig. 1. Demonstrates application of nonpenetrating titanium clips (AnastoClip®) during primary spinal dural closure following cord detethering in a pediatric patient with tethered cord syndrome.

alternative traditional suture-based closure. To do so, we identified patients who recently underwent LFT followed by standard closure with sutures or microsurgical TC closure. In comparing the two groups, we hypothesized that using TC could enable a less technically challenging dural closure for the involved surgeons, ultimately leading to significantly reduced operating room (OR) times (resulting from faster dural closure), avoidance of risks associated with longer administration of anesthesia in pediatric patients, and an overall reduction in costs associated with LFT (based on time saved and cost of materials used).

2. Methods

A retrospective 4-surgeon series of 28 pediatric patients who underwent LFT with subsequent dural closure performed via one of two techniques were assessed, the use of the AnastoClip® nonpenetrating titanium clip closure system (Fig. 1) or the traditional suturing

Table 1
Demographics of patients in study.

Pt Number	Suture or Clip	Indication	Section of Spine	Sex	Age (years)	Follow-up (Months)	CSF Leak?	If yes, day #?	Infection?	If yes, day #?	Reoperation?	Time
1	Suture	SFL	Lumbar	F	12	3	No		No		No	17:20
2	Suture	SFL	Lumbar	F	17	3	No		No		No	16:24
3	Suture	SFL	Lumbar	F	2	3	No		No		No	19:00
4	Suture	SFL	Lumbar	M	0.71	3	No		No		No	11:28
5	Clips	SFL	Lumbar	M	5	3	No		No		No	4:52
6	Suture	SFL	Lumbar	F	8	3	No		No		No	16:30
7	Suture	SFL	Lumbar	M	10	3	No		No		No	29:53
8	Suture	SFL	Lumbar	M	1.17	3	No		No		No	14:40
9	Suture	SFL	Lumbar	F	5	3	No		No		No	9:00
10	Suture	SFL	Lumbar	F	1.67	3	No		No		No	30:41
11	Clips	SFL	Lumbar	M	4	3	No		No		No	2:03
12	Suture	SFL	Lumbar	F	1.08	3	No		No		No	10:09
13	Clips	SFL	Lumbar	F	0.75	3	No		No		No	6:12
14	Clips	SFL	Lumbar	F	1.25	3	No		No		No	5:25
15	Suture	Lipoma	Lumbar	F	0.92	3	No		No		No	22:00
16	Clips	SFL	Lumbar	M	3	3	No		No		No	6:33
17	Clips	SFL	Lumbar	M	9	3	No		No		No	4:13
18	Suture	SFL	Lumbar	M	0.92	3	No		No		No	22:59
19	Suture	SFL	Lumbar	F	12	3	No		No		No	32:20
20	Suture	SFL	Lumbar	M	10	3	No		No		No	34:35
21	Suture	SFL/cyst resection	Lumbar	M	6	3	No		No		No	22:15
22	Suture	SFL	Lumbar	F	11	3	No		No		No	20:40
23	Suture	SFL	Lumbar	M	11	3	Yes	16	Yes	16	Yes	28:00
24	Clips	SFL	Lumbar	M	1.75	3	No		No		No	4:07
25	Suture	SFL	Lumbar	M	1.167	3	No		No		No	19:42
26	Clips	SFL	Lumbar	M	10	3	No		No		No	4:52
27	Suture	SFL	Lumbar	M	17	3	No		No		No	24:46
28	Clips	SFL	Lumbar	M	1.33	3	No		No		No	1:25

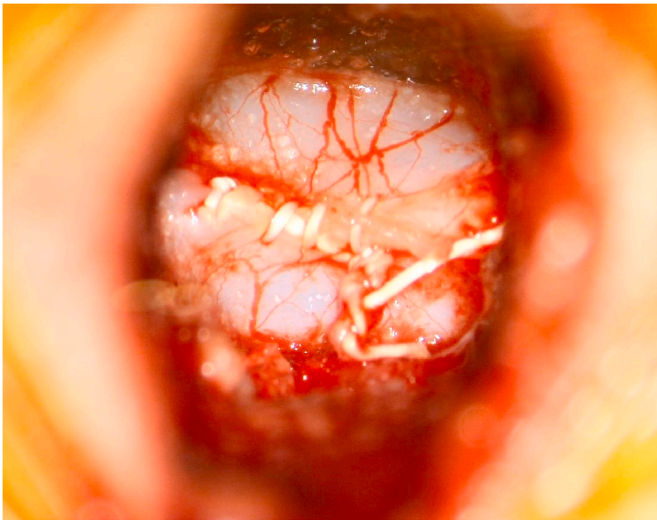


Fig. 2. Demonstrates traditional suturing with Gore-Tex® suture during primary spinal dural closure following cord detethering in a pediatric patient with tethered cord syndrome.

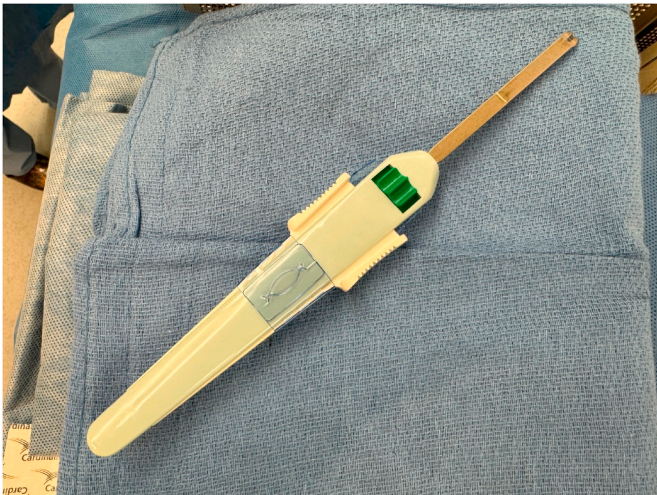


Fig. 3. Image of the applicator of nonpenetrating titanium clips (AnastoClip®) during primary spinal dural closure.

technique (Fig. 2) for closure of lumbar durotomy between July 2022 and May 2023. To compare the safety, efficacy, and cost-effectiveness between the two dural closure techniques, relevant data was collected including patient demographics and rates of cerebrospinal fluid (CSF) leak, infection at three-month follow-up, and reoperation. Furthermore, for comparative assessment of the efficiency between the two techniques, operative duration and time from beginning to end of dural closure were recorded (Table 1). Data on cost of materials used for dural closure and operating room costs was pulled from the electronic medical record and from existing contracts with companies supplying materials to our institution.

The dural closure procedure utilized traditional suturing with CV-6 Gore-Tex® (Gore Medical; Newark, Delaware). According to the manufacturer, CV-6 Gore-Tex® is a monofilament suture featuring polytetrafluoroethylene (ePTFE) biomaterial with a microstructure, combined with strong and ductile 300 series stainless steel alloy needles.⁹ A 6-0 suture of this type was employed during the procedure. In our institution, the approach involves a single-level laminotomy at the intralaminar space. The length of the dural defect was not specifically measured but was typically less than 8 mm. Notably, during dural

closure, the arachnoid layer was intentionally excluded. This delicate layer, dissected free from the nerve roots to confidently identify the filum, is wispy and not amenable to primary closure.

Our Institutional Review Board determined that the above quality improvement project was not human research.

3. Results

A total of 28 pediatric patients (5.9 years, 43% female, range: 0.71–17 years) with TCS underwent LFT. These included 26 patients who underwent isolated LFT for TCS via simple filum lysis, one patient who underwent LFT in conjunction with excision of a lipoma, and one patient who underwent LFT in conjunction with cyst resection. All patients underwent procedures involving durotomy of the lumbar region. Dural closure was performed using traditional suturing with CV-6 Gore-Tex® (Gore Medical; Newark, Delaware) suture in 19 patients (67.9%) and TC in 9 (32.1%). With respect to duration of closure, the average time to closure using traditional suturing techniques was 1271 s (or 21 min and 11 s), ranging from 9 min to 34 min and 35 s. The average time for TC was 265 s (or 4 min and 25 s), ranging from 1 min to 25 s to 6 min and 33 s. Performing a two-sample t-test on these two sets of data, assuming unequal variances, we obtain a t-statistic of −11.84 and a *p*-value less than 0.0001. At three-month follow-up, one case of cerebrospinal fluid (CSF) leak or infection was observed requiring reoperation. This patient had undergone dural closure using traditional suturing.

The AnastoClip® unit costs \$719 per unit (Fig. 3). The CV-6 Gore-Tex® suture, which is what is used for dural closure at our institution, costs \$31.33 per unit. Typically, when Gore-Tex® suture is used, Duraseal® Exact is then applied over the suture line using the MicroMyst™ system. Duraseal® Exact cost \$891.28 per unit, and the MicroMyst™ applicator \$425.80 per unit. The MicroMyst™ flow regulator is a one-time purchase at \$1360.

Based on billing records at our institution, the average cost of 1 min in the OR can be as high as \$133, and AnastoClip® closure saved 17 min of OR time on average. This equates to savings of \$2,261, but even when using more conservative OR cost estimates like \$37/minute such as suggested by Childers et al,¹⁰ the cost savings is significant (~\$630).

4. Discussion

4.1. Summary of data and relevance to study hypothesis

The primary objective of this study was to evaluate the safety, efficacy, and cost-effectiveness of TC for dural closure of durotomy following LFT in pediatric neurosurgery. The study aimed to compare the time taken for closure between TC and traditional suture methods, with the goal of assessing the relevant cost-effectiveness and rate of infection when utilizing both techniques. The patient cohort consisted of 28 individuals who were followed up for an average of 3 months. Ultimately, the results preliminarily confirm our prediction that use of TC for dural closure following LFT would significantly reduce the OR times and lead to decreases in procedural costs and risk for infection.

4.2. Faster, more efficient closure and reduced costs and complications

The results of the present study suggest that TC closure was, on average, significantly faster than traditional suture-based dural closure. At the three-month follow-up, we observed 1 patient who developed a CSF leak and related infection; this patient had undergone traditional Gore-Tex suturing for dural closure. This patient required reoperation, at which time a pinpoint area of CSF egression was noted from one of the suture holes. Importantly, TC do not penetrate the dura, preventing this exact complication.¹ Occasionally when suturing, CSF egress from a suture hole is encountered upon Valsalva necessitating a muscle patch placement in some cases. This only occurred in the suturing cohort in our series as the non-penetrating nature of the clips obviates this risk, a

significant advantage of TC. Furthermore, manipulation of a suture needle at a depth will generally require more space, i.e. a larger surgical corridor. Use of TC allows for a smaller surgical pathway without compromising the integrity of the dural closure integrity. Smaller incision size is a theoretical advantage of TC, though it was not measured in this study.

Our findings suggest that using the TC system is safe and is in line with prior research involving 152 pediatric patients who underwent lumbar durotomy procedures, where the TC system was used for dural closure. That study found a postoperative rate of CSF leak of 1.32% and only one patient (0.66%) with an infection.⁷ Our results, though a smaller sample size, confirm these findings regarding CSF leaks and infections and demonstrate the impact efficiency and cost-effectiveness of TC can have for the patient. Operating rooms are known to incur significant costs, as they require multiple factors to run successfully. In a study conducted by Childers et al, financial disclosure documents from general and subspecialty hospitals in California between 2005 and 2014 were analyzed, and it was found that the mean cost of OR time ranged from \$36 to \$37 per minute.¹⁰ By decreasing operating time, regardless of the operator's level of comfort, use of TC reduces the cost to both the hospital and the patient depending on billing practices. The Anastoclip® unit costs \$719 per unit compared to the cost of Gore-Tex® suture plus Duraseal® Exact plus the MicroMyst™ applicator, which comes out to \$1348.41. This excludes the one-time cost of the Flow Regulator. Duraseal is used at our institution after dural closure with suture due to the small holes made by the suture needle itself. As the Anastoclips are non-penetrating clips, this additional layer of security in closure is not needed. At a minimum, Anastoclip® closure costs \$1200 less than suturing, and at maximum about \$2890 less. With an average of 48 LFT procedures performed at our institution each year, this equates to an estimated annual savings of a minimum of \$57,600 and a maximum of \$138,720. Prolonged OR times not only result in increased costs to the patient, but also to the hospital due to higher utilization of resources such as increased anesthesia and nursing time, greater use of surgical supplies, and the need for more postoperative care. Improving the efficiency of the operating room by identifying components of a procedure that can be expedited without compromising patient safety is crucial for reducing overhead costs.¹¹

Our study shows that use of TCs can potentially decrease the incidence of infections and reoperations at the three-month follow-up. This is based on a direct comparison of absolute infection rates between the two groups - the clips group and the suture group. In the clips group, which consisted of 9 cases, there were zero infections. On the other hand, in the suture group with 19 cases, there was one infection. This difference in infection rates could suggest a correlation between the use of clips and a lower incidence of infections, although it is not statistically significant. Additionally, it is worth noting that the suturing process took significantly longer than clipping, which increases the patient's intraoperative exposure to the OR environment. Longer operating times are associated with more risk, such as increased exposure to pathogens and a greater number of people involved in the patient's care, a study by Short et al found that longer operative times in pediatric spine procedures increased the odds of major complications.¹² The study suggests that further investigation is necessary to identify the factors that contribute to longer operative times. Importantly, however, a systematic review of 81 studies found that longer surgical duration was associated with a higher risk of surgical site infection (SSI) in an incremental fashion, meaning as the duration increased, the SSI risk increased.¹³ In LFT, one potentially lengthy step is adequate dural closure. The incision made for this procedure in pediatric patients is intentionally small at our institution and therefore the working corridor for dural closure is exceedingly narrow. This makes manipulation of the dura more technically challenging, which increases the average time taken for this step. Utilizing the TC system in LFT is shown to be more efficient and faster than traditional suturing techniques since Anastoclips do not need as wide of a corridor for precise application, and therefore less time was

needed for this step with this technique. In a study by Iglesias et al, they demonstrate prolonged operating times were independently associated with surgical site infections, readmission, and reoperation within 30 days in pediatric patients undergoing complicated appendectomy.¹⁴ Therefore, minimizing operating time is essential to improve patient outcomes. Longer surgeries require patients to remain under anesthesia for extended periods. Research on rats, mice, and non-human primates has indicated that exposure to anesthetic agents can potentially cause neuronal cell death.¹⁵ Thus, there is growing concern about the safety and risk of neurotoxicity associated with anesthesia use in children. However, recent studies have found no significant differences in cognitive and behavioral development.¹⁶ Utilizing the TC system shortens the length of surgery and children can be spared the exposure to potentially harmful agents, reducing their risk of acute and chronic adverse effects from medication.

4.3. Limitations

Although TC has several advantages in dural closure, it is important to consider the potential limitations of its usage and of this study. One such limitation is the small sample size of our study, in addition to a discrepancy in size between the two groups (19 suture patients and 9 TC patients). As this was not a prospective trial, the decision to use clips vs sutures was determined by the individual surgeon. While multiple surgeons did use both methods, there was no initial intention to ensure equal cohorts. Our study time was limited to July 2022 to March 2023, so we do not have a retrospective control group with accurate times to compare to. However, power analysis led to the conclusion that this sample size had sufficient statistical power to detect a meaningful difference between the two groups. Additionally, application of TC for dural closure is supported here by data on initial primary dural closure, however their efficacy in re-do surgery where dura may be thickened or scarred may pose a greater challenge and has yet to be systematically evaluated. Finally, there is a learning curve associated with the use of TC, as with any new surgical technique, and surgeons may require training and practice before becoming proficient in using the device. While the use of TC may reduce the overall cost of the procedure due to decreased OR time, the initial cost of the device may be higher than that of traditional sutures. Although short-term outcomes of TC usage have been studied, there is limited data on the long-term outcomes and durability of the device. Anecdotally, the presence of titanium clips does not significantly affect the quality of MR imaging of the lumbar spine. In addition, clip removers may be used to remove clips should re-operation be necessary. Our institutional experience is, however, limited in terms of adverse effects in long-term follow up, though we are reassured by reported experiences in other uses. Further studies are needed to evaluate the long-term outcomes of TC usage. Therefore, while TC has several advantages in dural closure, it is important to consider its potential limitations and the need for further research to fully understand its long-term outcomes.

4.4. Future considerations

These clips can be used in cranial dural closure and have successfully been employed in a few cranial cases at our institution. However, further investigation and follow-up is needed to determine if this application has similar or even improved results when compared to suture closure of cranial dura. In addition, we did not specifically measure the length of the dural defect, which is something to be considered in future studies. By measuring the length of the incision, we can optimize the length of the dural defect needed to achieve filum lysis. Understanding the optimal length of incision would aid in this goal.

5. Conclusion

In conclusion, our findings suggest that TC may be a safe, efficacious,

and more efficient alternative to traditional suture for achieving dural closure in pediatric patients with TCS undergoing LFT surgery. This implies that TC may represent a cost-effective alternative that can reduce operating room times. Future studies should investigate the utility of TC for closure of spinal durotomy in larger cohorts over longer follow-up times, as well as assess the applicability of TC for dural closure following procedures involving other anatomical locations where watertight dural closure may be technically challenging.

CRedit authorship contribution statement

Jamila A. Godil: Writing – review & editing, Writing – original draft, Formal analysis. **Nolan J. Brown:** Writing – review & editing, Writing – original draft, Formal analysis. **Joshua Loya:** Writing – review & editing, Supervision, Data curation, Conceptualization, Brannan E. O'Neill, Writing – review & editing, Writing – original draft, Methodology, Formal analysis, Data curation, Conceptualization. **Ana Silva:** Data curation. **Jesse Winer:** Writing – review & editing, Supervision, Conceptualization.

Declaration of competing interest

The authors declare that they have no known competing financial interests or personal relationships that could have appeared to influence the work reported in this paper.

References

- Ito K, Aoyama T, Horiuchi T, Hongo K. Utility of nonpenetrating titanium clips for dural closure during spinal surgery to prevent postoperative cerebrospinal fluid leakage. *J Neurosurg Spine*. 2015;23(6):812–819. <https://doi.org/10.3171/2015.3.SPINE141215>.
- Chern JJ, Tubbs RS, Patel AJ, et al. Preventing cerebrospinal fluid leak following transection of a tight filum terminale: clinical article. *J Neurosurg Pediatr*. 2011;8(1):35–38. <https://doi.org/10.3171/2011.4.PEDS10502>.
- Faulkner ND, Finn MA, Anderson PA. Hydrostatic comparison of nonpenetrating titanium clips versus conventional suture for repair of spinal durotomies. *Spine*. 2012;37(9):E535–E539. <https://doi.org/10.1097/BRS.0b013e31824cf756>.
- Bhimani AD, Selner AN, Patel JB, et al. Pediatric tethered cord release: an epidemiological and postoperative complication analysis. *J Spine Surg*. 2019;5(3):337–350. <https://doi.org/10.21037/jss.2019.09.02>.
- Elmesallamy W, AbdAlwanis A, Mohamed S. Tethered cord syndrome: surgical outcome of 43 cases and review of literature. *Egypt J Neurosurg*. 2019;34(1):4. <https://doi.org/10.1186/s41984-019-0029-8>.
- Liu V, Gillis C, Cochrane D, Singhal A, Steinbok P. CSF complications following intradural spinal surgeries in children. *Childs Nerv Syst ChNS Off J Int Soc Pediatr Neurosurg*. 2013;30. <https://doi.org/10.1007/s00381-013-2276-4>.
- Shahrestani S, Brown NJ, Loya J, et al. Novel use of nonpenetrating titanium clips for pediatric primary spinal dural closure: a technical note. *Clin Neurol Neurosurg*. 2022;222, 107422. <https://doi.org/10.1016/j.clineuro.2022.107422>.
- Choi EH, Chan AY, Brown NJ, et al. Effectiveness of repair techniques for spinal dural tears: a systematic review. *World Neurosurg*. 2021;149:140–147. <https://doi.org/10.1016/j.wneu.2021.02.079>.
- GORE-TEX® Suture. Gore Medical. Accessed December 2, 2023. <https://www.goremedical.com/products/suture>.
- Childers CP, Maggard-Gibbons M. Understanding costs of care in the operating room. *JAMA Surg*. 2018;153(4), e176233. <https://doi.org/10.1001/jamasurg.2017.6233>.
- McLaughlin N, Burke MA, Setlur NP, et al. Time-driven activity-based costing: a driver for provider engagement in costing activities and redesign initiatives. *Neurosurg Focus*. 2014;37(5):E3. <https://doi.org/10.3171/2014.8.FOCUS14381>.
- Short HL, Fevrier HB, Meisel JA, et al. Defining the association between operative time and outcomes in children's surgery. *J Pediatr Surg*. 2017;52(10):1561–1566. <https://doi.org/10.1016/j.jpedsurg.2017.03.044>.
- Cheng H, Chen BPH, Soleas IM, Ferko NC, Cameron CG, Hinoul P. Prolonged operative duration increases risk of surgical site infections: a systematic review. *Surg Infect*. 2017;18(6):722–735. <https://doi.org/10.1089/sur.2017.089>.
- Iglesias NJ, Arrowood R, Montgomery L, Leeper E, Tsao KJ, Iglesias JL. Operative time is independently associated with morbidity in pediatric complicated appendicitis. *J Surg Res*. 2022;276:143–150. <https://doi.org/10.1016/j.jss.2022.02.045>.
- McCann ME, Soriano SG. Does general anesthesia affect neurodevelopment in infants and children? *BMJ*. 2019;367:l6459. <https://doi.org/10.1136/bmj.l6459>.
- Sun LS, Li G, Miller TLK, et al. Association between a single general anesthesia exposure before age 36 Months and neurocognitive outcomes in later childhood. *JAMA*. 2016;315(21):2312–2320. <https://doi.org/10.1001/jama.2016.6967>.