

UCSF

UC San Francisco Previously Published Works

Title

Silent sinus syndrome without opacification of ipsilateral maxillary sinus

Permalink

<https://escholarship.org/uc/item/9t73f5nv>

Journal

The Laryngoscope, 128(9)

ISSN

0023-852X

Authors

Lee, David S
Murr, Andrew H
Kersten, Robert C
[et al.](#)


Publication Date

2018-09-01

DOI

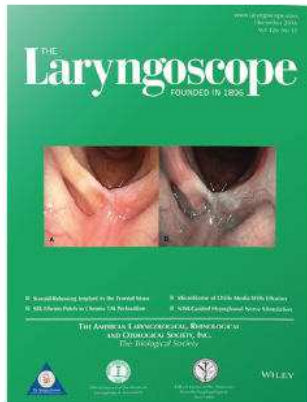10.1002/lary.27108

Peer reviewed



Premiere Publications from The Triological Society

Read all three of our prestigious publications, each offering high-quality content to keep you informed with the latest developments in the field.




THE Laryngoscope FOUNDED IN 1896

Editor-in-Chief: Michael G. Stewart, MD, MPH

The leading source for information in head and neck disorders.

Laryngoscope.com




Laryngoscope Investigative Otolaryngology

Open Access

Editor-in-Chief: D. Bradley Welling, MD, PhD, FACS

Rapid dissemination of the science and practice of otolaryngology-head and neck surgery.

InvestigativeOto.com



ENTtoday A publication of the Triological Society

Editor-in-Chief: Alexander Chiu, MD

Must-have timely information that Otolaryngologist-head and neck surgeons can use in daily practice.

Enttoday.org

WILEY

Case Report

Silent Sinus Syndrome Without Opacification of Ipsilateral Maxillary Sinus

David S. Lee, BA ; Andrew H. Murr, MD; Robert C. Kersten, MD; Steven D. Pletcher, MD

Silent sinus syndrome (SSS) is a rare disease characterized by spontaneous enophthalmos and hypoglobus secondary to collapse of the orbital floor in patients with asymptomatic maxillary sinusitis. Radiographic findings include ipsilateral maxillary sinus opacification, lateralization of the uncinate and middle turbinate, and infundibular occlusion. We present a case series of three patients with clinical and radiographic evidence of SSS but without maxillary sinus opacification. Although uncommon, an aerated maxillary sinus in patients with unexplained enophthalmos, hypoglobus, and maxillary atelectasis should not exclude the diagnosis of SSS.

Key Words: Silent sinus syndrome, chronic maxillary atelectasis, imploding antrum syndrome.

Laryngoscope, 00:000-000, 2018

INTRODUCTION

Montgomery first described enophthalmos and hypoglobus associated with an atelectatic maxillary sinus with ipsilateral sinus opacification in 1964.¹ The term *silent sinus syndrome* (SSS) was formally defined 30 years later by Soparkar et al.² Although the pathophysiology of SSS remains unknown, many consider formation of negative pressure due to ostiomeatal occlusion as the cause of unilateral maxillary sinus atelectasis.^{3,4}

SSS typically occurs in individuals during their fourth and fifth decade, although reports have been published in pediatric populations.^{5,6} Most patients present with painless progressive ocular asymmetry and variable degrees of unilateral upper-lid pseudoretraction, superior sulcus deepening, malar depression, and diplopia.^{2,6,7} Facial trauma, malignancies, and congenital defects may similarly present with enophthalmos and hypoglobus; however, classical diagnosis of SSS requires spontaneous initiation and progression of disease.^{8,9}

Previous case series of SSS report ipsilateral opacification of the maxillary sinus on imaging, and this finding is currently part of the syndrome's core diagnostic criteria.^{2,3,6,7} We present a case series of three patients

who exhibited idiopathic enophthalmos and hypoglobus with radiographic changes consistent with SSS but aeration of the affected sinus. Relevant clinical and radiographic findings are presented. Maxillary sinus volumetric analyses were performed using Brainlab software SmartBrush 2.5 (Brainlab AG, Munich, Germany), amalgamating different planes of imaging to estimate distances across user-defined contours of the maxillary sinus.

CASE REPORT

Among our three cases of aerated SSS, two patients underwent surgical intervention for this disorder, whereas a third declined treatment and was lost to follow-up. On average, there was a significant loss of volume ($29\% \pm 7.1\%$) between diseased and contralateral, uninvolved maxillary sinus (Table I).

Case 1

A 37-year-old man presented to an oculoplastics clinic with an 18-month history of diplopia worsened by leftward, upward, and superotemporal gaze. At initial onset of symptoms, the patient noted facial asymmetry with spontaneous deepening of the left superior sulcus. The patient denied a history of facial trauma or congenital craniofacial abnormalities. On physical exam, gross left-sided enophthalmos and -1 limitation of abduction were noted. Hertel exophthalmometry demonstrated 6 mm of enophthalmos. Magnetic resonance imaging (MRI) from an outside facility demonstrated a lateralized left middle turbinate and an atelectatic left maxillary sinus without opacification.

On referral to the otolaryngology clinic 2 weeks later, endoscopy confirmed lateralization of the left middle turbinate. Preoperative sinus computed tomography (CT) scan demonstrated left middle turbinate lateralization, a

From the University of California San Francisco School of Medicine (D.S.L.); the Department of Otolaryngology–Head and Neck Surgery (A.H.M., S.D.P.); and the Department of Ophthalmology–Ocular Plastics and Reconstructive Surgery (R.K.), University of California San Francisco School of Medicine, San Francisco, California, U.S.A.

The authors have no funding, financial relationships, or conflicts of interest to disclose.

Editor's Note: This Manuscript was accepted for publication December 29, 2017.

Send correspondence to Steven D. Pletcher, MD, Department of Otolaryngology–Head and Neck Surgery, University of California San Francisco, 2233 Post Street 3rd Floor, Box 1225, San Francisco, CA 94115. E-mail: steven.pletcher@ucsf.edu

TABLE I.
Clinical and Radiographic Features

Feature		Case 1		Case 2		Case 3	
Clinical Features	Age at presentation (years)	37		55		42	
	Gender	Male		Male		Male	
	Affected side	Left		Left		Right	
	Time since onset of symptoms (months)	18		4		NA	
	Presenting symptom	Diplopia		Diplopia		Dental pain	
	Hypoglobus	Yes		Yes		NA	
	Enophthalmos	Yes		Yes		Yes	
	Hertel exophthalmometry: pre-/posttreatment (mm)	DS	15	18	17.5	16	NA
		CS	21	21	16	16	
		Δ	6	3	1.5	0	
Management	Maxillary Antrostomy		Orbitotomy With Inferior Fornix Reconstruction		NA*		
Placement of orbital floor implant	No		Yes				
Radiographic Features	Preoperative orbital volume (cm ³)	DS	18.6	22.1	19.2		
		CS	27.6	32.8	24.1		
	Loss of volume (cm ³)	9.0		10.7		4.9	
	Uncinate lateralization	Yes		Yes		Yes	
	Middle turbinate lateralization	Yes		Yes		Yes	
	Maxillary sinus air–fluid level	No		No		No	
	Disease of contralateral sinus	No		No		No	
Maxillary opacification	No		No		No		

*Lost to follow-up.

Δ = degree of enophthalmos (mm); CS = contralateral sinus; DS = diseased sinus; NA = nonapplicable.

hypoplastic but aerated left maxillary sinus with mild circumferential mucosal thickening, and inferior displacement of the left orbital floor (Fig. 1). Following informed consent, including discussion of an atypical presentation of SSS, the patient underwent a left-sided endoscopic maxillary antrostomy to ventilate the maxillary sinus. Intraoperatively, lateralization of the middle turbinate

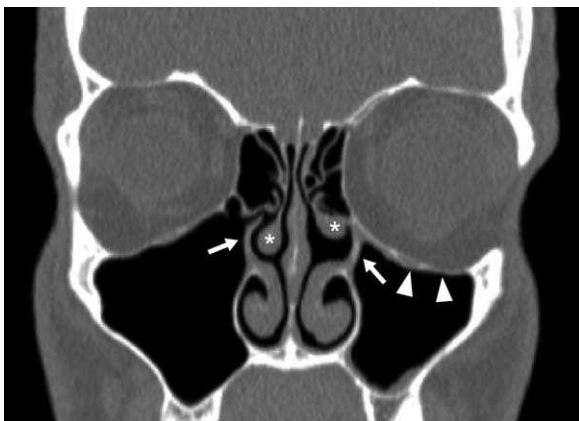


Fig. 1. Coronal CT of case 1, demonstrating an atelectatic left maxillary sinus. There is expansion of the orbit inferiorly with increased concavity of the orbital floor (arrowheads). Arrows indicate normal infundibulum on the right and obstruction of the infundibulum by lateralization of the uncinate process on the left. Asterisks identify normal (right) and lateralized (left) middle turbinates. The affected maxillary sinus remains aerated with mild mucosal edema.
CT = computed tomography.

and uncinate process as well as aeration of the maxillary sinus were observed.

Postoperatively, the patient reported immediate improvement of diplopia and enophthalmos. At the patient's 6-month follow-up at the oculoplastics clinic, Hertel exophthalmometry demonstrated a reduction in enophthalmos from 6 mm to 3 mm and improvement in the superior sulcus defect (Table I). The patient noted diplopia in extreme upward gaze but declined additional surgical intervention.

Case 2

A 55-year-old man presented to a neurology clinic for evaluation of transient diplopia associated with progressive changes in eye shape. The patient reported a fracture to the left medial orbital wall more than 20 years ago that was managed conservatively. Subtle findings of left pronator drift and loss of left nasolabial fold raised suspicion for an intracranial process and prompted an MRI, demonstrating left maxillary sinus atelectasis and increased volume of the ipsilateral orbit. Follow-up sinus CT scan confirmed lateralization of the uncinate and middle turbinate, increased intraorbital volume, and an aerated maxillary sinus (Fig. 2).

On referral to an otolaryngology clinic, nasal endoscopy noted an indistinct uncinate process and lateralization of the left middle turbinate. Oculoplastic surgery was consulted for preoperative assessment of the patient's baseline orbit, noting a -0.5 restriction of upgaze in the left eye. Hertel exophthalmometry demonstrated 1.5 mm

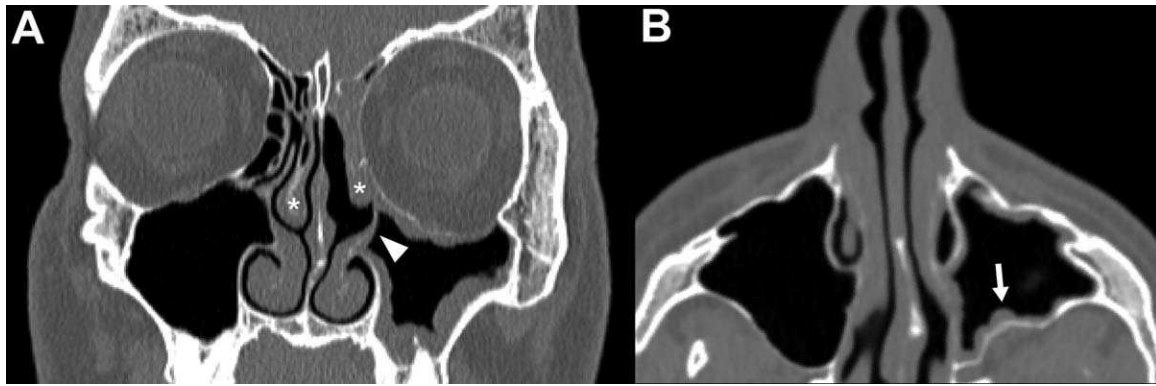


Fig. 2. (A) Coronal and (B) axial computed tomography images of case 2, demonstrating circumferential mucosal edema along the left maxillary sinus and orbital floor with overall aeration of the sinus. Arrowhead indicates lateralization of the uncinate process with subsequent obstruction of the infundibulum. Asterisks identify the normal (right) and lateralized (left) middle turbinates. Arrow indicates mild anterior displacement of the posterior maxillary wall.

of enophthalmos. The patient underwent placement of an orbital floor implant with the oculoplastic team. During follow-up, the patient denied diplopia and demonstrated complete resolution of enophthalmos, as assessed by Hertel exophthalmometry (Table I).

Case 3

A 42-year-old man with a history of shingles presented to a neurology clinic with right-sided dental pain. The patient was found to have mild enophthalmos on exam, and an MRI scan was performed. This revealed significant atelectasis of an aerated maxillary sinus on the right and findings in the pterygopalatine space that were initially interpreted by the radiologist as a retro-maxillary lipoma. The patient was referred to the otolaryngology service, and review of the patient's imaging demonstrated findings consistent with SSS, including lateralization of the middle turbinate and medial maxillary wall and anterior displacement of the posterior maxillary wall (Fig. 3). The lipoma was identified as a compensatory expansion of pterygopalatine fat in the setting of anterior displacement of the posterior maxillary wall. The patient works as a traveling nurse and moved out of state prior to CT imaging or ophthalmologic evaluation. At last contact, the patient reported

that he was pursuing treatment for silent sinus syndrome.

DISCUSSION

SSS is a rare disease, with approximately 150 cases reported to date.^{6,10} Despite the paucity of data, the literature consistently describes SSS with radiographic findings of uncinate process lateralization, inferomedial displacement of the orbital floor, and opacification of the ipsilateral maxillary sinus.^{10,11} However, the presented cases illustrate an unusual variant of SSS with an aerated maxillary sinus, suggesting that maxillary opacification is not a requirement for diagnosis of this clinical entity.

Several factors strongly argue that these patients suffer from silent sinus syndrome. First, all three patients noted new-onset enophthalmos. This is not consistent with a congenital maxillary sinus hypoplasia. The patients in our series all demonstrated significant maxillary atelectasis; their average loss of volume between affected and contralateral sinus is consistent with the published literature describing maxillary volume in patients with SSS.^{12,13} Imaging and physical examination also demonstrated uncinate and turbinate lateralization, as well as involvement of the posterior

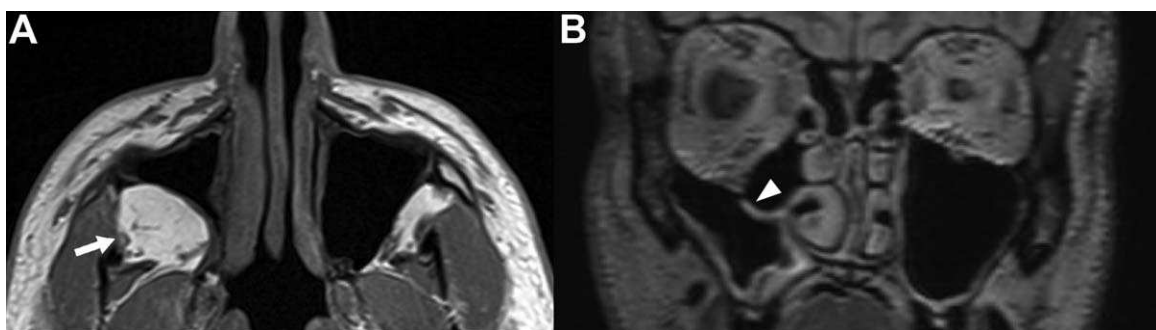


Fig. 3. (A) Axial T1 magnetic resonance imaging of case 3, demonstrating atelectasis but aeration of the right maxillary sinus. Note anterior displacement of the posterior maxillary wall with compensatory expansion of pterygopalatine fat (arrow). (B) T2 coronal MRI demonstrates marked atelectasis of sinus with orbital expansion and lateralization of medial wall of the maxillary sinus (arrowhead). The patient moved out of state before computed tomography imaging could be obtained.

and medial walls of the sinus, further distinguishing these patients from those with a congenital or traumatic etiology for maxillary hypoplasia (Figs. 1–3). In case 2, the patient had a history of an orbital fracture, which would classically exclude the diagnosis of SSS. However, the large time interval between injury and onset of symptoms argues against a direct connection between the trauma and enophthalmos. Furthermore, the appropriateness of excluding the diagnosis of SSS in the presence of facial trauma has recently been questioned.¹⁴ Finally, case 1 demonstrated significant improvement in enophthalmos following endoscopic maxillary antrostomy, consistent with bone remodeling seen in SSS patients following endoscopic surgery.¹⁵

Although this case series most likely describes a rare variant of SSS, it is possible that the presented cases are in the early stages of SSS. Cases 1 and 2 demonstrate mild mucosal edema in the diseased maxillary sinus, indicating an underlying inflammatory process and potentially foreshadowing complete opacification. However, pre- and postoperative imaging in case 2 did not demonstrate progression of circumferential mucosal thickening (not shown). Overall, little is known about the pathophysiology and rate of SSS progression; reports of orbital floor collapse range from overnight to 2.5 years.¹⁶ Therefore, it is possible that in a small subset of patients with SSS, maxillary atelectasis occurs prior to maxillary sinus opacification.

Management of SSS with a nonopacified maxillary sinus is identical to management of SSS with an opacified sinus. Collaborating with ophthalmologists is essential for diagnosis and surgical planning. Operative management includes endoscopic maxillary antrostomy with or without orbital floor reconstruction. Due to the potential for remodeling of the orbital floor following sinus aeration, most authors recommend a staged approach.^{10,15,17–19} Patient 2 underwent placement of an orbital implant without maxillary antrostomy. The patient's history of medial wall fracture and the presence of an aerated maxillary sinus confounded the diagnosis and made orbital volume corrective surgery a reasonable first step. Fortunately, the patient demonstrated complete resolution of diplopia and enophthalmos with a stable exam over 6 months. No additional surgery is planned at this time.

Whereas this case series demonstrates the possibility of SSS in the absence of maxillary sinus opacification, it should be noted that this form of SSS is exceedingly rare. Thorough examination of radiographic studies and ophthalmologic evaluation are required to identify this clinical entity. History and physical examination findings should include new-onset enophthalmos, hypoglobus, and/or diplopia. Radiographic images must include diminished size of the maxillary sinus and at least one additional characteristic finding: lateralization

of the uncinate process and middle turbinate, inferior displacement of the orbital floor, or displacement of the posterior wall of the maxillary sinus with expansion of the pterygopalatine fossa. Care must be taken, particularly in the setting of an aerated maxillary sinus, to avoid misdiagnosis and unnecessary surgical intervention.

CONCLUSION

SSS should remain a diagnostic consideration for patients with spontaneous enophthalmos and hypoglobus, even in the absence of maxillary sinus opacification. Endoscopic maxillary antrostomy may promote bone remodeling and recovery of orbital shape. Although evidence from this case series broadens the definition of SSS, strict diagnostic criteria should be applied before considering surgical intervention.

BIBLIOGRAPHY

1. Montgomery GW. Mucocoele of the maxillary sinus causing enophthalmos. *Eye Ear Nose Throat Mon* 1964;43:41–44.
2. Soparkar CN, Patrinely JR, Cuaycong MJ, et al. The silent sinus syndrome. A cause of spontaneous enophthalmos. *Ophthalmology* 1994;101:772–778.
3. Babar-Craig H, Kayhanian H, de Silva DJ, Geoffrey, Rose E, Lund VJ. Spontaneous silent sinus syndrome (Imploding antrum syndrome): case series of 16 patients. *Rhinology* 2011;49:315–317.
4. Davidson JK, Soparkar CN, Williams JB, Patrinely JR. Negative sinus pressure and normal predisease imaging in silent sinus syndrome. *Arch Ophthalmol* 1999;117:1653–1654.
5. Yip C-C, McCulley T, Kersten R, Tami T, Kulwin D. Silent sinus syndrome as a cause of diplopia in a child. *J Pediatr Ophthalmol Strabismus* 2003;40:309–311.
6. Brandt MG, Wright ED. The silent sinus syndrome is a form of chronic maxillary atelectasis: a systematic review of all reported cases. *Am J Rhinol* 2008;22:68–73.
7. Numa WA, Desai U, Gold DR, Heher KL, Annino DJ. Silent sinus syndrome: a case presentation and comprehensive review of all 84 reported cases. *Ann Otol Rhinol Laryngol* 2005;114:688–694.
8. Ross JJ, Kersten RC. Late enophthalmos mimicking silent sinus syndrome secondary to orbital trauma. *J Craniofac Surg* 2005;16:840–843.
9. Vander Meer JB, Harris G, Toohill RJ, Smith TL. The silent sinus syndrome: a case series and literature review. *Laryngoscope* 2001;111:975–978.
10. de Dorlodot C, Collet S, Rombaux P, Horoi M, Hassid S, Eloy P. Chronic maxillary atelectasis and silent sinus syndrome: two faces of the same clinical entity. *Eur Arch Otorhinolaryngol* 2017;274:3367–3373.
11. Illner A, Davidson HC, Harnsberger HR, Hoffman J. The silent sinus syndrome: clinical and radiographic findings. *AJR Am J Roentgenol* 2002;178:503–506.
12. Lin GC, Sedaghat AR, Bleier BS, et al. Volumetric analysis of chronic maxillary atelectasis. *Am J Rhinol Allergy* 2015;29:166–169.
13. Eyigor H, Kekic B, Turgut Coban D, et al. Is there a correlation between the clinical findings and the radiological findings in chronic maxillary sinus atelectasis? *J Craniomaxillofac Surg* 2016;44:820–826.
14. Araslanova R, Allen L, Rotenberg BW, Sowerby LJ. Silent sinus syndrome after facial trauma: a case report and literature review. *Laryngoscope* 2017;127:1520–1524.
15. Kram YA, Pletcher SD. Maxillary sinus posterior wall remodeling following surgery for silent sinus syndrome. *Am J Otolaryngol* 2014;35:623–625.
16. Soparkar CNS, Davidson JK, Patrinely JR. Silent sinus syndrome—new perspectives? *Ophthalmology* 2004;111:414–415.
17. Sesenna E, Oretti G, Anghinoni ML, Ferri A. Simultaneous management of the enophthalmos and sinus pathology in silent sinus syndrome: a report of three cases. *J Craniomaxillofac Surg* 2010;38:469–472.
18. Sivasubramaniam R, Sacks R, Thornton M. Silent sinus syndrome: dynamic changes in the position of the orbital floor after restoration of normal sinus pressure. *J Laryngol Otol* 2011;125:1239–1243.
19. Bossolesi P, Autelitano L, Brusati R, Castelnuovo P. The silent sinus syndrome: diagnosis and surgical treatment. *Rhinology* 2008;46:308–316.