

# UC Davis

## UC Davis Previously Published Works

### Title

A vascular syphilitic iris lesion.

### Permalink

<https://escholarship.org/uc/item/9sv940d1>

### Authors

Chen, Judy L

Tessema, Ruth

Emami-Naeini, Parisa

et al.

### Publication Date

2023-09-01

### DOI


10.1016/j.ajoc.2023.101858

### Copyright Information

This work is made available under the terms of a Creative Commons Attribution-NonCommercial-NoDerivatives License, available at

<https://creativecommons.org/licenses/by-nc-nd/4.0/>

Peer reviewed



## A vascular syphilitic iris lesion

Judy L. Chen<sup>a,b,\*</sup>, Ruth Tessema<sup>a</sup>, Parisa Emami-Naeini<sup>a</sup>, Michele C. Lim<sup>a</sup>

<sup>a</sup> Department of Ophthalmology & Vision Sciences, University of California, Davis, Sacramento, CA, USA

<sup>b</sup> Department of Ophthalmology, University of California, Los Angeles, Los Angeles, CA, USA

### ARTICLE INFO

#### Keywords:

Syphilis  
Granulomatous uveitis  
Iris lesion  
Ultrasound biomicroscopy  
Anterior segment optical coherence tomography

### ABSTRACT

**Purpose:** To describe examination and imaging characteristics of presumed iris papulosa in a case of ocular syphilis.

**Observations:** A 60-year-old man who presented with granulomatous anterior uveitis in his left eye was also noted to have an unusual vascularized iris papule associated with posterior synechiae at the nasal pupillary margin. Anterior segment OCT (AS-OCT) of the iris lesion demonstrated a hyperreflective anterior surface with multiple vascular lumen, internal hyperreflectivity, and shadowing. Ultrasound biomicroscopy (UBM) imaging revealed an echodense mass with relative hyperechogenicity in the anterior portion of the lesion. Systemic work-up confirmed a diagnosis of syphilis, and he was treated with topical steroids and parenteral penicillin.

**Conclusion and Importance:** We characterize the rare finding of iris papulosa that may be encountered in syphilitic uveitis and its distinctive features on both UBM and AS-OCT. This report highlights that syphilis should be considered as a possible diagnosis for an undifferentiated vascular iris mass.

### 1. Introduction

Vascularized syphilitic iris lesions have been reported in the literature but due to their transient nature, few have been imaged thoroughly. With the rising number of syphilis cases in the U.S., it is important to characterize these lesions since early recognition may aid in diagnosis and treatment.<sup>1</sup> We report a case of ocular syphilis presenting with a presumed iris papulosa, and describe features of the lesion using ultrasound biomicroscopy (UBM) and anterior segment optical coherence tomography (AS-OCT).

### 2. Case report

A 60-year-old male was referred for evaluation of progressive blurred vision in his left eye. He had a past ocular history notable for amblyopia and a dense cataract of the right eye. Upon presentation, his vision was counting fingers in the right eye (OD) and 20/60 in the left eye (OS). He had a right-sided relative afferent pupillary defect, and intraocular pressures (IOP) of 11 mmHg OD and 31 mmHg OS. Exam of the left eye was notable for ciliary flush, granulomatous keratic precipitates, 3–4+ anterior chamber cell and flare, and an approximately 3 mm nodular iris lesion associated with dilated blood vessels and posterior synechiae at the nasal pupillary margin (Fig. 1). AS-OCT of the lesion demonstrated a

hyperreflective anterior surface with visualization of multiple vascular lumen, internal hyperreflectivity, and shadowing (Fig. 2A). UBM imaging revealed an echodense mass with relative hyperechogenicity in the anterior portion of the lesion (Fig. 2B). A secluded pupil prevented a view of the left fundus, but examination of the right eye revealed optic disc edema with splinter disc hemorrhages and tortuous vasculature. Macular OCT and fluorescein angiography studies were limited but did not demonstrate signs of macular edema, retinitis, or vasculitis. B-scan ultrasound of the left eye revealed no vitritis.

On further questioning, the patient admitted to a recently resolved painless penile “lump” and a diffuse, presumably maculopapular rash within 3 months of presentation. Systemic work-up returned positive for syphilis IgG with an RPR titer of 1:2048. The remainder of his work-up, including HIV, Quantiferon gold, chest x-ray, and MRI brain, was negative. He was treated with topical steroids and ocular hypotensives, and started on intravenous penicillin G 4 million units every 4 hours. After receiving 2 days of penicillin, he was started on systemic prednisone 40 mg daily.

At the patient's last examination six days after presentation, vision had improved to 20/400 OD and 20/40 OS, and IOP was 12 mm Hg OD and 10 mm Hg OS after 4 days of penicillin. He was discharged with a plan to complete 2 full weeks of intravenous penicillin and a prednisone taper, with a reduction in steroid dose by 10 mg daily weekly over 4

\* Corresponding author. UCLA Department of Ophthalmology, 800 S. Fairmount Ave., Suite 215, Pasadena, CA, 91105, USA.

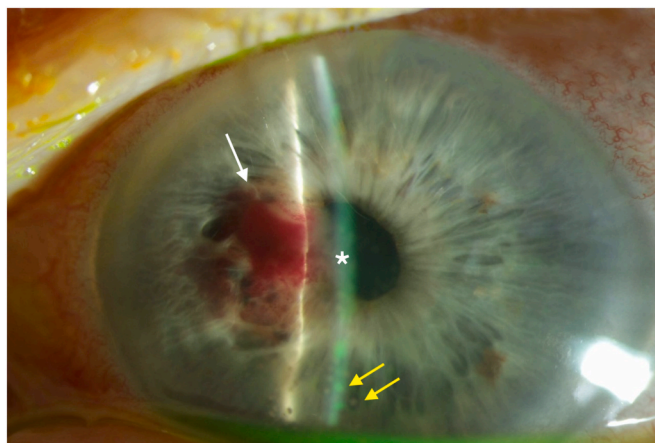
E-mail address: [jlchen@mednet.ucla.edu](mailto:jlchen@mednet.ucla.edu) (J.L. Chen).

<https://doi.org/10.1016/j.ajoc.2023.101858>

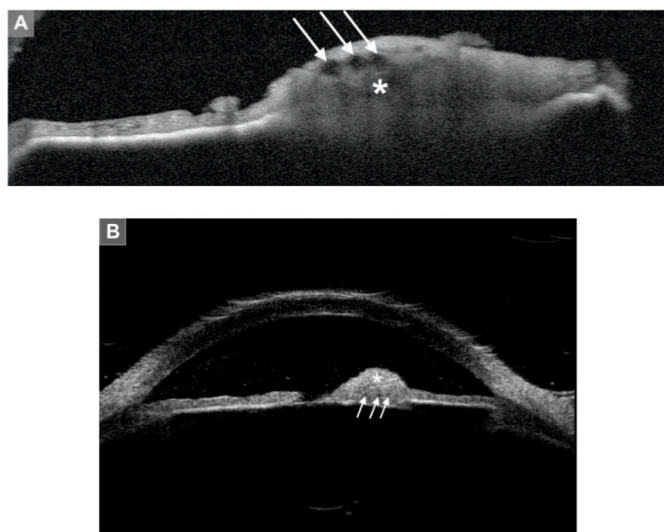
Received 11 November 2022; Received in revised form 30 April 2023; Accepted 5 May 2023

Available online 18 May 2023

2451-9936/© 2023 The Authors. Published by Elsevier Inc. This is an open access article under the CC BY-NC-ND license (<http://creativecommons.org/licenses/by-nc-nd/4.0/>).



**Fig. 1.** Initial presentation demonstrating vascular iris lesion at pupillary border (white arrow) associated with posterior synechiae (asterisk), as well as the presence of granulomatous keratic precipitates (yellow arrows). (For interpretation of the references to color in this figure legend, the reader is referred to the Web version of this article.)



**Fig. 2.** A) Anterior segment OCT through the lesion demonstrated a nodular mass with presumed superficial (arrows) and deep vascular-appearing structures (asterisk). B) Ultrasound biomicroscopy revealed a solid, echodense lesion, with relative hyperechogenicity in the anterior portion of the lesion (asterisk), and diffuse areas of small circular hypoechoic structures (white arrows) that may be vascular in nature.

weeks. The patient never presented for follow-up examination.

### 3. Discussion and conclusions

Syphilis is a sexually transmitted disease caused by *Treponema pallidum*, and its incidence has risen dramatically in the U.S. in the past two decades from 2.1 to 10.8 cases per 100,000 population from 2001 to 2018.<sup>1</sup> In this report, we demonstrate the rare finding of a vascularized syphilitic lesion of the iris utilizing multiple imaging modalities. Described previously during an era when syphilis was more commonly diagnosed, the spectrum of vascularized syphilitic iris masses consists of iris roseola or roseata, iris papulosa, iris nodosa, and iris gummata or granulomata.<sup>2</sup> These vascular inflammatory lesions typically present during the secondary stage of syphilis with concurrent systemic findings.<sup>2</sup> Iris roseola represent dilated iris capillaries or engorged vascular tufts and are thought to be a reaction to treponemal capillary emboli. These may expand and transform into vascularized papules, or iris

papulosa.<sup>2</sup> Iris papulosa appear as one or more nodular, richly vascular lesions that arise from deep tissue layers at the pupillary or ciliary border of the iris during active iritis and may be associated with posterior synechiae.<sup>2</sup> This stage of iris lesion most closely resembles the one described in our case. The further enlargement of iris papulosa to form larger yellow-red nodules is termed iris nodosa, which may persist for days or weeks before spontaneously resolving, leaving an area of localized iris atrophy.<sup>2</sup> In contrast to the prior described lesions, iris gummata are more often observed in the late stage as poorly vascular masses that undergo eventual degeneration with or without necrosis.<sup>2</sup>

Only a handful of vascular syphilitic iris lesions have been described in the literature to date likely owing to their transient nature, and none using AS-OCT (Table 1). Haug and Cunningham published a colorful slit lamp photograph of iris roseola.<sup>3</sup> Another publication presented images and iris fluorescein angiography of a case of mid-stromal iris papulosa that developed in a patient with secondary syphilis two days following completion of his course of penicillin.<sup>4</sup> The remainder of reports describe iris granulomata, which were found to emanate from the iris base with associated involvement of the ciliary body.<sup>5,6</sup> The granulomata appear as echodense lesions on ultrasonography.<sup>5,6</sup> Uniquely, UBM in our patient illustrated relative hyperechogenicity in the anterior portion of the lesion, which correlated with the superficial vascularity of the lesion seen on clinical examination and with the multiple vascular lumen appreciated on AS-OCT. With this report, we therefore characterize a rare finding that may be encountered in syphilitic uveitis and highlight that syphilis should be considered as a possible diagnosis for an undifferentiated vascular iris mass.

### Patient consent

Written consent to publish this case has not been obtained. This report does not contain any personal identifying information.

### Acknowledgments and disclosures

No funding or grant support.

### Authorship

All authors attest that they meet the current ICMJE criteria for Authorship.

**Table 1**  
Summary of syphilitic iris lesions reported in the literature.

Authors	Stage of Syphilis Diagnosed	Type of Iris Lesion	Imaging Characteristics of Iris Lesions
Haug and Cunningham <sup>3</sup>	Unspecified	Iris roseola	SL photograph: Dilated iris capillaries
Schwartz and O'Connor <sup>4</sup>	Secondary	Iris roseola and papulosa	SL photograph: Dilated superficial iris vessels with subsequent development of superficial papules in midstroma IFA: Early and late leakage from lesions
De Jong et al. <sup>5</sup>	Secondary	Iris granulomata	SL photograph: Translucent vascularized mass with iris dimpling UBM: Echodense lesion
McCarron and Albert <sup>6</sup>	Secondary	Iris granulomata	SL photograph: Vascular nonpigmented mass at ciliary border of iris IFA: Early filling of vessels leading to mass, and within the mass; diffuse late leakage UBM: Echodense lesion extending from the ciliary body into the anterior chamber
Chen et al. (Current report)	Secondary	Iris papulosa	SL photograph: Vascular iris lesion at pupillary border associated with posterior synechia UBM: Echodense lesion with relative hyperechogenicity of anterior surface, small circular hypochoic structures within lesion AS-OCT: Isoreflexive nodular mass with superficial and deep vascular lumen

SL = slit lamp.

IFA = iris fluorescein angiography.

UBM = ultrasound biomicroscopy.

AS-OCT = anterior segment optical coherence tomography.

### Declaration of competing interest

The authors declare that they have no known competing financial interests or personal relationships that could have appeared to influence the work reported in this paper.

### Acknowledgements

None.

### References

- Centers for Disease Control and Prevention. *Sexually Transmitted Disease Surveillance 2018*. Atlanta: U.S.: Dep. Health Hum. Serv.; 2019:24–31. <https://doi.org/10.15620/cdc.79370>.
- Duke-Elder S, Perkins ES. Diseases of the uveal tract. In: Duke-Elder S, ed. *System of Ophthalmology*. vol. 9. St. Louis: C.V. Mosby; 1966:292.
- Haug SJ, Cunningham ET Jr. Syphilitic uveitis. *Emerg Infect Uveitis*. doi:10.1007/978-3-319-23416-8\_4.
- Schwartz LK, O'Connor GR. Secondary syphilis with iris papules. *Am J Ophthalmol*. 1980;90:380–384.
- De Jong Y, Haverkort ME, Van Sorge AJ, et al. A translucent vascularized iris granuloma in a patient with secondary syphilis. *Lancet*. 2017;17:255–256.
- McCarron MJ, Albert DM. Iridocyclitis and an iris mass associated with secondary syphilis. *Ophthalmology*. 1984;91(10):1264–1268.