

UC Davis

UC Davis Previously Published Works

Title

The history and future of the cornual nerve block for calf disbudding.

Permalink

<https://escholarship.org/uc/item/9sn3h3fk>

Journal

JDS Communications, 5(4)

Authors

Sheedy, David

Aly, Sharif

Tucker, Cassandra

et al.

Publication Date

2024-07-01

DOI

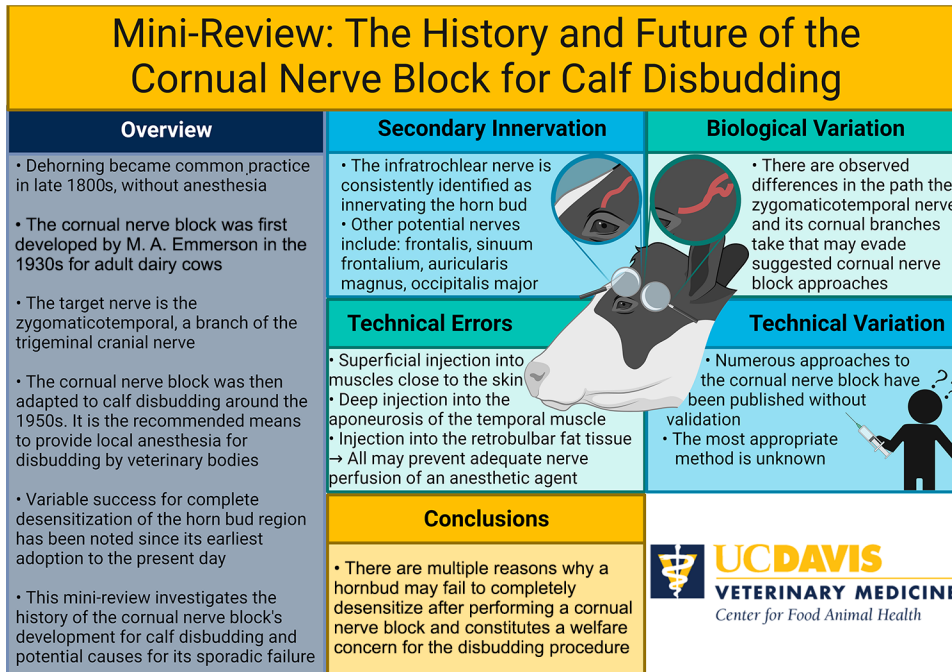
10.3168/jdsc.2023-0506

Peer reviewed

The history and future of the cornual nerve block for calf disbudding

David B. Sheedy,^{1,2*} Sharif S. Aly,^{1,3} Cassandra B. Tucker,⁴ and Terry W. Lehenbauer^{1,3}

Graphical Abstract




Summary

The cornual nerve block was developed to desensitize the horn in adult cows and subsequently adapted for disbudding calves. Failure to fully desensitize the horn bud region is often reported, resulting in numerous iterations of recommended blocking techniques without consensus on the most reliable and repeatable approach. Potential causes for nerve block failure include biologically important variation in the zygomaticotemporal nerve and its cornual branches, secondary innervation to the horn bud, and technical errors resulting in poor nerve perfusion with the chosen anesthetic agent. Revisiting regional perfusion may potentially circumvent the previously listed causes for failure. Without a consistent and reliable approach, the welfare of calves undergoing disbudding will be compromised. Graphical abstract created with BioRender.com.

Highlights

- The cornual nerve block was developed for desensitization of the horn in 1932.
- This block was subsequently adapted for disbudding in calves.
- Full desensitization is not always achieved with the cornual nerve block.
- Technical errors, biological variation, and secondary innervation may explain failure.
- Developing a consistent, effective block is necessary to protect calf welfare.



¹Veterinary Medicine Teaching and Research Center, School of Veterinary Medicine, University of California–Davis, Tulare, CA 93274, ²School of Life and Environmental Sciences, The University of Sydney, Camden, New South Wales, 2570, Australia, ³Department of Population Health and Reproduction, School of Veterinary Medicine, University of California–Davis, Tulare, CA 95616, ⁴Center for Animal Welfare, Department of Animal Science, University of California–Davis, Davis, CA 95616. *Corresponding author: david.sheedy@sydney.edu.au. © 2024, The Authors. Published by Elsevier Inc. on behalf of the American Dairy Science Association®. This is an open access article under the CC BY license (<http://creativecommons.org/licenses/by/4.0/>). Received September 28, 2023. Accepted February 05, 2024.

The history and future of the cornual nerve block for calf disbudding

David B. Sheedy,^{1,2*} Sharif S. Aly,^{1,3} Cassandra B. Tucker,⁴ and Terry W. Lehenbauer^{1,3}

Abstract: Disbudding damages the germinal horn bud cells and prevents subsequent horn growth in young calves. Hot-iron cauterization or caustic paste are the most common disbudding techniques and are unequivocally painful procedures. An important technique in controlling the acute pain experienced during disbudding is the cornual nerve block (CNB) that uses a local anesthetic agent and targets a branch of the trigeminal cranial nerve, the zygomaticotemporal nerve, as it travels along the temporal groove of the skull. Though CNB have been used since 1932, practitioners have reported variability in achieving full desensitization of the horn bud region since its inception. This failure may have led to the establishment of variations in the CNB technique, without consensus on a reliable and repeatable approach. Reasons for CNB failures may include technical errors by the practitioner, such as an injection into subcutaneous or deep muscle bodies; biologically important path variations in the zygomaticotemporal nerve and its cornual branches; and secondary innervation of the horn bud region, particularly the cornual branches of the infratrochlear nerve. Further investigation into documenting and understanding CNB failure and alternatives, such as regional perfusion, is warranted.

It is common practice in the dairy industry to prevent horn growth by removal of the germinal horn buds from young calves, typically at less than 8 wk of age, a process known as disbudding (Cozzi et al., 2015; NAHMS, 2016). It is reported that 94% of US dairy operations disbud calves, with hot-iron cauterization used in 55% of cases and caustic paste in 33% (NAHMS, 2016). Similarly, in the European Union 89% of dairy operations disbud, with cauterization used in 80% and caustic paste in 16%, inclusively (Cozzi et al., 2015). Disbudding is unequivocally painful with a long history of efforts to alleviate the immediate and chronic effects (Winder et al., 2018), including the development of the cornual nerve block (CNB; Emmerson, 1933). Incomplete desensitization can occur with the CNB and there is no consensus on the most reliable and repeatable approach for this block (Table 1). The objective of this mini-review is to present (1) the historical perspective and use of CNB in the context of dehorning/disbudding, (2) the subsequent development and technical variation of the CNB, (3) horn bud innervation and its impact on CNB effectiveness, (4) alternatives to the CNB for acute pain management, and (5) general and future considerations.

Efforts to remove or prevent horn growth have been the industry standard for over 100 yr (Haaff, 1886; Phares, 1889). An early advocate for dehorning was Herman Haaff, who sawed off the horns of an aggressive bull and later his entire herd following an attack by said bull (Kiner, 1910). The Humane Society of Illinois sought, unsuccessfully, to prosecute Haaff for cruelty to animals in 1885 for his actions (Haaff, 1886, 1888; Kiner, 1910). Haaff subsequently produced several instructional books (Haaff, 1886, 1888) under the moniker of the “Great Dehorner” and aided the rapid spread of dehorning across the United States and other nations. While any

discussion on dehorning as cruel was considered “absurd twaddle” from some contemporary veterinarians (Phares, 1889), the consensus among producers and veterinarians was that dehorning, though painful, did not constitute cruelty. Dehorning was not considered “inflicting unnecessary pain” given the benefits of raising calmer, safer animals to both the producer and animal (Haaff, 1888; Plumb, 1888; Roberts, 1893), a justification for hornless cattle that continues to be voiced (Kling-Eveillard et al., 2015; Marquette et al., 2023). As the practice of dehorning cattle spread, prosecutions also continued to be brought forward by concerned welfare groups and citizens, with results almost universally in favor of dehorning in North America, whereas Britain saw court decisions going both ways (Roberts, 1893). Ultimately the British parliament found consensus in favor of the animal welfare groups and enacted the Animals (Anaesthetics) Act (1919), which explicitly prohibited the dehorning of cattle above 1 mo of age, unless under a general anesthesia. This focus on general anesthesia may have inhibited the development of local anesthesia for dehorning in the United Kingdom, with the Act only being subsequently amended to allow for either general or local anesthesia in 1948 (His Majesty’s Stationery Office, 1949). The true consequence of ratifying the Act of 1919 is unclear; however, it may have increased the drive to disbud calves. For a long time, calves were not required to be provided with any analgesia or anesthesia for disbudding, despite legislation existing for their adult counterparts. While national veterinary associations strongly advocate for the use of anesthesia and analgesia (CVMA, 2022; AVMA, 2023) and nations are beginning to either ratify legislation (New Zealand, Belgium, UK) or self-regulate with market assurance programs that require effective pain mitigation regardless of cattle age (Cozzi et al., 2009, 2015;

¹Veterinary Medicine Teaching and Research Center, School of Veterinary Medicine, University of California–Davis, Tulare, CA 93274, ²School of Life and Environmental Sciences, The University of Sydney, Camden, New South Wales, 2570, Australia, ³Department of Population Health and Reproduction, School of Veterinary Medicine, University of California–Davis, Tulare, CA 95616, ⁴Center for Animal Welfare, Department of Animal Science, University of California–Davis, Davis, CA 95616. *Corresponding author: david.sheedy@sydney.edu.au. © 2024, The Authors. Published by Elsevier Inc. on behalf of the American Dairy Science Association®. This is an open access article under the CC BY license (<http://creativecommons.org/licenses/by/4.0/>). Received September 28, 2023. Accepted February 05, 2024.

Table 1. Examples of cornual nerve block technical variations that are presented in veterinary textbooks, extension pieces, and peer-reviewed publications

Technical aspects of the cornual nerve block	Citations that represent the range within the literature
Injected agent	
Anesthetic agent	Lidocaine (Weaver et al., 2018), procaine (Thomsen et al., 2021)
Volume per side	1.5 mL (Vickers et al., 2005), 4 mL (Sutherland et al., 2019), 5 mL (Stilwell et al., 2012), 6 mL (Reedman et al., 2020)
Buffered or concentrated	1:10 with sodium bicarbonate (Adcock and Tucker, 2020), 5% lidocaine (Doherty et al., 2007)
Epinephrine included	(Butler, 1967; Fierheller et al., 2012)
Time until disbudding	3–5 min (Weaver et al., 2018), 10 min (Adam et al., 2021), 15 min (Stilwell et al., 2012), 30 min (Doherty et al., 2007)
Hypodermic needle	
Needle gauge	18 G (Reedman et al., 2020), 20 G (Fierheller et al., 2012), 22 G (Adcock and Tucker, 2018)
Needle length	1.5 in/38 mm (Reedman et al., 2020), 1 in/25 mm (Adcock and Tucker, 2020)
Injection technique	
Angle of injection	Straight (Stuttgen and Van Os, 2020), ventromedial (Ames, 2013), 30° toward horn (Stewart and Alexander, 2016), 45° toward horn (UC Davis Center for Animal Welfare, 2020)
Distance from eye to horn base	Base of eye (UC Davis Center for Animal Welfare, 2020), 50% (Ames, 2013), 66% (Anderson, 2009)
Depth of injection	Inject at multiple depths per block (Anderson, 2009), subcutaneously (Stuttgen and Van Os, 2020), 0.5–1.5 cm (Stewart and Alexander, 2016)
Check for intravascular injection	(Anderson, 2009; Weaver et al., 2018)
Other considerations	
Additional regional anesthesia	Ring block (Vickers et al., 2005; Doherty et al., 2007; Adam et al., 2021), infratrochlear (Butler, 1967; Doherty et al., 2007)
Efficacy of desensitization tested	Pin pricks (Stilwell et al., 2012; Adcock and Tucker, 2020; Adam et al., 2021), upper eyelid ptosis (Weaver et al., 2018)

FARM, 2020; DFC, 2023), providing disbudding analgesia is still far from being universally practiced (Johnstone et al., 2021; Saraceni et al., 2021).

These first discussions on animal cruelty and dehorning of cattle occurred before effective local analgesic products were readily available. Synthetic local anesthetic agents such as procaine started to become widely available after 1904, and lidocaine (or lignocaine) was first marketed in 1949. The first published literature on the subject of providing local anesthesia for dehorning was from Emmerson in 1933. In a presentation, he noted the elevation of the veterinary profession through the use of local and general anesthetics and expressed a desire to introduce pain-mitigating procedures to the profession. The verbatim description for the procedure, developed for adult dairy cattle, from this seminal paper is as follows (Emmerson, 1933, p. 9–10):

The site of injection is located by drawing an imaginary line through the middle of the orbit and the middle of the base of the horn. About midway between the orbit and base of the horn on this imaginary line, the operator palpates with ease the lateral border of the extensive frontal bone. The hypodermic needle is inserted at this point and in a downward and inward direction keeping as close to the lateral border of the frontal bone as possible. A 20 gauge needle one and one half inches long is preferred. The needle is only inserted about half its length. About 5 c.c. of a 4% solution of procaine or any other good local anesthetic to which adrenalin has been added is then injected.

Though the technique has remained largely unchanged, numerous alterations have been recommended. Table 1 provides examples of technical variations in the CNB that have been reported in veterinary textbooks, peer-reviewed publications, and extension material. To the authors' knowledge, there are no available pub-

lished studies using a randomized study design that justifies one approach over another.

We have attempted to replicate specifically stated reasons for CNB failure by using tissue dye on calf cadavers (aged 0–6 wk) sent to our laboratory for nonrelated routine postmortem examination. These investigations confirmed that injection into the aponeurosis of the temporal muscle (Browne, 1938) was surprisingly easy to achieve despite the thickness of this aponeurosis being extremely small (~2 mm) in these calves (Figure 1a). It is possible to inject into the thin frontoscutularis muscle (involved in moving the ear) closely adherent to subcutaneous tissue when attempting a shallow subcutaneous injection (Figure 1b). Retro-orbital fat occupies the rostral portion of the temporal fossa and may be inadvertently injected if the needle is directly rostral, noted by Wheat (1950)

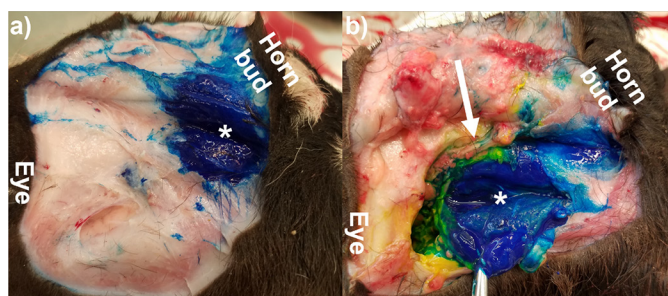


Figure 1. Postmortem examinations exemplifying 2 technical errors associated with the cornual nerve block. Blue tissue: dye (5 mL) was injected transcutaneously before dissection and was contained entirely within the muscle body, failing to perfuse the cornual nerve. (a) Injection into the superficially located frontoscutularis muscle (sectioned surface *); cornual nerve was medial and unseen. (b) Injection into the temporalis muscle aponeurosis; the white arrow indicates the unperfused cornual nerve.

who advocated for a more caudal injection site in adult cattle. In all 3 cases listed above, the structure being inadvertently injected was able to completely contain 5 mL of tissue dye, such that the cornual nerve would not have been exposed to the injected fluid. It is reasonable to assume that technical errors of this nature, which result in reduced exposure of an anesthetic agent to the cornual nerve, may contribute to sporadic CNB failures.

The development of numerous iterations to the CNB presumably follows from the experience of practitioners not satisfied with success in accomplishing a desired complete desensitization of the horn bud, as reported by Butler (1967) and by current practitioner anecdotes. Behavioral responses indicative of sensitivity during disbudding include vocalization, falling, rearing, kicking, tail wagging, defecation, and distinct head movements (Graf and Senn, 1999; Tschoner, 2021). Such escape behaviors are less frequently observed in calves provided local anesthesia compared with those disbudded without; however, these behaviors are often greater than a sham-disbudded group, indicating incomplete desensitization in some calves. Using a CNB, Morisse et al. (1995) reported 40% of calves displaying escape behaviors, whereas Bates et al. (2019) reported 55% ($n = 11/20$ calves). Thomsen et al. (2021) had 42% ($n = 70/167$) of calves displaying behavioral responses in calves sedated with xylazine and provided a procaine CNB. Grøndahl-Nielsen et al. (1999) observed increased escape behaviors in calves provided a CNB and hot-iron disbudded compared with calves sham-disbudded also with a CNB. Fierheller et al. (2012) reported a 12.5% failure rate ($n = 1/8$ calves, monitored with responses to ball electrodes up to 22 min), and Winder et al. (2017) had a 7.14% failure ($n = 2/30$ calves) in a study investigating on-line versus in-person CNB training techniques. Failure to effectively desensitize the horn bud, beyond technical errors, may also be due to biological variation in both the source and location of nerve branches that supply innervation to the horn bud.

Innervation of the horn region has been described by many authors and texts (Butler, 1967; Godinho, 1968; Godinho and Getty, 1975; Madekurozwa, 1996). The zygomaticotemporal nerve is considered the predominant nerve supply to the bovine horn, particularly for youngstock. The zygomaticotemporal nerve originates from the ophthalmic nerve (a branch of the trigeminal cranial nerve) and typically consists of a medial and lateral branch that join in the peri-orbit and travel caudally, ventral to the facial crest within the temporal fossa, with branches of cornual nerves splitting midway along this crest to supply innervation to the horn bud (Figure 2a). However, there are noted biologically important variations to the branching pattern and course that the zygomaticotemporal and its cornual nerves take in reaching the horn bud. Observed variations on gross dissection include the medial branch of the zygomaticotemporal exiting the orbit through a caudo-dorsal foramen in the orbital rim and never uniting with the lateral branch ($n = 1/25$, 4%; Madekurozwa, 1996); the medial branch of the zygomaticotemporal coursing within the periosteum of the temporal groove, either to unite caudally with the cornual nerves or run directly to the horn ($n = 3/32$, 9.4%; Lauwers and DeVos, 1966); cornual nerve branches that split from the zygomaticotemporal nerve rostral to the often instructed location for cornual nerve injection (midway or one-third distance from the horn base to eye [Wheat, 1950; Weaver et al., 2018], $n = 3/25$, 12% [Madekurozwa, 1996]). These anatomical variations may result in the cornual nerve evading the injected anesthetic agent and subsequently inadequate anesthesia.

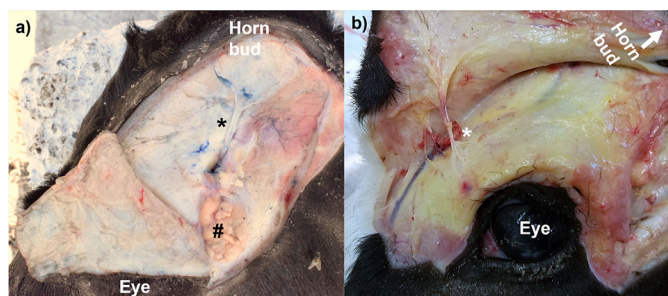


Figure 2. Postmortem examination of nerves supplying horn bud sensation. (a) The cornual nerve (*) exits the orbit, traverses the retro-orbital fat pad (#), and splits roughly midway to the horn bud. (b) The cornual branch of the infratrochlear nerve (*) exits over the orbital upper rim. Panel a image courtesy of Alycia Drwencke (University of California–Davis).

Although the zygomaticotemporal nerve is unanimously considered the predominant nerve supply to the bovine horn bud, authors note that blocking the infratrochlear nerve (Figure 2b) may be required to consistently achieve adequate desensitization (Butler, 1967; Godinho, 1968; Godinho and Getty, 1975; Madekurozwa et al., 2004). Butler, while investigating the innervation of the horn region for various farm species in 1967, performed a CNB with procaine on 10 calves. He noted that the rostral aspect of the base of the horn was sensitive to needle prick in 11 of the 20 blocks performed (55%). When he subsequently blocked the cornual branch of the infratrochlear nerve there was complete desensitization of the horn area. Likewise, Madekurozwa noted the uptake of a neurotracer in the cornual branches of the infratrochlear nerve from the horn bud, despite being unable to identify such branches extending to the horn region on gross dissection (Madekurozwa, 1996; Madekurozwa et al., 2004). Goat kid disbudding anesthesia protocols have long identified the infratrochlear nerve as requiring specific blocking (Edmondson, 2016) and this nerve was also identified in buffalo as requiring blocking to achieve adequate anesthesia (Fouad et al., 1979). Other nerves that have been presented as providing possibly important innervation to the horn bud region are the frontalis, sinuum frontalem, auricularis magnus, and the occipitalis major, but these nerves have yet to be identified as having clinical relevance in disbudding calves (Madekurozwa, 1996). Lauwers's dissection of adult bovine heads suggests that 26% ($n = 16/62$) would remain sensible after a CNB due to biological variations and secondary innervation (Lauwers and DeVos, 1966).

The initial development of the CNB was for adult dairy cows (Emmerson, 1933), and it is unclear when the block was first recommended specifically for youngstock. Though some practitioners have been advocating for local anesthesia to disbud since at least the 1950s, the earliest recommendations were not to use the CNB, but rather perform direct infiltration of the horn bud with an anesthetic agent (Gendreau, 1953). By the 1960s this infiltrative technique seemed to have lost favor to the CNB (Butler, 1967). However, the infiltrative approach is not without merit and may be worth re-investigating given potential advantages over the CNB, including not being affected by the biological variation of nerve locations or the importance of nerves beside the cornual nerve that supply sensation to the horn bud and arguably requiring less technical skill. Recently this approach has been investigated by

Bates et al. (2019), who used 2 injections of 1 mL of lidocaine near the horn bud of 4- to 5-wk-old calves before cauterization. They found improved results compared with the CNB regarding adverse behavior during disbudding, and the infiltrative approach required significantly less time to reach desensitization (measured by needle prick: mean 60 vs. 240 s). Using a ring block technique for local anesthesia has likewise found favorable results ($n = 8/8$ horns desensitized; Fierheller et al., 2012), though it requires more injections around the horn bud, limiting its on-farm practicality. Further infiltrative technique investigations will need to consider the holistic nature of disbudding including how the approach affects wound healing time, hemostasis, calf-age limitations, stress during injection, operational processes, and producer acceptance.

The practicality of disbudding on-farm has traditionally involved manual restraint with the aid of purpose-built calf chutes, head-halters, or brute strength. Sedation, typically the α -2 adrenergic agonist xylazine, allows for easy handling of calves and as well as providing short-acting analgesia (Abrahamsen, 2008). However, the strength of this analgesia provided is unlikely to clinically contribute to mitigating the acute pain of disbudding, as hot-iron cauterization will cause breakthrough pain responses if horn bud desensitization was inadequate (Grøndahl-Nielsen et al., 1999; Stilwell et al., 2010; Adam et al., 2021). The use of caustic paste to disbud calves also requires less physical restraint, owing to a delayed behavioral response, has been available to producers since at least the 1880s (Phares, 1889), and has been showing resurgent use on large dairies in North America (NAHMS, 2016; Saraceni et al., 2021). For example, of 217 Wisconsin dairy farmers, 61% report using caustic paste as their primary means of disbudding calves (Saraceni et al., 2021). Concerningly, there is an association between caustic paste use and reduced use of local anesthetics for disbudding: 6.0 times the odds (95% CI: 1.0–35.7) of using local anesthesia when not using caustic paste to disbud in an Ontario survey (Winder et al., 2016), and respondents to a Wisconsin survey used lidocaine blocks 17% of the time with caustic paste disbudding compared with 30% with hot-iron cauterization (Saraceni et al., 2021). Onset of pain (as measured with adverse behavioral responses, heart rate, cortisol, and increased sensitivity to horn region) is nonetheless rapid (within 10 min) and can be significantly reduced with the use of local anesthesia (Morisse et al., 1995; Winder et al., 2017; Reedman et al., 2020). Failure of complete desensitization following a CNB is of equal concern for caustic paste disbudding and hot-iron disbudding, and it may be particularly important to check the effectiveness of the CNB with pinpricks before applying paste, as there will not be the immediate behavioral response (compared with the iron) to indicate it is incomplete. Irrespective of disbudding technique, CNB analgesia is transient (e.g., less than 75 min in Adcock et al., 2020; 2–8 h in Fierheller et al., 2012). Consequently, alternative management strategies to address the longer-term (up to 14 wk) pain or hyperesthesia from disbudding are required (Adcock and Tucker, 2018, 2020; Winder et al., 2018).

In conclusion, occasional incomplete desensitization of the horn region may have led to multiple iterations of the CNB being recommended, without a consensus on the most reliable and repeatable approach. Potential causes for CNB failure include technical error, biological variation of the cornual nerve, and contribution of other nerves providing sensation to the horn region. Adapting local anesthesia approaches to include the infratrochlear nerve or a

form of infiltrative or ring block may increase the success of horn bud anesthesia; however, more research will be needed to validate these approaches.

References

- Abrahamsen, E. J. 2008. Chemical restraint in ruminants. *Vet. Clin. North Am. Food Anim. Pract.* 24:227–243. <https://doi.org/10.1016/j.cvfa.2008.02.005>.
- Adam, M., K. Salla, R. Aho, L. Hänninen, S. Taponen, M. Norring, M. Raekallio, and A. H. Hokkanen. 2021. A comparison of sedative effects of xylazine alone or combined with levomethadone or ketamine in calves prior to disbudding. *Vet. Anaesth. Analg.* 48:906–913. <https://doi.org/10.1016/j.vaa.2021.08.004>.
- Adcock, S. J. J., D. M. Cruz, and C. B. Tucker. 2020. Behavioral changes in calves 11 days after cauterization: Effect of local anesthesia. *J. Dairy Sci.* 103:8518–8525. <https://doi.org/10.3168/jds.2020-18337>.
- Adcock, S. J. J., and C. B. Tucker. 2018. The effect of disbudding age on healing and pain sensitivity in dairy calves. *J. Dairy Sci.* 101:10361–10373. <https://doi.org/10.3168/jds.2018-14987>.
- Adcock, S. J. J., and C. B. Tucker. 2020. Conditioned place preference reveals ongoing pain in calves 3 weeks after disbudding. *Sci. Rep.* 10:3849. <https://doi.org/10.1038/s41598-020-60260-7>.
- AVMA (American Veterinary Medical Association). 2023. Castration and Dehorning of Cattle. Accessed Nov. 9, 2021. <https://www.avma.org/resources-tools/avma-policies/castration-and-dehorning-cattle>.
- Ames, N. K. 2013. Local and regional anesthesia. Pages 19–38 in Noordsy's Food Animal Surgery. 5th ed. John Wiley and Sons. <https://doi.org/10.1002/9781118770344.ch3>.
- Anderson, N. 2009. Dehorning of Calves. Ministry of Agriculture, Food and Rural Affairs, Order: 09–003.
- Animals (Anaesthetics) Act. 1919. 9 & 10 Geo. 5 c.54, United Kingdom.
- Bates, A. J., M. A. Sutherland, F. Chapple, S. K. Dowling, A. P. Johnson, B. Saldias, and J. Singh. 2019. A new method of administering local anesthesia for calf disbudding: Findings from a comparative on-farm study in New Zealand. *J. Dairy Sci.* 102:2492–2506. <https://doi.org/10.3168/jds.2018-15033>.
- Browne, T. G. 1938. The technique of nerve-blocking for dehorning cattle. *Vet. Rec.* 50:1336–1337.
- Butler, W. F. 1967. Innervation of the horn region in domestic ruminants. *Vet. Rec.* 80:490–492. <https://doi.org/10.1136/vr.80.16.490>.
- CVMA (Canadian Veterinary Medical Association). 2022. Horn Management of Cattle – Position Statement. Accessed May 31, 2024. <https://www.canadianveterinarians.net/policy-and-outreach/position-statements/statements/horn-management-of-cattle/>.
- Cozzi, G., F. Gottardo, M. Brscic, B. Contiero, N. Irrgang, U. Knierim, O. Pentelescu, J. J. Windig, L. Mirabito, F. Kling Eveillard, A. C. Dockes, I. Veissier, A. Velarde, C. Fuentes, A. Dalmau, and C. Winckler. 2015. Dehorning of cattle in the EU Member States: A quantitative survey of the current practices. *Livest. Sci.* 179:4–11. <https://doi.org/10.1016/j.livsci.2015.05.011>.
- Cozzi, G., P. Prevedello, A. Boukha, A. Winckler, U. Knierim, O. Pentelescu, J. Windig, L. Mirabito, F. Kling-Eveillard, A. C. Dockes, I. Veissier, A. Verlarde, C. Fuentes, and A. Dalmau. 2009. D.2.1.1. Report on Dehorning Practices across EU Member States. Accessed Nov. 5, 2021. http://www.vuzv.sk/DB-Welfare/telata/calves_alcasde_D-2-1-1.pdf.
- Dairy Farmers of Canada (DFC). 2023. ProAction Reference Manual. Accessed Sep. 14, 2023. <https://www.dairyfarmers.ca/proaction/resources/overview>.
- Doherty, T. J., H. G. Kattesh, R. J. Adcock, M. G. Welborn, A. M. Saxton, J. L. Morrow, and J. W. Dailey. 2007. Effects of a concentrated lidocaine solution on the acute phase stress response to dehorning in dairy calves. *J. Dairy Sci.* 90:4232–4239. <https://doi.org/10.3168/jds.2007-0080>.
- Edmondson, M. A. 2016. Local, regional, and spinal anesthesia in ruminants. *Vet. Clin. North Am. Food Anim. Pract.* 32:535–552. <https://doi.org/10.1016/j.cvfa.2016.05.015>.
- Emmerson, M. A. 1933. Nerve blocking in the dehorning of cattle. *Vet. Ext. Q.* 50:5–18.
- Farmers Assuring Responsible Management (FARM). 2020. Animal Care Reference Manual Version 4 2020–2022. Accessed Sep. 14, 2023. <https://nationaldairyfarm.com/dairy-farm-standards/animal-care/farm-animal-care-version-4/>.

- Fierheller, E. E., N. A. Caulkett, D. B. Haley, D. Florence, and L. Doepel. 2012. Onset, duration and efficacy of four methods of local anesthesia of the horn bud in calves. *Vet. Anaesth. Analg.* 39:431–435. <https://doi.org/10.1111/j.1467-2995.2012.00717.x>.
- Fouad, K., M. Shokry, and L. Fahmy. 1979. Anaesthesia of the horn in buffalo. *Zentralblatt für Veterinärmedizin R. A* 26:78–82. <https://doi.org/10.1111/j.1439-0442.1979.tb00652.x>.
- Gendreau, L. A. 1953. The dehorning of cattle. *Can. J. Comp. Med. Vet. Sci.* 17:344.
- Godinho, H. 1968. A comparative anatomical study of the cranial nerves in goat, sheep and bovine (*Capra hircus*, *Ovis aries* and *Bos taurus*): Their distribution and related autonomic components. Retrospective Theses Diss. 294–345. PhD Diss., Department of Veterinary Anatomy, Iowa State University, Ames, IA. <https://doi.org/10.31274/rtd-180813-889>.
- Godinho, H. P., and R. Getty. 1975. Ruminant nervous system: Peripheral nervous system: Cranial nerves, part 1 bovine. 5th ed. R. Getty, ed. Saunders, Philadelphia, PA.
- Graf, B., and M. Senn. 1999. Behavioural and physiological responses of calves to dehorning by heat cauterization with or without local anaesthesia. *Appl. Anim. Behav. Sci.* 62:153–171. [https://doi.org/10.1016/S0168-1591\(98\)00218-4](https://doi.org/10.1016/S0168-1591(98)00218-4).
- Grøndahl-Nielsen, C., H. B. Simonsen, J. Damkjær Lund, and M. Hesselholt. 1999. Behavioural, endocrine and cardiac responses in young calves undergoing dehorning without and with use of sedation and analgesia. *Vet. J.* 158:14–20. <https://doi.org/10.1053/tvjl.1998.0284>.
- Haaff, H. H. 1886. Dehorning Cattle, Castration of Bulls, Cattle Sheds, and Warm Drinking Water. Rand, McNally & Co., Printers and Engravers, Heman's Grove, IL.
- Haaff, H. H. 1888. Haaff's Practical Dehorner or Every Man His Own Dehorner. The Clark and Longley Company, Printers and Publishers, Chicago, IL.
- His Majesty's Stationery Office. 1949. Statutory Instruments Other than Those of a Local, Personal or Temporary Character for the Year 1948. London, UK.
- Johnstone, E. C. S., J. F. Coetzee, P. J. Pinedo, and L. Edwards-Callaway. 2021. Current attitudes of veterinarians and producers regarding the use of local and systemic analgesia in beef and dairy cattle in the United States. *J. Am. Vet. Med. Assoc.* 258:197–209. <https://doi.org/10.2460/javma.258.2.197>.
- Kiner, H. L. 1910. History of Henry County, Illinois. Pioneer Publishing Company, Chicago, IL.
- Kling-Eveillard, F., U. Knierim, N. Irrgang, F. Gottardo, R. Ricci, and A. C. Dockès. 2015. Attitudes of farmers towards cattle dehorning. *Livest. Sci.* 179:12–21. <https://doi.org/10.1016/j.livsci.2015.05.012>.
- Lauwers, H., and N.R. DeVos. 1966. Innervatie van de hoorn bij het rund in verband met het verloop van de ophthalmicus. *Vlaams dierengeneeskundig Tijdschr.* 35:451.
- Madekurozwa, M.-C., M. Purton, and J. S. Boyd. 2004. Re-examination of horn innervation in cattle using Fluorogold. *Zimbabwe Vet. J.* 31:65–72. <https://doi.org/10.4314/zvj.v31i2.5359>.
- Madekurozwa, M.-C. N. 1996. Studies on the development and innervation of the bovine and caprine horn. University of Glasgow, Glasgow.
- Marquette, G. A., S. Ronan, and B. Earley. 2023. Calf disbudding – animal welfare considerations. *J. Appl. Anim. Res.* 51:616–623. <https://doi.org/10.1080/09712119.2023.2264912>.
- Morisse, J. P., J. P. Cotte, and D. Huonnic. 1995. Effect of dehorning on behaviour and plasma cortisol responses in young calves. *Appl. Anim. Behav. Sci.* 43:239–247. [https://doi.org/10.1016/0168-1591\(95\)00569-E](https://doi.org/10.1016/0168-1591(95)00569-E).
- National Animal Health Monitoring System (NAHMS). 2016. Dairy 2014: Dairy cattle management practices in the United States. Fort Collins, CO.
- Phares, D. L. 1889. Dishorning. Mississippi Agricultural Experiment Station, Agricultural College, MS.
- Plumb, C. S. 1888. History and Reorganization. Dehorning Cattle. University of Tennessee Agricultural Experiment Station, Knoxville, TN.
- Reedman, C. N., T. F. Duffield, T. J. DeVries, K. D. Lissemore, N. A. Karrow, Z. Li, and C. B. Winder. 2020. Randomized control trial assessing the efficacy of pain control strategies for caustic paste disbudding in dairy calves younger than 9 days of age. *J. Dairy Sci.* 103:7339–7350. <https://doi.org/10.3168/jds.2019-18118>.
- Roberts, I. P. 1893. Dehorning. Cornell University Agricultural Experiment Station, Ithaca, NY.
- Saraceni, J., C. B. Winder, D. L. Renaud, C. Miltenburg, E. Nelson, and J. M. C. Van Os. 2021. Disbudding and dehorning practices for preweaned dairy calves by farmers in Wisconsin, USA. *J. Dairy Sci.* 104:11995–12008. <https://doi.org/10.3168/jds.2021-20411>.
- Stewart, K., and D. Alexander. 2016. Regional anaesthesia of the bovine head. *Livestock (Lond.)* 21:354–360. <https://doi.org/10.12968/live.2016.21.6.354>.
- Stilwell, G., R. C. Carvalho, N. Carolino, M. S. Lima, and D. M. Broom. 2010. Effect of hot-iron disbudding on behaviour and plasma cortisol of calves sedated with xylazine. *Res. Vet. Sci.* 88:188–193. <https://doi.org/10.1016/j.rvsc.2009.06.012>.
- Stilwell, G., M. S. Lima, R. C. Carvalho, and D. M. Broom. 2012. Effects of hot-iron disbudding, using regional anaesthesia with and without carprofen, on cortisol and behaviour of calves. *Res. Vet. Sci.* 92:338–341. <https://doi.org/10.1016/j.rvsc.2011.02.005>.
- Stuttgen, S., and J. Van Os. 2020. Disbudding Calves. University of Wisconsin–Madison Livestock Extension, Madison, WI.
- Sutherland, M. A., F. J. Huddart, and M. Stewart. 2019. Short communication: Evaluation of the efficacy of novel disbudding methods for dairy calves. *J. Dairy Sci.* 102:666–671. <https://doi.org/10.3168/jds.2018-15230>.
- Thomsen, P. T., J. H. Hansen, and M. S. Herskin. 2021. Dairy calves show behavioural responses to hot iron disbudding after local anaesthesia with procaine. *Vet. Rec.* 188:e52. <https://doi.org/10.1002/vetr.52>.
- Tschoner, T. 2021. Methods for pain assessment in calves and their use for the evaluation of pain during different procedures—A review. *Animals (Basel)* 11:1235. <https://doi.org/10.3390/ani11051235>.
- UC Davis Center for Animal Welfare. 2020. Disbudding calves. Accessed Feb. 25, 2022. <https://www.youtube.com/watch?v=liv9orxiFW0>.
- Vickers, K. J., L. Niel, L. M. Kiehlbauch, and D. M. Weary. 2005. Calf response to caustic paste and hot-iron dehorning using sedation with and without local anesthetic. *J. Dairy Sci.* 88:1454–1459. [https://doi.org/10.3168/jds.S0022-0302\(05\)72813-7](https://doi.org/10.3168/jds.S0022-0302(05)72813-7).
- Weaver, A. D., O. Atkinson, G. St. Jean, and A. Steiner. 2018. General considerations and anaesthesia. Pages 29–30 In *Bovine Surgery and Lameness*. 3rd ed. John Wiley & Sons Ltd.
- Wheat, J. D. 1950. New landmark for cornual nerve block. *Vet. Med.* 45:29–30.
- Winder, C. B., S. J. LeBlanc, D. B. Haley, K. D. Lissemore, M. A. Godkin, and T. F. Duffield. 2016. Practices for the disbudding and dehorning of dairy calves by veterinarians and dairy producers in Ontario, Canada. *J. Dairy Sci.* 99:10161–10173. <https://doi.org/10.3168/jds.2016-11270>.
- Winder, C. B., S. J. LeBlanc, D. B. Haley, K. D. Lissemore, M. A. Godkin, and T. F. Duffield. 2017. Comparison of an online learning module to hands-on training in teaching a cauterization technique for dairy calves including cornual nerve block application. *Can. Vet. J.* 58:735–740. <https://doi.org/10.3168/jds.2017-13217>.
- Winder, C. B., C. L. Miltenburg, J. M. Sargeant, S. J. LeBlanc, D. B. Haley, K. D. Lissemore, M. A. Godkin, and T. F. Duffield. 2018. Effects of local anesthetic or systemic analgesia on pain associated with cauterization disbudding in calves: A systematic review and meta-analysis. *J. Dairy Sci.* 101:5411–5427. <https://doi.org/10.3168/jds.2017-14092>.

Notes

- David B. Sheedy  <https://orcid.org/0000-0001-6671-432X>
 Sharif S. Aly  <https://orcid.org/0000-0003-0330-5013>
 Cassandra B. Tucker  <https://orcid.org/0000-0002-6014-444X>
 Terry W. Lehenbauer  <https://orcid.org/0000-0003-0896-3939>

Funding was provided by the Edward E. Hills Fund for Educational Outreach for the Humane Treatment of Food Animals (Woodside, CA). The authors thank the California Animal Health and Food Safety Lab System, Tulare, for allowing access to postmortem specimens.

No human or animal subjects were used, so this analysis did not require approval by an Institutional Animal Care and Use Committee or Institutional Review Board.

The authors have not stated any conflicts of interest.

Nonstandard abbreviations used: CNB = cornual nerve block.