

UCSF

UC San Francisco Previously Published Works

Title

Use of Posterior Hamstring Harvest During Anterior Cruciate Ligament Reconstruction in the Pediatric and Adolescent Population

Permalink

<https://escholarship.org/uc/item/9rz3714x>

Journal

Orthopaedic Journal of Sports Medicine, 6(6)

ISSN

2325-9671

Authors

Khanna, Krishn
Janghala, Abhinav
Pandya, Nirav K

Publication Date

2018-06-01

DOI

10.1177/2325967118775597

Copyright Information

This work is made available under the terms of a Creative Commons Attribution-NonCommercial-NoDerivatives License, available at <https://creativecommons.org/licenses/by-nc-nd/4.0/>

Peer reviewed

Use of Posterior Hamstring Harvest During Anterior Cruciate Ligament Reconstruction in the Pediatric and Adolescent Population

Krishn Khanna,* MD, Abhinav Janghala,* BA, and Nirav K. Pandya,*[†] MD

Investigation performed at UCSF Benioff Children's Hospital Oakland, Oakland, California, USA

Background: Posterior hamstring harvest has been described in the adult population in a limited fashion, but no study is available describing the use of posterior hamstring harvest in an active pediatric and adolescent cohort. At times, surgeons may be faced with a challenging anterior harvest due to patient anatomic characteristics, particularly the anatomic features and size of the pes tendons. Clinicians need to have multiple harvest approaches at their disposal. Complications with hamstring harvest such as premature graft transection are more problematic in this population due to higher failure rates with allograft tissue. The posterior harvest via its more proximal location may allow for easier tendon identification, visualization of the accessory attachments, and longer preserved tendon length if transection error occurs when the anterior approach is avoided based on surgical technique, patient anatomic characteristics, and surgeon and patient preference.

Purpose: To describe the technique of a posterior hamstring harvest in pediatric and adolescent patients and to analyze complications.

Study Design: Case series; Level of evidence, 4.

Methods: This study was a retrospective review of a consecutive series of pediatric and adolescent patients who underwent posterior hamstring harvest. During surgery, the patient's leg was abducted and externally rotated to expose the posteromedial aspect of the knee. A 2-cm incision was made overlying the palpable medial hamstring at the popliteal crease. The posterior hamstring tendons were first harvested proximally with an open tendon stripper and distally with a closed stripper. Preoperative, intraoperative, and postoperative findings and complications were analyzed.

Results: A total of 214 patients (mean \pm SD age, 15.7 ± 4.1 years; range, 8.0–19.8 years) underwent posterior harvest, with a mean \pm SD follow-up of 1.83 ± 1.05 years. No complications occurred in our series related to graft harvest—no graft transections, neurovascular injuries, secondary procedures for wound healing or closure, cosmetic concerns, or limitations in return to activity due to the posterior incision.

Conclusion: The posterior hamstring harvest is a safe and reliable technique to harvest autograft tendon in pediatric and adolescent anterior cruciate ligament reconstructions. The posterior technique entailed no complications related to harvest. No patients expressed any cosmetic concerns about their incision or had limitations in return to sport due to the posterior harvest.

Keywords: pediatric ACL reconstruction; hamstring autograft; hamstring tendon harvest; ACL

Anterior cruciate ligament (ACL) injuries in the pediatric and adolescent population are rapidly increasing, with a concomitant increase in surgical reconstruction attributable

to the decreased risk of meniscal and chondral injury with surgery.⁴ Reports of successful intra-epiphyseal, partial transphyseal, and fully transphyseal techniques have allowed for surgical reconstruction while patients are skeletally immature.⁷ Open physes preclude the use of bone-patellar tendon-bone reconstruction, and the use of allograft in this age group has a several-fold higher failure rate.^{8–10} As a result, autograft hamstring tissue has become the preferred graft choice for this patient population. Quadriceps tendon autografts are also a potential graft option for the skeletally immature population, although further study is necessary.

The traditional method for harvesting the hamstring tendons involves locating them at the pes anserine and harvesting them through an anteromedial incision. Numerous anatomic studies have demonstrated the location, anatomic

[†]Address correspondence to Nirav K. Pandya, MD, UCSF Benioff Children's Hospital Oakland, Department of Pediatric Orthopaedic Surgery, 747 52nd Street, Oakland, CA 94609, USA (email: Nirav.Pandya@ucsf.edu) (Twitter: @DrNiravPandya).

*Department of Orthopedic Surgery, University of California San Francisco, Benioff Children's Hospital, Oakland, California, USA.

One or more of the authors has declared the following potential conflict of interest or source of funding: N.K.P. is a consultant for Orthopediatrics.

Ethical approval for this study was waived by the UCSF Benioff Children's Hospital Oakland.

variation, and accessory attachments of the gracilis and semitendinosus tendon insertion on the pes.^{3,13,16,21} Many surgeons use the anterior technique in a facile and reproducible manner. Yet, as with any technique, certain technical factors must be taken into consideration, including the inability to separate the hamstrings (or the need to blindly separate them) due to a conjoint tendon insertion, amputation of the tendons due to deviation caused by accessory attachments from the tendons to the gastrocnemius, saphenous nerve injury, wound healing, and a large anterior scar (cosmesis).^{12,19,23}

Surgeons should use a hamstring harvesting technique with which they are comfortable and which allows them to readily identify the tendons and avoid premature amputation. Each technique entails multiple risks and benefits, and the surgeon must weigh each with regard to patient anatomic features, surgical technique, and patient preference. Inadequate graft harvest can be far costlier in the pediatric and adolescent patient, whose tendons are already small and who may have a higher failure rate with hybrid allograft augmentation.²

Prodromos et al^{14,15} described an alternative hamstring harvesting technique in adult patients, in which a posterior mini-incision was used to identify and begin the harvest.^{11,12} When the hamstring harvest was begun more proximally on the hamstrings, pitfalls were avoided and excellent clinical results were obtained—particularly, excellent cosmesis and no graft transections. The authors noted that they could consistently identify both tendons, identify and section the accessory semitendinosus, limit the risk of graft transection, and do so in a safe and cosmetic fashion.¹⁵

A recent anatomic study examining the posterior approach demonstrated that the tendons were located 14.4 mm (gracilis) and 24 mm (semitendinosus) from the medial edge of the knee, and that in 90% of the cases, the accessory semitendinosus connection toward the medial gastrocnemius muscle could be directly visualized; lack of such visualization is a common cause of premature transection from an anterior approach. The posterior approach is directly over the accessory connection, which can allow easier visualization. In addition, saphenous nerve branches were protected by the sartorius muscle.¹⁷

The posterior approach can be beneficial for multiple reasons, including easily identifiable tendons that are palpable in the posteromedial knee without a conjoint insertion, increased tendon length if amputation does occur due to a more proximal harvest away from gastrocnemius attachments, and a harvest site distinct from tibial tunnel placement.

This study aimed to analyze the posterior mini-incision hamstring harvesting technique in the pediatric and adolescent patient population, which has not been reported previously. We hypothesized that the posterior hamstring harvest is a safe, reliable, and reproducible technique with a minimal risk of graft transection and wound healing complications.

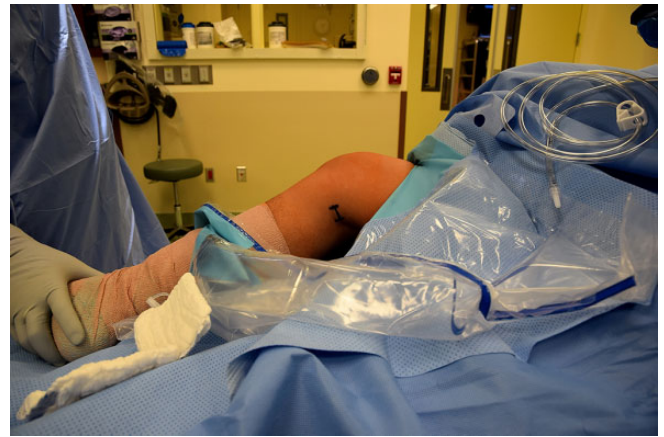

Figure 1. A 2- to 3-cm incision is made in the posteromedial aspect of the operative leg. Flexion and external rotation help provide access to the medial hamstring tendons.

METHODS

This study was a retrospective review of a series of consecutive pediatric and adolescent patients who underwent ACL reconstruction by a single surgeon (N.K.P.) from September 2011 to May 2017 using a posterior hamstring harvesting technique. Patients were included in the study if they were present for at least 6 months of follow-up. Progress notes and operative reports were reviewed. Preoperative, intraoperative, and postoperative findings and complications were recorded and analyzed—in particular, graft transections, neurovascular injuries, infection rate, secondary procedures for wound healing and closure, cosmetic concerns, and limitations in return to activity due to the posterior incision. Institutional review board exemption for this study was obtained from our institution.

Surgical Technique

After arthroscopy, the supine patient's leg was abducted and externally rotated to expose the posteromedial aspect of the knee. It is critical to drape the thigh in a manner that allows adequate proximal exposure. A 2- to 3-cm transverse incision was made overlying the palpable medial hamstrings at the popliteal crease (Figure 1). Caution must be taken to avoid damaging the tendon with the initial skin incision, particularly in children with minimal soft tissue posteriorly. The fascia overlying the tendons was released. The more lateral semitendinosus was identified, as was the more medial gracilis (Figures 2 and 3). The two tendons were bluntly dissected to their anterior insertion and more proximally past the accessory bands.

The tendon harvest was started proximally with an open tendon stripper (Figure 4) releasing the proximal attachment. The accessory connections between the tendons and surrounding fascia, particularly the semitendinosus and the medial gastrocnemius, must be identified and sharply transected adjacent to the tendon to allow an obstacle-free harvest (Figure 5). The proximal end of the tendon was

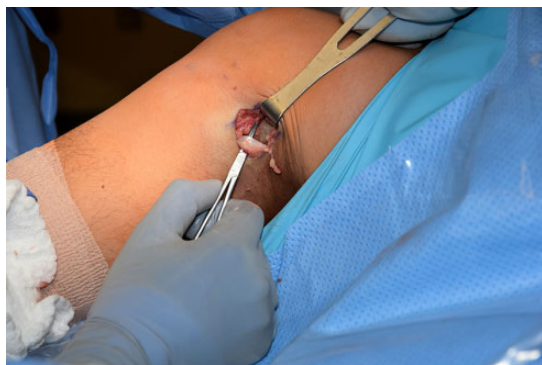

Figure 2. After dissection through the superficial tissues and fascia, the semitendinosus tendon is identified.

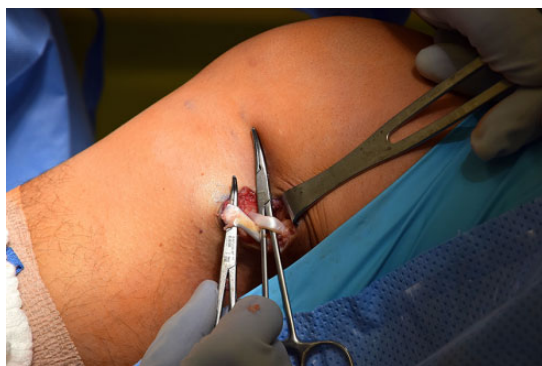


Figure 3. Intraoperative picture demonstrating the semitendinosus and gracilis tendons identified.

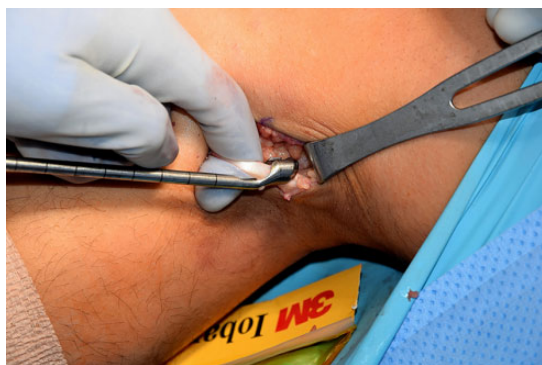

Figure 4. After dissection of the tendon free from the surrounding tissue, an open tendon stripper is directed proximally to harvest the hamstring tendon.

then placed through a closed tendon stripper and was released distally (Figure 6). The procedure was repeated with the second tendon. The wound was then copiously irrigated. The subcutaneous tissue was closed with an interrupted No. 3-0 Vicryl suture (Ethicon) followed by a No. 4-0 Monocryl suture (Ethicon) placed in a running fashion for the skin. The wound was then sealed with a skin adhesive (Ethicon).

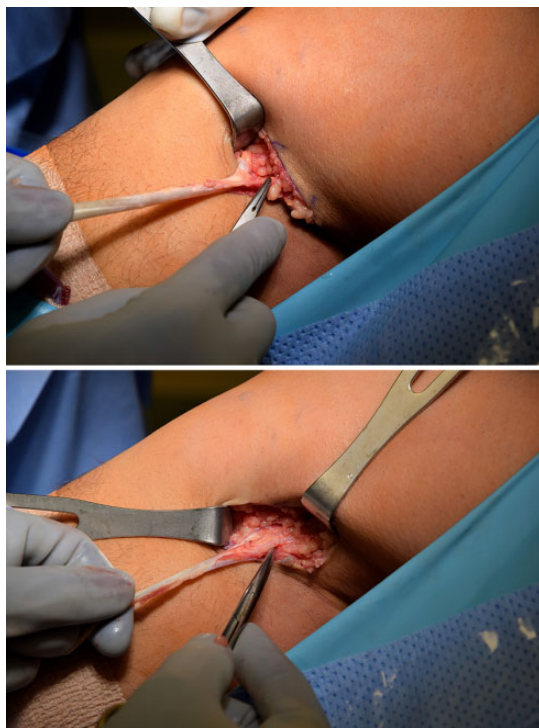


Figure 5. After proximal tendon harvest, fascial bands from the tendon to the medial gastrocnemius muscle are directly identified and removed. These cannot be easily visualized from an anterior approach.

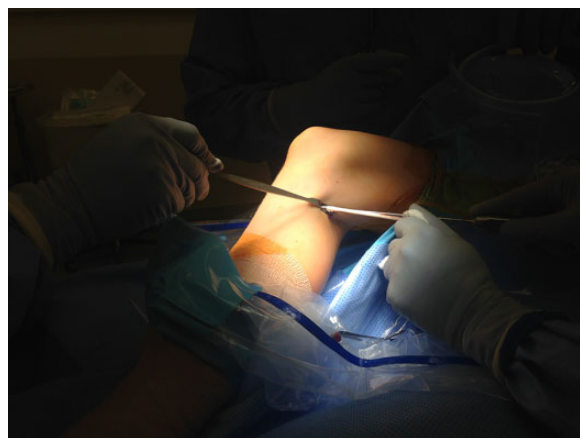

Figure 6. A closed tendon stripper is used to harvest the tendon distally toward the insertion on the anteromedial tibia.

After diagnostic arthroscopy, meniscal-chondral intervention, and the hamstring harvest were completed, a small stab incision was made via an outside-in drilling technique to create the femoral tunnel. This was followed by a 0.5-cm anterior incision to drill the tibial tunnel. Patients who were noted to be Tanner stages 1 and 2 underwent intraepiphyseal femoral tunnel placement and transphyseal tibial tunnel placement; fluoroscopic guidance was used to ensure that drilling took place medial to the tibial

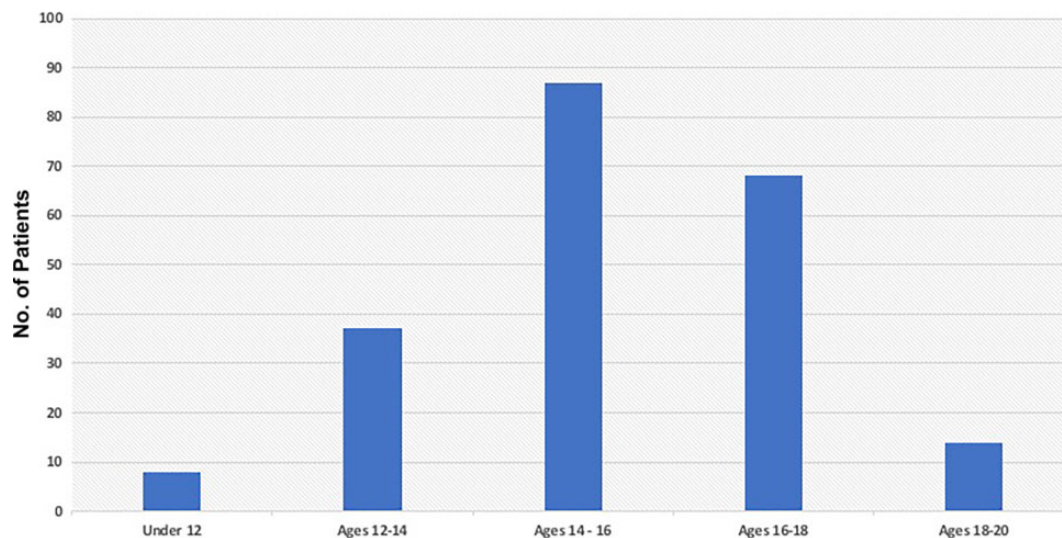


Figure 7. Age distribution of patients in the study.

tubercle and that hardware was not placed across the physis. In patients who were Tanner stages 3 and 4, a soft tissue graft with a transphyseal tunnel on both the femoral and tibial sides with drill hole diameters less than 9 mm was used. Tanner stage 5 patients underwent standard adult-style drilling techniques. Femoral fixation was achieved via suspensory fixation (Smith and Nephew), and tibial fixation was achieved via biointerference screw fixation (Smith and Nephew).

Standard skin closure was performed, and a nonadherent dressing was placed on the hamstring incision for the first week after surgery. Immediate range of motion was allowed after surgery.

RESULTS

During the study period, 214 patients underwent hamstring tendon harvest via the aforementioned technique. The mean \pm SD patient age was 15.7 ± 4.1 years (range, 8.0-19.8 years). The age breakdown of the patients was as follows: younger than 12 years (8 patients), 12-14 years (37 patients), 14-16 years (87 patients), 16-18 years (68 patients), and 18-20 years (14 patients) (Figure 7). Mean \pm SD follow-up was 1.83 ± 1.05 years. All patients were observed for a minimum of 6 months after surgery. Both tendons were identified during all harvests, and no premature graft transections occurred during harvesting of the tendons. There were no neurovascular injuries. No patients required a return to the operating room for wound healing or closure. One case of septic arthritis occurred (0.4%). No patients had range of motion deficits due to the posterior scar, complaints of pain over the scar, or cosmetic concerns.

DISCUSSION

The results of our study demonstrate that the posterior hamstring harvest is a safe and reliable option for the

pediatric and adolescent patient undergoing ACL reconstruction. We noted no graft transections, neurovascular injuries, secondary procedures for wound healing and closure, cosmetic concerns, or limitations in return to activity due to the posterior incision.

Prodromos et al^{14,15} originally described the posterior mini-incision technique in adult patients undergoing ACL reconstruction. When performing a traditional anterior approach, the surgeon must be cognizant of conjoint tendon insertions, which are accessory attachments to the gastrocnemius that cannot be directly visualized and which can cause premature transection, nerve injury, and at times a larger scar, which in turn may cause healing, cosmetic, and infectious issues.^{12,17,19,23} The posterior approach provides another option that can be used based on surgeon preference, patient anatomic features, and the reconstruction technique used.

For pediatric and adolescent patients, the surgeon must use a technique that safely and reliably obtains autograft tissue, because the risk of morbidity increases if allograft augmentation has to be used due to harvesting complications such as transection.^{8,9} In younger patients who may have underdevelopment of the pes anserine tendons, it can be difficult for clinicians to feel the insertion of the medial hamstring tendons onto the pes anserine as well as distinguish between the semitendinosus and the gracilis, placing the graft at risk for amputation during the harvest. The posterior technique can be used as an option in this situation.

The posterior approach has certain anatomic advantages. By beginning more proximally, this technique allows the surgeon to expose the tendons at a point where they have bifurcated, generally 18 mm proximal to the insertion site.¹³ Accidental harvest of the medial collateral ligament, which lies one layer deeper than the hamstring tendons at their insertion site,²² is also impossible with the posterior approach because the harvest site is proximal to the medial collateral ligament. Furthermore, in certain situations the posterior approach may allow for improved identification of

accessory attachments to the hamstring tendons. This is especially important for the semitendinosus, which can have accessory attachments in 90% to 100% of patients.^{3,16,17} These attachments are highly variable and can be as far proximal as 14 cm from the insertion site.¹⁶

The subcutaneous location of the hamstring tendons in this area (and their bifurcated nature in this location) may allow for a more rapid harvest in some situations. If graft transection does occur with this technique, the more proximal location of the incision may allow for salvage of a tendon of adequate length that may not necessitate allograft augmentation.

Two potential concerns with the posterior approach include healing of the posterior wound and difficulty accessing the posterior aspect of the knee. We found a 100% rate of wound healing, and no returns to the operating room were necessary to revise or close the wound. In addition, the increased flexibility of pediatric patients with a decreased amount of posterior adipose tissue makes accessing the posterior aspect of the knee quite easy.

The posterior approach may avoid potential donor site morbidity from a large anterior incision. Although the hamstring tendon autograft is thought to minimize the incidence of anterior knee symptoms relative to a bone-patellar tendon-bone autograft,^{5,6,18} studies suggest that anterior knee symptoms persist in 12% to 23% of patients even after hamstring tendon harvest.^{5,6,20} The soft tissue disruption from the anterior harvest incision resulting in these anterior knee symptoms may be reduced by use of the posterior mini-incision, although we did not specifically analyze this in our study. In addition, hamstring ACL reconstructions entail a higher rate of infection compared with bone-patellar tendon-bone reconstructions.¹ The digital manipulation that occurs with hamstring harvest through the same incision that is used to drill the tibial tunnel and place fixation (i.e. a biointerference screw) may account for the increased infection risk, although this is conjecture and not a reason to choose this technique over another harvesting strategy. By eliminating anterior digital manipulation to a certain extent, the posterior incision technique may decrease infection rates. Further study is necessary to determine the cause of higher rates of hamstring infection.

The strengths of this study include a well-described surgical technique reported for the first time in pediatric and adolescent patients, a large sample size, consistency in the surgical technique, and close follow-up for complications. Weaknesses of this study are that it is a single-surgeon study and that standardized functional or cosmetic outcomes were not collected, although we hope to do so prospectively in the future. It is also important to note that an anterior incision is not eliminated with this technique, because an anterior incision, albeit smaller, is still used to drill the tibial tunnel and place fixation.

CONCLUSION

Choices of graft and harvesting technique are surgeon-dependent decisions based on patient selection, comfort,

and outcomes. Although we have demonstrated that posterior hamstring harvest is safe and efficacious in this surgeon's pediatric and adolescent population, other surgeons should use the technique of their choice. For many surgeons who use an anterior approach and are quite facile with it, the posterior harvesting technique can be used when a challenging anterior harvest is encountered.

REFERENCES

1. Bansal A, Lamplot JD, Vandenberg J, et al. Meta-analysis of the risk of infections after anterior cruciate ligament reconstruction by graft type. *Am J Sports Med.* 2018;46(6):1500-1508.
2. Burrus MT, Werner BC, Crow AJ, et al. Increased failure rates after anterior cruciate ligament reconstruction with soft-tissue autograft-allograft hybrid grafts. *Arthroscopy.* 2015;31:2342-2351.
3. Candal-Couto JJ, Deehan DJ. The accessory bands of gracilis and semitendinosus: an anatomical study. *Knee.* 2003;10:325-328.
4. Dodwell ER, Lamont LE, Green DW, et al. 20 years of pediatric anterior cruciate ligament reconstruction in New York State. *Am J Sports Med.* 2014;42:675-680.
5. Ejherhed L, Kartus J, Sernet N, et al. Patellar tendon or semitendinosus tendon autografts for anterior cruciate ligament reconstruction? A prospective randomized study with a two-year follow-up. *Am J Sports Med.* 2003;31:19-25.
6. Freedman KB, D'Amato MJ, Nedeff DD, et al. Arthroscopic anterior cruciate ligament reconstruction: a metaanalysis comparing patellar tendon and hamstring tendon autografts. *Am J Sports Med.* 2003;31:2-11.
7. Gausden EB, Calcei JG, Fabricant PD, et al. Surgical options for anterior cruciate ligament reconstruction in the young child. *Curr Opin Pediatr.* 2015;27:82-91.
8. Kaeding CC, Aros B, Pedroza A, et al. Allograft versus autograft anterior cruciate ligament reconstruction: predictors of failure from a MOON prospective longitudinal cohort. *Sports Health.* 2011;3:73-81.
9. Kaeding CC, Pedroza AD, Reinke EK, et al. Risk factors and predictors of subsequent ACL injury in either knee after ACL reconstruction: prospective analysis of 2488 primary ACL reconstructions from the MOON cohort. *Am J Sports Med.* 2015;43:1583-1590.
10. Kocher MS, Saxon HS, Hovis WD, et al. Management and complications of anterior cruciate ligament injuries in skeletally immature patients: survey of the Herodicus Society and the ACL Study Group. *J Pediatr Orthop.* 2002;22:452-457.
11. Letarte R, Isida R, Pommepuy T, et al. Horizontal posterior hamstring harvest. *Orthop Traumatol Surg Res.* 2014;100:959-961.
12. McGuire DA, Hendricks SD. Anterior cruciate ligament reconstruction graft harvesting: pitfalls and tips. *Sports Med Arthrosc.* 2007;15:184-190.
13. Pagnani MJ, Warner JJ, O'Brien SJ, et al. Anatomic considerations in harvesting the semitendinosus and gracilis tendons and a technique of harvest. *Am J Sports Med.* 1993;21:565-571.
14. Prodromos CC. Posterior mini-incision hamstring harvest. *Sports Med Arthrosc.* 2010;18:12-14.
15. Prodromos CC, Han YS, Beller BL, et al. Posterior mini-incision technique for hamstring anterior cruciate ligament reconstruction graft harvest. *Arthroscopy.* 2005;21:130-137.
16. Reina N, Abbo O, Gomez-Bouchet A, et al. Anatomy of the bands of the hamstring tendon: how can we improve harvest quality? *Knee.* 2013;20:90-95.
17. Roussignol X, Bertiaux S, Rahali S, et al. Minimally invasive posterior approach in the popliteal fossa for semitendinosus and gracilis tendon harvesting: an anatomic study. *Orthop Traumatol Surg Res.* 2015;101:167-172.

18. Shelton WR, Fagan BC. Autografts commonly used in anterior cruciate ligament reconstruction. *J Am Acad Orthop Surg*. 2011;19:259-264.
19. Solman CG, Pagnani MJ. Hamstring tendon harvesting: reviewing anatomic relationships and avoiding pitfalls. *Orthop Clin North Am*. 2003;34:1-8.
20. Spicer DD, Blagg SE, Unwin AJ, et al. Anterior knee symptoms after four-strand hamstring tendon anterior cruciate ligament reconstruction. *Knee Surg Sports Traumatol Arthrosc*. 2000;8:286-289.
21. Tillett E, Madsen R, Rogers R, et al. Localization of the semitendinosus-gracilis tendon bifurcation point relative to the tibial tuberosity: an aid to hamstring tendon harvest. *Arthroscopy*. 2004;20:51-54.
22. Warren LF, Marshall JL. The supporting structures and layers on the medial side of the knee: an anatomical analysis. *J Bone Joint Surg Am*. 1979;61:56-62.
23. Wilson TJ, Lubowitz JH. Minimally invasive posterior hamstring harvest. *Arthrosc Tech*. 2013;2(3):e299-e301.