

UC Davis

Dermatology Online Journal

Title

Annular elastolytic giant cell granuloma: a “visible” diagnosis

Permalink

<https://escholarship.org/uc/item/9rq3j927>

Journal

Dermatology Online Journal, 23(7)

Authors

Raposo, Inês
Mota, Fernando
Lobo, Inês
et al.

Publication Date

2017

DOI

10.5070/D3237035755

Copyright Information

Copyright 2017 by the author(s). This work is made available under the terms of a Creative Commons Attribution-NonCommercial-NoDerivatives License, available at <https://creativecommons.org/licenses/by-nc-nd/4.0/>

Peer reviewed

Annular elastolytic giant cell granuloma: a “visible” diagnosis

Inês Raposo¹, Fernando Mota¹, Inês Lobo¹, José Ricardo Brandão², Manuela Selores^{1,3,4}

Affiliations: ¹Department of Dermatology, Centro Hospitalar do Porto, Portugal ²Department of Pathology, Centro Hospitalar do Porto, Portugal ³Instituto de Ciências Biomédicas Abel Salazar, University of Porto, Portugal ⁴Dermatology Research Unit, Centro Hospitalar do Porto, Portugal

Corresponding Author: Inês Raposo, Serviço de Dermatologia, Centro Hospitalar do Porto, Edifício das Consultas Externas, Ex-CICAP, Rua D. Manuel II, s/n, 4100 Porto, Portugal, E-mail: inesraposovs@gmail.com

Abstract

Annular elastolytic giant cell granuloma (AEGCG) is a rare granulomatous skin disease of undetermined cause, characterized by annular plaques with raised erythematous borders in sun-exposed skin. The typical histologic features are dermal infiltration by multinucleated giant cells, elastin degeneration, and elastophagocytosis. The authors describe a clinical case of AEGCG, which exhibited an excellent response to hydroxychloroquine.

Keywords: actinic granuloma; annular elastolytic giant cell granuloma

Introduction

Annular elastolytic giant cell granuloma (AEGCG) was first described by O'Brien in 1975 and represents a rare granulomatous skin disease of undetermined

cause [1]. Clinically it is characterized by annular plaques with raised erythematous borders, affecting predominantly sun-exposed skin (face, neck, upper extremities, anterior chest wall), [2]. Annular elastolytic giant cell granuloma usually presents in adults (age 40-70) and has a slight male predominance [3]. Histopathology shows infiltration of the upper and mid dermis by multinucleated giant cells, elastin degeneration, and elastophagocytosis [3].

Case Synopsis

A 38-year-old male, type II phototype, was observed in our dermatology department owing to a cutaneous frontal plaque, which displayed slow centrifugal growth for more than 1 year. He had previously been treated with topical and systemic antifungal agents, without improvement.

Dermatologic examination revealed an arciform erythematous plaque with sharply demarcated

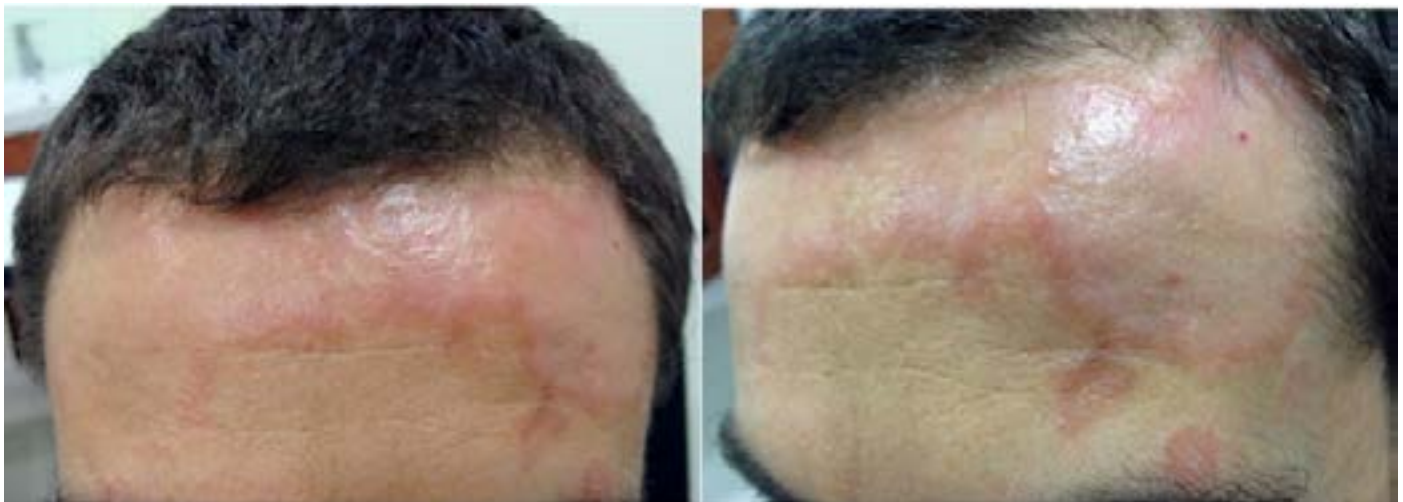

Figure 1. Clinical aspect of the lesions - frontal arciform erythematous plaque, with central atrophy.

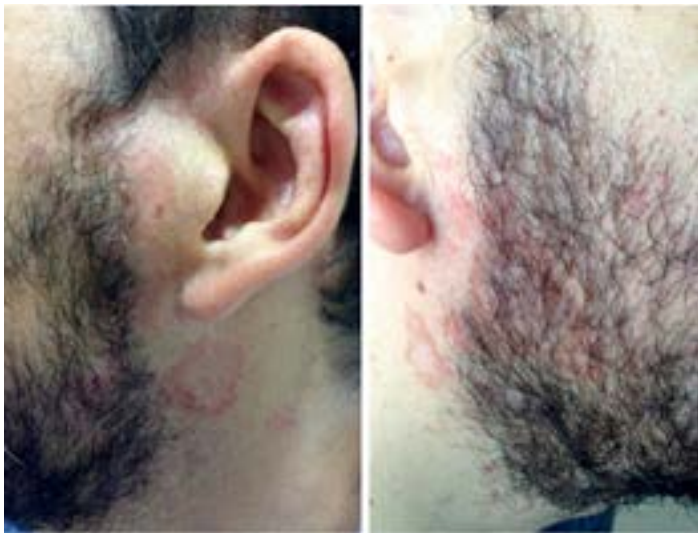

Figure 2. Clinical aspect of the lesions: lateral cervical annular erythematous plaques.

elevated borders, measuring 16cm x 5cm and occupying the upper half of the frontal region (**Figure 1**). The center of the lesion exhibited clearing with slightly atrophic skin. The lesions were non-scaling and symptoms such as itching, tenderness, or pain were absent.

Annular erythematous plaques with the same characteristics were also present on the lateral cervical regions (two plaques on the right side, two on the left), the largest measuring 4cm (**Figure 2**). The latter lesions had appeared 2 months before observation.

The patient was a computer programmer and had no history of chronic sun exposure. There was no record of medical history, chronic disease, or medication.

All blood parameters were within normal values (hematological study, liver and renal function, lipid profile, glucose, serum angiotensin-converting enzyme levels, antinuclear antibody).

Histopathology demonstrated a granulomatous infiltrate in the superficial dermis, consisting of giant multinucleated cells (**Figure 3a**). Verhoeff van Gieson stain verified the degeneration of elastin fibers and elastophagocytosis (**Figure 3b**). No mucin deposition or altered collagen fibers were observed. A diagnosis of AEGCG was established and the patient was placed on sun protective measures and hydroxychloroquine 400mg a day after ophthalmologic examination. No new lesions developed after initiation of treatment and a marked clearing of clinical lesions was observed after 3 months of therapy. Complete clearing of the lesions was observed after 6 months of treatment (**Figure 4**). Hydroxychloroquine was suspended and continuous sun protective measures recommended.

Case Discussion

Although the etiopathogenesis of AEGCG is still unclear, actinic damage is regarded as a trigger. O'Brien originally named this clinical entity "actinic granuloma" given what was thought to be the environmental origin of the cutaneous disease. According to this theory, elastic tissue damaged by actinic radiation acts as an antigenic trigger of an autoimmune reaction [1]. Although clinical lesions of AEGCG may present in other body areas, sun exposed skin is mainly affected. Supporting this theory is the fact that this disease is more frequently observed in lighter skin and in countries with higher UV index [4].

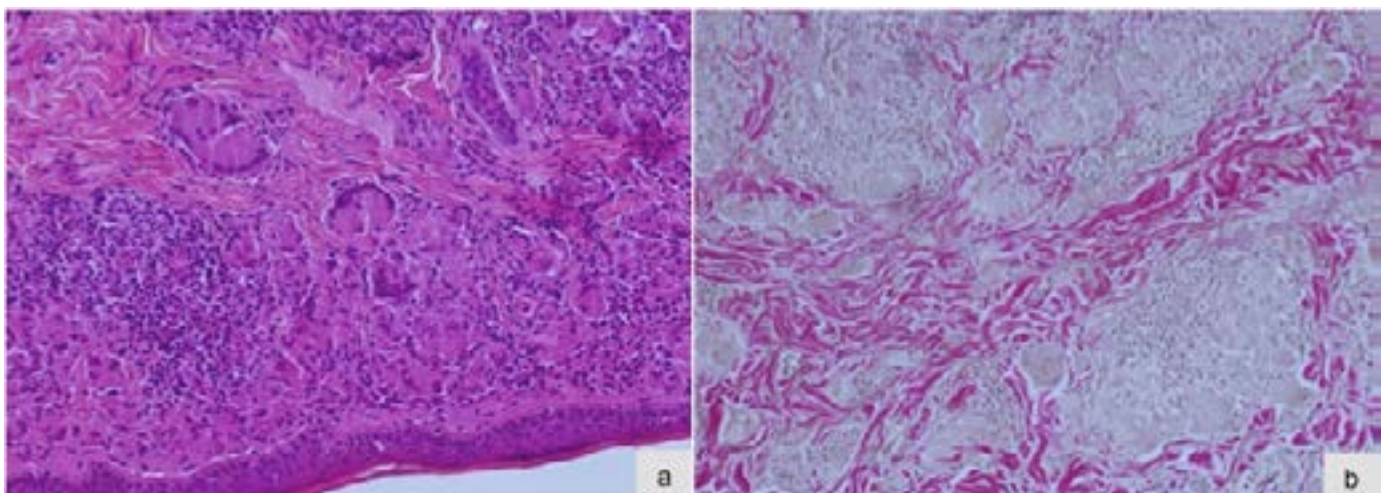


Figure 3. A) Upper dermis granulomatous infiltrates (H&E, 10x). B) Elastophagocytosis and degeneration of elastin fibers (Verhoeff van Gieson, 10x).

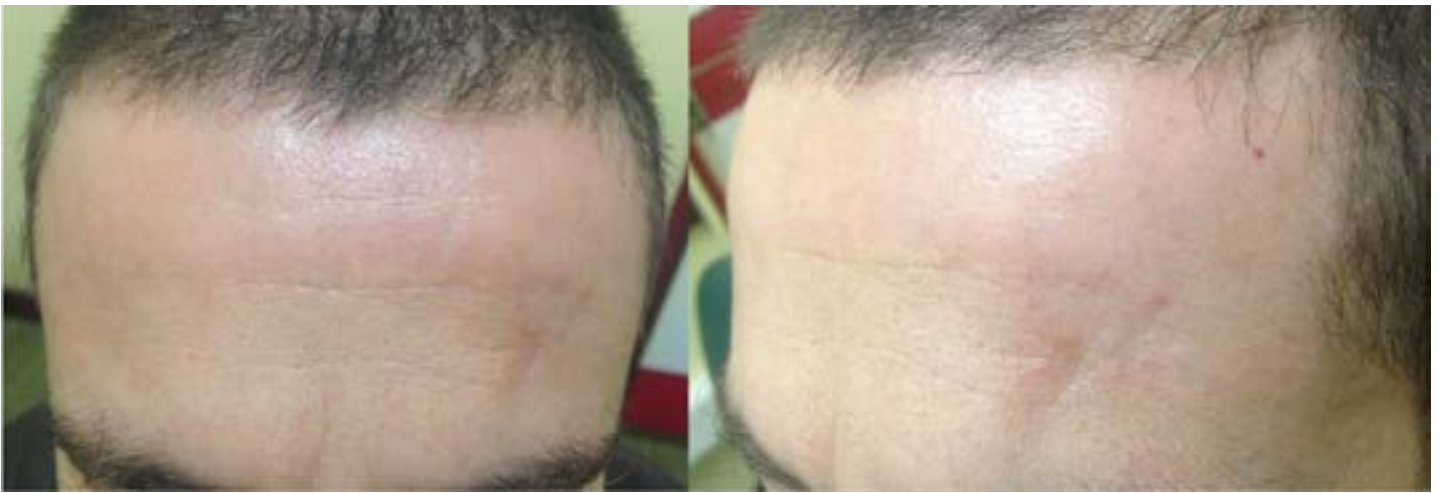

Figure 4. Clinical aspect after treatment.

Although our patient had a low phototype (type II) and resided in a sunny country, which can be regarded as two risk factors in the pathogenesis of the disease, no history of chronic outdoor activities was present. The authors question whether the chronic exposure to computer screens could have played some role in the etiology of our patient's disease [5].

Conclusion

AEGCG has a slow, self-limited course, persisting many years before resolving [6]. Given the fact that lesions are often multiple and affect visible areas with consequent important cosmetic significance, therapy is of utmost importance in order to prevent the appearance of new lesions and the growth of established ones [6].

Treatment options are based on a small number of case reports, with different efficacy outcomes. Topical, intralesional, and systemic corticosteroids, hydroxychloroquine, cyclosporine, topical pimecrolimus, and sun protective measures are the most frequent therapeutic modalities used [6-9].

We report a clinical case of AEGCG with exuberant clinical presentation, which exhibited excellent response to hydroxychloroquine.

References

1. O'Brien JP. Actinic granuloma. An annular connective tissue disorder affecting sun- and heat-damaged (elastotic) skin. *Arch Dermatol.* 1975;111(4):460-6. Epub 1975/04/01. [PMID: 1122146].
2. Arora S, Malik A, Patil C, Balki A. Annular elastolytic giant cell granuloma: A report of 10 cases. *Indian Dermatol Online J.* 2015;6(Suppl 1):S17-20. Epub 2016/02/24. [PMID: 26904442].
3. Gutierrez-Gonzalez E, Gomez-Bernal S, Alvarez-Perez A, Sanchez-Aguilar D, Toribio J. Elastolytic giant cell granuloma: clinic-pathologic review of twenty cases. *Dermatol Online J.* 2013;19(10):20019. Epub 2013/10/22. [PMID: 24139362].
4. Thacker PM, Nayak K, Lobo FD, Govindasamy P. O'Brien's Granuloma- A Case Report. *J Clin Diag Res.* 2016;10(10):Wd05-wd6. Epub 2016/11/29. [PMID: 27891439].
5. Sayre RM, Dowdy JC, Poh-Fitzpatrick M. Dermatological risk of indoor ultraviolet exposure from contemporary lighting sources. *Photochem Photobiol.* 2004;80:47-51. Epub 2004/09/02. [PMID: 15339209].
6. Coutinho ID, Ramos LI, Brites MM, Tellechea O. O'Brien Actinic Granuloma: A Case Report and Brief Review of Literature. *Indian J Dermatol.* 2015;60(4):391-3. Epub 2015/08/20. [PMID: 26288411].
7. Can B, Kavala M, Turkoglu Z, Zindanci I, Topaloglu F, Zemheri E. Successful treatment of annular elastolytic giant cell granuloma with hydroxychloroquine. *Intl J Dermatol.* 2013;52(4):509-11. Epub 2012/04/20. [PMID: 22512720].
8. Ventura F, Vilarinho C, da Luz Duarte M, Pardal F, Brito C. Two cases of annular elastolytic giant cell granuloma: Different response to the treatment. *Dermatol Online J.* 2010;16(3):11. Epub 2010/03/18. [PMID: 20233568].
9. Errichetti E, Stinco G, Avellini C, Patrone P. Annular elastolytic giant cell granuloma treated with topical pimecrolimus. *Indian J Dermatol Venereol Leprol.* 2014;80(5):475-6. Epub 2014/09/10. [PMID: 25201861].