

# UCSF

## UC San Francisco Previously Published Works

### Title

The tumour immune microenvironment and microbiome of pancreatic intraductal papillary mucinous neoplasms

### Permalink

<https://escholarship.org/uc/item/9r02z2xw>

### Journal

The Lancet Gastroenterology & Hepatology, 7(12)

### ISSN

2468-1156

### Authors

Pollini, Tommaso  
Adsay, Volcan  
Capurso, Gabriele  
[et al.](#)

### Publication Date

2022-12-01

### DOI

10.1016/s2468-1253(22)00235-7

Peer reviewed



# HHS Public Access

Author manuscript

*Lancet Gastroenterol Hepatol*. Author manuscript; available in PMC 2023 June 01.

Published in final edited form as:

*Lancet Gastroenterol Hepatol*. 2022 December ; 7(12): 1141–1150. doi:10.1016/S2468-1253(22)00235-7.

## The tumour immune microenvironment and microbiome of pancreatic intraductal papillary mucinous neoplasms

**Tommaso Pollini, MD,**

Division of Surgical Oncology, Department of Surgery, University of California San Francisco, San Francisco, CA, USA

Department of General and Pancreatic Surgery, The Pancreas Institute, Section of Pathology University of Verona, Verona, Italy

**Volcan Adsay, MD,**

Department of Pathology, Koç University Hospital and Koç University Research Center for Translational Medicine, Istanbul, Turkey

**Gabriele Capurso, MD PhD,**

Department of Pancreatobiliary Endoscopy and Endosonography, Pancreas Translational and Clinical Research Center, IRCCS San Raffaele, Milan, Italy

**Marco Dal Molin, MD,**

Department of Surgery, University of Maryland Medical Center, Baltimore, MD, USA

**Irene Esposito, MD PhD,**

Department of Pathology, Heinrich Heine University and University Hospital of Düsseldorf, Düsseldorf, Germany

**Ralph Hruban, MD,**

Department of Pathology, the Sol Goldman Pancreatic Cancer Research Center, Johns Hopkins University School of Medicine, Baltimore, MA, USA

**Claudio Luchini, MD PhD,**

Department of Diagnostics and Public Health, Section of Pathology University of Verona, Verona, Italy

**Laura Maggino, MD PhD,**

Department of General and Pancreatic Surgery, The Pancreas Institute, Section of Pathology University of Verona, Verona, Italy

---

Correspondence to: Prof Ajay V Maker, Division of Surgical Oncology, Department of Surgery, University of California San Francisco, San Francisco, CA 94143, USA [ajay.maker@ucsf.edu](mailto:ajay.maker@ucsf.edu).

Contributors

AVM conceptualised the Review. The literature search was performed by TP and AVM. The original draft was written by TP and AVM. All authors contributed to revision and critical discussion of the manuscript.

Declaration of interests

The Department of General and Pancreatic Surgery at the University of Verona received funding from the Italian Ministry of Health (Grant FIMP-CUP J38D19000690001). GP reports funding from Associazione Italiana Ricerca sul Cancro (IG 2021-26201). RH is under a license agreement between Thrive Earlier Detection, a subsidiary of Exact Sciences, and the Johns Hopkins University. AVM's research in tumour immunology is funded through the National Institutes of Health Method To Extend Research in Time award (R37CA238435), and AVM is an inventor who has the following pending or issued patents: WO2018183603A1 (PCT/US2018/025027) and US9757457B2.

**Hanno Matthaei, MD,**

Department of Surgery, University Hospital of Bonn, Bonn, Germany

**Giovanni Marchegiani, MD PhD,**

Department of General and Pancreatic Surgery, The Pancreas Institute, Section of Pathology  
University of Verona, Verona, Italy

**Aldo Scarpa, MD,**

Department of Diagnostics and Public Health, Section of Pathology University of Verona, Verona,  
Italy

**Laura D Wood, MD PhD,**

Department of Pathology, the Sol Goldman Pancreatic Cancer Research Center, Johns Hopkins  
University School of Medicine, Baltimore, MA, USA

**Claudio Bassi, MD,**

Department of General and Pancreatic Surgery, The Pancreas Institute, Section of Pathology  
University of Verona, Verona, Italy

**Roberto Salvia, MD PhD,**

Department of General and Pancreatic Surgery, The Pancreas Institute, Section of Pathology  
University of Verona, Verona, Italy

**Mari Mino-Kenudson, MD,**

Department of Pathology, Massachusetts General Hospital and Harvard Medical School, Boston,  
MA, USA

**Ajay V Maker, MD FACS**

Division of Surgical Oncology, Department of Surgery, University of California San Francisco, San  
Francisco, CA, USA

**Abstract**

Pancreatic intraductal papillary mucinous neoplasms (IPMNs) have gained substantial attention because they represent one of the only radiographically identifiable precursors of invasive pancreatic ductal adenocarcinoma. Although most of these neoplasms have low-grade dysplasia and will remain indolent, a subset of IPMNs will progress to invasive cancer. The role of the immune system in the progression of IPMNs is unclear, but understanding its role could reveal the mechanism of neoplastic progression and targets for immunotherapy to inhibit progression or treat invasive disease. The available evidence supports a shift in the immune composition of IPMNs during neoplastic progression. Although low-grade lesions contain a high proportion of effector T cells, high-grade IPMNs, and IPMNs with an associated invasive carcinoma lose the T-cell infiltrate and are characterised by a predominance of immunosuppressive elements. Several possible therapeutic strategies emerge from this analysis that are unique to IPMNs and its microbiome.

## Introduction

Pancreatic intraductal papillary mucinous neoplasms (IPMNs) are the most common pancreatic cystic neoplasm.<sup>1</sup> The recognised prevalence of these neoplasms in the general population has increased secondary to the widespread use of high-quality cross-sectional abdominal imaging.<sup>2</sup> Together with pancreatic intraepithelial neoplasms (PanINs), mucinous cystic neoplasms, and rare relations of IPMNs such as intraductal tubulopapillary neoplasms,<sup>3</sup> IPMNs are the only known precursors of invasive pancreatic ductal adenocarcinoma.<sup>4,5</sup> However, unlike PanINs, IPMNs are radiographically identifiable, which means they are an ideal target for early diagnosis and intervention.<sup>6</sup> Because most IPMNs are at low risk of malignant transformation and can be safely surveilled, identifying the subset of lesions at high risk of malignant transformation remains one of the challenges of this field.<sup>7,8</sup>

The progression of IPMNs from low-grade to high-grade dysplasia is associated with a measurable inflammatory response. With progressive amounts of dysplasia, the tumour microenvironment shows an increase in the concentration of prostaglandins and cyst fluid cytokines, which is indicative of a Th1 and Th2 immunological response.<sup>9,10</sup> Thus, it could be hypothesised that evaluation and characterisation of the immune response to IPMNs could allow for early diagnosis, and potentially enhance treatments to halt progression or treat invasive disease. Pancreatic ductal adenocarcinomas are traditionally considered cold tumours (ie, they do not provoke a strong immunological response) that are microsatellite stable, checkpoint blockade resistant, contain a paucity of actionable mutations or tumour-associated antigens, and have a low mutational burden.<sup>11</sup> Even less is known about the immunogenicity of IPMNs. Regardless, patients with invasive IPMNs are treated with the same clinical paradigms and agents as patients with pancreatic ductal adenocarcinomas. Therefore, an understanding of the immune response to neoplastic progression in IPMNs is crucial and remains to be fully elucidated.

PanINs are characterised by an immunosuppressive environment including myeloid-derived suppressor cells (MDSCs), regulatory T cells, tumour-associated macrophages (TAMs), and  $\gamma$ -T cells. MDSCs represent 1-9% of CD45<sup>+</sup> cells in pancreatic intraepithelial neoplasm lesions, a result that is similar to what is reported for non-invasive IPMNs.<sup>12</sup> In particular, regulatory T cells promote tumour growth with an associated absence of cytotoxic CD8<sup>+</sup> T cell activation via direct interaction with CD11c<sup>+</sup> dendritic cells.<sup>13</sup> Furthermore, regulatory T cells are found in similar numbers in IPMNs and PanINs. Different to PanINs, IPMNs have a unique subclass of type 2 dendritic myeloid cells that are present in both low-grade dysplastic IPMNs and high-grade dysplastic IPMNs. Perhaps the largest difference in the tumour immune microenvironment between IPMNs and PanINs are in the populations of cytotoxic CD8<sup>+</sup> T cells, activated CD4<sup>+</sup> T cells, and fibroblasts. Whereas pancreatic ductal adenocarcinomas preceded by PanINs show a loss of CD8<sup>+</sup> T cells at early stages, IPMNs have a high proportion of cytotoxic CD8<sup>+</sup> T cells in low grade lesions compared with more advanced lesions. IPMNs with low-grade dysplasia also have activated CD4<sup>+</sup> T cells that persist through increasing amounts of dysplasia, although differences in the spatial distribution of these cells becomes more evident as the condition progresses. Furthermore, PanINs are characterised by restraining cancer-associated fibroblasts instead of the cancer-

promoting cancer-associated fibroblasts (cancer-associated myofibroblasts in particular) that characterise IPMNs.<sup>14</sup>

During the progression from IPMNs with low-grade dysplasia, to IPMNs with high-grade dysplasia, and then to invasive carcinoma, a shift towards immune tolerance in the tumour microenvironment is evident (figure 1). Whether this immunological change results in an escape of tumour recognition or an enhancement of an immunosuppressive tumour microenvironment<sup>15</sup> remains to be determined. However, there is a need to better characterise the tumour immune microenvironment of IPMNs for diagnostic and therapeutic implications. In this Review, we discuss the changes to the tumour immune microenvironment and microbiome of IPMNs that could contribute to the neoplastic progression of IPMNs.

## The pro-inflammatory tumour immune microenvironment of IPMNs

### Polyclonality and signalling pathways

Few transcriptomic studies have been done on IPMNs. Bernard and colleagues<sup>16</sup> reported the results of single-cell RNA sequencing of a small number of IPMNs with low-grade dysplasia, IPMNs with high-grade dysplasia, and IPMNs with invasive carcinoma. At the single-cell transcript level, there appeared to be an overlap of phenotypes between IPMNs with different amounts of dysplasia. Lesions with histological low-grade dysplasia revealed gene clusters with different proliferative states. Lesions with histological low-grade dysplasia also had clusters of cells with the same gene expression profile as lesions with high-grade dysplasia or invasive cancer, suggesting the presence of tumour heterogeneity even in low-grade dysplastic tumours. This finding supports other studies that show a polyclonal origin of IPMNs and suggest that there are multiple pathways to invasive disease.<sup>17</sup> Nonetheless, the study by Bernard and colleagues<sup>16</sup> did crucially reveal distinct patterns of T-cell responses that were linked to the grade of dysplasia. A pro-inflammatory immune signature was clearly apparent in IPMNs with low-grade dysplasia, which was composed of cytotoxic T cells, activated T-helper cells, and dendritic cells. This finding is consistent with analyses revealing increased proinflammatory markers IL-1 $\beta$ , IL-5, and IL-8 in the cyst fluid of dysplastic IPMNs.<sup>9</sup> However, instead of increasing, the populations of T cells decreased in a stepwise manner during progressive dysplasia, suggesting a decrease in the immune response or a tumour escape mechanism during tumour progression.

The pro-inflammatory environment of IPMNs with low-grade dysplasia included clustered expression of tumour suppressor genes that also decreased with disease progression, including a progressive loss of tumour suppressor gene *RAP1GAP* expression.<sup>16</sup> *RAP1GAP* suppresses invasion and metastases, and the expression of *RAP1GAP* was increased in neoplasms with low-grade dysplasia but downregulated in neoplasms with high-grade dysplasia. The downregulation of *RAP1GAP* correlated with enrichment of G2/M phase and S phase tumour cells in more advanced disease, and G1/S phase regulation specifically in IPMNs with high-grade dysplasia. Furthermore, cell pathway analysis demonstrated upregulated signalling of integrins, small GTPases, Wnt- $\beta$ -catenin, axonal guidance, and apoptosis genes in IPMNs with high-grade dysplasia. IPMNs with an associated invasive carcinoma contained additional enrichment of genes involved with the DNA

damage response, TGF- $\beta$ 1 signalling, and SAPK and JNK signalling. Taken together, single-cell RNA sequencing analyses support that progressive dysplasia is associated with specific patterns of inflammation, decreased T-cell trafficking, cell-cycle disinhibition, apoptosis, oncogene expression, decreased tumour suppressor gene expression, and enhanced proliferative signalling pathways. Each of these characteristics could be targets for intervention to halt the progression of IPMNs or to treat invasion.

### **Tumour-infiltrating lymphocytes and tumour architecture**

The signalling events associated with dysplasia are also reflected in the changing immunocyte population during progression to invasive cancer. Total CD45<sup>+</sup> leukocytes and CD3<sup>+</sup> T cells were increased in IPMNs of all grades compared with adjacent normal pancreatic parenchyma.<sup>15</sup> A higher proportion of cytotoxic CD8<sup>+</sup> T cells and CD4<sup>+</sup> T cells were observed in IPMNs with low-grade dysplasia than in IPMNs with high-grade dysplasia or neoplasms with an associated invasive carcinoma.<sup>16,18</sup> The tumour immune microenvironment of low-grade dysplasia areas in IPMNs that progressed to high-grade dysplasia resembled the tumour immune microenvironment of neoplasms with only high-grade dysplasia, underscoring the fact that an attenuated immune surveillance occurs at an early stage of progression.<sup>18</sup> In fact, apart from regulatory T-cells, all T-cell subset densities decreased from IPMNs with low-grade dysplasia to neoplasms with invasive cancer. A principal component analysis of only the number of tumour-infiltrating T-cells and macrophages revealed distinctive clustering that differentiated non-invasive IPMNs from those associated with invasive carcinoma. This distinctive clustering could be reflective of progression enabled by immune escape and highlights that the tumour immune microenvironment changes with the degree of dysplasia and is unique to the progression of IPMNs.

As is the case for other neoplasms, the location, type, and density of immunocytes in the tumour microenvironment are crucial to understanding the immune response that occurs in IPMNs. Roth and colleagues<sup>19</sup> assessed the spatial distribution of immune cell populations during progression from IPMNs with low-grade dysplasia to those associated with invasive carcinoma. Utilising immunohistochemistry, T cells were mapped to the juxtatumoral stroma (approximately 150  $\mu$ m surrounding the neoplastic epithelium), peritumoral stroma (surrounding the juxtatumoral stroma), tertiary lymphoid structures, and normal adjacent pancreatic tissue. In low-grade lesions, the most abundant T cells were CD3<sup>+</sup>, Th1, and Th2 cells. The CD4<sup>+</sup> T cells, namely Th1, Th2, Th7, and Th22 helper T cells, infiltrated low-grade lesions, but then decreased during progression of the lesion, particularly in the juxtatumoral stroma. Similarly, in non-invasive IPMNs there was a significantly higher proportion of CD8<sup>+</sup> T cells in the juxtatumoral space than in neoplasms associated with invasive disease, whereas the number of CD8<sup>+</sup> cells in the peritumoral stroma did not change. Moreover, all the investigated subtypes of T cells except regulatory T cells, Th9 cells, and Th22 cells decreased as IPMNs progressed from low-grade to invasive pancreatic cancer.

Tertiary lymphoid structures were identified in IPMNs but not in normal pancreatic tissue. Within these tertiary lymphoid structures, similar to within the tumours themselves, T cells

dominated and Th2 helper T cells were replaced in prominence by regulatory T cells during progression to invasive disease.

Furthermore, transcriptome analysis was performed specifically on the tumour stroma, identifying seven unique stromal clusters associated with the amount of dysplasia, including cancer-associated myofibroblasts and inflammatory cancer-associated fibroblasts.<sup>16</sup> The cancer-associated myofibroblasts were more common in IPMNs with low-grade dysplasia and high-grade dysplasia than in IPMNs associated with invasive carcinoma, and were identified by a relatively decreased expression of *CXCL12*, *ACTA2*, and *COL3A1* compared with IPMNs associated with invasive carcinoma. Inflammatory cancer-associated fibroblasts were only present in pancreatic ductal adenocarcinomas and were identified by increased expression of *FAP*, *ACTA2*, *COL3A1*, and *CXCL12*. Different to IPMNs, the microenvironment of PanINs is characterised by cancer-restraining cancer-associated fibroblasts. These cells express high concentrations of meflin that binds to BMP-7 and counteracts TGF- $\beta$ -induced fibrosis.<sup>14</sup>

Taken together, immunophenotyping of the tumour microenvironment of IPMNs has helped identify differences based on the degree of dysplasia. These data support that IPMNs drive tumour-infiltrating lymphocytes, and that although the total number of T cells in the tumour microenvironment does not change considerably during neoplastic progression, the phenotype, localisation, and prevalence of T-cell subtypes changes substantially during progression to invasive carcinoma. IPMNs with high-grade dysplasia and those with invasive carcinoma appear to be associated with decreased CD8<sup>+</sup> T-cell infiltration into the juxtatumoral space and increased infiltration of accompanying regulatory T cells compared with neoplasms with low-grade dysplasia, which possibly reflects immune escape. Tertiary lymphoid structures appear only in invasive disease. In invasive disease, the stroma also changes in character, revealing expression of inflammatory fibroblasts that were not present in non-invasive IPMNs. This observation is consistent with findings of increased inflammatory cancer-associated fibroblasts in traditional pancreatic cancer. It appears that non-invasive IPMNs are associated with a considerable T-cell driven immune response that is decreased and replaced by an inflammatory stroma when the lesions progress into invasive carcinomas.

## The immunosuppressive tumour microenvironment of IPMNs

Although there are a small minority of pancreatic ductal adenocarcinomas that are microsatellite unstable or that attract a non-exhausted immune infiltrate,<sup>20,21</sup> it is accepted that the majority of pancreatic ductal adenocarcinomas are generally non-immunogenic. The tumours are characterised by a predominance of immunosuppressive cells, including regulatory T cells and MDSCs, and a low effector T-cell infiltrate.<sup>22,23</sup> Similar findings have been observed in IPMNs, but with some important differences that give clues to the unique pattern of invasion.

Regulatory T cells are a subset of CD4<sup>+</sup> T cells that modulate the immune system by maintaining self-tolerance and preventing autoimmune disease.<sup>24</sup> Initially characterised by a high expression of CD25, regulatory T cells were subsequently defined by the expression

of FOXP3, which regulates the conversion of naive CD4<sup>+</sup> CD25<sup>-</sup> T cells into CD4<sup>+</sup> CD25<sup>+</sup> regulatory T cells with inhibitory function.<sup>25</sup> The presence of these regulatory T cells in several cancer types has been associated with immunosuppressive activity that inhibits the anti-tumour immune response.<sup>26</sup> Nonetheless, the precise role that regulatory T cells play in the tumour microenvironment, including in IPMNs, remains unclear. In pancreatic ductal adenocarcinoma, increased regulatory T-cell densities correlate with the presence of distant metastasis, advanced tumour stage, and high tumour grade.<sup>27</sup> However, the inhibition of regulatory T cells has not resulted in tumour regression in animal models. In a pancreatic intraepithelial neoplasia mouse model, Zhang and colleagues<sup>28</sup> showed that the depletion of regulatory T cells actually caused an acceleration to progression to invasive cancer. This paradoxical phenomenon might be explained by the fact that the inhibition of regulatory T cells was associated with the loss of tumour-restraining fibroblasts and an increase in pro-tumour chemokines including CCL3, CCL6, and CCL8.

Although effort has gone into studying the immunosuppressive environment involved in the progression of PanINs, there has been a comparative paucity of research on the progression of IPMNs. Early studies of resected IPMNs revealed that, similar to pancreatic ductal adenocarcinoma, the concentration of CD4<sup>+</sup>CD25<sup>+</sup>FOXP3<sup>+</sup> regulatory T cells were associated with progression of IPMNs, with a significant increase of these cells when invasive IPMNs develop.<sup>27,29</sup> These findings were confirmed in a larger study of resected IPMNs from 58 patients,<sup>19</sup> where FOXP3<sup>+</sup> regulatory T cells increased as IPMNs progressed to invasive disease. Furthermore, FOXP3<sup>+</sup> regulatory T cells constituted a proportionally larger component of the T-cell repertoire in invasive tumours than in non-invasive tumours. The regulatory T cells were found to be the predominant T-cell subset in the juxtatumoural area of intraductal papillary mucinous neoplasm-associated invasive lesions. An additional retrospective study done on human samples confirmed these results, showing no increase in the density of FOXP3<sup>+</sup> regulatory T cells between IPMNs with low-grade dysplasia and those with high-grade dysplasia.<sup>18</sup> This result might imply that the immune suppression mediated by regulatory T cells is involved specifically in the transition between high-grade dysplasia and invasive cancer.

One of the possible factors related to the increased presence of regulatory T cells in progressive intraductal papillary mucinous neoplasm is IDO1, an enzyme that is correlated with the number of regulatory T cells in the peripheral blood of patients with IPMNs with associated invasive carcinoma.<sup>30</sup> IDO1 expression in the tumour also correlates with the prevalence of regulatory T cells, and appears to be one of the late-stage phenomena of intraductal papillary mucinous neoplasm carcinogenesis.<sup>29</sup> IDO1 is an enzyme involved in tryptophan metabolism. Tryptophan metabolism has been associated with the development of tumour tolerance and activates and supports regulatory T-cell function. Both the reduction in the tryptophan concentration and the immunosuppressive effect of tryptophan metabolites contribute to the effects of IDO1. In IPMNs, IDO1 is thought to be secreted by dendritic cells, possibly through the activation of the Notch signalling pathway through Jagged1 interaction,<sup>31</sup> leading to possible targets for therapeutic intraductal papillary mucinous neoplasm intervention.<sup>32,33</sup>



In addition to regulatory T cells, myeloid-derived suppressor cells are immunosuppressive cells that could have a role in the progression of IPMNs. Myeloid-derived suppressor cells belong to a heterogeneous group of immature myeloid cells that are undergoing evolving characterisation. These cells appear to consist of both granulocytic and monocytic phenotypes. Myeloid-derived suppressor cells promote carcinogenesis in several ways: by permitting immune evasion through induction of natural killer and T-cell anergy; by remodelling the tumour microenvironment to promote tumour growth; by creating and establishing a metastatic niche for cancer dissemination; by inducing epithelial to mesenchymal transition and mesenchymal to epithelial transition; by promoting angiogenesis; and by improving tumour cell survival through immunosuppressive activities.<sup>34</sup> In particular, myeloid-derived suppressor cells are able to suppress the anti-tumour immune response directly, through PD1 expression,<sup>35</sup> and indirectly, through the release of reactive oxygen species.<sup>36</sup> Furthermore, myeloid-derived suppressor cells can differentiate into M2 macrophages, which contribute to immunosuppression through the release of chemokines that include IL-10 and TGF- $\beta$ .<sup>37</sup> In IPMNs, myeloid-derived suppressor cells are present in lesions with high-grade dysplasia with increasing density. In contrast, in lesions with low-grade dysplasia, myeloid-derived suppressor cells are almost absent.<sup>16,38</sup> The macrophages accumulate in the peritumoural stroma of these neoplasms and infiltrate in areas surrounding neoplastic cells, potentially suppressing the anti-tumour immune response. There is also a considerably enriched proportion of myeloid-derived suppressor cells in the stromal component of invasive IPMNs, specifically pro-tumoural cells of the polymorphonucleate phenotype, which represent 51% of single stromal cells in invasive carcinomas compared with 2% in neoplasms with low-grade dysplasia and 4% in neoplasms with high-grade dysplasia. Similarly, myeloid-derived suppressor cells represented 2% of CD45<sup>+</sup> cells in a mouse model of PanINs.<sup>12</sup> Alternatively, conventional type 2 dendritic cells appear in greater proportion in neoplasms with low-grade dysplasia or high-grade dysplasia than in those associated with invasive carcinoma.<sup>26</sup> These myeloid cells stimulate T cells and mediate the cross presentation of tumour antigens. The fact that a pro-inflammatory myeloid subpopulation dominates pre-invasive lesions and are proportionally replaced by pro-tumoral myeloid-derived suppressor cells in invasive IPMNs further supports that an anti-tumour immune response within pre-neoplastic lesions is overcome during invasion.

In this context, the pivotal role that PGE2 plays in myeloid-derived suppressor cell expansion and maturation is particularly intriguing because PGE2 is associated with increased amount of intraductal papillary mucinous neoplasm dysplasia.<sup>10,39,40</sup> PGE2 alone is sufficient to induce differentiation of dendritic cells into the mesenchymal phenotype of myeloid-derived suppressor cells.<sup>41</sup> Furthermore, several signals that lead to myeloid-derived suppressor cells expansion also induce COX2 activity, leading to a positive feedback loop that stabilises the suppressive functions of myeloid-derived suppressor cells. The production of IDO1 by myeloid-derived suppressor cells also induces regulatory T cells and points to a crucial role of PGE2 in the induction of an immunosuppressive tumour microenvironment through the combined activity of both cell populations.<sup>42</sup> The role of PGE2 is consistent with our earlier reports of high-risk IPMNs being associated with higher expression of PTGES2, an enzyme that catalyses the conversion of PGH2 to PGE2, than

low-risk IPMNs.<sup>10,43</sup> Combined, this evidence could explain the reported higher prevalence of myeloid-derived suppressor cells in IPMNs with high-grade dysplasia than in those with low-grade dysplasia.

There is little research on PD-1 or PD-L1 expression in IPMNs. In a study by Shen and colleagues,<sup>44</sup> the expression of PD-1 on peripheral CD8<sup>+</sup> T cells was higher in pancreatic ductal adenocarcinomas than in IPMNs, perhaps indicative of increased T cell exhaustion. This year, Hernandez and colleagues<sup>18</sup> reported an increase in the stromal density of PD-L1-expressing macrophages in isolated IPMNs with low-grade dysplasia compared with those with high-grade dysplasia, but no epithelial expression of PD-L1 was observed. Higher grade of dysplasia in IPMNs has been associated with HHLA2, a protein of the B7 family analogous to PD-L1, which inhibits CD4<sup>+</sup> and CD8<sup>+</sup> T cells.<sup>45,46</sup> Similar to PD-1 or PD-L1, HHLA2 could be a useful target for checkpoint inhibitor immunotherapy,<sup>47–49</sup> although more evidence is needed to fully understand its mechanism. In addition, single-cell RNA sequencing analysis of IPMNs revealed a unique subclass of myeloid cells in both neoplasms with low-grade dysplasia and those with high-grade dysplasia.<sup>16</sup> These cells are characterised by CD1c, THBD, and FCER1a. If and how these cells contribute to the progression of IPMNs remains to be defined, but the fact that they are specific to these neoplasms implies a possible therapeutic target.

## The potential role of immunotherapy in IPMNs

In the past decade, unprecedented responses to immune checkpoint inhibitor immunotherapy have been observed, particularly for the treatment of patients with melanoma and lung cancer.<sup>49–52</sup> With regards to pancreatic cancer, only about 1% of patients will receive adjuvant immunotherapy after resection, primarily patients with microsatellite unstable cancers. In these highly selected patients, adjuvant immunotherapy has shown a survival advantage.<sup>53,54</sup> There are several clinical trials assessing the effects of immune checkpoint inhibitor immunotherapy alone or in combination with other chemotherapeutics for the treatment of pancreatic cancer. However, none of these trials have reported a survival benefit in non-familial or microsatellite stable disease.<sup>55</sup> In fact, not all patients respond in a similar way to immune checkpoint inhibitor immunotherapy, highlighting the need to select patients that will benefit from specific therapies.<sup>56–58</sup> In part, these differences in response could be associated with the extent of tumour mutational burden (TMB), supporting the notion that tumours that develop a larger spectrum of neoantigens than other tumours trigger a more robust immune response once immune checkpoints are blocked.<sup>59</sup> The TMB is higher in cancers with mismatch repair deficiency than in proficient cancers, and as such, the response to PD-1 or PD-L1 blockade is increased in patients with microsatellite unstable pancreatic cancer. Unfortunately, mismatch repair deficiency represents an extremely small proportion of pancreatic ductal adenocarcinomas.<sup>60,61</sup> However, the presence of cytotoxic CD8<sup>+</sup> T cells, activated CD4<sup>+</sup> T cells, and dendritic cells in the microenvironment of IPMNs is distinct from that of PanINs, which means there could be biological evidence to support the ability to generate an anti-tumour immune response to either inhibit progression or treat cancers that arise in association with IPMNs.

Another possibility to increase the immune response in pancreatic cancer could come from the combination of vaccination against tumour-associated antigens and concomitant use of immune checkpoint inhibitor immunotherapy. This approach has been used for pancreatic ductal adenocarcinoma, by combining a granulocyte-macrophage colony-stimulating factor-secreting vaccine (GVAX) with immune checkpoint inhibitor immunotherapy. The combination increased the immune response of patients, but it did not improve survival of patients with metastatic disease compared with FOLFIRINOX chemotherapy (leucovorin, fluorouracil, irinotecan, and oxaliplatin), which is the current standard of care for pancreatic cancer.<sup>62–64</sup> Potential tumour-associated antigens in IPMN include unique MUC proteins, which are highly expressed by the neoplastic cells. The use of these proteins, particularly MUC1, to build cancer vaccines has gained popularity as an approach due to its overexpression in several adenocarcinomas, including pancreatic cancer.<sup>65,66</sup> In general, MUC1 is thought to have immunogenicity and carcinomas that express the hypoglycosylated form of MUC1 tend to have a more aggressive behaviour than carcinomas that express the fully glycosylated form of MUC1.<sup>3,67–71</sup> Different subsets of IPMNs have shown different MUC profiles.<sup>3,67–70</sup> For example, fully glycosylated MUC1 is expressed more abundantly in the subset of IPMNs that are characterised by a gastropancreatobiliary lineage,<sup>72</sup> whereas the tumour-associated hypoglycosylated form of MUC1 has been associated with areas of high-grade dysplasia in IPMNs<sup>73</sup> and with the presence of tumour-infiltrating neutrophils.<sup>74</sup>

MUC2 (also known as gel-forming MUC) is the hallmark of the indolent pathway of intestinal-type IPMNs and their invasive product, colloid carcinomas, both of which have features of intestinal differentiation, which is also evidenced by CDX2 expression.<sup>75</sup> Invasive colloid carcinomas have been reported to have better prognosis than conventional ductal adenocarcinomas.<sup>76</sup> It is plausible that part of this biological difference could be attributable to the different immunogenicity of these different pathways, which is presumably driven by MUC genes.<sup>68</sup> It is this MUC2<sup>+</sup> intestinal group that lead to excessive MUC production and secondary obstructive changes in the pancreas that could also induce a secondary inflammatory cascade. Colloid carcinomas of the pancreas, which derive from the MUC2<sup>+</sup> intestinal pathway, are also often associated with an inflammatory response. All of these factors alter the tumour microenvironment and warrant further studies to establish their biological importance. Furthermore, MUC4, which is absent in the normal pancreas, has been found to be expressed in IPMNs with high-grade dysplasia.<sup>10,77</sup> The role of MUC4 in cancer progression in several epithelial cancers has been described, including in pancreatic ductal adenocarcinomas and IPMNs.<sup>78,79</sup> Specifically, MUC4 has been shown to promote cell-mediated apoptosis of cytotoxic T cells in pancreatic ductal adenocarcinomas. For these reasons, MUC4 could provide a better target for a cancer vaccine than MUC1.<sup>80,81</sup> The fact that both MUC2 and MUC4 are overexpressed in the cyst fluid of high-risk IPMNs points to their potential use for targeted immunotherapy.<sup>77</sup>

Currently, a multicentre, randomised, placebo-controlled phase 2 clinical trial assessing the effect using sulindac to inhibit COX on the progression of IPMNs is ongoing ([NCT04207944](#)). The study, targeting IPMNs considered at high-risk of progression, will assess the effect of 3 years of therapy on the rate of malignant progression. A similar approach has been used to prevent progression of colorectal cancer in the past. This approach was shown to be effective in reducing the number and size of colorectal adenomas;

however, concerns regarding the toxicity of sulindac have restricted its use for cancer prevention.<sup>82,83</sup> Still, new emerging strategies to mitigate the adverse effects of sulindac might allow its use to prevent cancer progression if the drug is shown to be effective for IPMNs.<sup>84</sup> In 2017, a cohort study of 448 patients with IPMNs evaluated the effect of low-dose aspirin on the progression of IPMNs to invasive disease. During a median follow-up of over 5 years, there was no difference in progression to invasive cancer; however, there was a decrease in worsening main duct dilation compared with patients who were not given low-dose aspirin.<sup>85</sup> These approaches broadly affect the inflammatory mediators that are associated with IPMNs. However, more nuanced and targeted therapies are clearly needed, which is becoming more possible through phenotypic analysis of the tumour immune microenvironment.

## The role of the microbiome in the progression of IPMNs

It has become increasingly clear that the microbiome can play a crucial role in the development of cancer, cancer progression, immunogenicity, and response to specific immune therapies. Therefore, the composition and the role of the microbiome in the normal pancreas and in pancreatic diseases, including cancer, have become an important topic of investigation. Initially the pancreas was thought to be sterile, with no bacterial colonisation in normal conditions. However, several studies have now reported the presence of different bacteria in the normal pancreas, but there is no agreement on the typical taxa that compose this microbiome.<sup>86</sup> It should be noted that the definition of normal pancreas varied across studies. Some authors included samples from pancreases with non-malignant aetiologies (eg, benign cysts) in their analyses, whereas other authors analysed samples from organ donors or cadavers. Furthermore, no agreement is present on the mechanism by which the pancreas is colonised by microbes that are present in the gastrointestinal tract. On one hand, reflux through the pancreatic duct has been suggested as an aetiology in a genetically engineered mouse model, but not in wild-type C57BL/6<sup>87</sup> or germ-free 129SvEv<sup>88</sup> mice. On the other hand, translocation from the gut has been implicated with inconsistent results in multiple preclinical models.<sup>88,89</sup> Clearly, the flora that constitute the microbiome should be determined, and current studies do not support a specific source for the colonisation. This source will need to be further evaluated to advance our current understanding of the microbiome and to identify patients with similar microbial diversity.

The composition and role of the microbiome, specifically in IPMNs, has been investigated in relation to pancreatic ductal adenocarcinoma and healthy controls. In a pilot study, the oral microbiota of patients with pancreatic ductal adenocarcinomas (n=40), patients with IPMNs (n=39), and healthy controls (n=58) were evaluated. This study but did not reveal any difference in  $\alpha$ -diversity (ie, a metric that summarises the biological richness, or the number of different taxa, of each sample) between the groups. However, the relative abundance of specific taxa was different between patients with pancreatic ductal adenocarcinomas and those with IPMNs, with patients with pancreatic ductal adenocarcinomas having a higher proportion of Firmicutes. Although both patients with IPMNs with low-grade dysplasia (n=12, 37.5%) and those with high-grade dysplasia (20, 62.5%) were included in this study, the analysis did not focus on the differences that existed according to the degree of dysplasia, which will be crucial to understand differences in the progression towards

invasive disease.<sup>90</sup> This study and other similar reports could have diagnostic implications that will need to be further assessed in future studies.

When analysing the duodenal microbiome of patients with pancreatic ductal adenocarcinoma (n=74), a pancreatic cyst (n=98), or a normal pancreas (n=134), a decrease in  $\alpha$ -diversity was observed in patients with pancreatic ductal adenocarcinomas compared with those with unclassified pancreatic cysts or normal pancreases.<sup>91</sup> Furthermore, an increase in the relative abundance of *Escherichia*, *Shigella*, *Enterococcus*, *Clostridium sensu stricto 1* and *Bifidobacterium* was observed in patients with pancreatic ductal adenocarcinomas compared with those with pancreatic cysts. No differences were observed in the relative abundance of specific taxa between patients with pancreatic cysts and those with normal pancreases.

Analysis of the cyst fluid microbiome of 105 patients with pancreatic cystic neoplasms also revealed that IPMNs with high-grade dysplasia were associated with an increase in bacterial DNA and IL-1 $\beta$  expression compared with non-IPMN cystic neoplasms.<sup>92,93</sup> The positive association between bacterial DNA and IL-1 $\beta$  pointed to a possible role of the cyst microbiome in shaping the tumour immune microenvironment of the neoplasm. An investigation on the microbiome of the cyst fluid of IPMNs found that 29 patients that underwent preoperative invasive endoscopic procedures had a higher rate of bacterial growth than patients who did not undergo these procedures. The bacterial strains that were more commonly identified were *Klebsiella* spp, *Enterococcus faecalis*, and *Enterobacter cloacae*, with no difference found in the occurrence of these strains between neoplasms with low-grade dysplasia and those with high-grade dysplasia.<sup>94</sup> Similar to investigating the aetiology of pancreatic duct colonisation, the role that endoscopic interventions could play in changing the microbiome will need to be examined in the future, particularly if specific microbiomes are found to correlate with disease outcomes and malignant progression. Furthermore, three specific taxa were elevated in the oral microbiome of patients with an intraductal papillary mucinous neoplasm with high-grade dysplasia: *Fusobacterium*, *Granulicatella* and *Serratia*.<sup>92</sup> Among these taxa, *Fusobacterium nucleatum*, as an oncobacterium, had already been reported in association with an increased development of colorectal cancer in an animal model.<sup>95</sup> Antibiotic treatment with metronidazole was able to reduce *Fusobacterium* load and tumour growth in mice that had colorectal cancer xenografts.<sup>96</sup> The characteristics of the microbiome of pancreatic cancer and IPMNs are summarised in figure 2.

The causal relationship between the progression of IPMNs and the microbiome is still debated. Chronic inflammation caused by bacterial infection has been associated with the upregulation of transcription factors associated with epithelial to mesenchymal transition in humans.<sup>97</sup> Because this transition is known to occur in pancreatic cancer,<sup>98</sup> the contribution of the microbiome and the tumour microenvironment to epithelial to mesenchymal transition might offer an alternative strategy to identify patients at high risk of malignant transformation.<sup>99</sup> In a pancreatic cancer mouse model, bacterial ablation with oral antibiotics was associated with a reduction in the development of preinvasive and invasive pancreatic adenocarcinoma compared with mice who were not given oral antibiotics. Consequently, when the pancreatic ductal adenocarcinoma KC model mice (bearing a *KRAS*<sup>G12D</sup> mutation) were treated with oral antibiotic and then received gut

microbiome re-population with feces from mice with pancreatic ductal adenocarcinoma, an acceleration in tumour growth was observed that was similar to the growth seen before mice were treated with antibiotics.<sup>87</sup> These results point to the relevance of the gut microbiome in the development and progression of pancreatic adenocarcinoma. All of these associations are important for the identification of bacterial signatures that could reflect the amount of dysplasia in IPMNs. Furthermore, these associations might be modifiable by using antibiotics as part of the treatment strategy. Clearly this is a burgeoning field of research and both preclinical and clinical research evaluating the microbiome are needed to advance our understanding and to identify potential diagnostic and therapeutic interventions.

## Conclusions

The tumour immune microenvironment of IPMNs evolves during malignant progression in accordance with the paradigm of cancer immunoediting. A cytotoxic immune response rich in CD8<sup>+</sup>T cells and a paucity of suppressing immunocytes changes to an immunosuppressive environment when neoplasms progress from low-grade dysplasia to high-grade dysplasia, and then to invasive carcinoma. IPMNs with high-grade dysplasia or invasive carcinoma contain a predominantly immunosuppressive environment. This evidence suggests that therapies that support cytotoxic T cells could be ideal for IPMNs with low-risk disease, whereas treatments that target regulatory T cells, myeloid-derived suppressor cells, and inhibitory macrophages could play a role in reducing malignant progression and treating high-risk disease. In addition to the treatment of IPMNs with an associated invasive carcinoma, addressing the tumour immune microenvironment could, ideally, prevent the progression of IPMNs at high risk of malignant transformation. Clearly, further studies addressing the tumour immune microenvironment of pre-invasive lesions are needed, including assessment of main-duct disease compared with branch-duct disease.

One of the main obstacles toward a deeper understanding of the tumour immune microenvironment of IPMNs is the absence of a validated preclinical model, including organoids or syngeneic animal models that reliably recapitulate the progression towards invasive cancer with an intact immune system.<sup>100,101</sup> Although validated organoids for IPMNs have been created, these organoids have been developed with the WENR method (ie, using Wnt, EGF, Noggin, and R-spondin signalling pathways) and thus do not have a stromal component that makes it challenging to study the tumour immune microenvironment. One solution to this problem would be to co-culture patient-specific immune components with the neoplastic epithelial cells<sup>102,103</sup> or to use air–liquid interface organoids.<sup>104,105</sup> Mouse models of IPMNs have also been developed.<sup>106–108</sup> However, to date, murine IPMN cell lines that can be used in immunocompetent syngeneic murine models are yet to be realised.

Overall, in contrast to PanINs, there appear to be substantial changes in the tumour microenvironment during the progression of IPMNs. Furthermore, initial studies of the tumour immune microenvironment point towards the potential of using immunotherapeutic approaches to target IPMNs.

## Acknowledgments

All authors are members of the Verona Evidence-Based IPMN Genetic Alteration, Microbiota, and Microenvironment Group.

## References

1. Kromrey ML, Bülow R, Hübner J, et al. Prospective study on the incidence, prevalence and 5-year pancreatic-related mortality of pancreatic cysts in a population-based study. *Gut* 2018; 67: 138–45. [PubMed: 28877981]
2. Zerboni G, Signoretti M, Crippa S, Falconi M, Arcidiacono PG, Capurso G. Systematic review and meta-analysis: prevalence of incidentally detected pancreatic cystic lesions in asymptomatic individuals. *Pancreatol* 2019; 19: 2–9. [PubMed: 30503370]
3. Basturk O, Adsay V, Askan G, et al. Intraductal tubulopapillary neoplasm of the pancreas: a clinicopathologic and immunohistochemical analysis of 33 cases. *Am J Surg Pathol* 2017; 41: 313–25. [PubMed: 27984235]
4. Tanaka M Intraductal papillary mucinous neoplasm of the pancreas as the main focus for early detection of pancreatic adenocarcinoma. *Pancreas* 2018; 47: 544–50. [PubMed: 29702531]
5. Basturk O, Hong SM, Wood LD, et al. A revised classification system and recommendations from the baltimore consensus meeting for neoplastic precursor lesions in the pancreas. *Am J Surg Pathol* 2015; 39: 1730–41. [PubMed: 26559377]
6. Goggins M, Overbeek KA, Brand R, et al. Management of patients with increased risk for familial pancreatic cancer: updated recommendations from the International Cancer of the Pancreas Screening (CAPS) Consortium. *Gut* 2020; 69: 7–17. [PubMed: 31672839]
7. Khoury RE, Kabir C, Maker VK, Banulescu M, Wasserman M, Maker AV. What is the incidence of malignancy in resected intraductal papillary mucinous neoplasms? an analysis of over 100 US institutions in a single year. *Ann Surg Oncol* 2018; 25: 1746–51. [PubMed: 29560572]
8. Maker AV. ASO author reflections: improving identification of intraductal papillary mucinous neoplasm patients at risk-current status and the role of ipmn molecular biomarkers. *Ann Surg Oncol* 2018; 25 (suppl 3): 818–19.
9. Maker AV, Katabi N, Qin LX, et al. Cyst fluid interleukin-1beta (IL1beta) levels predict the risk of carcinoma in intraductal papillary mucinous neoplasms of the pancreas. *Clin Cancer Res* 2011; 17: 1502–08. [PubMed: 21266527]
10. Maker AV, Hu V, Kadkol SS, et al. Cyst fluid biosignature to predict intraductal papillary mucinous neoplasms of the pancreas with high malignant potential. *J Am Coll Surg* 2019; 228: 721–29. [PubMed: 30794864]
11. Mateos RN, Nakagawa H, Hirono S, et al. Genomic analysis of pancreatic juice DNA assesses malignant risk of intraductal papillary mucinous neoplasm of pancreas. *Cancer Med* 2019; 8: 4565–73. [PubMed: 31225717]
12. Clark CE, Hingorani SR, Mick R, Combs C, Tuveson DA, Vonderheide RH. Dynamics of the immune reaction to pancreatic cancer from inception to invasion. *Cancer Res* 2007; 67: 9518–27. [PubMed: 17909062]
13. Jang J-E, Hajdu CH, Liot C, Miller G, Dustin ML, Bar-Sagi D. Crosstalk between regulatory t cells and tumor-associated dendritic cells negates anti-tumor immunity in pancreatic cancer. *Cell Rep* 2017; 20: 558–71. [PubMed: 28723561]
14. Opitz FV, Haeblerle L, Daum A, Esposito I. Tumor microenvironment in pancreatic intraepithelial neoplasia. *Cancers (Basel)* 2021; 13: 6188. [PubMed: 34944807]
15. Gonzalez H, Hagerling C, Werb Z. Roles of the immune system in cancer: from tumor initiation to metastatic progression. *Genes Dev* 2018; 32: 1267–84. [PubMed: 30275043]
16. Bernard V, Semaan A, Huang J, et al. Single-cell transcriptomics of pancreatic cancer precursors demonstrates epithelial and microenvironmental heterogeneity as an early event in neoplastic progression. *Clin Cancer Res* 2019; 25: 2194–205. [PubMed: 30385653]

17. Fischer CG, Beleva Guthrie V, Braxton AM, et al. Intraductal papillary mucinous neoplasms arise from multiple independent clones, each with distinct mutations. *Gastroenterology* 2019; 157: 1123–37. [PubMed: 31175866]
18. Hernandez S, Parra ER, Uraoka N, et al. Diminished immune surveillance during histologic progression of intraductal papillary mucinous neoplasms offers a therapeutic opportunity for cancer interception. *Clin Cancer Res* 2022; 28: 1938–47. [PubMed: 35491652]
19. Roth S, Zamzow K, Gaida MM, et al. Evolution of the immune landscape during progression of pancreatic intraductal papillary mucinous neoplasms to invasive cancer. *EBioMedicine* 2020; 54: 102714. [PubMed: 32259711]
20. Wartenberg M, Cibin S, Zlobec I, et al. Integrated genomic and immunophenotypic classification of pancreatic cancer reveals three distinct subtypes with prognostic/predictive significance. *Clin Cancer Res* 2018; 24: 4444–54. [PubMed: 29661773]
21. Balachandran VP, Łuksza M, Zhao JN, et al. Identification of unique neoantigen qualities in long-term survivors of pancreatic cancer. *Nature* 2017; 551: 512–16. [PubMed: 29132146]
22. Kane S, Engelhart A, Guadagno J, Jones A, Usoro I, Brucher E. Pancreatic ductal adenocarcinoma: characteristics of tumor microenvironment and barriers to treatment. *J Adv Pract Oncol* 2020; 11: 693–98. [PubMed: 33575066]
23. Karamitopoulou E Tumour microenvironment of pancreatic cancer: immune landscape is dictated by molecular and histopathological features. *Br J Cancer* 2019; 121: 5–14. [PubMed: 31110329]
24. Shevryev D, Tereshchenko V. Treg heterogeneity, function, and homeostasis. *Front Immunol* 2020; 10: 3100. [PubMed: 31993063]
25. Shimizu J, Yamazaki S, Takahashi T, Ishida Y, Sakaguchi S. Stimulation of CD25(+)/CD4(+) regulatory T cells through GITR breaks immunological self-tolerance. *Nat Immunol* 2002; 3: 135–42. [PubMed: 11812990]
26. Ohue Y, Nishikawa H. Regulatory T (Treg) cells in cancer: can Treg cells be a new therapeutic target? *Cancer Sci* 2019; 110: 2080–89. [PubMed: 31102428]
27. Hiraoka N, Onozato K, Kosuge T, Hirohashi S. Prevalence of FOXP3+ regulatory T cells increases during the progression of pancreatic ductal adenocarcinoma and its premalignant lesions. *Clin Cancer Res* 2006; 12: 5423–34. [PubMed: 17000676]
28. Zhang Y, Lazarus J, Steele NG, et al. Regulatory T-cell depletion alters the tumor microenvironment and accelerates pancreatic carcinogenesis. *Cancer Discov* 2020; 10: 422–39. [PubMed: 31911451]
29. Kobayashi N, Kubota K, Kato S, et al. FOXP3+ regulatory T cells and tumoral indoleamine 2,3-dioxygenase expression predicts the carcinogenesis of intraductal papillary mucinous neoplasms of the pancreas. *Pancreatol* 2010; 10: 631–40. [PubMed: 21051918]
30. Ikemoto T, Shimada M, Komatsu M, et al. Indoleamine 2,3-dioxygenase affects the aggressiveness of intraductal papillary mucinous neoplasms through Foxp3+CD4+CD25+ T cells in peripheral blood. *Pancreas* 2013; 42: 130–34. [PubMed: 22722263]
31. Ikemoto T, Sugimoto K, Shimada M, et al. Clinical role of Notch signaling pathway in intraductal papillary mucinous neoplasm of the pancreas. *J Gastroenterol Hepatol* 2015; 30: 217–22. [PubMed: 25041344]
32. Masiero M, Li D, Whiteman P, et al. Development of therapeutic anti-JAGGED1 antibodies for cancer therapy. *Mol Cancer Ther* 2019; 18: 2030–42. [PubMed: 31395687]
33. Li D, Masiero M, Banham AH, Harris AL. The notch ligand JAGGED1 as a target for anti-tumor therapy. *Front Oncol* 2014; 4: 254. [PubMed: 25309874]
34. Law AMK, Valdes-Mora F, Gallego-Ortega D. Myeloid-derived suppressor cells as a therapeutic target for cancer. *Cells* 2020; 9: E561.
35. Pinton L, Sólito S, Damuzzo V, et al. Activated T cells sustain myeloid-derived suppressor cell-mediated immune suppression. *Oncotarget* 2016; 7: 1168–84. [PubMed: 26700461]
36. Gabrilovich DI, Nagaraj S. Myeloid-derived suppressor cells as regulators of the immune system. *Nat Rev Immunol* 2009; 9: 162–74. [PubMed: 19197294]
37. Pergamo M, Miller G. Myeloid-derived suppressor cells and their role in pancreatic cancer. *Cancer Gene Ther* 2017; 24: 100–05. [PubMed: 27910857]



38. Ma P, Beatty PL, McKolanis J, Brand R, Schoen RE, Finn OJ. Circulating myeloid derived suppressor cells (MDSC) that accumulate in premalignancy share phenotypic and functional characteristics with MDSC in cancer. *Front Immunol* 2019; 10: 1401. [PubMed: 31275327]
39. Yip-Schneider MT, Carr RA, Wu H, Schmidt CM. Prostaglandin E2: a pancreatic fluid biomarker of intraductal papillary mucinous neoplasm dysplasia. *J Am Coll Surg* 2017; 225: 481–87. [PubMed: 28739154]
40. Tulla KA, Maker AV. Can we better predict the biologic behavior of incidental IPMN? A comprehensive analysis of molecular diagnostics and biomarkers in intraductal papillary mucinous neoplasms of the pancreas. *Langenbecks Arch Surg* 2018; 403: 151–94. [PubMed: 29218397]
41. Sinha P, Clements VK, Fulton AM, Ostrand-Rosenberg S. Prostaglandin E2 promotes tumor progression by inducing myeloid-derived suppressor cells. *Cancer Res* 2007; 67: 4507–13. [PubMed: 17483367]
42. Tomi S, Joksimovi B, Beki M, et al. Prostaglandin-E2 potentiates the suppressive functions of human mononuclear myeloid-derived suppressor cells and increases their capacity to expand IL-10-producing regulatory T cell subsets. *Front Immunol* 2019; 10: 475. [PubMed: 30936876]
43. Maker AV, Carrara S, Jamieson NB, et al. Cyst fluid biomarkers for intraductal papillary mucinous neoplasms of the pancreas: a critical review from the international expert meeting on pancreatic branch-duct-intraductal papillary mucinous neoplasms. *J Am Coll Surg* 2015; 220: 243–53. [PubMed: 25592469]
44. Shen T, Zhou L, Shen H, et al. Prognostic value of programmed cell death protein 1 expression on CD8+ T lymphocytes in pancreatic cancer. *Sci Rep* 2017; 7: 7848. [PubMed: 28798308]
45. Yan H, Qiu W, Koehne de Gonzalez AK, et al. HHLA2 is a novel immune checkpoint protein in pancreatic ductal adenocarcinoma and predicts post-surgical survival. *Cancer Lett* 2019; 442: 333–40. [PubMed: 30447255]
46. Zhao R, Chinai JM, Buhl S, et al. HHLA2 is a member of the B7 family and inhibits human CD4 and CD8 T-cell function. *Proc Natl Acad Sci USA* 2013; 110: 9879–84. [PubMed: 23716685]
47. Rieder SA, Wang J, White N, et al. B7-H7 (HHLA2) inhibits T-cell activation and proliferation in the presence of TCR and CD28 signaling. *Cell Mol Immunol* 2021; 18: 1503–11. [PubMed: 32005952]
48. Janakiram M, Chinai JM, Zhao A, Sparano JA, Zang X. HHLA2 and TMIGD2: new immunotherapeutic targets of the B7 and CD28 families. *Oncolimmunology* 2015; 4: e1026534.
49. Jing CY, Fu YP, Yi Y, et al. HHLA2 in intrahepatic cholangiocarcinoma: an immune checkpoint with prognostic significance and wider expression compared with PD-L1. *J Immunother Cancer* 2019; 7: 77. [PubMed: 30885276]
50. Herrscher H, Robert C. Immune checkpoint inhibitors in melanoma in the metastatic, neoadjuvant, and adjuvant setting. *Curr Opin Oncol* 2020; 32: 106–13. [PubMed: 31876547]
51. Khan M, Lin J, Liao G, et al. Comparative analysis of immune checkpoint inhibitors and chemotherapy in the treatment of advanced non-small cell lung cancer: A meta-analysis of randomized controlled trials. *Medicine (Baltimore)* 2018; 97: e11936. [PubMed: 30113497]
52. Jain P, Jain C, Velcheti V. Role of immune-checkpoint inhibitors in lung cancer. *Ther Adv Respir Dis* 2018; 12: 1753465817750075. [PubMed: 29385894]
53. Tran TB, Maker VK, Maker AV. Impact of immunotherapy after resection of pancreatic cancer. *J Am Coll Surg* 2019; 229: 19–27.e1. [PubMed: 30742911]
54. Lawlor RT, Mattiolo P, Mafficini A, et al. Tumor mutational burden as a potential biomarker for immunotherapy in pancreatic cancer: systematic review and still-open questions. *Cancers (Basel)* 2021; 13: 3119. [PubMed: 34206554]
55. Schizas D, Charalampakis N, Kole C, et al. Immunotherapy for pancreatic cancer: a 2020 update. *Cancer Treat Rev* 2020; 86: 102016. [PubMed: 32247999]
56. Robert C A decade of immune-checkpoint inhibitors in cancer therapy. *Nat Commun* 2020; 11: 3801. [PubMed: 32732879]
57. Shen X, Zhao B. Efficacy of PD-1 or PD-L1 inhibitors and PD-L1 expression status in cancer: meta-analysis. *BMJ* 2018; 362: k3529. [PubMed: 30201790]
58. Jamieson NB, Maker AV. Gene-expression profiling to predict responsiveness to immunotherapy. *Cancer Gene Ther* 2017; 24: 134–40. [PubMed: 27834354]

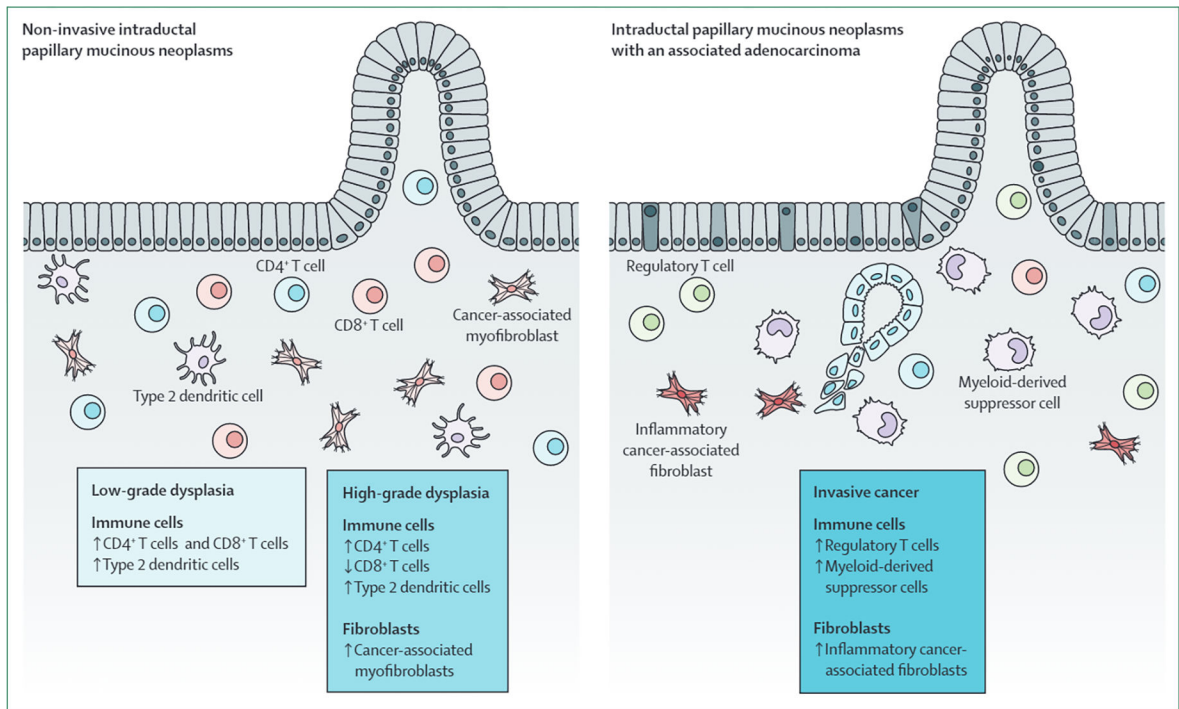
59. Maleki Vareki S High and low mutational burden tumors versus immunologically hot and cold tumors and response to immune checkpoint inhibitors. *J Immunother Cancer* 2018; 6: 157. [PubMed: 30587233]
60. Hu ZI, Shia J, Stadler ZK, et al. Evaluating mismatch repair deficiency in pancreatic adenocarcinoma: challenges and recommendations. *Clin Cancer Res* 2018; 24: 1326–36. [PubMed: 29367431]
61. Luchini C, Brosens LAA, Wood LD, et al. Comprehensive characterisation of pancreatic ductal adenocarcinoma with microsatellite instability: histology, molecular pathology and clinical implications. *Gut* 2021; 70: 148–56. [PubMed: 32350089]
62. Soares KC, Rucki AA, Wu AA, et al. PD-1/PD-L1 blockade together with vaccine therapy facilitates effector T-cell infiltration into pancreatic tumors. *J Immunother* 2015; 38: 1–11. [PubMed: 25415283]
63. Saung MT, Zheng L. Adding combination immunotherapy consisting of cancer vaccine, anti-PD-1 and anti-CSF1R antibodies to gemcitabine improves anti-tumor efficacy in murine model of pancreatic ductal adenocarcinoma. *Ann Pancreat Cancer* 2019; 2: 2.
64. Wu AA, Bever KM, Ho WJ, et al. A phase II study of allogeneic GM-CSF-transfected pancreatic tumor vaccine (GVAX) with Ipilimumab as maintenance treatment for metastatic pancreatic cancer. *Clin Cancer Res* 2020; 26: 5129–39. [PubMed: 32591464]
65. Nath S, Mukherjee P. MUC1: a multifaceted oncoprotein with a key role in cancer progression. *Trends Mol Med* 2014; 20: 332–42. [PubMed: 24667139]
66. Apostolopoulos V, McKenzie IFC. Cellular mucins: targets for immunotherapy. *Crit Rev Immunol* 2017; 37: 421–37. [PubMed: 29773028]
67. Adsay NV, Merati K, Andea A, et al. The dichotomy in the preinvasive neoplasia to invasive carcinoma sequence in the pancreas: differential expression of MUC1 and MUC2 supports the existence of two separate pathways of carcinogenesis. *Mod Pathol* 2002; 15: 1087–95. [PubMed: 12379756]
68. Levi E, Klimstra DS, Andea A, Basturk O, Adsay NV. MUC1 and MUC2 in pancreatic neoplasia. *J Clin Pathol* 2004; 57: 456–62. [PubMed: 15113850]
69. Adsay NV, Merati K, Basturk O, et al. Pathologically and biologically distinct types of epithelium in intraductal papillary mucinous neoplasms: delineation of an “intestinal” pathway of carcinogenesis in the pancreas. *Am J Surg Pathol* 2004; 28: 839–48. [PubMed: 15223952]
70. Basturk O, Chung SM, Hruban RH, et al. Distinct pathways of pathogenesis of intraductal oncocytic papillary neoplasms and intraductal papillary mucinous neoplasms of the pancreas. *Virchows Arch* 2016; 469: 523–32. [PubMed: 27591765]
71. Schueneman A, Goggins M, Ensor J, et al. Validation of histomolecular classification utilizing histological subtype, MUC1, and CDX2 for prognostication of resected ampullary adenocarcinoma. *Br J Cancer* 2015; 113: 64–68. [PubMed: 25989273]
72. Klausen P, Kovacevic B, Toxvaerd A, et al. Subtyping of intraductal papillary mucinous neoplasms - pitfalls of MUC1 immunohistochemistry. *APMIS* 2019; 127: 27–32. [PubMed: 30549137]
73. Beatty PL, van der Geest R, Hashash JG, et al. Immunobiology and immunosurveillance in patients with intraductal papillary mucinous neoplasms (IPMNs), premalignant precursors of pancreatic adenocarcinomas. *Cancer Immunol Immunother* 2016; 65: 771–78. [PubMed: 27106024]
74. Reid MD, Basturk O, Thirabanjasak D, et al. Tumor-infiltrating neutrophils in pancreatic neoplasia. *Mod Pathol* 2011; 24: 1612–19. [PubMed: 21822201]
75. Adsay NV, Merati K, Nassar H, et al. Pathogenesis of colloid (pure mucinous) carcinoma of exocrine organs: Coupling of gel-forming mucin (MUC2) production with altered cell polarity and abnormal cell-stroma interaction may be the key factor in the morphogenesis and indolent behavior of colloid carcinoma in the breast and pancreas. *Am J Surg Pathol* 2003; 27: 571–78. [PubMed: 12717243]
76. Adsay NV, Pierson C, Sarkar F, et al. Colloid (mucinous noncystic) carcinoma of the pancreas. *Am J Surg Pathol* 2001; 25: 26–42. [PubMed: 11145249]
77. Maker AV, Katabi N, Gonen M, et al. Pancreatic cyst fluid and serum mucin levels predict dysplasia in intraductal papillary mucinous neoplasms of the pancreas. *Ann Surg Oncol* 2011; 18: 199–206. [PubMed: 20717734]

78. Xia P, Choi AH, Deng Z, et al. Cell membrane-anchored MUC4 promotes tumorigenicity in epithelial carcinomas. *Oncotarget* 2017; 8: 14147–57. [PubMed: 27829225]
79. Rowson-Hodel AR, Wald JH, Hatakeyama J, et al. Membrane Mucin MUC4 promotes blood cell association with tumor cells and mediates efficient metastasis in a mouse model of breast cancer. *Oncogene* 2018; 37:197–207. [PubMed: 28892049]
80. Gautam SK, Kumar S, Cannon A, et al. MUC4 mucin-a therapeutic target for pancreatic ductal adenocarcinoma. *Expert Opin Ther Targets* 2017; 21: 657–69. [PubMed: 28460571]
81. Gautam SK, Kumar S, Dam V, Ghersi D, Jain M, Batra SK. MUCIN-4 (MUC4) is a novel tumor antigen in pancreatic cancer immunotherapy. *Semin Immunol* 2020; 47: 101391. [PubMed: 31952903]
82. Giardiello FM, Hamilton SR, Krush AJ, et al. Treatment of colonic and rectal adenomas with sulindac in familial adenomatous polyposis. *N Engl J Med* 1993; 328: 1313–16. [PubMed: 8385741]
83. Umezawa S, Higurashi T, Komiya Y, et al. Chemoprevention of colorectal cancer Past, present, and future. *Cancer Sci* 2019; 110: 3018–26. [PubMed: 31361372]
84. Davis JS, Kanikarla-Marie P, Gagea M, et al. Sulindac plus a phospholipid is effective for polyp reduction and safer than sulindac alone in a mouse model of colorectal cancer development. *BMC Cancer* 2020; 20: 871. [PubMed: 32912193]
85. Takasaki Y, Nagata N, Imbe K, et al. Effect of low-dose aspirin use on pancreatic cancer development and morphological changes on imaging in IPMN: a long-term cohort study. *United European Gastroenterol J* 2017; 5:1030–36.
86. Thomas RM, Jobin C. Microbiota in pancreatic health and disease: the next frontier in microbiome research. *Nat Rev Gastroenterol Hepatol* 2020; 17: 53–64. [PubMed: 31811279]
87. Pushalkar S, Hundeyin M, Daley D, et al. The pancreatic cancer microbiome promotes oncogenesis by induction of innate and adaptive immune suppression. *Cancer Discov* 2018; 8: 403–16. [PubMed: 29567829]
88. Thomas RM, Gharaibeh RZ, Gauthier J, et al. Intestinal microbiota enhances pancreatic carcinogenesis in preclinical models. *Carcinogenesis* 2018; 39: 1068–78. [PubMed: 29846515]
89. Widdison AL, Karanjia ND, Reber HA. Routes of spread of pathogens into the pancreas in a feline model of acute pancreatitis. *Gut* 1994; 35: 1306–10. [PubMed: 7959243]
90. Olson SH, Satagopan J, Xu Y, et al. The oral microbiota in patients with pancreatic cancer, patients with IPMNs, and controls: a pilot study. *Cancer Causes Control* 2017; 28: 959–69. [PubMed: 28762074]
91. Kohi S, Macgregor-Das A, Dbouk M, et al. Alterations in the duodenal fluid microbiome of patients with pancreatic cancer. *Clin Gastroenterol Hepatol* 2020.
92. Gaiser RA, Halimi A, Alkharaan H, et al. Enrichment of oral microbiota in early cystic precursors to invasive pancreatic cancer. *Gut* 2019; 68: 2186–94. [PubMed: 30872392]
93. Morgell A, Reisz JA, Ateeb Z, et al. Metabolic characterization of plasma and cyst fluid from cystic precursors to pancreatic cancer patients reveal metabolic signatures of bacterial infection. *J Proteome Res* 2021; 20: 2725–38. [PubMed: 33720736]
94. Halimi A, Gabarrini G, Sobkowiak MJ, et al. Isolation of pancreatic microbiota from cystic precursors of pancreatic cancer with intracellular growth and DNA damaging properties. *Gut Microbes* 2021; 13: 1983101. [PubMed: 34816784]
95. Brennan CA, Garrett WS. *Fusobacterium nucleatum*—symbiont, opportunist and oncobacterium. *Nat Rev Microbiol* 2019; 17: 156–66. [PubMed: 30546113]
96. Bullman S, Peadarallu CS, Sicinska E, et al. Analysis of *Fusobacterium* persistence and antibiotic response in colorectal cancer. *Science* 2017; 358: 1443–8. [PubMed: 29170280]
97. Vergara D, Simeone P, Damato M, Maffia M, Lanuti P, Trerotola M. The cancer microbiota: EMT and inflammation as shared molecular mechanisms associated with plasticity and progression. *J Oncol* 2019; 2019: 1253727. [PubMed: 31772577]
98. Rhim AD, Mirek ET, Aiello NM, et al. EMT and dissemination precede pancreatic tumor formation. *Cell* 2012; 148: 349–61. [PubMed: 22265420]
99. Bulle A, Lim KH. Beyond just a tight fortress: contribution of stroma to epithelial-mesenchymal transition in pancreatic cancer. *Signal Transduct Target Ther* 2020; 5: 249. [PubMed: 33122631]

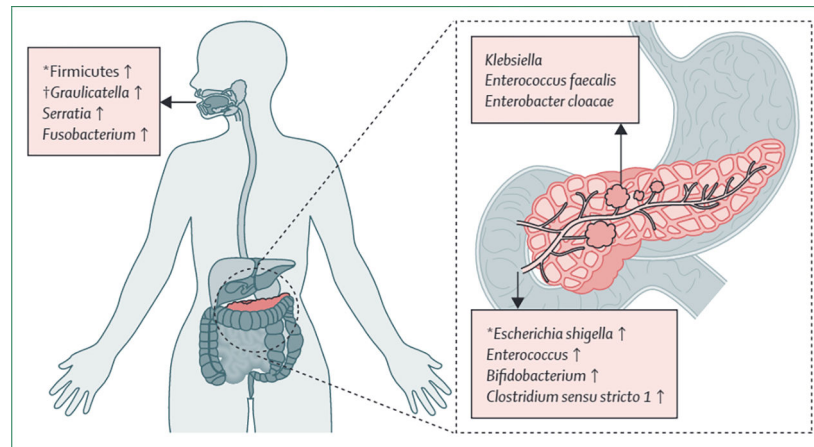
100. Beato F, Reverón D, Dezsai KB, et al. Establishing a living biobank of patient-derived organoids of intraductal papillary mucinous neoplasms of the pancreas. *Lab Invest* 2021; 101: 204–17. [PubMed: 33037322]
101. Huang B, Trujillo MA, Fujikura K, et al. Molecular characterization of organoids derived from pancreatic intraductal papillary mucinous neoplasms. *J Pathol* 2020; 252: 252–62. [PubMed: 32696980]
102. Yuki K, Cheng N, Nakano M, Kuo CJ. Organoid models of tumor immunology. *Trends Immunol* 2020; 41: 652–64. [PubMed: 32654925]
103. Holokai L, Chakrabarti J, Lundy J, et al. Murine- and human-derived autologous organoid/immune cell co-cultures as pre-clinical models of pancreatic ductal adenocarcinoma. *Cancers (Basel)* 2020; 12: E3816.
104. Neal JT, Li X, Zhu J, et al. Organoid modeling of the tumor immune microenvironment. *Cell* 2018; 175: 1972–88. [PubMed: 30550791]
105. Li Y, Tang P, Cai S, Peng J, Hua G. Organoid based personalized medicine: from bench to bedside. *Cell Regen (Lond)* 2020; 9: 21.
106. Ideno N, Yamaguchi H, Ghosh B, et al. GNAS<sup>R201C</sup> induces pancreatic cystic neoplasms in mice that express activated KRAS by inhibiting YAP1 signaling. *Gastroenterology* 2018; 155: 1593–607. [PubMed: 30142336]
107. Taki K, Ohmuraya M, Tanji E, et al. GNAS(R201H) and Kras(G12D) cooperate to promote murine pancreatic tumorigenesis recapitulating human intraductal papillary mucinous neoplasm. *Oncogene* 2016; 35: 2407–12. [PubMed: 26257060]
108. Kopp JL, Dubois CL, Schaeffer DF, et al. Loss of PTEN and activation of KRAS synergistically induce formation of intraductal papillary mucinous neoplasia from pancreatic ductal cells in mice. *Gastroenterology* 2018; 154: 1509–23. [PubMed: 29273451]

### Search strategy and selection criteria

A PubMed search to identify peer-reviewed articles in English was done from Jan 1, 1993 to Jan 1, 2022. The search terms “IPMN”, “Intraductal Papillary Mucinous Neoplasm”, and “pancreatic cancer” were chosen (on the basis of the authors’ expertise within the field). These search terms were used in combination with the terms “immune microenvironment”, “immunotherapy”, “lymphocyte”, “MDSC”, “Treg”, “immune checkpoint inhibitors”, and “cancer vaccine”. All titles, abstracts, and reference lists from identified articles were assessed for relevance.



**Figure 1:** Summary of immune cell and fibroblast populations during progression from low-grade dysplasia, to high-grade dysplasia, to invasive cancer in intraductal papillary mucinous neoplasms



**Figure 2: Summary of the oral, duodenal, and cyst fluid microbiome of intraductal papillary mucinous neoplasms**

\*Increased prevalence in patients with pancreatic ductal adenocarcinoma compared with patients with intraductal papillary mucinous neoplasm. †Increased prevalence in patients with intraductal papillary mucinous neoplasm with high-grade dysplasia compared with patients with neoplasms with low-grade dysplasia or invasive cancer.