

# UCLA

## UCLA Previously Published Works

### Title

Quantification of Anterior Chamber Cells in Children With Uveitis Using Anterior Segment Optical Coherence Tomography

### Permalink

<https://escholarship.org/uc/item/9pd6f846>

### Authors

Tsui, Edmund  
Chen, Judy L  
Jackson, Nicholas J  
[et al.](#)

### Publication Date

2022-09-01

### DOI

10.1016/j.ajo.2022.05.012

Peer reviewed



Published in final edited form as:

*Am J Ophthalmol.* 2022 September ; 241: 254–261. doi:10.1016/j.ajo.2022.05.012.

## Quantification of Anterior Chamber Cells in Children with Uveitis Using Anterior Segment Optical Coherence Tomography

Edmund Tsui,

Judy L. Chen,

Nicholas J. Jackson,

Omar Leyva,

Haroon Rasheed,

Elmira Baghdasaryan,

Simon S.M. Fung,

Deborah K. McCurdy,

Srinivas R Sadda,

Gary N. Holland

Ocular Inflammatory Disease Center, UCLA Stein Eye Institute (Drs. Tsui and Chen, Mr. Leyva, Drs. Fung and Holland) and the Department of Ophthalmology, David Geffen School of Medicine at UCLA, Los Angeles, CA (Drs. Tsui and Chen, Mssrs. Leyva and Rasheed, Drs. Baghdasaryan, Fung, Sadda, and Holland); the Division of General Internal Medicine and Health Services Research, Department of Medicine, David Geffen School of Medicine at UCLA, Los Angeles, CA (Dr. Jackson); the Doheny Eye Institute, Pasadena, CA (Drs. Baghdasaryan and Sadda); and the Department of Pediatrics, David Geffen School of Medicine at UCLA, Los Angeles, CA (Dr. McCurdy)..

### Abstract

**Purpose:** To evaluate the feasibility of anterior segment optical coherence tomography (AS-OCT) for measuring anterior chamber (AC) cells in children with uveitis and to compare different AS-OCT acquisition modes.

**Design:** Validity and reliability analysis.

---

Address correspondence to: Edmund Tsui, M.D., UCLA Stein Eye Institute, 100 Stein Plaza, Los Angeles, CA 90095-7000. [etsui@mednet.ucla.edu](mailto:etsui@mednet.ucla.edu).

**Publisher's Disclaimer:** This is a PDF file of an article that has undergone enhancements after acceptance, such as the addition of a cover page and metadata, and formatting for readability, but it is not yet the definitive version of record. This version will undergo additional copyediting, typesetting and review before it is published in its final form, but we are providing this version to give early visibility of the article. Please note that, during the production process, errors may be discovered which could affect the content, and all legal disclaimers that apply to the journal pertain.

#### Disclosures:

Tsui, EyePoint Pharmaceuticals (Watertown, MA), Kowa Company Ltd. (Nagoya, Japan), Cylite Pty Ltd. (Victoria, Australia); Chen, no financial disclosures; Jackson, no financial disclosures; Leyva, no financial disclosures; Rasheed, no financial disclosures; Baghdasaryan, no financial disclosures; Fung, Santen (Osaka, Japan), Daichii (Tokyo, Japan), Dompe (Milan, Italy); McCurdy, no financial disclosures; Sadda, Optos (Dunfermline, United Kingdom), Heidelberg (Heidelberg, Germany), Centervue (Padua, Italy), Carl Zeiss Meditec (Dublin, CA), Nidek (San Jose, CA), Topcon (Tokyo, Japan); Holland, no financial disclosures.

**Methods:** We enrolled children younger than 18 years of age who had uveitis involving the anterior segment and children without eye disease as controls. All underwent clinical grading of AC cells. AC images of each eye were obtained using the Optovue Avanti RTVue XR AS-OCT. Two acquisition modes were used: a single cross-sectional line scan and an 8-line radial scan in an asterisk pattern. Two independent, masked graders counted cells manually on AS-OCT images. Rater agreement was assessed using intraclass correlation (ICC).

**Results:** Included were 30 children (59 eyes) with uveitis (median age 13.0 years, range 3–17 years) and 20 control children (40 eyes, median age 10.5 years, range 4–17 years). The number of eyes assigned each clinical grade of cells were as follows: none, 32 (54%); 0.5+, 12 (20.3%); 1+, 5 (8.5%); 2+, 8 (13.6%); 3+, 2 (3.4%). ICC of graders for line and radial scan protocols were 0.87 and 0.90. There was no significant difference between acquisition modes for pooled grader results (95% confidence interval [CI] for difference: –0.04 to 0.14). ICC of cell counts between line and radial scan protocols was 0.85 (95% CI: 0.69–0.90). No control eyes had cells on AS-OCT images.

**Conclusions:** Quantification of AC cell in children with uveitis is feasible with AS-OCT and has excellent reliability between different graders and acquisition modes.

Classification of uveitis is by the primary anatomic location of intraocular inflammation, the most common category being anterior uveitis, involving the iris and anterior ciliary body.<sup>1</sup> Active anterior uveitis is recognized by the presence of cells (leukocytes) in the anterior chamber (AC) of the eye.<sup>2</sup> The amount of AC cells is used to guide treatment with local or systemic corticosteroids or with systemic immunosuppression.<sup>2</sup> Accurate quantification of cells is therefore critical in the management of anterior uveitis. Currently, the standard for determining the severity of an AC cellular reaction involves slit lamp biomicroscopy, during which the examiner assigns a semi-quantitative level to the amount of cells visualized in a 1 mm by 1 mm beam, as defined by the Standardization of Uveitis Nomenclature (SUN) Working Group.<sup>3</sup> This grading system is operator-dependent and requires patient cooperation. Even among uveitis specialists, there can be substantial variation in measurements using this system.<sup>4</sup> Accurate assessment of cells can be particularly difficult in children, especially among young children who may be uncooperative for slit lamp biomicroscopy.<sup>5</sup>

Children with uveitis represent a unique, at-risk population. They often have long disease courses, and children with chronic anterior uveitis are at high risk for ocular complications.<sup>5</sup> Children are often asymptomatic at disease onset, and during exacerbations of inflammation, they may not report any symptoms until vision-limiting complications, such as cataracts, glaucoma, or band keratopathy, occur;<sup>6–12</sup> thus, frequent monitoring of the AC plays a central role in long-term preservation of vision.<sup>13</sup> Children with uveitis may be evaluated by multiple clinicians who need to share clinical information, emphasizing the importance of accurate assessments.

To address the need for accurate and precise quantification of anterior segment inflammation, investigators have sought to develop objective image-based techniques to evaluate AC cells.<sup>14</sup> Anterior segment adaptor modules are available for multiple optical coherence tomography (OCT) platforms, which allows for high resolution imaging of

the anterior chamber which should make AS-OCT widely available to clinicians who see children with uveitis. Studies have shown that anterior segment OCT (AS-OCT) can quantify AC cells, based on the number of hyper-reflective dots in an AS-OCT image.<sup>15–18</sup> Results correlate strongly with the SUN grading criteria. Multiple studies have evaluated the use of AS-OCT for quantifying AC cells in adults; in contrast, studies of children with uveitis, the population for which such techniques would be particularly useful, are limited.<sup>19</sup> To understand the utility of AS-OCT for quantifying cells in children, investigations are needed that address the ability of children to cooperate sufficiently to detect cells consistently and reliably. One small, cross-sectional study suggested that use of AS-OCT for quantifying cells in children with uveitis was feasible, warranting additional studies.<sup>19</sup>

Although AS-OCT can identify AC cells, the quantification of cells by this technique has not been standardized.<sup>14</sup> Various studies have used different OCT platforms and varying protocols for image acquisition and processing, which limits the generalizability of individual reports. Before AS-OCT quantification of AC cell in children can be adopted widely in clinical practice, additional feasibility studies are needed, and a standardized approach must be developed. This study further evaluated the feasibility of AS-OCT for detecting AC cell in children of various ages who have anterior uveitis. It also compared different acquisition modes, to determine which mode is most suitable for children. Our ultimate goal is a more accurate and rapid, standard method for evaluating intraocular inflammation in children that can be used clinically.

## METHODS

Children less than 18 years of age with histories of uveitis involving the anterior segment were recruited from the practices of three uveitis specialists (ET, SSMF, GNH) at the UCLA Stein Eye Institute, University of California, Los Angeles. Not included were patients with histories of intraocular surgery during the 90 days immediately preceding recruitment. Patients were included whether or not uveitis was active at the time of the study. In addition, children without histories of intraocular inflammation, intraocular surgery, or ocular trauma were recruited as controls. The study was approved by the UCLA Health Institutional Review Board. Written informed consent was obtained from a parent of all study participants, and an additional assent document was signed by all study participants 7 years of age and older. The study adhered to the tenets of the Declaration of Helsinki.

### Data Acquisition

A comprehensive eye examination was performed on all study participants by one of three investigators (ET, SSMF, GNH), during which AC cells were scored using the SUN grading system.<sup>3</sup> Clinical grading was performed prior to AS-OCT imaging.

An experienced operator using the Optovue Avanti RTVue XR (Optovue, Inc., Fremont, CA) with the corneal adaptor module performed imaging on both eyes of all study participants. All AS-OCT images were acquired prior to pupillary dilation. AS-OCT scans were located in the central AC using two acquisition modes: a single 6 mm horizontal cross-sectional line B-scan and eight 6 mm cross-sectional line scans in a radial formation centered on the

corneal apex (schematic shown in Figure 1). If scans were unclear because of poor focus or artifact from motion or the corneal reflex, scans were repeated.

### Data Analysis and Statistical Techniques

AS-OCT B-scan images were de-identified and exported in JPEG format for manual assessment of AC cells. To assess inter-observer agreement, two independent graders (ET, JLC), who were masked to the clinical cells grades assigned to each eye, counted cells on all images from both children with uveitis and controls. Graders used the same definition of an AC cell that has been reported in previous AS-OCT studies: hyperreflective dots in the AC that are brighter than the background noise or greater than two pixels in size.<sup>19</sup> For the 8-line radial scan protocol, the mean number of cells for all eight images was calculated.

Agreement between the two masked graders within the single line and radial scans were assessed using intraclass correlation (ICC). ICC was also used to assess agreement between the single line and radial scans across raters. ICC differences between counts from the single line and radial scan protocols were evaluated using a bias-corrected bootstrap 95% confidence interval from 1,000 re-samplings. Linear regression analysis was used to compare AS-OCT cell counts to the clinically assigned SUN grades. Models were fit with clustered robust standard errors at the patient level. Statistical significance was defined as  $p < 0.05$ . All analyses were conducted in Stata version 16.1 (Stata Corp LP, College Station, TX).

## RESULTS

We enrolled 30 children with histories of uveitis (59 eyes) and 20 children without eye disease (40 eyes) as controls. Table 1 shows demographic and ophthalmic factors for study participants with uveitis and for controls. Figure 2 demonstrates representative AS-OCT images from line scans that correspond to each clinical grade of AC cells, as defined by the SUN Working Group.<sup>4</sup> All control eyes of children without eye disease were determined clinically to have no AC cells. No control eyes were found to have cells on AS-OCT images by the two masked graders.

Table 2 shows the mean cell counts, ranges, and mean differences corresponding to each clinical grade for the single line protocol and the radial scan protocol. The mean difference between the single line protocol and the radial scan protocol, regardless of clinical grade, was  $-0.9$  (95% CI  $-1.7, -0.1$ ). Figure 3 demonstrates the corresponding Bland-Altman plots for the two masked graders and their cell counts from the single line protocol (Figure 3A) and cell counts from the radial scan protocol (Figure 3B). Agreement between the graders for the single line scans (ICC 0.87) was not significantly different from the agreement between the graders for the 8 radial scan protocol (ICC 0.90; 95% confidence interval [CI] for the difference,  $-0.04$  to  $0.14$ ). Figure 4 shows a scatterplot demonstrating the mean number of cells counted on the single line scan protocol compared to the mean count for the 8 radial scan protocol (ICC 0.85, 95% CI 0.69 to 0.90).

Figure 5 shows box-and-whisker plots demonstrating the number of hyper-reflective foci in AS-OCT images corresponding to each level of clinical grades for the single line protocol

(Figure 5A) and for the radial scan protocol (Figure 5B). There was a significant association between mean counts on the AS-OCT scans and clinical grades for both the single line protocol and the radial scan protocol (both p values <0.001).

## DISCUSSION

Our study demonstrated that AS-OCT images obtained from children with uveitis are consistently of sufficient quality that results of manual cell counts are similar between independent, masked graders. We demonstrated that two common image acquisition modes (the single cross-sectional “line scan” and the 8-line “radial scan,” in an asterisk pattern) provided similar results in terms of cell numbers, especially for the clinically important lower cell grades. These results were significantly correlated with semi-quantitative anterior chamber cell categories (as defined by the SUN Working Group) that had been assigned to study eyes during slit lamp biomicroscopic examination by experienced uveitis specialists. We were able to image children as young as 3 years of age successfully. No child younger than 3 years of age was enrolled in the study.

The use of AS-OCT to evaluate intraocular inflammation will be particularly useful in the pediatric population. Patients with chronic anterior uveitis, as seen with JIA, may be examined as frequently as every 1–2 weeks during periods of increased intraocular inflammation, and will likely be examined at least every 3 months during periods of disease quiescence to monitor for symptomatic reactivation.<sup>13</sup> Children often do not cooperate fully with slit lamp biomicroscopic examinations, because of the prolonged time required for clinical assessment of cell at the brightest illumination of the slit beam, as recommended by the SUN Working Group,<sup>3, 5</sup> yet it is critical that inflammation be detected early, accurately, and precisely, to guide treatment and prevent vision loss. The illumination required for image acquisition with AS-OCT is considerably lower than the highest illumination setting on the slit lamp biomicroscope, thus facilitating assessment of anterior chamber cells in children who are photosensitive. Additional advantages to an image-based assessment of AC cell include the ability for post-acquisition image analysis and the future development of automated algorithms using these data. Image-based assessment may also permit longitudinal comparisons across different clinical settings and between multiple clinicians.

Several studies have described use of AS-OCT for assessment of anterior chamber cells in adults, but there has only been one report describing use of AS-OCT to assess cells in children with uveitis. Akbarali and associates investigated the feasibility of 8 cross-sectional AS-OCT scans in an asterisk formation for detecting cells in children as young as 3 years of age, using the Optovue AS-OCT.<sup>19</sup> They compared scan results to biomicroscopic assessment, and found a positive correlation ( $r = 0.63$ ,  $P=0.002$ ) with SUN categories. They reported a median image acquisition time of 8 minutes (range 1.5–22 minutes) to acquire the 8 cross-sectional images from both eyes. Our study did not evaluate the time taken to obtain scans, but a single line scan is inherently faster than 8 scans, especially in the absence of eye tracking. Manufacturer specifications for a single cross-sectional line scan is 0.23 seconds and for the eight-line radial scan is 0.89 seconds (personal communication, Peter Naismith (Senior Director of Product Strategy, Optovue, Inc., Fremont, CA, January

25, 2021). The shorter duration of the single line scan may also minimize artifacts caused by micromovements of the eye. Because AS-OCT scans do not have eye tracking, children must refrain from blinking for the duration of the scan.

Despite the advantage of shorter data acquisition time, a single line scan potentially could result in under- or over-counting of cells, as cells move freely within the AC. To begin addressing the advantages and disadvantages of different imaging modes, we found that the single line scan provided statistically similar results to the 8-line radial scan. A single B-scan through the central AC may therefore be representative of inflammation throughout the AC. It would be analogous to the single 1 × 1 mm slit beam used to categorize cells in the SUN grading system.<sup>3</sup>

SUN categories have been the “gold standard” for assessing the severity of anterior segment inflammation in both clinical practice and research. A systematic review by Liu and associates demonstrated that AC cell count by AS-OCT has achieved strong correlations with clinician grading in multiple studies.<sup>14</sup> Although cell counts from AS-OCT scans were correlated with SUN categories in both our study of children and the study of children by Akbarali and associates, that relationship should not be the ultimate goal in use of AS-OCT to assess intraocular inflammation. Each SUN category includes a range of cell numbers and there is no linear or other mathematical progression between categories. Most children with chronic anterior uveitis have <2+ cells by SUN criteria, limiting assessment of small changes in anterior chamber cell concentrations. AS-OCT assessment promises greater precision of measurement within these categories. Studies have shown that SUN categories have prognostic relevance,<sup>8</sup> but it is likely that more precise and reproducible measurements will offer even more information relevant to the course of disease. Validation against clinically relevant outcome measures will be required to confirm that assumption. Greater precision will also be important for clinical trials, which usually require a 2-step decrease in SUN categories to confirm a treatment effect, which makes it impossible to achieve that end-point in children who have 1+ cells on clinical evaluation (a level still considered to be a risk factor for adverse events). Our study also demonstrated that the two acquisition modes have the greatest agreement in patients with lower levels of inflammation (those with 1+ cells or less). Agreement at this level is particularly important, as the majority of children at presentation will have low-to-moderate inflammation (a SUN grade of 1+ cells) rather than 2+ or greater AC cells.<sup>8</sup> Again, validation studies will be required to determine the amount of change identified by AS-OCT images that predicts beneficial treatment effects and whether the potential differences in cell numbers between acquisition modes at higher grades are clinically relevant.

Imaging with AS-OCT also has the potential to detect subclinical inflammation. Eyes with a history of uveitis that appeared to have no AC cells on clinical examination in our study were found to have cells on AS-OCT imaging, with a mean of  $0.17 \pm 0.7$  cells on a single line scan. Multiple AS-OCT studies have found even higher cell ranges with AS-OCT imaging of eyes judged clinically to be quiet. In studies by Akbarali and associates<sup>19</sup> and Sharma and associates<sup>15</sup> using a similar Optovue AS-OCT platform, AS-OCT reliably detected cells in eyes without clinical detection of cells. These findings suggest that there may be subclinical inflammation in “quiet” eyes, but its clinical relevance is unknown.



There remains considerable variation in acquisition techniques among those studying the use of AS-OCT to count anterior chamber cells; they include line scans, radial scans, and volume scans. Volume scans image more of the AC than the other techniques, and possibly reveal more cells in the AC (particularly the inferior AC), which may be missed with slit lamp examination.<sup>20</sup> There has also been substantial variation in the size of the area scanned, levels of automation (manual, semi-automated, or fully automated), and use of algorithms that are not generally available through open-access.<sup>14</sup> In addition, multiple AS-OCT platforms have been used to image AC cells; they include the commercially available Optovue spectral-domain AS-OCT platform, which is similar to the one used in our study,<sup>15, 19</sup> and swept-source AS-OCT platforms,<sup>16, 18</sup> not all of which are commercially available. The latter are also more expensive than spectral-domain platforms. Additional studies that evaluate consistency across different platforms and lead to establishment of cross-platform standardization are needed.

A limitation of our study is its small sample size, and the fact that we had few eyes at the highest SUN categories of inflammation, which may have influenced the precision with which we were able to assess differences between acquisition modes at various levels. Our study is also limited by the small number of children at the lower end of our age range; nevertheless, we successfully imaged 3 children under 5 years of age, indicating that the technique can be used with very young children. A larger sample size of children in this age range will be needed to confirm this conclusion. Use of AS-OCT will not eliminate the need to perform slit lamp biomicroscopy to monitor for uveitic complications in the anterior segment and on the ocular surface, but that examination will be substantially shorter, and require less cooperation, than a clinical assessment of cell level. We have not found that children are uncooperative for AS-OCT after examination at the slit lamp biomicroscope. Additional experience will indicate whether two short examinations with two different devices will reduce or enhance a child's overall cooperation level during a clinic visit when compared to a single, longer session at the slit lamp biomicroscope. Poor cooperation often reflects a short attention span in young children, and thus, shorter sessions at multiple devices may enhance the success of a clinic visit.

Our study was cross-sectional and we therefore do not know how each acquisition mode performs over time. We plan to continue studying the utility of AS-OCT in longitudinal assessments of children with uveitis during periods of disease quiescence and active inflammation. Such studies will help to determine relevant thresholds of inflammatory activity that predict development of adverse events, including uveitic complications and vision loss. We will also compare test-retest reproducibility in each acquisition technique by repeating imaging on the same day. It is possible that the more detailed radial technique will be more appropriate for selected children, based on such studies. Our study describes agreement between techniques on a population basis, but there was some variation between results for the two techniques among individuals. Future studies will investigate host and disease factors that might influence these variations. Our technique is also limited by its inability to identify the nature of particulate matter in the anterior chamber. Future studies may identify characteristics that distinguish between white blood cells, pigment, or other particulate matter.



In summary, our study has begun to address obstacles to the use of AS-OCT for assessment of intraocular inflammation in children. As a step toward standardization, we evaluated two modes of data acquisition and found that the single line scan may be as useful as an 8-line radial scan. Single line scans may be a more suitable option for children, given the relative speed of image acquisition. We have also discussed the need for additional studies to standardize the use of AS-OCT and to validate measurements clinically. Automated and standardized algorithms for detecting and counting cells on AS-OCT images will make this technique more practical. We envision the eventual incorporation of objective image-based measurements of intraocular inflammation into routine clinical practice and as endpoints in clinical trials and other clinical research studies.

A prospective study evaluating the utility of anterior segment optical coherence tomography (AS-OCT) in the quantification of anterior chamber cells of 59 eyes of 30 children with uveitis found that this technique was feasible and can successfully detect cells. There was excellent reliability between masked graders in counting cells in AS-OCT images and between two different AS-OCT acquisition modes. AS-OCT may eventually be incorporated into the assessment of intraocular inflammation in children.

## ACKNOWLEDGEMENTS

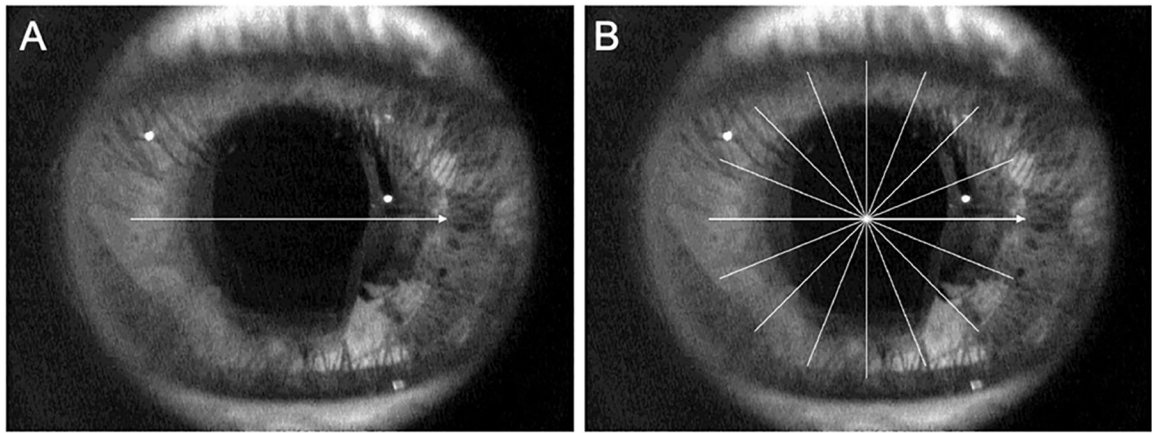
### Financial Support:

This work was supported by grants from the Knights Templar Eye Foundation (E.T.); the Thrasher Research Fund (E.T.); and the National Eye Institute of the National Institutes of Health under award number K23EY032990 (E.T.). The content is solely the responsibility of the authors and does not necessarily represent the official views of the National Institutes of Health.; the Skirball Foundation, New York, NY (G.N.H.); and an unrestricted grant from Research to Prevent Blindness, Inc. (New York, NY) to the UCLA Stein Eye Institute for research. The funding organizations had no role in the design or conduction of the study.

## REFERENCES

1. McCannel CA, Holland GN, Helm CJ, et al. Causes of uveitis in the general practice of ophthalmology. UCLA Community-Based Uveitis Study Group. *Am J Ophthalmol* 1996;121(1):35–46. [PubMed: 8554079]
2. Jabs DA. Immunosuppression for the Uveitides. *Ophthalmology* 2018;125(2):193–202. [PubMed: 28942074]
3. Jabs DA, Nussenblatt RB, Rosenbaum JT, Standardization of Uveitis Nomenclature Working G. Standardization of uveitis nomenclature for reporting clinical data. Results of the First International Workshop. *Am J Ophthalmol* 2005;140(3):509–16. [PubMed: 16196117]
4. Kempen JH, Ganesh SK, Sangwan VS, Rathinam SR. Interobserver agreement in grading activity and site of inflammation in eyes of patients with uveitis. *Am J Ophthalmol* 2008;146(6):813–8 e1. [PubMed: 18687418]
5. Holland GN, Stiehm ER. Special considerations in the evaluation and management of uveitis in children. *Am J Ophthalmol* 2003;135(6):867–78. [PubMed: 12788128]
6. Davis JL, Dacanay LM, Holland GN, et al. Laser flare photometry and complications of chronic uveitis in children. *Am J Ophthalmol* 2003;135(6):763–71. [PubMed: 12788114]
7. Holland GN. A reconsideration of anterior chamber flare and its clinical relevance for children with chronic anterior uveitis (an American Ophthalmological Society thesis). *Trans Am Ophthalmol Soc* 2007;105:344–64. [PubMed: 18427621]
8. Holland GN, Denove CS, Yu F. Chronic anterior uveitis in children: clinical characteristics and complications. *Am J Ophthalmol* 2009;147(4):667–78 e5. [PubMed: 19195641]

9. Chia A, Lee V, Graham EM, Edelsten C. Factors related to severe uveitis at diagnosis in children with juvenile idiopathic arthritis in a screening program. *Am J Ophthalmol* 2003;135(6):757–62. [PubMed: 12788113]
10. Edelsten C, Reddy MA, Stanford MR, Graham EM. Visual loss associated with pediatric uveitis in english primary and referral centers. *Am J Ophthalmol* 2003;135(5):676–80. [PubMed: 12719076]
11. Sijssens KM, Rothova A, Berendschot TT, de Boer JH. Ocular hypertension and secondary glaucoma in children with uveitis. *Ophthalmology* 2006;113(5):853–9 e2. [PubMed: 16650683]
12. Oray M, Khachatryan N, Ebrahimiadib N, et al. Ocular morbidities of juvenile idiopathic arthritis-associated uveitis in adulthood: results from a tertiary center study. *Graefes Arch Clin Exp Ophthalmol* 2016;254(9):1841–9. [PubMed: 27084082]
13. Angeles-Han ST, Ringold S, Beukelman T, et al. 2019 American College of Rheumatology/Arthritis Foundation Guideline for the Screening, Monitoring, and Treatment of Juvenile Idiopathic Arthritis-Associated Uveitis. *Arthritis Care Res (Hoboken)* 2019;71(6):703–16. [PubMed: 31021540]
14. Liu X, Solebo AL, Faes L, et al. Instrument-based Tests for Measuring Anterior Chamber Cells in Uveitis: A Systematic Review. *Ocul Immunol Inflamm* 2020;28(6):898–907.
15. Sharma S, Lowder CY, Vasani A, et al. Automated Analysis of Anterior Chamber Inflammation by Spectral-Domain Optical Coherence Tomography. *Ophthalmology* 2015;122(7):1464–70. [PubMed: 25846846]
16. Baghdasaryan E, Tepelus TC, Marion KM, et al. Analysis of ocular inflammation in anterior chamber-involving uveitis using swept-source anterior segment OCT. *Int Ophthalmol* 2019;39(8):1793–801. [PubMed: 30238391]
17. Invernizzi A, Marchi S, Aldigeri R, et al. Objective Quantification of Anterior Chamber Inflammation: Measuring Cells and Flare by Anterior Segment Optical Coherence Tomography. *Ophthalmology* 2017;124(11):1670–7. [PubMed: 28625685]
18. Lu M, Wang X, Lei L, et al. Quantitative Analysis of Anterior Chamber Inflammation Using the Novel CASIA2 Optical Coherence Tomography. *Am J Ophthalmol* 2020;216:59–68. [PubMed: 32251654]
19. Akbarali S, Rahi JS, Dick AD, et al. Imaging based uveitis surveillance in juvenile idiopathic arthritis: feasibility, acceptability and diagnostic performance. *Arthritis Rheumatol* 2020.
20. Li Y, Lowder C, Zhang X, Huang D. Anterior chamber cell grading by optical coherence tomography. *Invest Ophthalmol Vis Sci* 2013;54(1):258–65. [PubMed: 23249705]



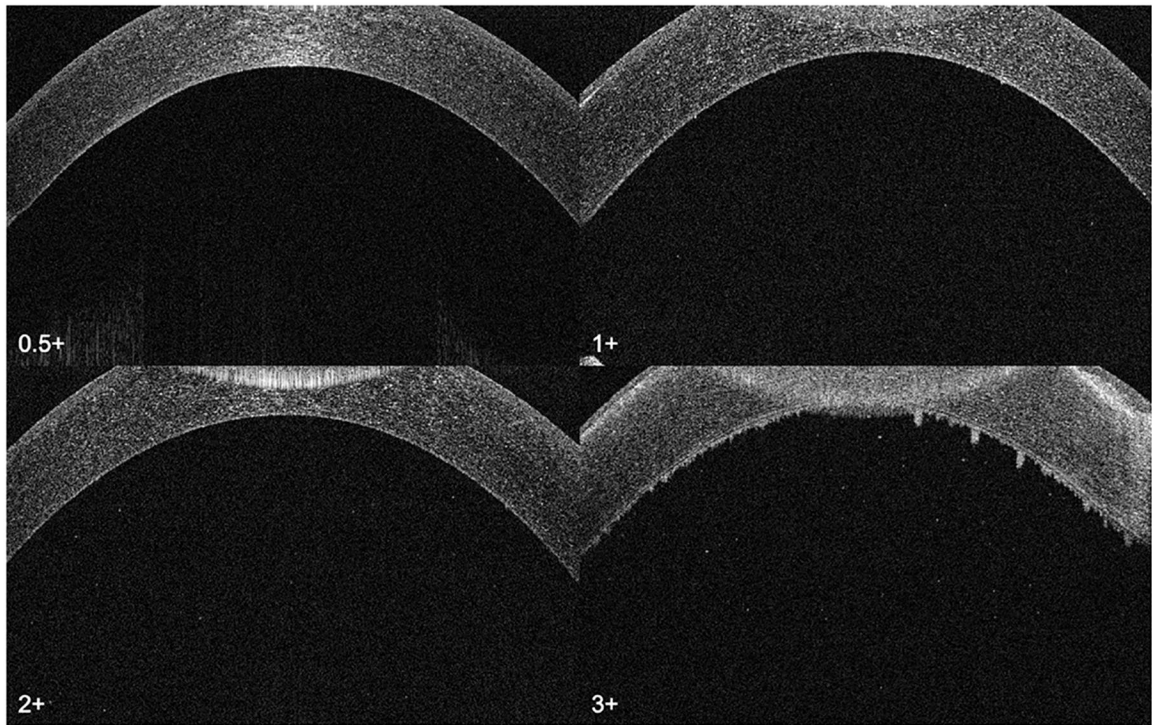
**Figure 1.** Schematic of a single cross-sectional line AS-OCT scan (A) through the central anterior chamber compared to the eight-line radial scans (B).

Author Manuscript

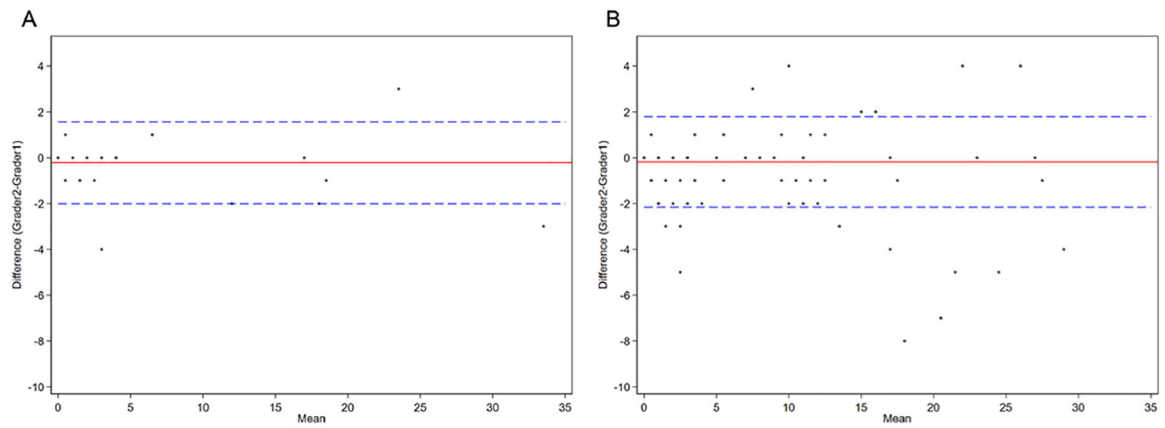
Author Manuscript

Author Manuscript

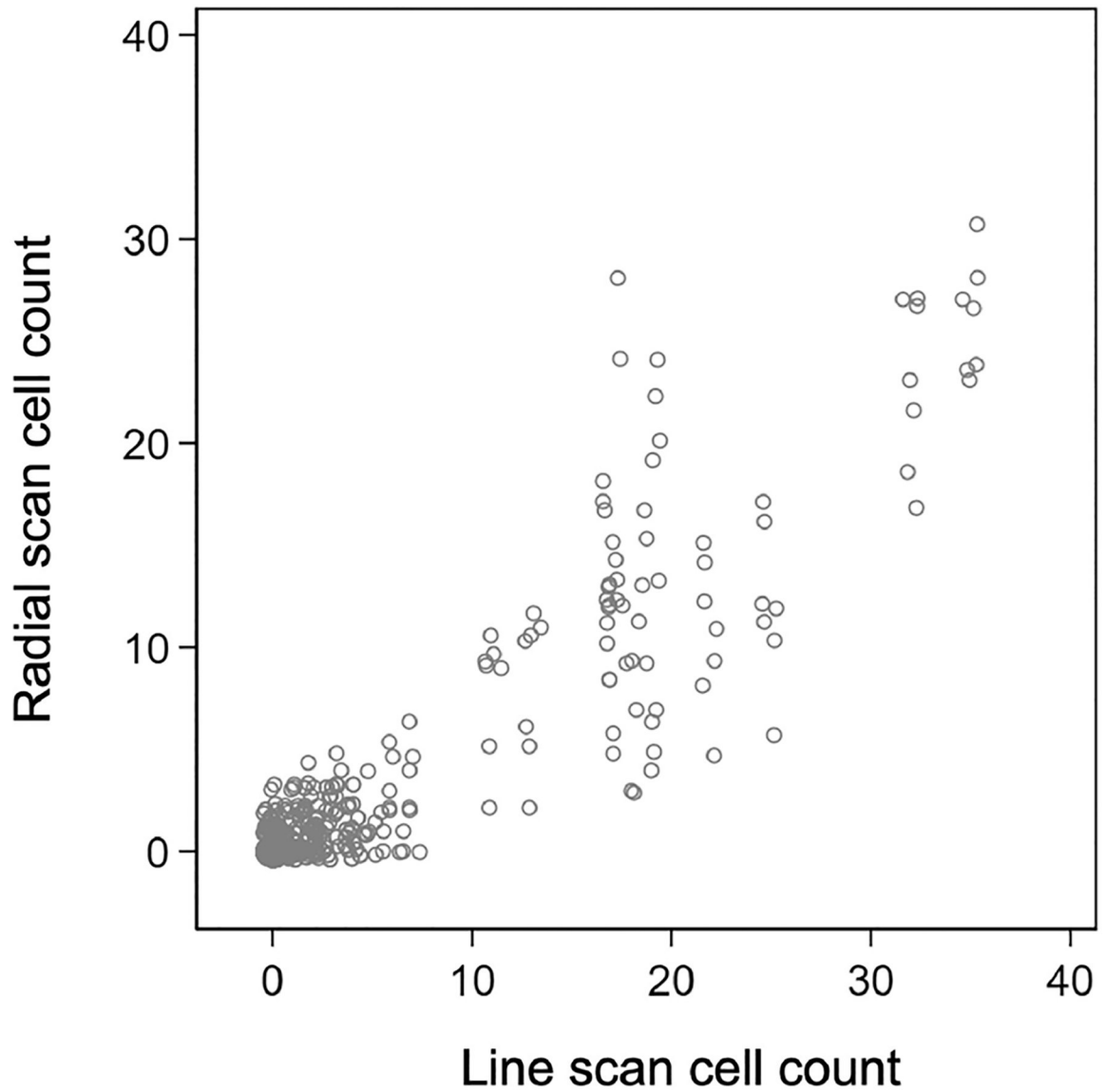
Author Manuscript



**Figure 2.** Representative images of AS-OCT single line scans through the central anterior chamber from grades 0 to 3+ using the Standardization of Uveitis Nomenclature (SUN) Working Group criteria. Hyperreflective foci represent cells in the anterior chamber.

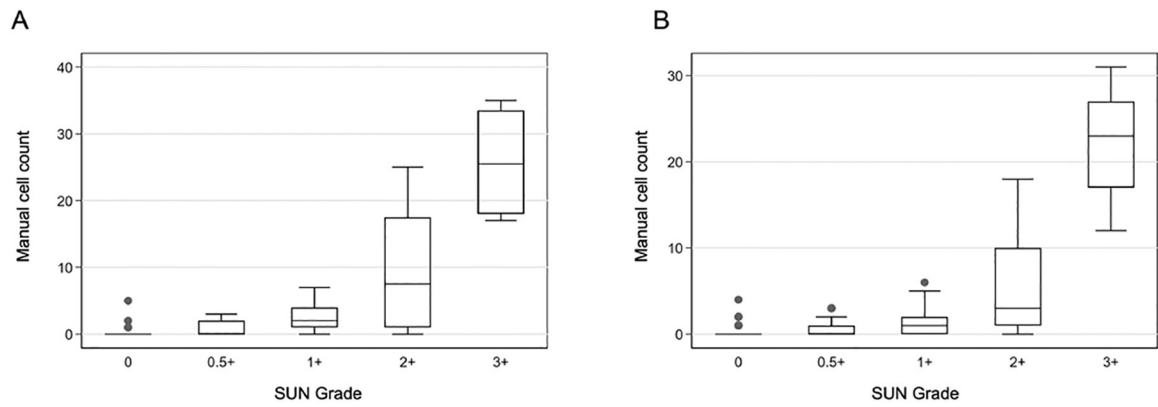


**Figure 3.** Bland-Altman plot showing the difference in cell counts between Grader 1 and Grader 2 for single line scans (A) and 8-line radial scans (B). The solid red lines show the mean difference. The dotted blue line shows 95% limits of agreement ( $\pm 1.96$  standard deviations).



**Figure 4.**

Scatterplot demonstrating the number of cells for the AS-OCT 8-line radial scans compared to single line scans. The intraclass correlation between 8-line radial scans and single line scans was 0.85 (95% confidence interval of 0.69 to 0.90). Note that “jitter” was added to the scatterplot display to avoid overlapping dots, thereby demonstrating more effectively the distribution of all data points. As a result, the 8 dots from the radial technique for individual study participants are not in perfect vertical alignment.



**Figure 5.**

Box and whisker plots demonstrating the number of hyperreflective foci that were counted in AS-OCT (A) single line scans and (B) 8-line radial scans. Lines inside the box represent medians. The lines of the box represent the first and third quartiles. Both single line scans and 8-line radial scans were significantly correlated with SUN grades with  $p < 0.001$  for both imaging modes. SUN: Standardization of Uveitis Nomenclature.



**Table 1.**

Demographic and Ophthalmic Factors of 30 Children with Uveitis involving the Anterior Segments (59 Eyes) and 20 Control Children without Eye Disease who Underwent Anterior Segment Optical Coherence Tomographic Imaging.

Factor	Children with Uveitis		Controls	
	Individuals (n=30)	Eyes (n=59)	Individuals (n=20)	Eyes (n=40)
Age (years)				
Mean $\pm$ SD	12.1 $\pm$ 3.7		10.9 $\pm$ 3.9	
Median (range)	13.0 (3 – 17)		(4 – 17)	
IQR	10.3 – 15.0		7.8 – 14	
Median (IQR)	13.0 (10.3 – 15.0)	-	10.5 (7.8 – 14)	-
Range	3 – 17	-	4 – 17	-
Sex				
Male	11	-	9	-
Female	19	-	11	-
Diagnosis of uveitis (n, [%])	-	-	-	-
No uveitis			20 (100)	40 (100)
Idiopathic anterior uveitis	7 (23.3)	14 (23.7)	-	-
Idiopathic anterior and intermediate uveitis	3 (10.0)	6 (10.2)	-	-
Idiopathic panuveitis	6 (20.0)	12 (20.3)	-	-
JIA-associated uveitis	11 (36.7)	22 (37.3)	-	-
HZO-associated anterior uveitis	1 (3.3)	1 (1.7)	-	-
Blau syndrome <sup>a</sup>	1 (3.3)	2 (3.4)	-	-
Tubulointerstitial nephritis and uveitis syndrome	1 (3.3)	2 (3.4)	-	-
Clinical grade of cells <sup>b</sup> (n, [%])				
None	-	32 (54.2)	20 (100)	40 (100)
0.5+	-	12 (20.3)	-	-
1+	-	5 (8.5)	-	-
2+	-	8 (13.6)	-	-
3+	-	2 (3.4)	-	-

HZO = herpes zoster ophthalmicus; IQR= interquartile range; JIA = juvenile idiopathic uveitis; SD = standard deviation

<sup>a</sup>The patient with Blau syndrome had panuveitis in both eyes.

<sup>b</sup>Based on the Standardization of Uveitis Nomenclature grading system.<sup>4</sup> Grades were assigned by one of three uveitis experts (ET, SMMF, GNH). No eye was assigned a grade of 4+.

**Table 2.**

Mean Number of Cells on AS-OCT Images by Manual Counting in Two Data Acquisition Protocols for 59 Eyes of 30 Children with Uveitis Involving the Anterior Segments.

Clinical Grade of Cells <sup>a</sup>	Single Line Protocol <sup>b</sup> Mean ± SD	Radial Protocol <sup>b,c</sup> Mean ± SD	Mean Difference (95% Confidence Interval)
None (n=32)	0.17 ± 0.7	0.11 ± 0.4	-0.06 (-0.21, 0.09)
0.5+ (n=12)	0.88 ± 1.2	0.49 ± 0.9	-0.38 (-0.98, 0.21)
1+ (n=5)	2.9 ± 2.3	1.4 ± 1.5	-1.5 (-3.9, 0.9)
2+ (n=8)	9.7 ± 8.9	5.5 ± 5.0	-4.2 (-10.2, 1.8)
3+ (n=2)	25.8 ± 9.1	22.0 ± 5.1	-3.8 (-10.0, 2.5)

<sup>a</sup>Based on the Standardization of Uveitis Nomenclature grading system.<sup>4</sup> Grades were assigned by one of three uveitis experts (ET, SMMF, GNH). No eye was assigned a grade of 4+.

<sup>b</sup>Mean ± standard deviation, based on identification of hyper-reflective foci in the anterior chambers of each line scan. Counts represent the average of counts determined by two independent masked evaluators. There was no significant difference in rater reliability between acquisition modes (95% confidence interval for difference: -0.04 to 0.14), as determined by intraclass correlation (ICC). ICC differences between counts were evaluated using a bias-corrected bootstrap 95% confidence interval from 1,000 re-samplings.

<sup>c</sup>The protocol includes 8 radial line scans. The mean is calculated from a summation of the counts assigned to all line scans.