

UCLA

UCLA Previously Published Works

Title

Progressive B Cell Loss in Revertant X-SCID

Permalink

<https://escholarship.org/uc/item/9m03h1hd>

Journal

Journal of Clinical Immunology, 40(7)

ISSN

0271-9142

Authors

Lin, Connie H
Kuehn, Hye Sun
Thauland, Timothy J
[et al.](#)

Publication Date

2020-10-01

DOI

10.1007/s10875-020-00825-3

Peer reviewed



Published in final edited form as:

J Clin Immunol. 2020 October ; 40(7): 1001–1009. doi:10.1007/s10875-020-00825-3.

Progressive B-cell loss in revertant X-SCID

Connie H. Lin¹, Hye Sun Kuehn², Timothy J. Thauland¹, Christine M. Lee³, Suk See DeRavin⁴, Harry L. Malech⁴, Timothy J. Keyes⁵, Astraea Jager⁵, Kara L. Davis⁵, Maria I. Garcia-Lloret¹, Sergio D. Rosenzweig², Manish J. Butte¹

¹University of California Los Angeles, Department of Pediatrics, Division of Immunology, Allergy, and Rheumatology, Los Angeles, CA 90095

²Immunology Service, Department of Laboratory Medicine, Clinical Center, NIH, Bethesda, MD

³University of California Los Angeles, Department of Pathology, Los Angeles, CA 90095

⁴National Institutes of Health, NIAID, Laboratory of Clinical Immunology and Microbiology, Bethesda, MD

⁵Stanford University, Department of Pediatrics, Division of Stem Cell and Regenerative Medicine, Stanford CA 90435

Abstract

We report the case of a patient with X-linked Severe Combined Immunodeficiency (X-SCID) who survived for over 20 years without hematopoietic stem cell transplantation (HSCT) because of a somatic mutation reversion. An important feature of this rare case included the strategy to validate the pathogenicity of a variant of the *IL2RG* gene when the T and B cell lineages comprised only revertant cells. We studied X-inactivation of sorted T cells from the mother to show the pathogenic variant was indeed the cause of his SCID. One interesting feature was a progressive loss of B cells over 20 years. CyTOF (cytometry time of flight) analysis of bone marrow offered a potential explanation of the B cell failure, with expansions of progenitor populations that suggest a developmental block. Another interesting feature was that the patient bore extensive granulomatous disease and skin cancers that contained T cells, despite severe T-cell lymphopenia in the blood. Finally, the patient had a few hundred T cells on presentation but his TCRs comprised a very limited repertoire, supporting the important conclusion that repertoire size trumps numbers of T cells.

Terms of use and reuse: academic research for non-commercial purposes, see here for full terms. <http://www.springer.com/gb/open-access/authors-rights/aam-terms-v1>

Author Contributions

CHL, SSD, HLM, MIG-L, and MJB provided patient care. MJB obtained IRB approval. CML prepared histology images. TJK, AJ, and KLD performed CyTOF studies. HSK and SDR performed cytokine studies. CHL, MIG-L, and MJB wrote the manuscript.

Conflict of Interest

We confirm that there are no known conflicts of interest relevant to this publication, and there has been no significant financial support for this work that could have influenced its outcome

Publisher's Disclaimer: This Author Accepted Manuscript is a PDF file of a an unedited peer-reviewed manuscript that has been accepted for publication but has not been copyedited or corrected. The official version of record that is published in the journal is kept up to date and so may therefore differ from this version.

Keywords

SCID; IL2RG; somatic reversion; B cells; T cells

INTRODUCTION

X-SCID is a disorder characterized by pathogenic variants affecting the *IL2RG* gene, which encodes the common gamma chain (γ_c) protein, also known as CD132 [1]. It is one of the most common genetic causes of SCID, accounting for about 30% of cases [2]. In this disorder, the developing immune system cannot appropriately respond to cytokines that signal through the γ_c chain: IL-2, IL-4, IL-7, IL-9, IL-15, and IL-21. The result is a characteristic phenotype lacking T cells and NK cells but often with B cells present. Without allogeneic hematopoietic stem cell transplantation (HSCT) or gene therapy, X-SCID is thought to be uniformly fatal. However, several cases of revertant mutations have been described in X-SCID patients who demonstrate a milder clinical phenotype than the classic presentation. Reversion mosaicism has been described in a variety of disorders, including other primary immunodeficiencies including NEMO (gene name *IKBKG*), Wiskott-Aldrich Syndrome (*WAS*), X-linked lymphoproliferative disease (*SH2D1A*), Leukocyte adhesion deficiency type 1 (*CD18*), SCID and Omenn syndrome (*RAG1*), Adenosine deaminase deficiency (*ADA*), and CD3-zeta deficiency (*CD247*) [3].

This case report demonstrates new features of reversion mosaicism in X-linked SCID not reported in previous cases. We review our case in light of previous revertant cases that have been reported. Some cases include reversion of T cells only while others showed rescue of T and B cells, suggesting that the reversion can arise at the level of the common lymphoid progenitor cell. To study the progressive loss of B cells, we examined the role of γ_c signaling in the revertant bone marrow stem and progenitor cells.

METHODS

Subjects

All research on human subjects was performed after written informed consent was obtained for protocols approved by the IRBs of the University of California Los Angeles and the National Institutes of Health.

Flow cytometry

Peripheral blood mononuclear cells were stained for T cells (CD3, CD4, and CD8) or B cell markers (CD19 and CD27) and for CD132 (γ_c). Antibodies were obtained from BioLegend or BD.

Measurement of STAT phosphorylation

Signaling of common-gamma chain dependent cytokines was studied on CD4⁺ T cells and CD19⁺ CD20⁺ B cells. PBMCs were either left unstimulated or stimulated with the following cytokines: IL-2 (10 ng/mL), IL-4 (10 ng/mL), IL-7 (10 ng/mL), IL-15 (50 ng/mL), and IL-21 (50 ng/mL) for 20 min at 37 °C. The cytokines were purchased from PeproTech

(Rocky Hill, NJ) or Invitrogen (for IL-15, Waltham, MA). Cells were stained with CD4APC or CD19-APC and CD20-PECy7 for gating on cell population. Cells were fixed with BD Cytotfix Fixation Buffer for 15 min at 37 °C, and then permeabilized with BD Phosflow Perm Buffer III for 30 min on ice, respectively. For flow cytometry, the following monoclonal antibodies for phospho-STAT were used from BD Biosciences (La Jolla, CA): p-STAT3 [Y705], p-STAT5 [Y694], and p-STAT6 [Y641]. The stained cells were measured by flow cytometry on a BD FACSCanto II instrument. All FACS analyses were performed using FlowJo (Treestar).

CyTOF

To assess the patient's B-cell phenotype, his bone marrow was analyzed and compared to age-matched, healthy-donor controls (All Cells, Inc.) using mass cytometry as previously described [4]. Briefly, viably-frozen bone marrow cells were thawed in 90% RPMI medium (ThermoFisher Scientific) with 10% FBS supplemented with 20 units/mL of sodium heparin (SigmaAldrich), 0.025 units/mL Benzodase (Sigma-Aldrich), L-glutamine/penicillin-streptomycin (Invitrogen). After thawing, cells were rested at 37 °C for 30 min, stained for viability with cisplatin, and stimulated for 15 min with IL-7 (20 ng/mL; BD Biosciences). Cells were then immediately fixed for 10 min with 1.6% paraformaldehyde at room temperature, washed, and incubated for 30 min at room temperature with antibodies to surface markers (Table 1). After washing, cells were then permeabilized with methanol for 10 min at 4 °C prior to staining with intracellular marker- and phospho-specific antibodies for 30 min at room temperature (Table 1). Finally, cells were washed and stained with ¹⁹¹Ir/¹⁹³Ir DNA intercalator (Fluidigm), washed, filtered, and suspended in ¹³⁹La/¹⁴²Pr/¹⁵⁹Tb/¹⁶⁹Tm/¹⁷⁵Lu normalization beads before analysis using a Helios mass cytometer (Fluidigm). Data were normalized using standard bead normalization and single-cell protein expression data were extracted using CyTOF software, yielding approximately 250,000 events per patient for analysis. All analysis was performed using Cytobank (Fluidigm) and R software (CRAN). Progenitor and B cell populations in bone marrow were gated similarly as published [5].

X-inactivation

Studies were performed on the mother's blood clinically through the Center for Human Genetics (Cambridge, MA). We started with the *HUMARA* gene but found that both sets of CAG short tandem repeats were identical in whole blood, which occurs in ~5% of individuals. We successfully analyzed X-inactivation with the *PCSKIN* gene, which also contains variable repeats [6].

Exome sequencing

Whole exome sequencing was performed clinically in the UCLA Clinical Exome Service using the Agilent SureSelect Clinical Research Exome capture kit and sequenced on Illumina sequencers.

TCR Vβ

Studied were performed clinically at ARUP by flow cytometry.

RESULTS

CASE PRESENTATION

A male child was born at 42 weeks gestational age to non-consanguineous parents without perinatal complications. He was the only child of this union. Around one year of age, he developed a papular rash on his face and body, confirmed to be granulomata by biopsy. At ~2 years of age, he developed chronic diarrhea, failure to thrive, and thrush. Workup for infection, celiac disease, and malabsorption was unrevealing. At age 2.5, his lymphocytes showed a significant deficiency of T and NK cells and poor proliferation in response to mitogens (Table 1). Based on these findings, a diagnosis of atypical SCID was made and meeting criteria for leaky SCID in modern parlance [7]. He was started on replacement immunoglobulin. The option of HSCT was discussed with the family, but they declined and the patient was lost to follow-up

During the following years, the patient was treated with a number of vitamins, nutritional supplements, minerals, and herbal medications. His health improved after age 3–4. Despite being off immunoglobulin therapy, he regained weight, his rashes disappeared, and his physical and cognitive development were normal for age. He did not receive any live virus vaccines. As he neared adolescence, his health problems resurfaced. At age 11, he developed chronic diarrhea due to *Giardia* infection. At around age 13, he started to develop a violaceous, papular rash and several skin superinfections. Around age 17, he developed chronic diarrhea due to norovirus

At age 18, he re-presented to our institution for ongoing dermatological concerns including cutaneous granulomas, global flat wart infection, and squamous cell carcinoma [8]. His T cell count remained low (Table 1). Whole-exome sequencing was undertaken, which showed a hemizygous missense variant at chrX:g.70330145 (hg19), NM_000206.2:c.455T>C, which codes for the change p.Val152Ala in the *IL2RG* gene. This variant was inherited from his mother, who was asymptomatic. This variant was assumed to be pathogenic because it had been reported in a patient with low T and NK cells and supra-normal numbers of B cells [9,10]. Our patient was given the diagnosis of atypical X-SCID, started on immunoglobulin replacement, given prophylaxis for *Pneumocystis*, and presented the option of allogeneic HSCT. Patient declined transplantation and was again lost to follow-up

Four years later, the patient re-presented with significant interval deterioration in status. He had developed chronic enteropathy, complicated by large bowel perforation requiring surgical resection and a colostomy, severe failure to thrive and cachexia (body mass index ~15), worsening dermatitis, and recurrent skin and sinopulmonary infections. In addition, he had frequent swelling of the knees and of the soft tissues of his lower extremities (Fig. 1A). Based on his ill appearance, he was admitted for inpatient management of pneumonia, enteropathy with norovirus genotype 2 diarrhea, malnutrition, and recurrent fever. His T cell counts remained low and NK and B cells were virtually absent (Table 1). Proliferation testing showed low responses to anti-CD3 but excellent augmentation with the addition of IL-7 or IL-15. A bone marrow biopsy showed hypocellularity (50%) and multiple aggregates of epithelioid histiocytes and a few well-formed granulomas.

Over the subsequent year, granulomatous disease affected his liver and lung as well. An immunosuppressive strategy was escalated eventually entailing use of alemtuzumab (anti-CD52), resulting in ablation of almost all circulating lymphocytes, which recovered over 2–3 months. B cells remained low from 0–0.4%. There was an attempt to harvest bone marrow or mobilized peripheral blood stem cells for *IL2RG* gene therapy, but the yield was too low, precluding this intervention. The patient refused conventional HSCT.

Subsequently, the patient demonstrated progressive cholestatic disease with bilirubin levels over 30 mg/dL (60+% conjugated), with no focal blockage noted on imaging and nodular regenerative hyperplasia noted on hepatic biopsy. After an episode of severe sepsis due to *Serratia*, he suffered end-organ injury of bone marrow, liver, kidneys, and heart. Despite surviving the acute infection, the injury to these organs was progressive and led to his death at age 24.

REVERSION IN T CELLS

Given the presence of T cells in peripheral blood, erythematous rash, and enteropathy at age 22, we questioned whether his symptoms could be due to allogeneic engraftment (either maternal or from an un-irradiated blood transfusion) causing graft-vs-host disease (GVHD). To test this hypothesis, we examined short tandem repeats from sorted T cells showed no evidence of a second genome, and specifically no evidence of maternal sequences (at the 2% detection limit of the assay). To further investigate this hypothesis, skin biopsies were taken from his ear, temporal scalp, elbow, and anterior tibial skin. The lesions on his ear, scalp, and elbow showed squamous cell carcinoma. Notably, CD3+ cells were noted in the areas with squamous cell carcinoma (Fig. 1B) indicating he was able to recruit some T cells to areas of malignancy. A punch biopsy obtained from his left shin revealed dermal fibrosis and scarring associated with granulomatous infiltration; features of GVHD were not present. A colonoscopy with biopsy of his large intestine showed no histologic abnormality. Thus, we could not find objective findings of GVHD.

We reasoned that the presence of T cells could be explained by a reversion mutation of the gamma chain. To test this hypothesis, we first assessed the expression of CD132, which was present on all T cells (Fig. 3A). Next, we evaluated the T-cell responses to γ c cytokines. The patient's T cells exhibited normal phosphorylation of STAT5 following stimulation with IL-2, IL-7, and IL-15 (Fig. 3B). T-cell responses to IL-21 and IL-4 were also normal as determined by phosphorylation of STAT3 and STAT6, respectively. His T cells also proliferated well in response to anti-CD3 plus IL-7 or IL-15 (Table 1). Together, these results confirm his T cells responded well to γ c cytokines. We next assessed the diversity of the T cells by examining the frequency of usage of the 27 TCR V β regions in CD4+ T cells. We found that 38% the patient's T cells bore a single V β 7.2 (normal range 0.2–3.2%), while proportions of 11 other V β regions were lower than normal (Table 2). Taken together these results showed that T-cells had normal signaling but were quite oligoclonal.

These findings prompted us to corroborate whether the p.V152A variant in *IL2RG* was indeed pathogenic. We could not study any cells that normally express common gamma, since they all showed the revertant sequence (see below) and/or signaled normally. We chose a strategy to examine the X-inactivation pattern of the proband's mother's T cells. Her T

cells demonstrated 97.3% skewing, whereas all her peripheral blood mononuclear cells (PBMC) showed normal, random X-inactivation (<70%). Her sorted B cells also showed equal and random X-inactivation. Notably, there was not any bimodality to the expression of γ_c on her B cells, thus confirming that the V152A variant is expressed normally. These results showed that the *IL2RG* variant skewed the genesis of T cells, whereas her B cells and the ensemble of her bulk leukocytes was unselected. Thus, the variant was pathogenic to T-cell development.

To validate the hypothesis of reversion on a genetic level, we re-examined the patient's initial whole-exome sequencing done at age 18 on whole blood samples. We found that 41 of 44 reads had the variant nucleotide (93%), while 3 of 44 reads showed wild-type sequence (7%). This kind of imbalance suggested a somatic mosaicism or a reversion mutation. To recreate the origin of the mutant and wild-type reads, we compared these percentages to the differential of his white blood cells. His blood count at the time showed 87.3% neutrophils, 2.9% monocytes, 9.8% lymphocytes, and 0% eosinophils or basophils. Thus, the percentage of lymphocytes in the blood corresponded roughly with the proportion of reads at that nucleotide that showed wild-type *IL2RG* sequence. To prove this assumption, we performed whole-exome sequencing on sorted peripheral T cells (age 22), and observed that 100% of the reads at that nucleotide showed the wild-type sequence (112 out of 112 reads at that base). Taken together, these results confirmed that his T cells all bore a reversion variant that restored the wild-type sequence and function of *IL2RG*.

COMMON GAMMA SIGNALING IN B CELL PROGENITORS

Ordinarily, B cells in X-SCID are functionally deficient but normal in number. In our patient, the progressive B-cell lymphopenia was an unexpected finding. Essentially no CD19+ B cells could be detected in the peripheral blood or in the bone marrow beyond age 22, which limited our ability to perform conventional studies of B-cell proliferation and function. We therefore analyzed the bone marrow (age 22) by CyTOF, using an extended panel targeted towards B-cell development (Table 3) and compared to three healthy controls. We found diminished progression in the patient's B-lineage along its normal developmental trajectory [11]. As shown in Fig. 2A, in healthy marrow the frequency of most discrete B-cell progenitors was less than those of the patient's, especially in mid- to late-stage progenitors compared to the control. In our patient, there was a pronounced increase at the pre-B cell stage and a decrease in populations beyond that stage.

The cytokine IL-7 promotes in the development of B cells, facilitating proliferation of B-cell progenitors, and advancing the transition from pro-B to pre-B cells [12]. We sought to better understand the loss of B cells in our subject by examining the phosphorylation of STAT5 (pSTAT5) both at baseline and in response to IL-7 as compared to healthy controls. In previous work studying cells from healthy control subjects, pSTAT5 responses to IL-7 were shown in Pre-Pro-B cells, Pro-BI cells, Pro-BII cells, and Pre-BI cells but not in Pre-BII cells [11]. In this work, we saw healthy control pro-BI and pro-BII cells respond to IL-7 (Fig. 2B, **healthy**). A demonstrable proportion of our patient's Pro-BI and Pre-BI cells showed increases in pSTAT5 upon IL-7 stimulation in the patient (Fig. 2B, **patient**). Thus, B progenitor populations in our subject had intact γ_c function. In healthy subjects, there is

ligand-independent activation of STAT5 in populations of B-cell precursors including Pro-BII and Pre-BI cells [11]. In this work, we indeed saw pSTAT5 in healthy control Pre-BI cells even without stimulation in the patient and controls (Fig. 2B).

At age 22, there were only a few B cells detected, 0.5–1.1% of lymphocytes (Fig. 2C). At that time, we stimulated B cells with IL-4 and showed normal phosphorylation of STAT6 (Fig. 2D). However, IL-4 can signal through both γ c-dependent and non- γ c-dependent pathways [10,13]. Unfortunately, later attempts to study common gamma signaling in peripheral B cells were fruitless because B cells had disappeared from the periphery. Together, these results showed intact γ c signaling in B cell precursors but not conclusive activity in peripheral B cells, and thus only indirectly suggests the B lineage also contained the somatic reversion.

DISCUSSION

Our subject's clinical improvement during childhood and early teenage years were likely due to expansion of a suitable number of functional T cells that offered a sufficient repertoire to protect him from opportunistic infections and allowed growth to adolescence with relative normalcy. What led to his decline in adolescence is unclear but we speculate that a combination of waning (but not altogether lost) output from his reverted lymphocyte progenitor led to a lack of sufficient clonal diversity and allowed for a neo-infection such as norovirus to take hold. The secondary malnutrition that resulted further compromised his immune response.

Most reported cases of somatic reversion show only influential rescue of the T cells. However, one published case similar to ours supports the impact of the reversion of X-SCID on lymphocytes beyond T cells. Hsu *et al* describe a patient initially diagnosed at age 5 with CVID and later found to have X-SCID with somatic reversion [14]. In contrast to our case, the variant allele affected expression of γ c and so could be assessed across lymphocytes by flow cytometry. Lymphocyte counts tracked from ages 23 to 27 showed declining T cell and B cell counts. On sequencing, PBMC demonstrated equal parts wild-type and variant allele, and only 1% of primary B cells showed γ c expression. Thus, that subject had a mixed population of B cells that were γ c competent and incompetent. His EBV-transformed B cells, however, showed only the pathogenic allele and did not phosphorylate STAT5 in response to IL-2. Common gamma signaling was not tested in primary B cells.

One other hypothesis could be considered for explaining the signaling responses of B cell progenitors seen here. The *IL2RG* variant p.V152A could be hypomorphic and allow for some signaling through the IL7R. Certainly other variants of *IL2RG* allow for some cytokine signaling, as we recently showed for a variant that allows for IL-21 signaling [19]. In this model, however, one also needs to assert that the capability of partial IL7R signaling is sufficient to allow for genesis of B cells but not T cells, which we have no evidence for.

A common observation in our patient and the subject of the Hsu *et al* paper [14] was the initial presence of B cells that decreased over the years to undetectable levels. The need for γ c signaling in late stage B-cell maturation is undeniable because of the critical role of

IL-21 [15,16]. On the other hand, γ c is not absolutely required for the genesis of B cells, as seen in most boys with X-SCID who have plentiful B cells upon diagnosis. Curiously, the X-inactivation pattern of B cells from X-SCID carriers usually shows skewing but not as extreme as the T cells [17], suggesting that γ c signaling offers a potent but non-essential proliferative advantage to cells expressing normal γ c chain [18]. In our patient's mother, however, circulating B cells showed unskewed (equal, random) X-inactivation. This finding could support the hypothesis that the V152A variant actually does support some B cell development (e.g., intact IL7R signaling in B but not T precursor populations). Our use of CyTOF in this case offered elucidation about the loss of B cells based on the identification that B-cell progenitors were accumulated in pre-pro-B, pro-B, and pre-BI stages but not at pre-BII or beyond. STAT5 phosphorylation, both basally and in response to IL-7, was relatively intact in our patient as compared to healthy controls. Given that both the subject of the Hsu paper (who had just 1% revertant B cells) and our subject (who offered some evidence of revertant B-cell progenitors) lost B cells over time may suggest that progressive B-cell loss is a common feature of abnormal bone marrow development in common gamma SCID or may be due to hypomorphic activity of IL7R over time, and not due to reversion at all.

In the modern era when sequencing is typically begun early in the investigation of an immunodeficiency, it should be carefully noted when reads in the hemizygous context show both pathogenic and wild-type bases, as this situation may suggest a somatic reversion or somatic mosaicism [20].

To our knowledge, this is the longest reported follow up of a X-SCID patient with a reversion in *IL2RG*. The reversion, which likely occurred at the level of a single progenitor, initially attenuated the clinical phenotype but was unable to build sufficient immunity for survival. A key factor was, perhaps, the lack of diversity in the T-cell repertoire, which set the stage for the infections and immune dysregulation, complications that eventually resulted in his demise. We recommend assessment of TCR diversity whenever there is reason to suspect that meager T cell counts are further complicated by poor diversity. Diversity can be assessed by next generation sequencing approaches or by flow cytometry as we did here. When the TCR repertoire is compromised in leaky or revertant SCID, definitive treatment by gene therapy or allogeneic HSCT should be attempted as soon as possible before immune dysregulation compromises the chances of success.

Acknowledgements

We thank the subject and his family for their willingness to participate in studies. We gratefully acknowledge funding from the Jeffrey Modell Foundation and the NIH.

REFERENCES

1. Puck JM, Pepper AE, Henthorn PS, Candotti F, Isakov J, Whitwam T, et al. Mutation analysis of *IL2RG* in human X-linked severe combined immunodeficiency. *Blood* [Internet]. 1997;89:1968–77 Available from: <http://www.ncbi.nlm.nih.gov/pubmed/9058718>
2. Dvorak CC, Haddad E, Buckley RH, Cowan MJ, Logan B, Griffith LM, et al. The genetic landscape of severe combined immunodeficiency in the United States and Canada in the current era (2010/2018). *J Allergy Clin Immunol*. 2019;143:405–7. [PubMed: 30193840]

3. Wada T, Candotti F. Somatic mosaicism in primary immune deficiencies. *Curr Opin Allergy Clin Immunol*. 2008;8:510–4. [PubMed: 18978464]
4. Bendall SC, Simonds EF, Qiu P, Amir ED, Krutzik PO, Finck R, et al. Single-cell mass cytometry of differential immune and drug responses across a human hematopoietic continuum. *Science* [Internet]. 2011;332:687–96. Available from: <http://www.ncbi.nlm.nih.gov/pubmed/21551058>
5. Good Z, Sarno J, Jager A, Samusik N, Aghaepour N, Simonds EF, et al. Single-cell developmental classification of B cell precursor acute lymphoblastic leukemia at diagnosis reveals predictors of relapse. *Nat Med*. 2018;24:474–83. [PubMed: 29505032]
6. Bertelsen B, Tümer Z, Ravn K. Three new loci for determining X chromosome inactivation patterns. *J Mol Diagnostics*. 2011;
7. Heimall J, Logan BR, Cowan MJ, Notarangelo LD, Griffith LM, Puck JM, et al. Immune Reconstitution and Survival of 100 SCID Patients Post Hematopoietic Cell Transplant: A PIDTC Natural History Study. *Blood* [Internet]. 2017;blood-2017-05-781849. Available from: <http://www.bloodjournal.org/lookup/doi/10.1182/blood-2017-05-781849>
8. Wang YT, Geng B, Yoo KY, Stiehm ER, Garcia-Lloret M, Wong D, et al. Cutaneous granulomas and epidermodysplasia verruciformis in early onset combined immunodeficiency syndrome. *Am J Dermatopathol*. 2014;36:179–83. [PubMed: 24247584]
9. Kumaki S, Ishii N, Minegishi M, Ohashi Y, Hakozaki I, Nonoyama S, et al. Characterization of the gamma chain among 27 unrelated Japanese patients with X-linked severe combined immunodeficiency (X-SCID). *Hum Genet*. 2000;107:406–8. [PubMed: 11129345]
10. Izuhara K, Heike T, Otsuka T, Yamaoka K, Mayumi M, Imamura T, et al. Signal transduction pathway of interleukin-4 and interleukin-13 in human B cells derived from X-linked severe combined immunodeficiency patients. *J Biol Chem* [Internet]. 1996;271:619–22. Available from: <http://www.ncbi.nlm.nih.gov/pubmed/8557662>
11. Bendall SC, Davis KL, Amir E-AD, Tadmor MD, Simonds EF, Chen TJ, et al. Single-cell trajectory detection uncovers progression and regulatory coordination in human B cell development. *Cell* [Internet]. Elsevier; 2014;157:714–25. Available from: 10.1016/j.cell.2014.04.005
12. Corfe SA, Paige CJ. The many roles of IL-7 in B cell development; Mediator of survival, proliferation and differentiation. *Semin Immunol* [Internet]. Elsevier Ltd; 2012;24:198–208. Available from: 10.1016/j.smim.2012.02.001
13. Matthews DJ, Clark PA, Herbert J, Morgan G, Armitage RJ, Kinnon C, et al. Function of the interleukin-2 (IL-2) receptor γ -chain in biologic responses of X-linked severe combined immunodeficient B cells to IL-2, IL-4, IL-13, and IL-15. *Blood*. 1995;85:38–42. [PubMed: 7803808]
14. Hsu AP, Pittaluga S, Martinez B, Rump AP, Raffeld M, Uzel G, et al. IL2RG Reversion Event in a Common Lymphoid Progenitor Leads to Delayed Diagnosis and Milder Phenotype. *J Clin Immunol*. 2015;35:449–53. [PubMed: 26076747]
15. Recher M, Berglund LJ, Avery DT, Cowan MJ, Gennery AR, Smart J, et al. IL-21 is the primary common γ chain-binding cytokine required for human B-cell differentiation in vivo. *Blood* [Internet]. 2011;118:6824–35. Available from: <http://www.ncbi.nlm.nih.gov/pubmed/22039266>
16. Ozaki K, Spolski R, Feng CG, Qi C-F, Cheng J, Sher A, et al. A critical role for IL-21 in regulating immunoglobulin production. *Science* [Internet]. 2002;298:1630–4. Available from: <http://www.ncbi.nlm.nih.gov/pubmed/12446913>
17. Conley ME, Lavoie A, Briggs C, Brown P, Guerra C, Puck JM. Nonrandom X chromosome inactivation in B cells from carriers of X chromosome-linked severe combined immunodeficiency. *Proc Natl Acad Sci U S A*. 1988;85:3090–4. [PubMed: 2896355]
18. Johnson SE, Shah N, Panoskaltis-Mortari A, LeBien TW. Murine and Human IL-7 Activate STAT5 and Induce Proliferation of Normal Human Pro-B Cells. *J Immunol*. 2005;175:7325–31. [PubMed: 16301638]
19. Deal C, Thauland TJ, Stiehm ER, Garcia-Lloret MI, Butte MJ. Intact B-Cell Signaling and Function With Host B-Cells 47 Years After Transplantation for X-SCID. *Front Immunol*. 2020;11:1–7. [PubMed: 32038653]

20. Mensa-Vilaró A, Bravo García-Morato M, de la Calle-Martin O, Franco-Jarava C, MartínezSaavedra MT, González-Granado LI, et al. Unexpected relevant role of gene mosaicism in patients with primary immunodeficiency diseases. *J Allergy Clin Immunol* [Internet]. 2019;143:359–68. Available from: <http://www.ncbi.nlm.nih.gov/pubmed/30273710>

Author Manuscript

Author Manuscript

Author Manuscript

Author Manuscript

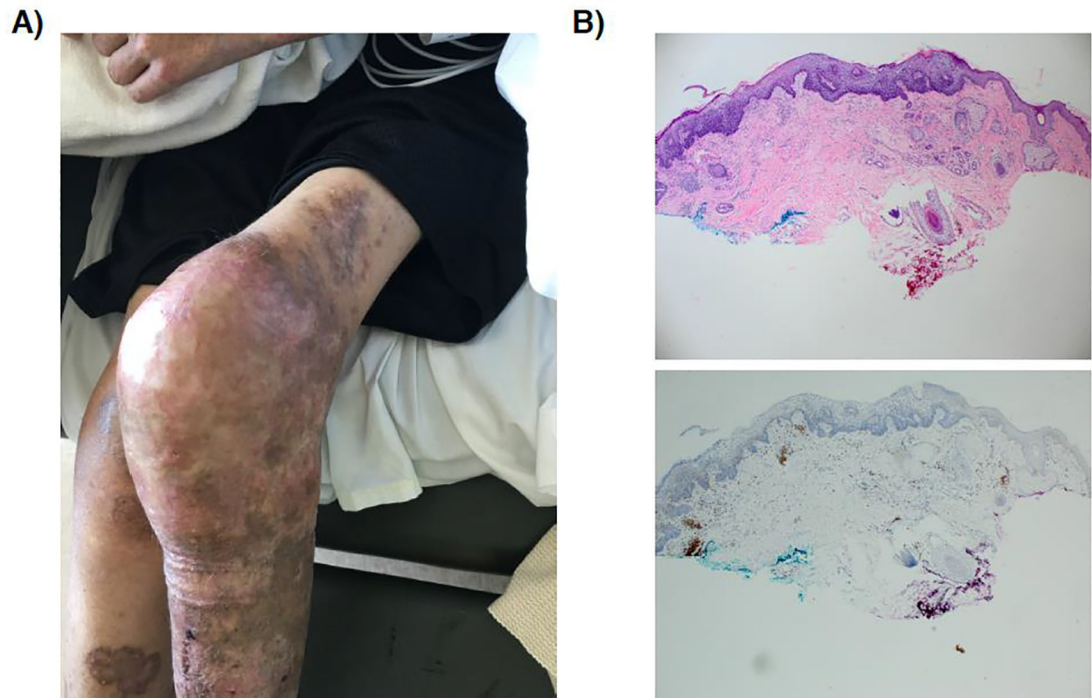


Fig. 1.

A) Leg rash and knee swelling. **B) Skin biopsy.** (top) Hematoxylin and eosin staining showing infiltration of lymphocytes in the region of a squamous cell lesion, (bottom) CD3 immunostaining confirming the presence of collections of T cells in the dermis.

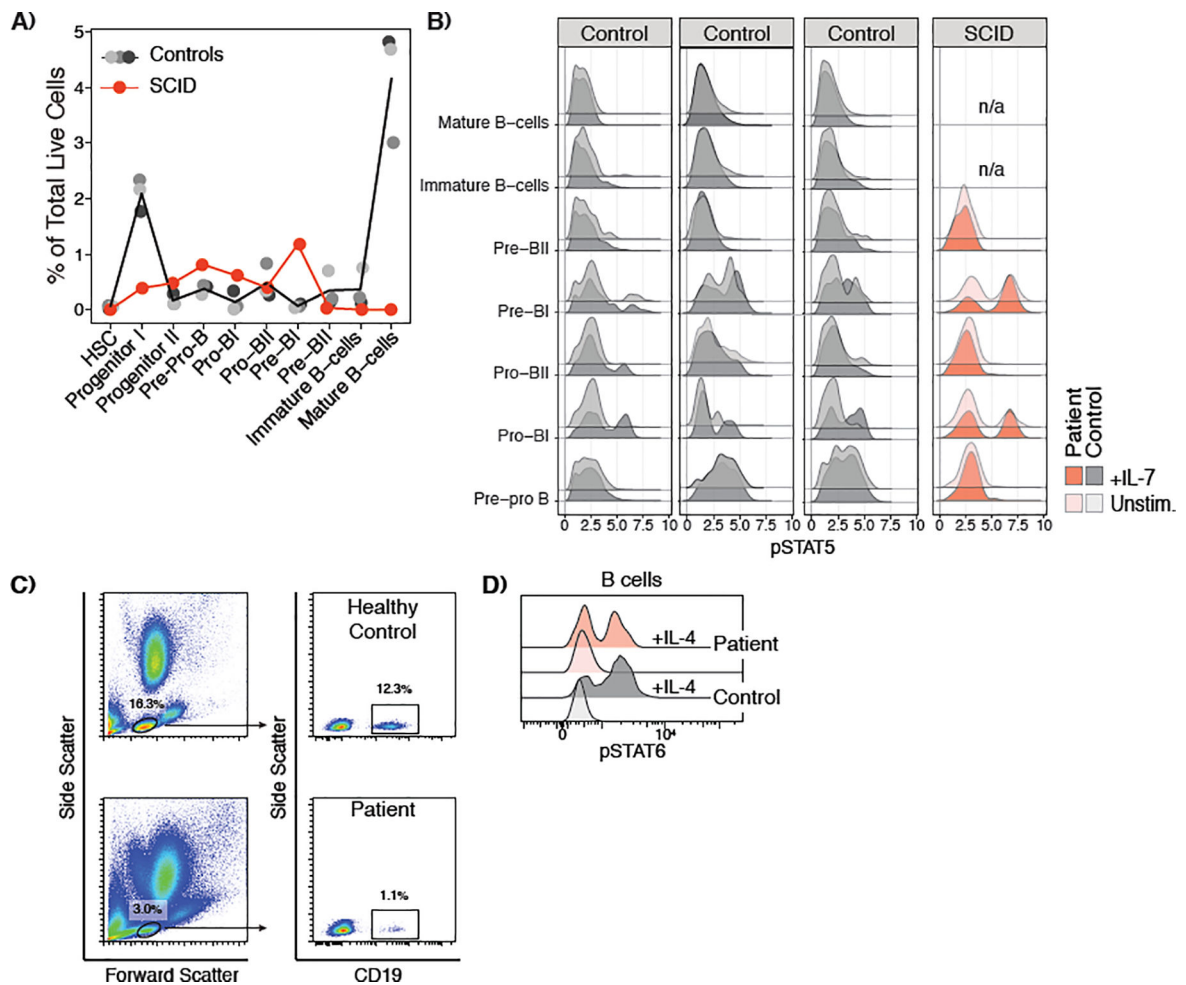


Fig. 2.

A) Pre-B cells and other progenitors are enriched in a SCID patient relative to a healthy control. The percent of the total live cells (DNA⁺, cisplatin⁻) collected gated within each stage of Bcell development is reported. While the patient's mid- and late-progenitor stages are slightly enriched, he has essentially no mature B-cells or progenitors following the pre-BI cell stage. **B) SCID pre-B cells exhibit higher median pSTAT5 levels than healthy controls.** The median value of pSTAT5 measured by mass cytometry is reported for each stage of B-cell development. pSTAT5 levels are log₁₀-transformed for better visualization. **C) Gating of peripheral blood B cells (age 22).** **D) IL-4 induced phosphorylation of STAT6.**

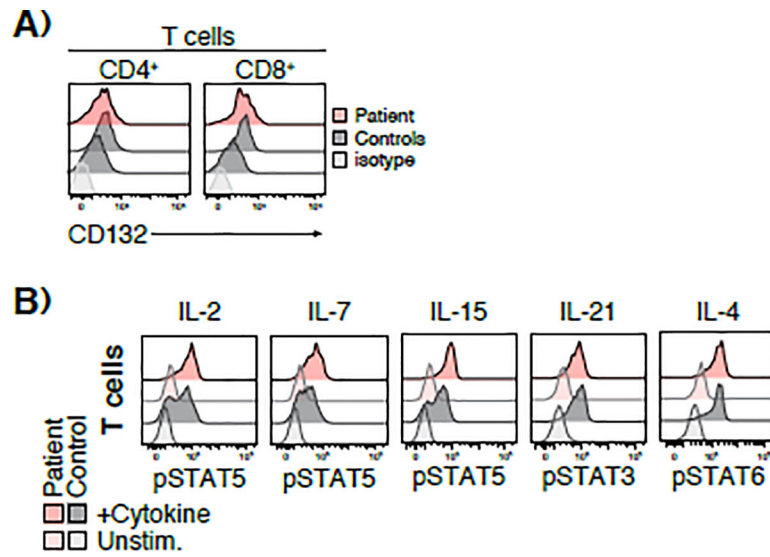


Fig. 3.

A) CD132 expression is normal on T cells. Total PBMCs were stained for CD3, CD4, CD8, CD132 or isotype control. Expression of CD132 on normal controls and patient was determined by flow cytometry. **B)** CD4⁺ T cells show normal common gamma signaling in response to stimulation with a variety of cytokines for 20 min.

Table 1.

Immunological phenotype

Lymphocyte Enumeration (Cells/μL)	Age 2	Age 18	Age 22	Normal
T cells (CD3+)	306	685	233	603–2990 cells/ μ L
Helper T cells (CD4+)	45	159	203	441–2156 cells/ μ L
Cytotoxic T cells (CD8+)	225	480	33	125–1312 cells/ μ L
B cells (CD19+)	625	5	0–5	95–640 cells/ μ L
NK cells (CD56+/CD16+)	16	148	0.1	107–698 cells/ μ L
Proliferation	Absent response to low dose PHA; 10 to high dose PHA (normal 55–155, daily control 144)	Low to PWM; Absent to PHA, ConA, tetanus	IL2 alone (control) 38% (control 5%); CD3 alone 28% (control 93%); CD3+IL7 75% (control 97%); CD3+IL15 97% (control 97%)	
Other functional assays		NK function low		
	Percentage			Normal
Memory B cells			0	6–52
Unswitched memory B cells			0	2–29
Switched memory B cells			0	2–26
Immature B cells			0	0–9
CD4+CD62L+ Naive			0.3%	15–72%
CD4+ Memory (CD45RO+)			99%	37–71%
CD8+CD62L+ Naive			5%	26–68%
CD8+ Effector memory			77%	12–41%
Immunoglobulins				
IgG (mg/dL)	445	133	1080 (on replacement)	
IgA (mg/dL)	536	54	18	
IgM (mg/dL)	145	10	14	
IgE (IU/mL)	16	2	1	

Table 2.T-cell clonality by flow cytometry analysis of TCR V β

V β region	Percentage	Reference Interval
1	2.69%	1.9–4.67
2	4.95%	4.16–8.91
3	0.37%	0.64–8.22
4	1.51%	1.08–3.76
5.1	1.26%	3.77–7.33
5.2	0.92%	0.87–2.27
5.3	0%	0.73–4.57
7.1	0.92%	1.28–4.33
7.2	38.15%	0.02–3.22
8	4.22%	2.78–8.56
9	1.62%	2.62–4.15
11	0.57%	0.81–1.5
12	0.55%	1.08–1.92
13.1	3.85%	2.62–9.42
13.2	1.72%	1.31–6.55
13.6	3.49%	1.29–2.5
14	0.57%	2.75–4.45
16	1.62%	0.47–2.91
17	5.88%	3.45–7.88
18	0.31%	0.55–1.01
20	1.26%	1.19–4.60
21.3	0.83%	1.69–2.56
22	5.35%	2.46–4.62
23	0%	0.5–1.47

Table 3.

Panel of CyTOF Markers

Lineage Surface Markers		Intracellular Markers	
CD3	CD4	RAG1	TDT
CD7	CD10	PAX5	IgM (intracellular)
CD16	CD19		
CD20	CD22	Signaling Molecules	
CD24	CD33	p4EBP1	pAKT
CD34	CD38	pERK	pSTAT5
CD45	CD45RA	pS6	
CD56	CD61		
CD79b	CD117	B- and T-Cell Receptors	
CD123	CD127	IgM (surface)	IgG
CD179a	CD179b	BCR- κ chain	BCR- λ chain
CD235ab	HLA-DR	TCR- α chain	TCR- β chain

Author Manuscript

Author Manuscript

Author Manuscript

Author Manuscript