

UCSF

UC San Francisco Previously Published Works

Title

Ultrasound-guided Access and Dilation for Percutaneous Nephrolithotomy in the Supine Position: A Step-by-Step Approach.

Permalink

<https://escholarship.org/uc/item/9jc700rh>

Authors

Tzou, David T
Metzler, Ian S
Usawachintachit, Manint
[et al.](#)

Publication Date

2019-11-01

DOI

10.1016/j.urology.2019.07.022

Peer reviewed



Ultrasound-guided Access and Dilation for Percutaneous Nephrolithotomy in the Supine Position: A Step-by-Step Approach

David T. Tzou, Ian S. Metzler, Manint Usawachintachit, Marshall L. Stoller, and Thomas Chi

INTRODUCTION Ultrasound guidance for percutaneous nephrolithotomy (PCNL) has gained acceptance amongst urologists given its numerous advantages over fluoroscopy. While traditionally performed in the prone position, this video demonstrates a step-by-step approach to performing PCNL in the supine position, solely under ultrasound guidance.

MATERIALS AND METHODS Once in the modified supine (Galdakao-modified Valdivia) position, important anatomic landmarks are identified. It is important to first orient the ultrasound probe such that its cranial side corresponds to the left of the ultrasound screen. After optimizing a target calyx, keeping the needle in the imaging plane of the probe facilitates renal access. Tract dilation under ultrasound guidance is then achieved by keeping the wire and dilators in the same imaging plane.

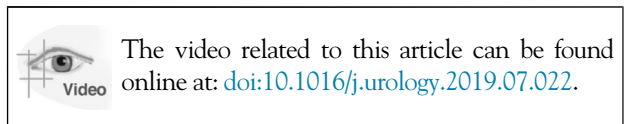
RESULTS The 11th and 12th ribs, paraspinous muscle, iliac crest, midaxillary line, and costal margin are the anatomic landmarks that orient the probe to the location of the kidney. Placing the ultrasound probe in the midaxillary line, parallel to the 11th rib allows the operator to identify key renal landmarks: the renal cortex, peri-pelvic fat, collecting system, kidney stone with its associated postacoustic shadow, and the intended target calyx. Controlling the needle is easiest in the longitudinal view, as the needle can be visualized from skin to target. Dilation under ultrasound relies on keeping the wire in view. The tip of the 10-French dilator is based on the location where the wire image disappears as the dilator advances. The balloon dilator tip is visualized on ultrasound reaching the appropriate depth just inside the collecting system, at which time balloon inflation results in complete dilation of the tract.

CONCLUSIONS This video provides a step-by-step approach demonstrating that PCNL can be performed in the supine position using only ultrasound-guidance. This approach facilitates renal access in this position and obviates the need for radiation exposure. UROLOGY 133: 245–246, 2019. © 2019 Elsevier Inc.

- 0:00 In this video we demonstrate a step-by-step technique to perform Ultrasound-Guided Access and Dilation for PCNL in the Supine Position
- 0:09 Several advantages have been associated with ultrasound guided PCNL. These include a substantial reduction in radiation exposure¹ as well as the ability to visualize surrounding structures in real time. Other advantages are that it can be easier to identify the most posterior calyx and there are potentially fewer skills to master with this technique².
- 0:30 Ultrasound Access relies on performing 2 basic skills. Number 1, imaging the kidney and achieving an appropriate target. Number 2, controlling the access needle. If able to perform these 2 basic skills, we believe that urologists can achieve ultrasound access regardless of the position chosen.
- 0:48 For supine, we use the Galdakao-modified Valdivia position. Here, the important landmarks are the paraspinous muscle, the caudal edges of the 11th and 12th ribs, and the iliac crest. Specific to the supine position, the midaxillary line and costal margin can also be helpful.
- 1:06 To further illustrate these landmarks, here we have a right-sided PCNL and we start by outlining the iliac crest. Next, we feel for the 12th rib and paraspinous muscle. This is followed by identifying the important 11th rib. After this, we identify the midaxillary line which

Funding: NIH grant P20-DK-116193 and R21-DK-109433.
Declarations of Interest: We wish to confirm that there are no known conflicts of interest associated with this publication and there has been no significant financial support for this work that could have influenced its outcome.
Financial Disclosures: David T Tzou: Consultant for Boston Scientific Corporation; Ian S Metzler: None; Manint Usawachintachit: None; Marshall L Stoller: Paid speaker and consultant for Boston Scientific Corporation paid speaker for Karl Storz Company; Thomas Chi: Consultant for Boston Scientific Corporation consultant for Auris Robotics.
 From the Department of Urology, University of California San Francisco, San Francisco, CA; the Department of Urology, University of Arizona College of Medicine, Tucson, AZ; and the Division of Urology, Faculty of Medicine, King Chulalongkorn Memorial Hospital, Chulalongkorn University, Patumwan, Bangkok, Thailand
 Address correspondence to: David T. Tzou, M.D., Department of Urology, University of Arizona College of Medicine, 1501 N. Campbell Ave, PO Box 245077, Tucson, AZ 85724. E-mail: dtzou@surgery.arizona.edu
 Submitted: February 24, 2019, accepted (with revisions): July 22, 2019

- is generally the initial location to place the ultrasound probe. After rotating the probe parallel to the 11th rib, one can see a longitudinal view of the right kidney, unobstructed by rib shadow.
- 1:47 Once in position, the first step is orienting the ultrasound probe. This is done by pressing on the skin next to the probe so that the left and right of the ultrasound screen corresponds to the head and foot of the patient. In this shot here, the probe needs to be flipped to ensure that the foot is to the operator's right of the screen appropriately.
- 2:06 In the supine position, placing the probe in the midaxillary line, parallel to the 11th rib, allows one to identify the kidney. As you can see demonstrated here, scanning back and forth and then moving the probe slightly, allows for important ultrasound landmarks to be identified. These include the renal cortex, peripelvic fat, collecting system, kidney stone, and the intended target calyx.
- 2:32 Moving on to controlling the needle, the longitudinal view is the easiest, as it allows the operator to see the needle tip from skin to target, essentially in the plane of the ultrasound.
- 2:42 The goal is to keep the intended target in view, and then bring the needle into the target. Here the patient is supine, and we are puncturing the right kidney, a lower pole access is taking place, coming from the right of the screen, or foot of the probe. You can see some real-time adjustments of the needle and probe to visualize the tip eventually reaching the target calyx.
- 3:17 Additional tips for successful access focus on the target calyx. Here you can see a right kidney, impending lower pole access. First it can sometimes be challenging to differentiate renal pyramids from the target calyx. Moreover, if there is stone occupying most of the calyx, looking for a crescent of darker black often helps with guiding you correctly into the collecting system.
- 3:41 Meanwhile, as the kidney moves, sometimes the target and needle phase in and out of view. As you can see, right here, the operator makes a small adjustment toward the foot, correcting the trajectory while keeping the needle in the same plane as the target stone. This allows the needle to directly hit the stone, dislodging it from the calyx.
- 4:01 Maintaining the correct ultrasound plane, one can see entry of the wire into the collecting system. As you can see here, the tip of our J-tip wire is clearly seen curling within the renal pelvis.
- 4:12 Advanced techniques of ultrasound PCNL involve performing dilation under ultrasound guidance. Here, the wire is already in the collecting system, and you can see withdrawal of the needle sheath, leaving the wire in place.
- 4:26 Next you can see as a 10F dilator is advanced, there is a loss of signal of the wire which corresponds to the tip of the dilator. As the dilator is withdrawn, there is reappearance of the wire.
- 4:42 This leads us to the tip of the balloon dilator being advanced over the wire. Here you can see the balloon tip reach the appropriate depth, just inside the collecting system.
- 4:57 With our balloon dilator positioned correctly, our balloon is subsequently inflated, and this expansion of the tract can be visualized on ultrasound. At this point, we've completed creating our proper tract into the kidney.
- 5:14 Some tips and tricks can be helpful as one begins to learn ultrasound guided PCNL. First and foremost, becoming familiar with the controls of the ultrasound machine helps the operator adjust the depth and gain to optimize renal imaging.
- 5:28 Here you can see that adjusting the depth helps to enlarge the appearance of the kidney on the ultrasound screen.
- 5:37 Likewise, adjusting the gain by pushing the knobs to the left or right can be crucial to help make sure that the image is optimized.
- 5:49 Other imaging tips include being cognizant of how surrounding structures appear on ultrasound. Recognizing these structures can help you avoid them with your needle. While subtle, here you can see the sliding pleural sign coming from the left of the screen.
- 6:10 Meanwhile in this view, bowel can be seen in the lower right portion of the screen, appearing as a moving area with a relatively bright signal.
- 6:23 In summary, this video has demonstrated that radiation-free ultrasound guided PCNL is achievable in the supine position. Gaining ultrasound access relies on 2 basic skills—imaging the kidney well and then controlling the needle into the target calyx. Meanwhile, performing renal tract dilation under ultrasound is an advanced skill that relies on imaging cues predominantly related to the signal of the wire. In general, we recommend the transition from fluoroscopy to ultrasound in stages.
- 6:53 We thank you for your attention.



References

1. Usawachintachit M, Tzou DT, Hu W, Li J, Chi T. X-ray free ultrasound-guided percutaneous nephrolithotomy: how to select the right patient? *Urology*. 2017;100:38–44.
2. Usawachintachit M, Masic S, Allen IE, Li J, Chi T. Adopting ultrasound guidance for prone percutaneous nephrolithotomy: evaluating the learning curve for the experienced surgeon. *J Endourol*. 2016;30:856–863.