

UCSF

UC San Francisco Previously Published Works

Title

Femoral condyle insufficiency fractures: associated clinical and morphological findings and impact on outcome

Permalink

<https://escholarship.org/uc/item/9j84r644>

Journal

Skeletal Radiology, 44(12)

ISSN

0364-2348

Authors

Plett, SK
Hackney, LA
Heilmeyer, U
[et al.](#)

Publication Date

2015-12-01

DOI

10.1007/s00256-015-2234-1

Peer reviewed

Femoral condyle insufficiency fractures: associated clinical and morphological findings and impact on outcome

Sara K. Plett¹ · Lauren A. Hackney¹ · Ursula Heilmeier¹ · Lorenzo Nardo¹ · Aihong Yu^{1,2} · Chiyuan A. Zhang¹ · Thomas M. Link¹

Received: 15 April 2015 / Revised: 1 August 2015 / Accepted: 3 August 2015 / Published online: 20 August 2015
© ISS 2015

Abstract

Objective To determine the characteristics of femoral condyle insufficiency fracture (FCIF) lesions and their relative associations with the risk of clinical progression.

Materials and methods This HIPAA-compliant retrospective study was approved by our Institutional Review Board. Seventy-three patients (age range, 19–95) were included after excluding patients with post-traumatic fractures, bone marrow infarct, osteochondritis dissecans, or underlying tumor. Two board-certified musculoskeletal radiologists classified morphologic findings including lesion diameter, associated bone marrow edema pattern, and associated cartilage/meniscus damage. Electronic medical charts were evaluated for symptoms, risk factors, and longitudinal outcomes, including total knee arthroplasty (TKA). Imaging characteristics were correlated with clinical findings, and comparison of outcome groups was performed using a regression model adjusted for age.

Results The majority of patients with FCIF were women (64.4 %, 47/73), on average 10 years older than men (66.28 ± 15.86 years vs. 56.54 ± 10.39 years, $p=0.005$). The most common location for FCIF was the central weight-bearing surface of the medial femoral condyle; overlying full thickness cartilage loss (75.7 %, 53/70) and ipsilateral meniscal injury (94.1 %, 64/68) were frequently associated. Clinical

outcomes were variable, with 23.9 % (11/46) requiring TKA. Cartilage WORMS score, adjacent cartilage loss, and contralateral meniscal injury, in addition to decreased knee range of motion at presentation, were significantly associated with progression to TKA ($p<0.05$).

Conclusions FCIF are frequently associated with overlying cartilage loss and ipsilateral meniscal injury. The extent of cartilage loss and meniscal damage, in addition to loss of knee range of motion at the time of presentation, are significantly associated with clinical progression.

Keywords Spontaneous osteonecrosis of the knee · Insufficiency fracture · Femoral condyle · Magnetic resonance imaging

Introduction

Spontaneous osteonecrosis of the knee (SONK) was introduced as a distinct entity by Ahlbäck et al. in 1968 [1]. The authors described a subset of elderly patients presenting with acute onset of unprovoked severe knee pain maximally tender over the weight-bearing surface of the medial femoral condyle. Radiographs obtained during the first weeks were normal; however, subsequent flattening of the medial femoral condyle and development of subchondral lucency with a well-circumscribed sclerotic margin appeared after several months. After excluding entities such as osteochondritis dissecans, osteoarthritis, fracture, infection, neuropathy, and tumor, the authors concluded that the condition represented an atypical spontaneous manifestation of femoral osteonecrosis.

Since the introduction of SONK, there has been much inquiry into its pathophysiology. Traumatic and vascular insults are thought to be the most plausible etiologies, although the

✉ Lauren A. Hackney
lhackney@montefiore.org

¹ Department of Radiology and Biomedical Imaging, University of California, San Francisco, 185 Berry Street, Suite 350, San Francisco, CA 94107, USA

² Department of Radiology, Beijing Jishuitan Hospital, 4th Medical College of Peking University, Beijing, China

absence of a clear precipitating factor suggests a multifactorial pathogenesis [2, 3]. In 1999, Yamamoto et al. described subchondral insufficiency fractures of the femoral head within lesions previously classified as osteonecrosis [4]. This discovery prompted a reevaluation of SONK at the femoral condyle [2, 5, 6]. A spectrum of femoral condylar pathology has since been proposed, with FCIF and osteonecrosis being recognized as distinct entities along this spectrum, and osteoporosis was implicated as a risk factor [2, 7–10]. Currently, there remains limited knowledge about the clinical findings and morphological abnormalities associated with femoral condyle insufficiency fractures (FCIF). In particular, meniscal tears appear to be frequently encountered with these lesions, although existing studies are limited by small numbers and low-field-strength magnetic resonance (MR) imaging systems [7]. Though treatment options vary widely and include oral/intravenous bisphosphonate treatment, high tibial osteotomy, unicompartmental knee arthroplasty, and total knee arthroplasty (TKA), no studies to date have explored the ways in which MR findings of FCIF lesions can be used to predict the longitudinal evolution of these lesions and how they are associated with treatment [11–16]. Our objectives were therefore to (i) analyze MR characteristics of FCIF, (ii) describe associated cartilage, bone marrow, and ligamentous abnormalities, and (iii) correlate these findings with concomitant clinical symptoms, risk factors, and longitudinal outcomes. We hypothesized that elucidation of coexisting imaging and clinical findings would further our understanding of the pathophysiology and prognosis of the disease process, thus helping to guide clinicians towards a more appropriate prognosis-based treatment plan.

Materials and methods

Subjects

The Institutional Review Board approved this HIPAA-compliant retrospective study. The requirement for informed consent was waived. A picture archiving and communications system (PACS) database search from August 2000 through August 2013 was performed for the keywords “femoral condyle insufficiency fracture,” “spontaneous osteonecrosis knee,” and/or “SONK” in the radiology report impression. This search yielded 162 patients; 84 met the typical inclusion criteria of an insufficiency fracture previously described by Yamamoto et al. [2]; these include a low-signal band on T1-weighted imaging adjacent to the subchondral bone in the weight-bearing portion of the femoral condyle associated with significant amount of bone marrow edema pattern (BMEP) with high signal on T2-weighted imaging (Fig. 1). Patients with non-insufficiency type fracture, bone marrow infarct, osteochondritis dissecans (defined as a central osteochondral

separation and/or fragmentation), or underlying tumor were excluded [17]. Technically limited MR images (motion artifact, phase encoding artifact, research protocols) were also excluded. This ultimately yielded 73 patients for inclusion (Fig. 2).

Clinical data

All 73 subjects underwent retrospective review of their clinical data documented within the electronic medical record. “Baseline” was defined as the initial orthopedic visit to address knee pain. Pain was described by duration of symptoms and the visual analog pain scale [18]. Historical information including previous trauma, steroid administration (intra-articular versus systemic), and prior knee surgery was recorded. Body mass index (BMI), vitamin D, and dual-energy X-ray absorptiometry (DXA) analysis of bone mineral density were also noted. Records and follow-up radiographs were reviewed to determine healing of FCIF or disease progression. In particular we analyzed the number of patients which went on to require TKA within the follow-up period. Patients in the non-TKA group with less than 6 months of follow-up were excluded from the outcomes analysis.

An orthopedic surgeon or sports medicine physician performed a physical examination of the knee at baseline. Objective indicators of the knee exam were recorded according to the New Knee Society Knee Scoring System, including alignment, instability, range of motion, flexion contracture, and extensor lag [19].

MR imaging

Subjects underwent MR imaging of the knee at 3 Tesla ($n=35$) and 1.5 Tesla ($n=38$) (GE Healthcare, Waukesha, WI, USA) in an eight-channel knee coil (In-Vivo, Gainesville, FL, USA). The following sequences were used for image analysis: (1) coronal intermediate-weighted (iw) 2D fast spin-echo (FSE) sequence with fat saturation, (2) coronal T1-weighted 2D FSE sequence, (3) sagittal proton density-weighted 2D FSE sequence, (4) sagittal iw 2D FSE sequence with fat saturation and (5) axial iw 2D FSE sequence with fat saturation (Table 1).

Image analysis

MR images were reviewed on PACS workstations (Agfa, Ridgefield Park, NJ, USA) and assessed for the presence and location of FCIF, meniscal, cartilage, and ligamentous lesions as well as the presence of bone marrow edema pattern (BMEP), synovitis, and other pathology. Two board-certified musculoskeletal radiologists with 6 years of experience analyzed the studies independently. In cases of divergent findings,

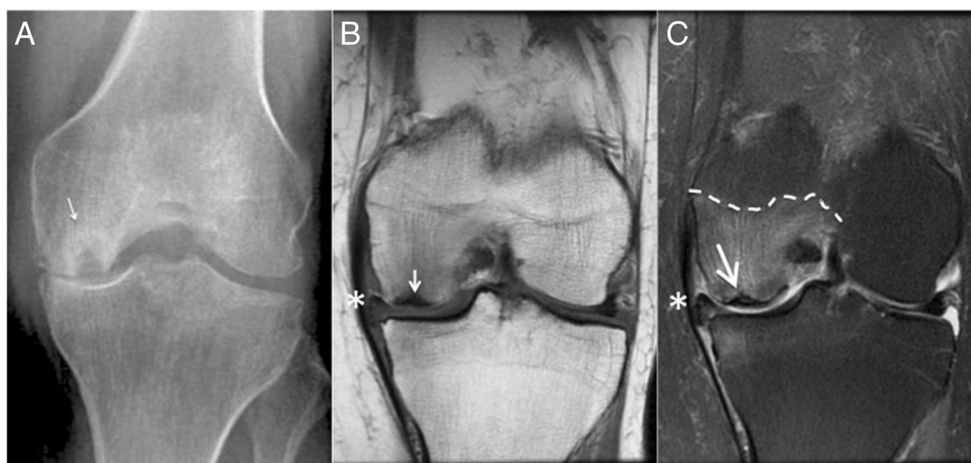


Fig. 1 a A 67-year-old female with knee pain. AP radiograph demonstrates radiolucent ovoid lesion with sclerotic halo within the medial femoral condyle (*white arrow*). b An 84-year-old female with left knee pain after a fall. Coronal T1-weighted image demonstrates a low signal intensity focus beneath the articular surface of the medial femoral condyle (*white arrow*). Abnormal intrinsic signal and extrusion

of the medial meniscus (*asterisk*) is consistent with associated meniscal injury. c Corresponding fat-suppressed intermediate-weighted image from patient in (b) demonstrates markedly increased bone marrow edema pattern (*dashed outline*) within the medial femoral condyle with fracture line (*white arrow*). Abnormal intrinsic signal, tear, and extrusion of the medial meniscus is again shown (*asterisk*)

consensus readings with a third board-certified musculoskeletal radiologist (23 years of experience) were performed.

FCIF were characterized in terms of morphology, location, and size. Location was described according to a zone system detailed by Ramnath and Kattapuram, which is outlined in

Fig. 3 [6]. Involvement of the weight-bearing versus non-weight-bearing condyle surface was noted. Size measurements in two dimensions were obtained from coronal and sagittal iw fat-saturated FSE images, along with the maximum depth of the defect, measured from the articular surface to the

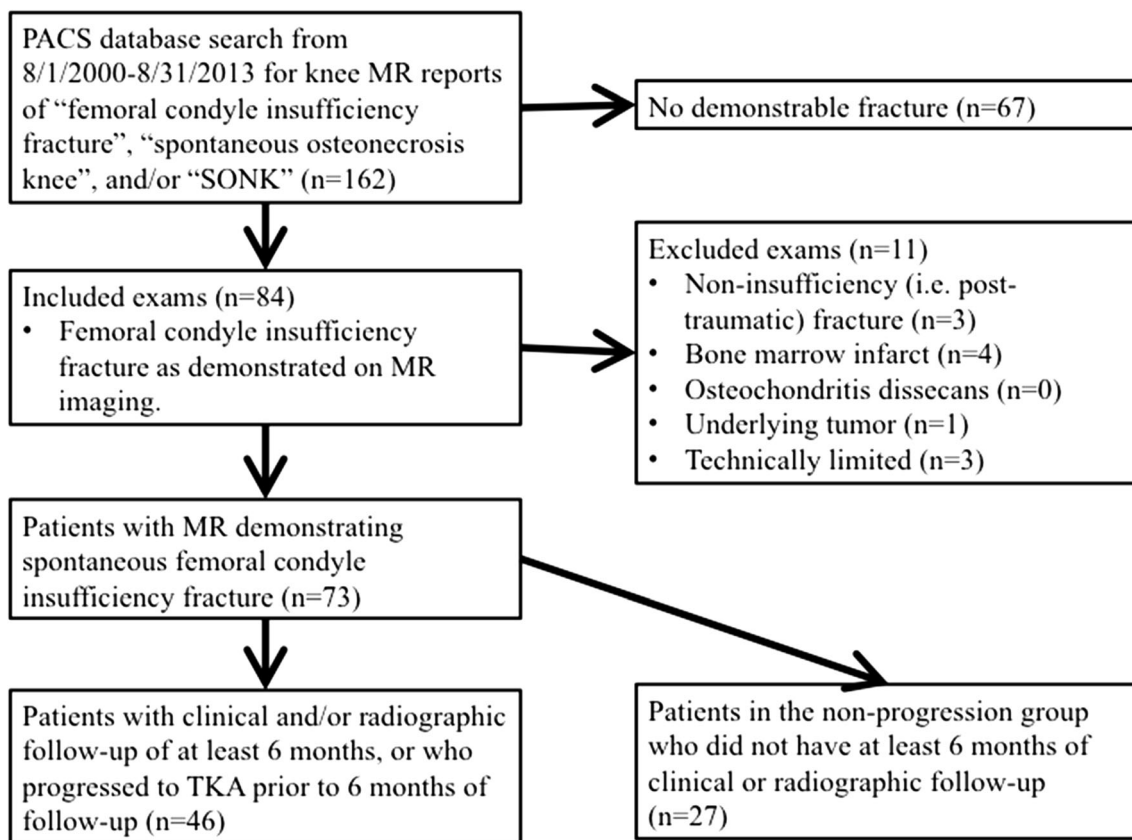


Fig. 2 Flowchart demonstrates patient inclusion and exclusion criteria

Table 1 MR sequence parameters

MR sequence	TR (ms)	TE (ms)	FOV (cm)	BW (kHz/pixel)	Slice thickness (mm)	Matrix size ^b (pixels)
Coronal intermediate-weighted 2D FSE with fat saturation ^a	3200–4600	40–55	130–150	81.37–139.49	4	320×224
Coronal T1-weighted 2D FSE sequence	550–780	7–15	130–150	61.04–244.14	4	384×256
Sagittal proton density-weighted 2D FSE	760–1800	15–25	130–150	61.04–81.37	3	320×224
Sagittal intermediate-weighted 2D FSE with fat saturation ^a	3000–5000	40–60	130–150	81.37–139.49	3	320×224
Axial intermediate weighted 2D FSE with fat saturation ^a	3000–5000	40–60	130–150	81.37–139.49	4	320×192

MR magnetic resonance; TR repetition time; TE echo time; FOV field of view; BW bandwidth; 2D 2-dimensional; FSE fast spin-echo

^a Frequency-selective fat saturation

^b Acquisition matrix

most proximal aspect of the fracture line in either coronal or sagittal images.

BMEP, cartilage defects or thinning, ipsilateral meniscal pathology, and ligamentous injury were characterized. BMEP was classified as none, mild (involving less than one-third of the femoral condyle, excluding the trochlea), moderate (one-third to two-thirds of the femoral condyle) or severe (greater than two-thirds of the femoral condyle) [20]. Cartilage loss was described according to the Modified Outerbridge classification system with size further characterized as either involving less than or greater than 50 % of the fracture diameter for overlying cartilage pathology, or involving less than or greater than 1 cm in greatest sagittal dimension for adjacent cartilage pathology [21]. The presence of cartilage fracture (defined as chondral separations involving the full thickness of the articular cartilage down to subchondral bone) or delamination as well as a Whole Organ MR Score (WORMS) cartilage score for the entire knee were also recorded [22, 23]. The WORMS cartilage score was determined by deriving the maximum value cartilage score from any compartment, with the exclusion of the compartment containing the FCIF lesion. Femoral condyle deformity was assessed in

initial and follow-up radiographs based on a previously described grading scheme of articular surface bone attrition as none, mild, moderate, or severe [23].

Meniscal morphology was graded using a six-point scale as an expansion of the WORMS classification: 1, normal, 2, intrasubstance degeneration, 3, simple tear, 4, complex tear without deformity, 5, complex tear with deformity, 6, macerated [23]. Maceration was defined as advanced destruction of the meniscus with abnormal signal, deformity, and tear. Associated meniscal extrusion (greater than 3 mm of the medial meniscus or 2 mm of the lateral meniscus) or meniscal root involvement was noted. Ipsilateral and contralateral collateral ligament integrity was described on a four-point scale: 1, normal, 2, intrinsic signal abnormality but normal thickness, 3, thickening and/or incomplete disruption of fibers, and 4, complete tear. Cruciate ligaments were assessed for signal abnormality, thickening, and/or tear.

The presence of synovitis was noted, manifest by joint effusion, diffuse hyperintense signal in the fat pad on T2/proton density/intermediate-weighted fat-suppressed sequences, thickening of the synovial membranes, and intra-articular synovial bands or debris [24, 25]. Muscle atrophy and edema were also documented.

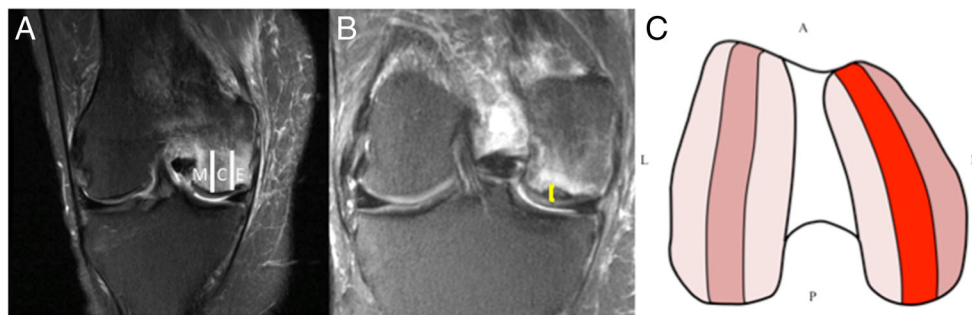


Fig. 3 A 50-year-old female with a 10-day history of right knee pain. **a** The lateral and medial femoral condyles are divided into an external, central, and medial zone in the coronal plane to demonstrate the zonal classification system, here demonstrating a lesion in the external zone. **b** Coronal image of the FCIF measuring 3.5 mm in depth; this measurement

(yellow bracket) is obtained by measuring the distance from the articular surface of the condyle to the proximal-most aspect of the lesion. **c** Schematic representation of location classification modality, with relative frequencies in each section represented by color. Light pink=0–5 %; medium pink=5–10 %; bright red=79.5 %

Statistical analysis

Statistical analysis was performed using IBM SPSS® Statistics 20.0 (IBM, Armonk, NY, USA) and Stata/IC Version 13 (StataCorp, College Station, TX, USA). Descriptive statistics were calculated for each parameter per group, and comparisons of outcome subgroups between predictor variables were performed using a logistic regression model adjusted for age and gender. Statistical significance was defined as $p < 0.05$, and a statistical trend as $p < 0.10$ [26].

Results

Subject characteristics

Baseline characteristics of the study population are summarized in Table 2. A total of 73 subjects, 26 men and 47 women, were included. Mean patient age was 62.81 ± 14.84 years, and mean BMI was 27.74 ± 5.73 . Of note, the female subjects with FCIF were older than the males (mean age 66.28 ± 15.86 compared to 56.54 ± 10.39 , p value < 0.005).

Sixteen of the subjects (two men and 14 women) underwent DXA to assess bone mineral density. Of these, 13 (81.3 %) demonstrated an abnormal DXA result indicating either osteopenia or osteoporosis based on T-scores [27]. The serum 25-hydroxy vitamin D levels were available for 23 patients, with an average concentration of 24.17 ± 14.38 ng/ml (lab normal reference range 30.0–74.0 ng/ml). Of the patients for whom clinical data on intra-articular and systemic steroid use was available, 21.3 % (10/47) had received at least one prior intra-articular steroid injection into the affected knee, and 6.5 % (3/46) were prescribed ongoing oral steroid therapy.

Imaging characteristics

The location and associated imaging characteristics of FCIF lesions are summarized in Table 3. Of the total 73 study patients, three of the patients had an extended field of view MRI, which limited evaluation of the meniscus, cartilage, and ligamentous structures to varying degrees. Two additional patients had undergone previous meniscal resection, precluding evaluation of the ipsilateral meniscus.

Table 2 Demographic and clinical characteristics of the subjects

Parameter	All patients ($n=73$)	Non-TKA** ($n=35$)	TKA** ($n=11$)	p value ^b
Gender*				0.086
Male	35.6 (26/73)	40.0 (14/35)	9.1 (1/11)	
Female	64.4 (47/73)	60.0 (21/35)	90.9 (10/11)	
Age (years) ^a	62.81 ± 14.84	61.17 ± 14.74	67.91 ± 14.05	0.189
Body mass index (kg/m^2) ^a	27.74 ± 5.73	28.48 ± 6.66	29.72 ± 3.82	0.290
Abnormal DXA scan*	81.3 (13/16)	45.5 (5/11)	25.0 (1/4)	0.415
Joint tenderness present*				
Medial	74.5 (35/47)	78.3 (18/23)	75.0 (6/8)	0.908
Lateral	23.4 (11/47)	17.4 (4/23)	37.5 (3/8)	0.362
Both	2.1 (1/47)	13.0 (3/23)	25.0 (2/8)	
Visual analog pain ^a	5.8 ± 1.8	4.2 ± 3.0	4.7 ± 3.0	0.483
Prior ipsilateral knee surgery*	16.7 (8/48)	8.0 (2/25)	16.7 (1/6)	0.555
Prior steroid treatment*	27.7 (13/47)			
Intra-articular	21.3 (10/47)	20.8 (5/24)	0 (0/7)	0.905
Oral	6.4 (3/47)	10.5 (2/23)	0 (0/7)	0.897
Vitamin D level (ng/ml) ^a	18.91 ± 16.24	21.38 ± 16.95	13.50 ± 13.44	0.533
Physical therapy*	65.9 (27/41)	69.6 (16/23)	20.0 (1/5)	0.070
Range of motion at presentation ^a	122.8 ± 15.3	123.5 ± 15.8	109.0 ± 12.9	0.038
Duration symptoms to 1st visit (days) ^a	228.6 ± 407.2	415.0 ± 818.0	1741.9 ± 1765.3	0.053

DXA dual X-ray absorptiometry; TKA total knee arthroplasty

*Values reported as percentage, with number values in parentheses

**Note that in only 46 patients follow-up of more than 6 months or clinical documentation of TKA was available

^a Values reported as mean \pm standard deviation

^b All associations between parameters and outcome (TKA vs. non-TKA) were calculated using a logistic regression model adjusted for age and gender, with the exception of both age and gender which were entered into univariate regression models. Significance defined as $p < 0.05$

The medial femoral condyle was the most common site of insufficiency fracture (65/73, 89.0 %), with the majority of cases involving the central, weight-bearing condylar segment (63/73, 86.3 %) (Figs. 1 and 3). The average size of the insufficiency fracture line measured 12.8 ± 5.0 mm in the coronal plane by 18.8 ± 9.1 mm in the sagittal plane, with an average depth of 3.9 ± 2.3 mm.

BMEP, one of the criteria used to define the presence of insufficiency fracture, was present in all cases to varying degrees. Mild edema was present in 40.8 % (29/71) of cases, moderate edema was present in 28.2 % (20/71) of cases, and severe edema was present in 31.0 % (22/71) of cases.

Cartilage loss was strongly associated with the presence of insufficiency fractures, as overlying full-thickness cartilage loss was present in the majority of cases (75.7 %, 53/70). Additionally, half of the cases demonstrated full-thickness loss of cartilage along the affected condyle adjacent to the insufficiency fracture. The overall maximum cartilage WORMS score for the knee (excluding the compartment with the

insufficiency fracture) was 4.57 ± 1.36 , indicating that the majority of patients had associated large full-thickness cartilage defects in compartments separate from the site of the lesion.

Ipsilateral meniscal pathology was also commonly associated with insufficiency fracture at the knee. Nearly all of the cases (94.1 %, 64/68) demonstrated ipsilateral meniscal pathology on MRI, with over half (54.4 %, 37/68) revealing complete meniscal maceration. By contrast, the contralateral meniscus was much less affected, with 44.3 % (31/70) of cases appearing normal and an additional 28.6 % (20/70) with only mild intrasubstance degeneration.

Imaging in relation to clinical outcomes

A summary of the clinical and imaging outcomes is provided in Tables 2 and 3, respectively. While the orthopedists' clinical notes suggested overall favorable outcomes, with only 4.3 % (2/46) of patients reporting worsened symptoms at time of follow-up, subsequent imaging studies were less optimistic.

Table 3 MRI characteristics of femoral condyle insufficiency fractures

Parameter	All patients (n=73)	Non-TKA** (n=35)	TKA** (n=11)	p value ^b
Location of femoral condyle*				
Medial	89.0 (65/73)	94.3 (33/35)	81.8 (9/11)	0.249
Lateral	11.0 (8/73)	5.7 (2/35)	18.2 (2/11)	
Location of FCIF within condyle*				
External	9.6 (7/73)	14.3 (5/35)	0 (0/11)	0.581
Central	86.3 (63/73)	85.7 (30/35)	90.9 (10/11)	
Mesial	4.1 (3/73)	0 (0/35)	9.1 (1/11)	
Size of fracture band (mm) ^a				
Coronal diameter	12.82 ± 5.02	12.21 ± 3.97	12.55 ± 5.18	0.349
Sagittal diameter	18.83 ± 9.11	18.27 ± 8.55	19.25 ± 9.81	0.345
Depth	3.90 ± 2.27	3.39 ± 1.84	4.1 ± 2.54	0.284
Cartilage quality score ^a				
Overlying cartilage loss	4.33 ± 1.35	4.1 ± 1.6	4.9 ± 0.3	0.244
Overlying cartilage defect size (mm)	2.73 ± 0.72	2.6 ± 0.8	3.0 ± 0	0.082
Adjacent cartilage loss	3.90 ± 1.36	3.6 ± 1.4	4.8 ± 0.4	0.027
WORMS maximum cartilage score ^c	4.57 ± 1.36	4.4 ± 1.3	5.7 ± 0.5	0.042
Meniscus quality score ^a				
Ipsilateral meniscus	4.57 ± 1.84	4.85 ± 1.64	5.1 ± 1.66	0.396
Contralateral meniscus	2.23 ± 1.56	1.85 ± 1.26	3.8 ± 1.81	0.039
Bone marrow edema pattern ^a	2.90 ± 0.85	3.0 ± 0.8	3.0 ± 0.8	0.324
Presence of muscle edema*	16.7 (12/72)	11.8 (4/34)	36.4 (4/11)	0.213
Presence of joint effusion*	89.0 (65/73)	86.8 (33/38)	80.0 (8/10)	0.270

FCIF femoral condyle insufficiency fracture; TKA total knee arthroplasty; WORMS Whole-Organ Magnetic Resonance Imaging Score

*Values reported as percentages, with number values in parentheses

**Note that in only 46 patients follow-up of more than 6 months or TKA was available

^a Values reported as mean±standard deviation

^b All analyses performed with logistic regression model adjusted for age and gender to determine association of parameter with outcome group (TKA vs. non-TKA). Significance defined as $p<0.05$

^c Calculated as worst cartilage lesion score from *unaffected* compartment

Follow-up radiographs were available for 46 of the 73 cases, and demonstrated overall unchanged (30.4 %, 14/46) or worsened (39.1 %, 18/46) deformity of the femoral condyle suggesting progression of the underlying process (Fig. 4). Interestingly, only two of the cases (4.3 %) demonstrated interval healing with resolution of the initial insufficiency fracture (Fig. 5).

A total of 46 patients were included in the outcome analysis of this study after excluding 27 patients who did not have at least 6 months of clinical or radiographic follow-up. For patients included in the outcomes analysis, the average follow-up was 36.1 ± 30.1 months; this included an average of 39.9 ± 32.6 months in the non-progression group and 22.5 ± 11.7 months in the progression group. Ultimately, TKA was performed in an additional 23.9 % (11/46) of these cases. Initial MR imaging findings that were associated with progression to TKA included adjacent and overall cartilage lesions, as well as meniscal tears. Adjacent cartilage defects were significantly more severe in patients who progressed to TKA (adjacent cartilage loss score 3.6 ± 1.4 in the non-TKA group vs. 4.8 ± 0.4 in the TKA group, $p=0.027$) and overall WORMS cartilage scores were higher in the TKA group (4.4 ± 1.3 in the non-TKA group vs. 5.7 ± 0.5 in the TKA group, $p=0.042$). Interestingly, integrity of the contralateral meniscus was also found to be significantly associated with progression as well, with significantly higher meniscal injury scores in the TKA group (1.85 ± 1.26 vs. 3.80 ± 1.81 , $p=0.039$). No significant associations were found with regards to muscle atrophy and edema and risk of FCIF progression.

Clinical variables that were shown to be significantly related to progression of FCIF to TKA included decreased range of motion at time of presentation (123.5 ± 15.8 degrees in the non-TKA group vs. 109.0 ± 12.9 degrees in the TKA group, $p=0.038$). Physical therapy treatment also trended towards significance, with the non-TKA group being more likely to have sought treatment by a physical therapist (69.6 vs. 20.0 %, $p=0.070$). Association of gender with progression trended towards significance, with females tending to have a higher

rate of progression (47.6 vs. 6.7 %, $p=0.086$). Other clinical characteristics, such as presence of abnormal DXA, serum vitamin D level, and visual analog pain scale (VAS), were found to have no significant association with risk of progression to TKA.

Discussion

With this retrospective review of 73 cases, we present to the best of our knowledge the largest case series of MRI-diagnosed FCIF reported to date. In addition to demonstrating the frequent association of FCIF with ipsilateral meniscal pathology and full-thickness cartilage loss, our study demonstrated the frequency of FCIF progression to TKA, and the relative infrequency of demonstrable radiographic healing. Patients with signs of diffuse intra-articular knee pathology, in addition to patients with decreased range of knee motion at presentation, were found to have significantly increased risk of progression to TKA.

To understand the demographics of FCIF, it is worth noting that the majority of patients in our case series were female (64.4 %) and on average were approximately 10 years older than the male patients. Imaging pathology was typically manifest at the central weight-bearing surface of the medial femoral condyle. The high frequency of osteopenia or osteoporosis among our study population, especially in comparison to previously reported rates of osteopenia or osteoporosis in normal adult populations, supports that the impaired bone architecture along the load-bearing surfaces is likely a risk factor for insufficiency fracture [28, 29]. However, the degree of abnormality (osteopenia versus osteoporosis) to predispose to fracture remains controversial [10, 30]. Additionally, in our study, female gender did show a modest association with progression of FCIF to TKA. The basis for this finding is unclear but may be related to differences in bone quality between male and female subgroups, which has previously been demonstrated in normal adult populations [31, 32].

Fig. 4 Natural history of medial femoral insufficiency fracture. Initial intermediate-weighted coronal image in a 50-year-old woman with knee pain (a) demonstrates subchondral insufficiency fracture of the posterior aspect of the medial femoral condyle (arrow). Three months later, follow-up MR (b) demonstrates disease progression with additional site of fracture (asterisk)

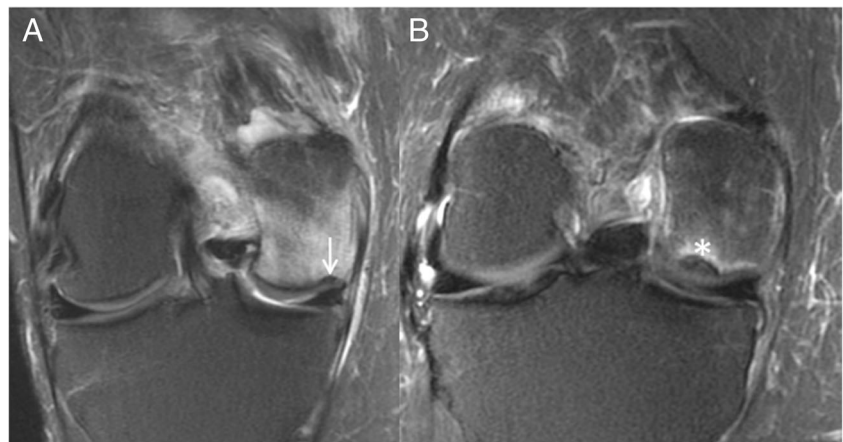
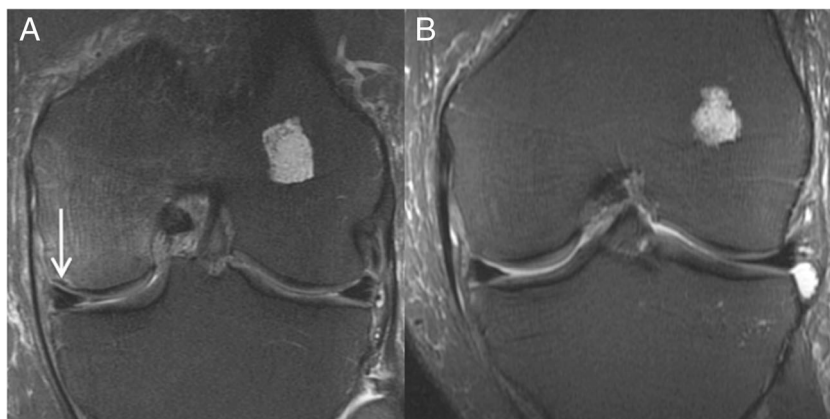


Fig. 5 In contrast to Fig. 4, baseline iw-coronal MR obtained in a 56-year-old male (a) demonstrates medial femoral condyle insufficiency fracture (arrow), while follow-up MR obtained 5 months later (b) demonstrates interval healing. Incidentally shown is a small enchondroma in the lateral femoral condyle



FCIF were also strongly associated with ipsilateral meniscal pathology, as nearly all of the cases (94.1 %) demonstrated ipsilateral meniscal pathology on MRI, and over half (54.4 %) had complete meniscal maceration. Similarly, in our study full thickness cartilage loss was also strongly associated with FCIF lesions, and was found in over 75 % of our cohort. These associations support the hypothesis that altered biomechanical forces at the femoral condyle due to a damaged meniscus and cartilage loss can contribute to the development of an insufficiency fracture.

Interestingly, in our outcomes analysis, diffuse cartilage and meniscal health was significantly associated with risk of progression of FCIF. In particular, adjacent cartilage loss and cartilage WORMS score were significantly higher among the progression group, with overlying cartilage loss also showing a mild association with progression as well. The intimate ties between cartilage health and FCIF have previously been described [6]. Though our study does not establish causality in this relationship between cartilage integrity and lesion progression, it does raise the possibility that FCIF lesions may give rise to more rapid cartilage destruction, as is sometimes seen with similar lesions of the femoral head [33, 34].

Knee functionality was also found to be significantly correlated with tendency for FCIF progression. Specifically, increased knee range of motion at the time of presentation was found to be significantly associated with decreased rate of FCIF progression, and attendance of at least one physical therapy session was similarly associated with a lower progression rate. Though again lacking in the ability to determine causality, our study still raises an interesting question as to whether targeted physical therapy sessions designed to increase knee mobility might ultimately prevent or slow FCIF progression, especially when started early during the course of the disease.

Finally, it is interesting to note that characteristics that we anticipated would significantly influence progression rates of FCIF such as lesion depth or diameter, or BMEP extent (which itself can suggest a diagnosis of FCIF), were not found to have a significant relationship to prognosis [35]. This could

potentially have important implications for how best to interpret these imaging studies, and reinforces the concept that, in cases of FCIF, the integrity of the surrounding cartilage and intra-articular structures has greater prognostic value than characteristics such as fracture diameter and depth. Of note, with only 46 patients included in our outcomes analysis, our study was not sufficiently powered to detect small differences in these variables between progression and non-progression groups, and thus the potential prognostic value of these variables with regards to FCIF lesions remains unclear. Future multi-center studies enrolling greater numbers of patients may be able to provide a more definitive answer as to whether these imaging characteristics have any association with progression risk.

Our study had several limitations. For one, this study was limited by its retrospective design and relatively small sample size, yet to the best of our knowledge this is the largest study that has been published on FCIF lesions. Another inherent limitation in the retrospective design of this study is the lack of consistency among the clinical follow-up protocol. Because of this lack of a standard protocol, patients had varying degrees of clinical and radiographic follow-up after the initial imaging diagnosis. Additionally, there was no established treatment protocol for modalities such as physical therapy, and patients who attended one physical therapy session could potentially be grouped in the same manner as those who attended multiple sessions on a regular basis.

Another limitation posed by the retrospective nature of the study is our inability to include a normal control cohort for comparison purposes in determining relative frequency of certain imaging findings. However, the frequencies reported in our study differ quite notably from those that have been reported in healthy adult cohorts in previously published studies. For one, our reported frequency of osteoporosis/osteopenia (81.3 %) is notably different than that of normal asymptomatic adult populations of similar age ranges, which have previously been reported at 25.8–35 % [28, 29]. Similarly, the rate of BMEP in our study population (100 %, with 31 % having severe BMEP) is notably higher than a

previously published study reporting the frequency of any BMEP in knee MR exams performed in healthy normal adults as 36 % [36]. The previously described rates of cartilage loss and meniscal lesions in normal control populations, reported as 1.0–5.3 and 40 %, respectively, was also significantly less than the frequencies of these lesions in our study cohort (75.7 and 94.1 %, respectively) [36]. We feel that these differences in frequencies effectively demonstrate the relative prevalence of certain imaging findings among FCIF patients.

Finally, though TKA is in itself a verifiable outcome measure, it is not ideal in the sense that the decision to proceed with TKA is based on many factors, some of which are independent of lesion severity. Nevertheless, we feel that this outcome measure generally speaks to the extent of lesion progression in a majority of FCIF patients. Future studies emphasizing a standardized clinical and radiographic follow-up protocol, in addition to a larger sample size, may provide further insight into the prognostic value of FCIF imaging characteristics.

In summary, FCIF are frequently associated with concurrent meniscal and cartilage damage, and coexistence of these abnormalities, along with knee mobility at time of presentation, may be important prognostic indicators of more rapidly progressive lesions. The findings of this study emphasize the importance of close interpretation of MR imaging when dealing with potential FCIF lesions, to establish a proper diagnosis and to consider potential clinical outcomes.

Acknowledgments This study was funded by the National Institute of Arthritis and Musculoskeletal and Skin Diseases, a branch of the National Institutes of Health, under grant no. P50 AR060752.

Conflict of interest The authors declare that they have no conflict of interest.

References

- Ahlback S, Bauer GC, Bohne WH. Spontaneous osteonecrosis of the knee. *Arthritis Rheum*. 1968;11(6):705–33.
- Yamamoto T, Bullough PG. Spontaneous osteonecrosis of the knee: the result of subchondral insufficiency fracture. *J Bone Joint Surg Am*. 2000;82(6):858–66.
- Jones JPJ. Fat embolism, intravascular coagulation, and osteonecrosis. *Clin Orthop Relat Res*. 1993;292:294–308.
- Yamamoto T, Bullough PG. Subchondral insufficiency fracture of the femoral head: a differential diagnosis in acute onset of coxarthrosis in the elderly. *Arthritis Rheum*. 1999;42(12):2719–23.
- Kattapuram TM, Kattapuram SV. Spontaneous osteonecrosis of the knee. *Eur J Radiol*. 2008;67(1):42–8.
- Ramnath RR, Kattapuram SV. MR appearance of SONK-like subchondral abnormalities in the adult knee: SONK redefined. *Skelet Radiol*. 2004;33(10):575–81.
- Yao L, Stanczak J, Boutin RD. Presumptive subarticular stress reactions of the knee: MRI detection and association with meniscal tear patterns. *Skelet Radiol*. 2004;33(5):260–4.
- Mears SC, McCarthy EF, Jones LC, Hungerford DS, Mont MA. Characterization and pathological characteristics of spontaneous osteonecrosis of the knee. *Iowa Orthop J*. 2009;29:38–42.
- Adriaensen ME, Mulhall KJ, Borghans RA, Magill P, Kavanagh EC. Transient osteoporosis of the hip and spontaneous osteonecrosis of the knee: a common aetiology? *Ir J Med Sci*. 2012;181(3):341–3.
- Akamatsu Y, Mitsugi N, Hayashi T, Kobayashi H, Saito T. Low bone mineral density is associated with the onset of spontaneous osteonecrosis of the knee. *Acta Orthop*. 2012;83(3):249–55.
- Breer S, Oheim R, Krause M, Marshall RP, Amling M, Barvencik F. Spontaneous osteonecrosis of the knee (SONK). *Knee Surg Sports Traumatol Arthrosc*. 2013;21(2):340–5.
- Kraenzlin ME, Graf C, Meier C, Kraenzlin C, Friedrich NF. Possible beneficial effect of bisphosphonates in osteonecrosis of the knee. *Knee Surg Sports Traumatol Arthrosc*. 2010;18(12):1638–44.
- Langdown AJ, Pandit H, Price AJ, et al. Oxford medial unicompartmental arthroplasty for focal spontaneous osteonecrosis of the knee. *Acta Orthop*. 2005;76(5):688–92.
- Koshino T. The treatment of spontaneous osteonecrosis of the knee by high tibial osteotomy with and without bone-grafting or drilling of the lesion. *J Bone Joint Surg Am*. 1982;64(1):47–58.
- Jureus J, Lindstrand A, Geijer M, Robertsson O, Tagil M. The natural course of spontaneous osteonecrosis of the knee (SPONK): a 1- to 27-year follow-up of 40 patients. *Acta Orthop*. 2013;84(4):410–4.
- Myers TG, Cui Q, Kuskowski M, Mihalko WM, Saleh KJ. Outcomes of total and unicompartmental knee arthroplasty for secondary and spontaneous osteonecrosis of the knee. *J Bone Joint Surg Am*. 2006;88 Suppl 3:76–82.
- Jans LBO, Jaremko JL, Ditchfield M, Huysse WC, Verstraete KL. MRI differentiates femoral condylar ossification evolution from osteochondritis dissecans. A new sign. *Eur Radiol*. 2011;21:1170–9.
- Campbell WI, Lewis S. Visual analogue measurement of pain. *Ulster Med J*. 1990;59(2):149–54.
- Scuderi GR, Bourne RB, Noble PC, Benjamin JB, Lonner JH, Scott WN. The new knee society knee scoring system. *Clin Orthop Relat Res*. 2012;470(1):3–19.
- Filardo G, Kon E, Tentoni F, et al. Anterior cruciate ligament injury: post-traumatic bone marrow oedema correlates with long-term prognosis. *Int Orthop* 2015.
- Outerbridge RE. The etiology of chondromalacia patellae. *J Bone Joint Surg (Br)*. 1961;43-B:752–7.
- Johnson-Nurse C, Dandy DJ. Fracture-separation of articular cartilage in the adult knee. *J Bone Joint Surg (Br)*. 1985;67(1):42–3.
- Peterfy CG, Guermazi A, Zaim S, et al. Whole-organ magnetic resonance imaging score (WORMS) of the knee in osteoarthritis. *Osteoarthr Cartil*. 2004;12(3):177–90.
- Hunter DJ, Guermazi A, Lo GH, et al. Evolution of semi-quantitative whole joint assessment of knee OA: MOAKS (MRI Osteoarthritis Knee Score). *Osteoarthr Cartil*. 2011;19:990–1002.
- Atukorala I, Kwok CK, Guermazi A, et al. Synovitis in knee osteoarthritis: a precursor of disease? *Ann Rheum Dis* 2014:1–6.
- Taneja AK, Miranda FC, Braga CAP, et al. MRI features of the anterolateral ligament of the knee. *Skelet Radiol*. 2015;44:403–10.
- Kanis J, on behalf of the World Health Organization Scientific Group. World Health Organization Scientific Group on the Assessment of Osteoporosis at Primary Health Care Level. <http://www.who.int/chp/topics/Osteoporosis.pdf>. 2007. April 10. 2015.
- Lee CNY, Lam SC, Tsang AYK, Ng BTY, Leung JCY, Chong ACY. Preliminary investigation on prevalence of osteoporosis and osteopenia: should we tune our focus on healthy adults? *Jpn J Nurs Sci*. 2014:1–17.

29. Häussler B, Gothe H, Göll D, Glaeske G, Pientka L, Felsenberg D. Epidemiology, treatment and costs of osteoporosis in Germany—the BoneEVA study. *Osteoporos Int.* 2007;18:77–84.
30. Nelson FR, Craig J, Francois H, Azuh O, Oyetakin-White P, King B. Subchondral insufficiency fractures and spontaneous osteonecrosis of the knee may not be related to osteoporosis. *Arch Osteoporos* 2014;9(1):2014 Sep 19.
31. Dalzell N, Kaptoge S, Morris N, et al. Bone micro-architecture and determinants of strength in the radius and tibia: age-related changes in a population-based study of normal adults measured with high-resolution pQCT. *Osteoporos Int.* 2009;20:1683–94.
32. Mueller TL, van Lenthe GH, Stauber M, Gratzke C, Eckstein F, Müller R. Regional, age and gender differences in architectural measures of bone quality and their correlation to bone mechanical competence in the human radius of an elderly population. *Bone.* 2008;45:882–91.
33. Yamamoto T, Takabatake K, Iwamoto Y. Subchondral insufficiency fracture of the femoral head resulting in rapid destruction of the hip joint: a sequential radiographic study. *AJR Am J Roentgenol.* 2002;178(2):435–7.
34. Yamamoto T, Bullough PG. The role of subchondral insufficiency fracture in rapid destruction of the hip joint: a preliminary report. *Arthritis Rheum.* 2000;43(11):2423–7.
35. Lecouvet FE, van de Berg BC, Maldague BE, et al. Early irreversible osteonecrosis versus transient lesions of the femoral condyles: prognostic value of subchondral bone and marrow changes on MR imaging. *AJR Am J Roentgenol.* 1998;170(1):71–7.
36. Pan J, Bialat JB, Joseph T, et al. Knee cartilage T2 characteristics and evolution in relation to morphologic abnormalities detected at 3-T MR imaging: a longitudinal study of the normal control cohort from the Osteoarthritis Initiative. *Radiology.* 2011;261:507–15.