

UCLA

UCLA Previously Published Works

Title

Trans-synaptic degeneration of the optic radiation from optic nerve atrophy

Permalink

<https://escholarship.org/uc/item/9fn7d2hw>

Journal

Radiology Case Reports, 16(4)

ISSN

1930-0433

Authors

Kihira, Shingo

Arnold, Anthony C

Pawha, Puneet S

et al.

Publication Date

2021-04-01

DOI

10.1016/j.radcr.2021.01.017

Copyright Information

This work is made available under the terms of a Creative Commons Attribution-NonCommercial-NoDerivatives License, available at

<https://creativecommons.org/licenses/by-nc-nd/4.0/>

Peer reviewed

Available online at www.sciencedirect.com

ScienceDirect

journal homepage: www.elsevier.com/locate/radcr

Case Report

Trans-synaptic degeneration of the optic radiation from optic nerve atrophy ☆,☆☆

Shingo Kihira, MD^a, Anthony C. Arnold, MD^b, Puneet S. Pawha, MD^a,
Pablo Villablanca, MD^c, Kambiz Nael, MD^{c,*}

^aDepartment of Radiology, Icahn School of Medicine at Mount Sinai, New York, NY, USA

^bDepartment of Ophthalmology, David Geffen School of Medicine at UCLA, Los Angeles, CA, USA

^cDepartment of Radiological Sciences, David Geffen School of Medicine at University of California Los Angeles, CA, USA

ARTICLE INFO

Article history:

Received 10 November 2020

Revised 5 January 2021

Accepted 11 January 2021

Keywords:

Optic nerve atrophy

Optic radiation

Trans-synaptic degeneration

ABSTRACT

Forty-seven-year-old woman with 5-year history of progressive decreased left eye vision. Optical coherence tomography showed optic nerve atrophy (left > right) and brain MRI revealed T2 hyperintense signal along the course of left optic radiations. We present a case of a trans-synaptic degeneration of the optic radiation in a patient with confirmed optic atrophy. Trans-synaptic degeneration of the optic radiation without associated infarct or inflammatory disease has not been reported before in patients with optic atrophy.

© 2021 The Authors. Published by Elsevier Inc. on behalf of University of Washington.

This is an open access article under the CC BY-NC-ND license

(<http://creativecommons.org/licenses/by-nc-nd/4.0/>)

Introduction

Trans-synaptic degeneration typically occurs following damage to the cerebral tissue. Axonal degeneration in the terminal direction following injury is classified as anterograde degeneration, also known as Wallerian degeneration [1,2]. Retinal nerve fiber layers consist of retinal ganglion cell axons, which form the optic nerves, conjoining at the optic chiasm, coursing through the optic tracts, and synapse at the lateral geniculate nucleus. The axons from the cell bodies in the lateral geniculate nucleus form the optic radiation and terminate at the visual cortex of the occipital lobes.

Damage along the visual pathway can lead to visual defects that can help localize the lesion. For example, a lesion in the optic chiasm will affect both eyes leading to bipolar hemianopsia. A lesion in the optic tract can lead to homonymous hemianopia of the contralateral visual field. A lesion in the optic nerve can lead to ipsilateral blurred vision or visual loss.

Case Report

A 47-year-old woman with no known past medical history besides recurrent migraines presented with 5-year history of progressive decreased left eye vision. Patient endorsed no recent fever, altered mental status, or other neurologic symptoms besides stated above. No history of IV drug abuse or recent infection. Her metabolic profile was within normal

☆ Grant Support: None.

☆☆ Conflicts of Interest: None.

* Corresponding author.

E-mail address: kambiznael@gmail.com (K. Nael).

<https://doi.org/10.1016/j.radcr.2021.01.017>

1930-0433/© 2021 The Authors. Published by Elsevier Inc. on behalf of University of Washington. This is an open access article under the CC BY-NC-ND license (<http://creativecommons.org/licenses/by-nc-nd/4.0/>)

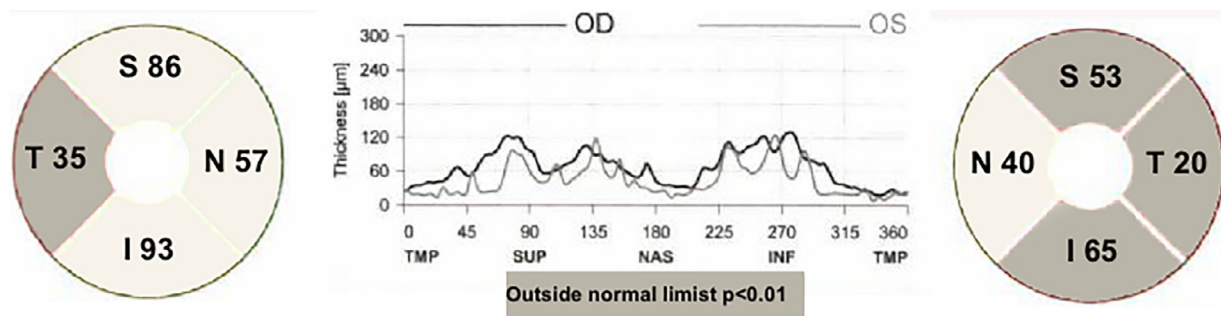


Fig. 1 – Optical coherence tomography shows decreased thickness (numbers in microns) of the peripapillary nerve fiber layer, consistent with left optic atrophy. There is also thinning of the temporal region of the right optic nerve.

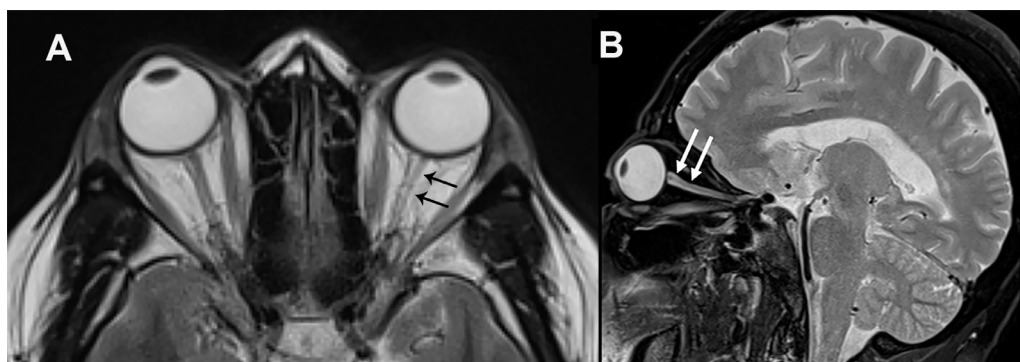


Fig. 2 – MR images of the orbits. (A) Axial T2-weighted image (repetition time msec/echo time msec, 6000/60) shows small caliber of left optic nerve (black arrows) in comparison to the right optic nerve. (B) Sagittal fat-suppressed T2-weighted image (3000/66) through the left orbit shows small caliber of left optic nerve and increased fluid signal within the perioptic nerve sheath (white arrows).

limits. Notably, patient endorses history of head injury at age 19, but does not clearly remember if she experienced orbital trauma. Optical coherence tomography (OCT) showed thinning of the peripapillary nerve fiber layer consistent with optic nerve atrophy (left > right; Fig. 1). MRI of the brain and orbits were performed. Axial and sagittal T2 MRI shows increased fluid signal within the left perioptic nerve sheath suggestive of volume loss (Fig. 2a, b), confirming OCT findings of left-sided optic atrophy. Axial MRI of the brain revealed T2 hyperintense signal along the course of left optic radiations (Fig. 3). Wallerian degeneration indicates an antegrade distal degeneration of the axon and its myelin sheath caused by a more proximal neural insult. It is often seen on MRI as a T2 hyperintensity suggestive of gliosis.

Discussion

This patient presented with 5-year history of progressive decreased left eye vision with OCT confirming left-sided optic nerve atrophy. Subsequent MR of the orbits confirmed left-sided optic atrophy, and MR brain showed T2 prolongation along the course of the left optic radiations. Together, these

findings are suggestive of trans-synaptic degeneration of the optic radiation from optic nerve atrophy.

Prior studies have demonstrated retrograde degeneration of neurons linking optic nerve atrophy and occipital lobe damage [3,4]. Furthermore, Jindahra et al. [5] demonstrated retrograde degeneration of the optic nerve fibers following a stroke in the occipital lobe. Multiple sclerosis-related injury to the occipital lobe or along the visual pathway has also been linked to retrograde degeneration leading to optic nerve atrophy [6]. However, trans-synaptic degeneration of the optic radiation without associated infarct or inflammatory disease has not been reported in patients with optic atrophy, making this case unusual and challenging.

Aside from the diagnosis of trans-synaptic degeneration, differential diagnosis for T2 prolongation of periventricular white matter include leukomalacia, prior infarct, and demyelinating process such as multiple sclerosis. However, there was no MR evidence of ischemic injury or demyelinating disease. Furthermore, the clinical history of progressive decreased left eye vision, confirmed atrophy of the left optic nerve by OCT, and T2 prolongation along the course of left optic radiations altogether favor the diagnosis for trans-synaptic degeneration of the optic radiation over other differentials.

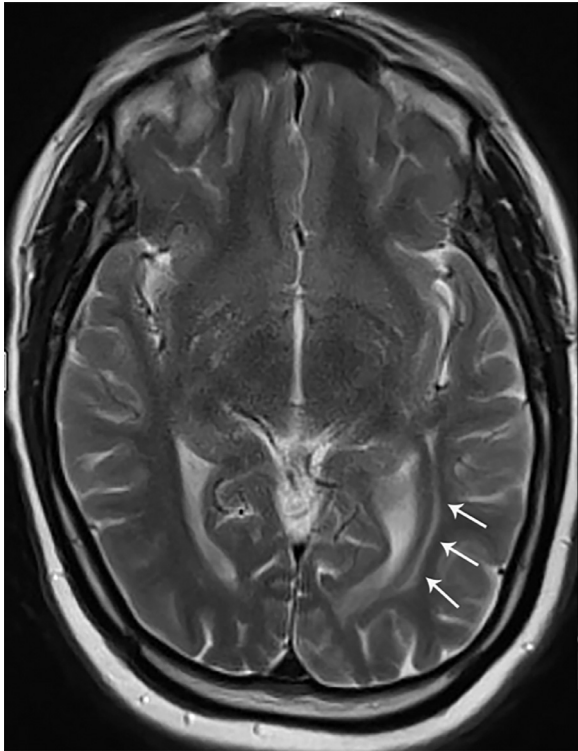


Fig. 3 – Axial T2-weighted image (repetition time ms/echo time msec 3140/105) shows hyperintense signal along the course of the left optic radiations (arrows) suggestive of trans-synaptic degeneration.

Conclusion

This is an unusual case of a trans-synaptic degeneration of the optic radiation in a patient with optic atrophy. It is important

to consider trans-synaptic degeneration from optic atrophy in the differential diagnosis as this can dictate further work-up and management.

Ethical standards

This study was approved by the institutional Ethics Committee. Informed consent was waived under an approved protocol.

REFERENCES

- [1] Coleman M. Axon degeneration mechanisms: commonality amid diversity. *Nat Rev Neurosci* 2005;6:889–98. doi:[10.1038/nrn1788](https://doi.org/10.1038/nrn1788).
- [2] Saxena S, Caroni P. Mechanisms of axon degeneration: from development to disease. *Prog Neurobiol* 2007;83:174–91. doi:[10.1016/j.pneurobio.2007.07.007](https://doi.org/10.1016/j.pneurobio.2007.07.007).
- [3] Jindahra P, Petrie A, Plant GT. Retrograde trans-synaptic retinal ganglion cell loss identified by optical coherence tomography. *J Neurol* 2009;132:628–34. doi:[10.1093/brain/awp001](https://doi.org/10.1093/brain/awp001).
- [4] Cowey A, Alexander I, Stoerig P. Transneuronal retrograde degeneration of retinal ganglion cells and optic tract in hemianopic monkeys and humans. *J Neurol* 2011;134:2149–57. doi:[10.1093/brain/awr125](https://doi.org/10.1093/brain/awr125).
- [5] Jindahra P, Petrie A, Plant GT. The time course of retrograde trans-synaptic degeneration following occipital lobe damage in humans. *J Neurol* 2012;135:534–41. doi:[10.1093/brain/awr324](https://doi.org/10.1093/brain/awr324).
- [6] Puthenparampil M, Federle L, Poggiali D, Mianze S, Signori A, Pilotto E, et al. Trans-synaptic degeneration in the optic pathway. A study in clinically isolated syndrome and early relapsing-remitting multiple sclerosis with or without optic neuritis. *PLoS One* 2017;12. doi:[10.1371/journal.pone.0183957](https://doi.org/10.1371/journal.pone.0183957).