

UC Davis

UC Davis Previously Published Works

Title

Diagnosis, treatment, and outcome of and risk factors for ophthalmic disease in leopard geckos (*Eublepharis macularius*) at a veterinary teaching hospital: 52 cases (1985-2013).

Permalink

<https://escholarship.org/uc/item/9f3970kv>

Journal

Journal of the American Veterinary Medical Association, 252(3)

ISSN

0003-1488

Authors

Wiggans, K Tomo
Sanchez-Migallon Guzman, David
Reilly, Christopher M
et al.

Publication Date

2018-02-01

DOI

10.2460/javma.252.3.316

Peer reviewed

Diagnosis, treatment, and outcome of and risk factors for ophthalmic disease in leopard geckos (*Eublepharis macularius*) at a veterinary teaching hospital: 52 cases (1985–2013)

K. Tomo Wiggins DVM, M_{ENG}

David Sanchez-Migallon Guzman LV, MS

Christopher M. Reilly DVM, MAS

Claire Vergneau-Grosset DVM

Philip H. Kass DVM, PhD

Steven R. Hollingsworth DVM

From the Veterinary Medical Teaching Hospital (Wiggins) and Departments of Medicine and Epidemiology (Sanchez-Migallon Guzman, Vergneau-Grosset), Pathology, Microbiology, and Immunology (Reilly), Population Health and Reproduction (Kass), and Surgical and Radiological Sciences (Hollingsworth), School of Veterinary Medicine, University of California-Davis, Davis, CA 95616. Dr. Wiggins' present address is Bay Area Animal Eye Care, 2100 Monument Blvd, Ste 7, Pleasant Hill, CA 94523. Dr. Reilly's present address is Insight Veterinary Specialty Pathology, 6902A Bennett Ave, Austin, TX 78752. Dr. Vergneau-Grosset's present address is Université de Montréal, Companion Animal Hospital, 3200 rue Sicotte, St-Hyacinthe, QC J2S 2M2, Canada.

Address correspondence to Dr. Hollingsworth (srhollingsworth@ucdavis.edu).

OBJECTIVE

To describe diagnosis, treatment, and outcome of and risk factors for ophthalmic disease in leopard geckos (*Eublepharis macularius*) evaluated at a veterinary teaching hospital.

DESIGN

Retrospective case series.

ANIMALS

112 of 144 (78%) leopard geckos that were evaluated at a veterinary teaching hospital in January 1985 through October 2013 and for which sufficient medical record information was available.

PROCEDURES

Information from medical records was used to identify leopard geckos with ophthalmic disease, characterize cases, and determine risk factors for the presence of ophthalmic disease.

RESULTS

Of the 112 leopard geckos, 52 (46%) had ophthalmic disease (mainly corneal or conjunctival disease). Female geckos were less likely to have ophthalmic disease, and there was a positive association between increasing age and ophthalmic disease. Use of a paper towel substrate, absence of any heat source, and lack of vitamin A supplementation were positively associated with a diagnosis of ophthalmic disease. Head dysecdysis was the only concurrent disorder significantly associated with ophthalmic disease. At necropsy, 5 affected leopard geckos had squamous metaplasia of the conjunctivae.

CONCLUSIONS AND CLINICAL RELEVANCE

Results indicated that ophthalmic disease is a common finding in leopard geckos. The cause of ocular surface disease in leopard geckos may be multifactorial, and hypovitaminosis A may be an important risk factor. Although animals receiving supplemental vitamin A were less likely to have ophthalmic disease, further understanding is required regarding the metabolism of and nutritional requirements for vitamin A in leopard geckos. (*J Am Vet Med Assoc* 2018;252:316–323)

Leopard geckos (*Eublepharis macularius*) are reptiles belonging to the family Eublepharidae. Leopard geckos are distinguished from other geckos by the presence of moveable eyelids and the absence of a spectacle. This nocturnal insectivorous species is native to the desert regions of Pakistan, Afghanistan, and India.¹ Leopard geckos are popular indoor companion animals and have been used to investigate reptile wound healing and tissue regeneration^{2–6} as well as reproduction.^{7–11}

Excluding case reports, there are few large-scale studies^{12–14} of ophthalmic disease in captive reptiles. Studies and case reports of disease in leopard geckos in the peer-reviewed veterinary medical literature have so far been limited to dermatologic,¹⁵ gastro-

intestinal,^{16,17} and reproductive disease.¹⁸ To the authors' knowledge, there are no peer-reviewed reports of the types and frequency of diagnosis of ophthalmic disease in leopard geckos. The purpose of the study reported here was to describe the diagnosis, treatment, and outcome of and risk factors for ophthalmic disease in leopard geckos evaluated at a veterinary teaching hospital.

Materials and Methods

Case selection

The electronic medical records system of the William R. Pritchard Veterinary Medical Teaching Hospital of the University of California-Davis was searched for records of all leopard geckos evaluated by the Companion Exotic Animal Medicine and Surgery Service in January 1985 through October 2013. Medical records that had insufficient information regarding history, physical ex-

ABBREVIATIONS

CI Confidence interval

amination findings, clinical diagnoses, and treatment recommendations were excluded from the study.

Medical records review

All leopard geckos had received a complete physical examination by a clinician (faculty or resident-in-training) as part of the evaluation. For each leopard gecko, age, sex (male or female), husbandry (including enclosure size, enclosure substrate, heating source, temperature monitoring, humidity source, humidity monitoring, and UV light source), diet (including prey type [mealworm, waxworm, unspecified type of worm, mice, and cricket] and nutritional supplementation in the form of prey dusting, gut loading, or both), physical examination findings (including signs of ophthalmic disease; weight and body condition score; dehydration; signs of dysecdysis on the head, body, and limbs; missing digits or nails; stomatitis; plugged hemipenes; and musculoskeletal abnormalities), results of diagnostic testing (including a CBC, plasma biochemical panel, histologic examination of biopsy specimens, and, when available, necropsy results), medical treatment, and husbandry modifications were recorded. Enclosure size categories (in gallons) included not indicated or insufficient information, < 10, ≥ 10 to < 20, ≥ 20 to < 30, ≥ 30 to < 40, and ≥ 40. Enclosure substrate categories included unknown or not specified, sand, wood chips, peat moss, paper or cloth towel, newspaper, and reptile carpet or felt. Heating source types included no heating source, a heating lamp, a heating pad, a combination of a heating lamp and pad, heating log or rock, and a combination of a heating log or rock with a heating lamp or pad. The UV light source categories included none, a UV light that was not changed every 6 months (or the changing interval was unknown), and a UV light that was changed every 6 months. When available, results of an ophthalmic examination performed by a board-certified veterinary ophthalmologist or resident-in-training were recorded. Leopard geckos were classified as having or not having ophthalmic disease on the basis of their initial examination findings. For leopard geckos with ophthalmic disease, follow-up intervals and outcome based on a repeated physical and ophthalmic examination were recorded; outcomes included no improvement, partial improvement, or complete resolution of ophthalmic clinical signs.

Diets were classified on the basis of their vitamin A content. Supplements and prey containing any amount of vitamin A included carnivore diet protein supplement,^a chicken starter,^b kitten pelleted food (unspecified brands), reptile multivitamin and mineral supplements including vitamin A,^{c-e} silkworms,¹⁹ and trout chow (unspecified brands). Silkworms possess vitamin A intrinsically, whereas the other food products (carnivore diet protein supplement, chicken starter, kitten pelleted food, reptile multivitamin and mineral supplements, and trout chow) were manufactured with products containing vitamin A. Supplements containing no vitamin A included carrots,^f in-

sect diet with no vitamin A,^g and reptile multivitamin and mineral supplements with no vitamin A.^{h-k} When data about vitamin supplementation were missing in the records, owners were contacted via telephone or email to obtain complete information. On the basis of the diet, individual animals were then classified as receiving or not receiving any vitamin A supplementation.

Data and statistical analysis

Leopard geckos were considered affected with ophthalmic disease when an abnormality was noted on general physical examination or on consultation with the ophthalmology service, or when a clinical diagnosis of ophthalmic disease was recorded in the medical record. Diagnoses for all leopard geckos regarding nonophthalmic disease were categorized into dermatologic, gastrointestinal, musculoskeletal, reproductive, or traumatic disease; those without a specific diagnosis in the medical record were considered to have an open diagnosis. Among animals for which follow-up information was available, resolution of clinical signs was determined to be absent, partial, or complete on the basis of physical examination findings at a recheck examination. Univariate logistic regression analysis¹ was performed on data regarding age, sex, husbandry variables, diet, vitamin A supplementation, physical examination findings, and concurrent nonophthalmic diseases or disorders between leopard geckos with and without ophthalmic disease. Age in years was analyzed as a continuous variable, and ORs pertained to a 1-year increase. Body weight (kg) was also analyzed as a continuous variable. When available, results of CBCs and plasma biochemical panels for leopard geckos with and without ophthalmic disease were also compared via univariate logistic regression analysis.¹ A value of $P \leq 0.05$ was considered significant. Logistic regression results are reported as ORs with 95% CIs. Descriptive statistics are reported as medians, means, and ranges.

Results

During the 28.8-year period of interest, 144 leopard geckos were evaluated at the teaching hospital. Only 112 (78%) leopard geckos had sufficient information in their medical records to be included in the study. Of these 112 animals, 52 (46%) had ophthalmic disease. Ophthalmic disease was unilateral in 17 (33%) leopard geckos and bilateral in 35 (67%) leopard geckos. Twenty-five of 52 (48%) leopard geckos were referred to the ophthalmology service for consultation. At the evaluation, all 52 leopard geckos had blepharospasm, and 40 (77%) had ocular discharge. Of the 40 leopard geckos with ocular discharge, 31 (78%) had solid or dried crusted discharge, 6 (15%) had tenacious caseous discharge, and 3 (8%) had mucoid discharge (**Figure 1**). Of the 52 leopard geckos, 6 (12%) had a diagnosis of conjunctivitis, 12 (23%) had a diagnosis of nonulcerative keratitis, 12 (23%) had a diagnosis of ulcerative

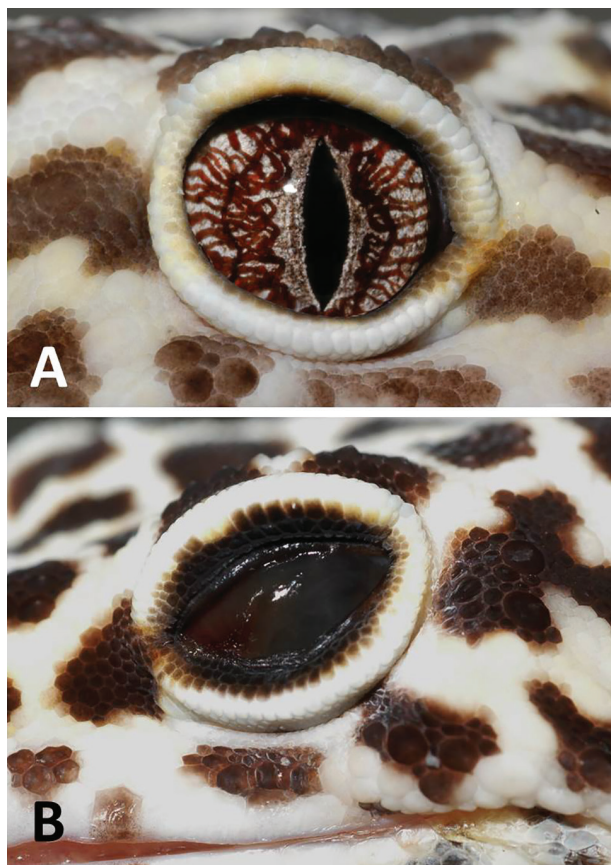


Figure 1—Photographs to illustrate the appearance of a normal leopard gecko eye (A) and a leopard gecko eye with dried crusted discharge overlying the entire corneal surface (B). The animal with ophthalmic disease also has dysecdysis along the lower lip.

keratitis, 3 (6%) had a diagnosis of anterior uveitis, and 7 (13%) had a diagnosis of other ocular disease (all unilateral; irregular third eyelid [$n = 1$], inferior eyelid defect [1], phthisis bulbi [3], and shallow anterior chamber [2]). Ophthalmic findings in leopard geckos with keratitis included corneal surface irregularity ($n = 17$), corneal neovascularization (13), corneal edema (8), and corneal fibrosis (5); 14 leopard geckos had 2 or more concurrent findings associated with keratitis. Ophthalmic findings in leopard geckos with anterior uveitis included aqueous flare ($n = 2$), anterior chamber fibrin (2), hyphema (1), and hypopyon (1); 2 leopard geckos had 2 or more concurrent findings associated with anterior uveitis. Two leopard geckos had both ulcerative keratitis and anterior uveitis. For the 52 leopard geckos with ophthalmic disease, results of a CBC and plasma biochemical panel were available for 9 and 10 animals, respectively. For the 60 leopard geckos not affected with ophthalmic disease, results of a CBC and plasma biochemical panel were available for 6 and 7 animals, respectively.

The median ages of leopard geckos with and without ophthalmic disease were 5 years (mean age, 4 years; range, < 1 to 14 years) and 3 years (mean age,

2 years; range, < 1 to 10 years), respectively. For each 1-year increase in age, the odds of having ophthalmic disease increased by 16% (OR, 1.16; 95% CI, 1.03 to 1.32; $P = 0.015$). Among the 52 leopard geckos with ophthalmic disease, there were 26 (50%) males and 20 (38%) females; 6 (12%) leopard geckos were of unknown sex. Among the 60 leopard geckos without ophthalmic disease, there were 14 (23%) males and 31 (52%) females; 15 (25%) leopard geckos were of unknown sex. Compared with males, females were less likely to have ophthalmic disease (OR, 0.35; 95% CI, 0.15 to 0.82; $P = 0.016$).

No leopard geckos were specifically reported to be housed with another leopard gecko. Various substrate types were used in the leopard geckos' housing (**Table 1**). Of all husbandry variables assessed (enclosure type, enclosure substrate, heat source, temperature monitoring, humidity source, humidity monitoring, and UV light source), there was a significantly greater odds of ophthalmic disease in leopard geckos that were housed on a paper towel substrate (OR, 8.89; 95% CI, 2.29 to 34.43; $P = 0.002$) and without any heat source (OR, 6.55; 95% CI, 1.17 to 36.61; $P = 0.032$). Data regarding dietary vitamin A content were obtained for 88 of the 112 (79%) leopard geckos. Those 88 leopard geckos included 45 (51%) with ophthalmic disease and 43 (49%) without ophthalmic disease. Presence of vitamin A in the diet was significantly and negatively associated with ophthalmic disease (OR, 0.11; 95% CI, 0.023 to 0.52; $P = 0.005$). No other diet component (prey type) or supplementation (prey dusting or gut loading) was a risk factor for ophthalmic disease.

Leopard geckos with head dysecdysis were more likely to have concurrent ophthalmic disease (OR, 3.02; 95% CI, 1.28 to 7.11; $P = 0.012$). There was no significant association between ophthalmic disease and body weight, body condition score, dehydration, dysecdysis of the body or limbs, missing nails or digits, plugged hemipenes, stomatitis, or musculoskeletal abnormalities. Furthermore, there was no significant difference in the CBC and plasma biochemical panel values between leopard geckos with and without ophthalmic disease for which data were available. Ophthalmic disease was less likely to be found in leopard geckos with gastrointestinal (OR, 0.31; 95% CI, 0.12 to 0.81; $P = 0.017$) and reproductive disease (OR, 0.08; 95% CI, 0.01 to 0.63; $P = 0.016$). There was no significant association between the presence of ophthalmic disease and a concurrent diagnosis of dermatologic, musculoskeletal, or traumatic disease as well as an open diagnosis.

Topical treatments for the 52 affected leopard geckos included ofloxacin ($n = 20$ [38%]), artificial tear supplement (18 [35%]), neomycin-polymyxin-gramicidin (6 [12%]), ciprofloxacin (4 [8%]), cefazolin (2 [4%]), *N*-acetylcysteine (1 [2%]), chloramphenicol (1 [2%]), gentamicin (1 [2%]), diclofenac (1 [2%]), natamycin (1 [2%]), and neomy-

Table 1—Housing substrate types (as recorded in medical records) for 52 leopard geckos with ophthalmic disease and 60 leopard geckos without ophthalmic disease that were evaluated at a veterinary teaching hospital in January 1985 through October 2013.

Substrate	No. of leopard geckos with ophthalmic disease (%)	No. of leopard geckos without ophthalmic disease (%)
Sand	21 (40)	40 (67)
Paper towel	14 (27)	3 (5)
Reptile carpet	10 (19)	10 (17)
Peat moss	2 (4)	0 (0)
Wood chips	2 (4)	3 (5)
Unknown or not specified	2 (4)	3 (5)
Newspaper	1 (2)	1 (2)

cin-polymyxin-bacitracin (1 [2%]). Systemic treatments for affected animals included ceftazidime (n = 13 [25%]), meloxicam (11 [21%]), trimethoprim-sulfamethoxazole (5 [10%]), enrofloxacin (3 [6%]), tramadol (3 [6%]), metronidazole (2 [4%]), sucralate (2 [4%]), and itraconazole (1 [2%]). Among the 40 leopard geckos with ocular discharge, 12 (30%) underwent irrigation of the discharge with eyewash or balanced salt solution, 9 (23%) underwent manual removal of the discharge, and 9 (23%) underwent both manual removal and irrigation of the discharge. Ten (25%) of the leopard geckos with ocular discharge did not undergo any attempts to manually remove or irrigate the discharge. Manual removal of the discharge was accomplished with custom eyelid retractors fashioned from paper clips (**Figure 2**) held by an assistant while the discharge was removed with straight or curved Harms tying forceps or jeweler's forceps. Of those that underwent some form of discharge removal, the outcome of the procedure was recorded in 12 cases; the cornea was completely visualized in 9 cases, was partially visualized in 2 cases, and could not be visualized in 1 case.

For 43 of the 52 (83%) leopard geckos affected by ophthalmic disease, specific recommendations regarding changes to husbandry were noted in the patient's discharge instructions. Most owners of affected geckos received recommendations regarding increasing humidity (n = 39 [75%]), which included soaking (29 [56%]), provision of a humidity box (22 [42%]), and misting (8 [15%]). Additional recommendations included changing the enclosure substrate to paper towels, newspaper, or artificial turf (n = 21 [40%]), provision of a UV light source (17 [33%]), more strict regulation of light cycles (2 [4%]), improvement in enclosure temperature monitoring (18 [35%]), improvement in enclosure humidity monitoring (6 [12%]), gut loading (19 [37%]) and dusting (15 [29%]) of prey with vitamin and mineral supplements, provision of assisted feeding (23 [44%]), and provision of increased variety of prey (9 [17%]).

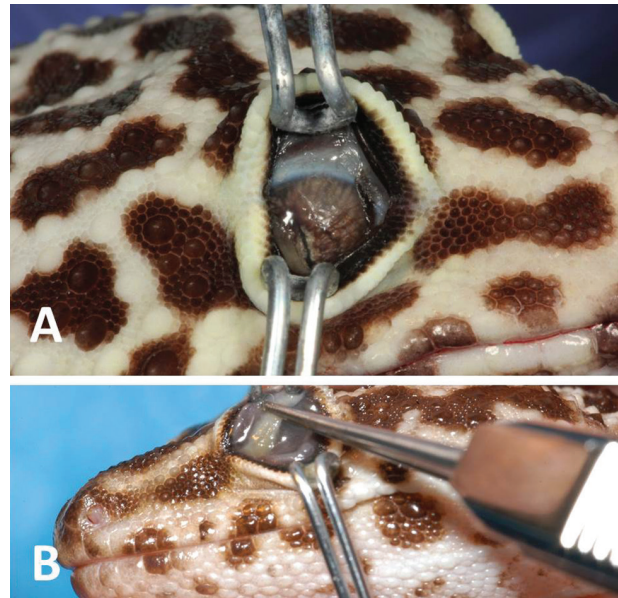


Figure 2—Photographs depicting the use of eyelid specula fashioned from standard paper clips to facilitate visualization and removal of ocular debris (A) and to illustrate the use of straight Harms tying forceps to grasp and remove solid ocular debris (B) in leopard geckos with ophthalmic disease. Each affected animal is restrained by one assistant, and the eyelids are retracted by a second assistant.

Follow-up information was available for 28 of the 52 (54%) leopard geckos with ophthalmic disease. Median follow-up time was 36 days (mean follow-up time, 149 days; range, 6 to 1,577 days). On physical examination, 14 animals had partial resolution of clinical signs with a median time of 25 days (mean, 40 days; range, 8 to 239 days); 4 animals had complete resolution of clinical signs with a median time of 54 days (mean, 130 days; range, 20 to 390 days). Ten animals had no improvement in clinical signs during the follow-up period, including 1 leopard gecko with anterior uveitis.

Necropsy was performed in 9 leopard geckos with ophthalmic disease (2 animals with ulcerative keratitis, 6 animals with nonulcerative keratitis, and 1 animal with nonulcerative keratitis and uveitis) and 3 geckos without ophthalmic disease. In 1 patient, antemortem biopsy of crusted ocular discharge was also performed.

For 5 of the affected leopard geckos, necropsy revealed histologic changes consistent with hypovitaminosis A, including squamous metaplasia, hyperplasia, and hyperkeratosis of epithelial-lined structures, including conjunctiva (n = 5), cloaca (1), ureter (1), respiratory epithelium (1), lacrimal gland (1), and nasal cavity (1; **Figure 3**). The leopard gecko with nonulcerative keratitis and uveitis was among the patients with squamous metaplasia of the conjunctiva, but no systemic abnormalities were noted to suggest nonophthalmic causes for the uveitis. Eyes of the remaining 4 geckos with ophthalmic disease were not examined histologically. Of the 9 affected geckos that were nec-

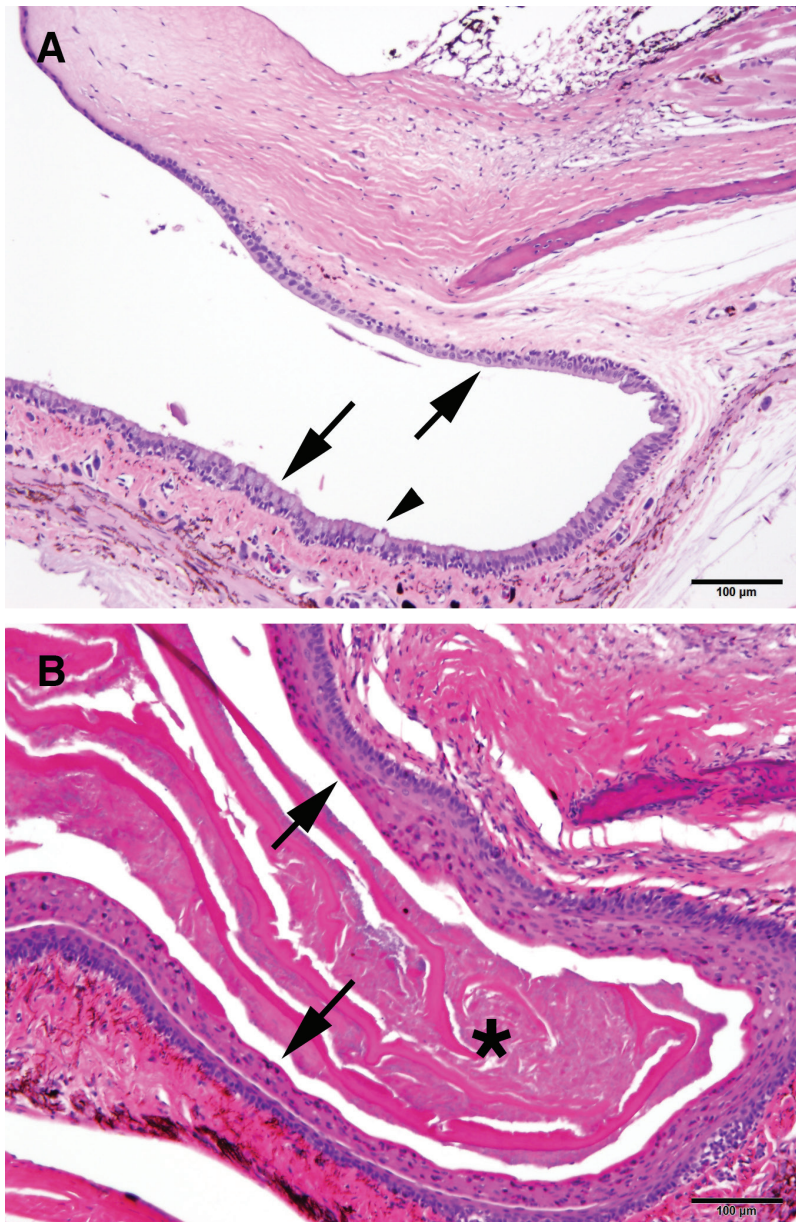


Figure 3—Photomicrographs of sections of the conjunctival fornix of a leopard gecko that had no clinical evidence of ophthalmic disease (A) and that of a leopard gecko with squamous metaplasia (B). In panel A, notice the presence of stratified cuboidal to columnar epithelium lining the fornix (arrows) and an example of a goblet cell (arrowhead). H&E stain; bar = 100 µm. In panel B, the conjunctival epithelium is thickened and keratinized as evidenced by increased eosinophilic staining of the superficial layers (arrows), as well as the presence of keratin debris within the fornix (asterisk). H&E stain; bar = 100 µm.

ropsied, 8 were not reported to receive any type of vitamin A supplementation. For the 3 leopard geckos without ophthalmic disease, 2 had no evidence of squamous metaplasia of epithelial-lined structures; the eyes of the third animal were not available for examination. All 3 of these geckos received vitamin A supplementation. Histologic examination of crusted ocular discharge collected as an antemortem sample from the 1 aforementioned affected leopard gecko revealed parakeratotic and orthokeratotic squamous epithelial

cells admixed with keratin, necrotic debris, and aggregates of bacteria in an amorphous, fibrillar, myxomatous matrix.

Discussion

One hundred twelve of 144 leopard geckos evaluated at a single teaching facility in a 28.8-year period had sufficient medical record documentation to allow their inclusion in the present study. Of those animals, a diagnosis of ophthalmic disease was made for almost half (52 leopard geckos). Most of the leopard geckos with ophthalmic disease had blepharospasm, ocular discharge, and ocular surface disease. Diet (lack of vitamin A supplementation), environment (paper towel substrate and lack of a heat source), and concurrent disorders (head dysecdysis) were all identified as risk factors associated with ophthalmic disease in this population of leopard geckos. Furthermore, increasing age and being male were found to be associated with increased odds of ophthalmic disease.

To our knowledge, the present study was the first to identify a possible association between vitamin A supplementation and the presence of ophthalmic disease in leopard geckos. There was a nearly 10-fold reduction in risk of ophthalmic disease in leopard geckos that were receiving some type of vitamin A supplementation. The histopathologic findings of squamous metaplasia in most of the affected animals that were necropsied also strongly suggested that hypovitaminosis A can cause ophthalmic disease in leopard geckos, although the low number of patients necropsied did not allow for statistical analysis. There are reports of hypovitaminosis A in numerous species of reptiles, including aquatic^{12,20} and box turtles,^{21,22} crocodilians,²³ and chameleons,²⁴⁻²⁶ although specific vitamin A requirements have not been determined for

any reptile species to date.²¹ Epithelial squamous metaplasia is typically detected histologically in cases of hypovitaminosis A,^{20,22} but the clinical signs vary depending on the reptile species. Reported clinical signs of hypovitaminosis A include blepharidema in aquatic turtles^{20,21}; metabolic bone disease,²⁶ stomatitis, and conjunctivitis in chameleons²⁵; cheilitis in green anoles (*Anolis carolinensis*)²⁷; nodules on the dorsal surface of the tongue in crocodiles (*Crocodylus porosus* and *Crocodylus johnstoni*)²³; and aural

abscesses in box turtles.²⁸ Lesions of internal organs, such as the pancreas and urinary system,²⁰ likely go undetected without histologic evaluation of affected tissues. Although the pathophysiology is not well studied in reptiles, experimental induction of hypovitaminosis A requires > 6 months of vitamin A-deficient diet administration.^{22,25}

At this time, however, a recommendation of vitamin A supplementation for leopard geckos with ocular surface disease cannot be made. It is difficult to determine what type of vitamin A supplementation is appropriate for this species given the wide variety of commercially available products and prey gut-loading methods. Many arthropods fed to captive insectivorous lizards have naturally low levels of vitamin A,^{29,30} with the exception of silkworms (*Bombyx mori*), termites, and honey bees (*Apis mellifera*). Gut-loading of the prey offered to insectivorous lizards is a common practice,²⁹ but the final vitamin A content within a gut-loaded insect body is dependent upon the species.^{19,31,32} Vitamin A supplementation is controversial and not universally performed by reptile owners because of the risk of inducing hypervitaminosis A, which has been reported for tortoises³³ and chameleons²⁵ among other reptiles.²¹ Furthermore, metabolism of vitamin A among reptile species is likely not similar. An *in vitro* study in green iguanas (*Iguana iguana*) revealed that this species is able to absorb oxygenated carotenoids only, but supplementation with β -carotene failed to result in increased plasma concentration of β -carotene.³⁴ Similarly, the ability of the panther chameleon (*Furcifer pardalis*) to use dietary carotenoids has been questioned.^{24,25} Whether leopard geckos are able to absorb and convert carotenoids is unknown, and future studies are required to determine normal tissue and circulating concentrations of vitamin A within this species. Ideally, experimental induction of hypovitaminosis A in leopard geckos in a controlled environment would be needed to confirm causality. Although the results of the present study have suggested a possible association between ophthalmic disease and vitamin A deficiency in leopard geckos, vitamin A requirements remain unknown in this species and vitamin A supplements should be administered cautiously owing to the potential risk of hypervitaminosis A.

In the present study, other husbandry variables were found to be significantly associated with ophthalmic disease, including increased risk with a paper towel substrate and also lack of a heat source. Leopard geckos are inhabitants of semi-arid, rocky desert regions in southwestern Asia.¹ Paper towels, as well as newspaper, reptile carpet, and plastic green mats, are a recommended substrate for leopard geckos because fine granular substrates such as sand, corncob, bark, and wood shavings may lead to gastrointestinal impaction.¹ Furthermore, it is possible that fine granular substrates may act as ocular surface irritants. Thus, this statistical association of increased risk of ophthalmic disease with a paper towel substrate appears to be

counterintuitive. It may have been the leopard geckos were switched to a different substrate by referring veterinarians because of their ophthalmic disease prior to evaluation at the teaching hospital, thereby leading to an artificially skewed representation of patients with ophthalmic disease housed on a paper towel substrate. Furthermore, paper towels alone without adjunctive humidification may facilitate an excessively dry captive microenvironment, whereas leopard geckos prefer to shelter in cool and damp burrows beneath rocks within their desert environment.¹ Other substrates such as reptile carpet, corncobs, or large wood chips may retain more moisture within the habitat. However, because leopard geckos originate from a rocky geographic area, a preponderance of a granular substrate does not accurately mimic their natural environment. Further investigation is warranted into the influence of substrate on leopard gecko habitat humidity levels. The desert origin of leopard geckos suggests that these animals have adapted to extremes of temperature. Inadequate temperature regulation or even possibly a lack of temperature variation may have a role in ocular surface health in this species. Again, further study is warranted to determine how temperature regulation affects the development of ophthalmic disease in leopard geckos when all other husbandry factors are controlled. Further studies with larger numbers of animals may reveal additional dietary factors that are associated with ophthalmic disease in leopard geckos.

Dysecdysis on the head was significantly associated with ocular disease in leopard geckos in the present study. In snakes, a retained spectacle is a result of dysecdysis over their specialized transparent and fused eyelids and was found to be the most common ophthalmic disease in snakes evaluated at a single teaching hospital.¹⁴ Members of the family Eublepharidae are unique from other geckos (as well as snakes) in that they possess true eyelids. Two possible explanations exist for the association between ophthalmic disease and head dysecdysis in leopard geckos. The first is that ocular discharge may be components of retained shed that have become trapped within the conjunctival fornix. The second is that dysecdysis is potentially associated with dietary vitamin A deficiency. The latter explanation is less likely because other forms of dysecdysis (on the body or limbs) were not significantly associated with ophthalmic disease in leopard geckos in the present study. However, the data obtained in the present study suggested that examination of a greater number of cases in future studies may allow for a stronger argument that vitamin A deficiency is associated with dysecdysis. Overall, ophthalmic disease in leopard geckos appears to be multifactorial in nature. The authors suggest that future studies could perhaps more accurately characterize the composition of the ocular discharge and determine an association of the clinical appearance of the discharge with concurrent or underlying disease.

Anterior uveitis was an uncommon diagnosis among the leopard geckos of the present study. Of

3 leopard geckos with anterior uveitis, 2 had ulcerative keratitis indicating the possibility of a reflex anterior uveitis. Results of a study³⁵ in dogs indicate that topical anesthesia with proparacaine disrupts pilocarpine-induced breakdown of the blood-aqueous barrier, suggesting a neurally mediated link between corneal irritation and uveitis. Because a systemic diagnostic workup was not performed in the third leopard gecko with anterior uveitis, other underlying causes of anterior uveitis were not determined. Given the low number of leopard geckos with uveitis, insufficient follow-up information was available to make conclusions regarding treatment efficacy.

The present study had several limitations. First, the retrospective nature of the study allowed neither standardization nor quantification of the patients' dietary vitamin A supplementation nor collection of tissue samples for measurement of vitamin A concentration. A greater understanding of the vitamin A metabolism of leopard geckos and the normal vitamin A concentrations within tissues (eg, the liver) and plasma is required before future clinical studies of the effect of hypovitaminosis A on epithelial-lined tissues can be performed. Second, because of the small number of patients from which samples were obtained for histologic examination, the cause of ocular discharge and conjunctivitis in all affected leopard geckos could not be confirmed to be hypovitaminosis A. Third, because medical treatments and recommendations for husbandry changes for affected geckos were not controlled, their efficacy could not be determined. At a minimum, for those individuals with debris covering the ocular surface, it is still recommended to remove the debris by use of custom eyelid retractors with vigorous irrigation of the eye or manual clearance and to provide appropriate topical ophthalmic antimicrobial treatment if corneal ulceration is present. Fourth, the study animals' histories provided by owners did not include detailed information on some of the husbandry variables, such as humidity or temperature. Although attempts were made to document the means by which humidity and temperature were controlled, actual values could not be obtained. The maintenance of exotic species is quite variable, which makes assessment of husbandry details difficult in a retrospective study. Thus, humidity and temperature remain possible factors in the development of ophthalmic disease in geckos.

The results of the present study indicated that ophthalmic disease was a common diagnosis for leopard geckos evaluated at a veterinary teaching hospital over a nearly 29-year period. Most affected leopard geckos had ocular surface disease, and intraocular disease was rare. The causes of ophthalmic disease in leopard geckos appeared to be multifactorial; some husbandry variables were significantly associated with the presence of ophthalmic disease. Of these, vitamin A supplementation was of particular interest on the basis of the statistical association with ophthalmic disease and the histopathologic findings.

However, at this time, recommendations cannot be made regarding specific amounts or types of vitamin A supplementation for leopard geckos until further studies have been performed to understand the normal metabolism and reference ranges of plasma and tissue vitamin A concentrations in this species. Treatment of leopard geckos with severe, tenacious ocular discharge is recommended to improve vision and allow for proper penetration of topical medications when corneal or conjunctival disease is present.

Acknowledgments

Supported in part by the RM Cello Endowment.

Presented in abstract form at Association of Reptilian and Amphibian Veterinarians (ARAV), San Antonio, Tex, August 2015.

Footnotes

- a. Carnivore Care, Oxbow Animal Health, Murdock, Neb.
- b. Chick Starter, MannaPro Products LCC, Chesterfield, Mo.
- c. Bug Burger, Repashy Ventures Inc, San Marcos, Calif.
- d. Calcium Plus, Repashy Ventures Inc, San Marcos, Calif.
- e. Reptivite, Zoo Med Laboratory Inc, San Luis Obispo, Calif.
- f. USDA Food Composition Databases [database online] (search term: raw carrots). Beltsville, Md: USDA Agricultural Research Service, 2017. Available at: ndb.nal.usda.gov/ndb/. Accessed Jun 16, 2017.
- g. Fluker's Orange Cubes Complete Cricket Diet, Fluker's Farms, Port Allen, La.
- h. Fluker's Calcium without vitamin D, Fluker's Farms, Port Allen, La.
- i. Herptivite, Rep-Cal Research Labs, Los Gatos, Calif.
- j. Leopard Gecko Dust, T-Rex, San Diego, Calif.
- k. Miner-All, Sticky Tongue Farms, Sun City, Calif.
- l. Stata/IC 13.1, StatCorp LP, College Station, Tex.

References

1. Bradley T, Nieves D. Leopard gecko, *Eublepharis macularius*, captive care and breeding. *Bull Assoc Reptilian Amphib Vet* 1999;9:36-41.
2. McLean KE, Vickaryous MK. A novel amniote model of epimorphic regeneration: the leopard gecko, *Eublepharis macularius*. *BMC Dev Biol* 2011;11:50.
3. Delorme SL, Lungu IM, Vickaryous MK. Scar-free wound healing and regeneration following tail loss in the leopard gecko, *Eublepharis macularius*. *Anat Rec (Hoboken)* 2012;295:1575-1595.
4. Gilbert RW, Vickaryous MK, Vilorio-Petit AM. Characterization of TGF β signaling during tail regeneration in the leopard gecko (*Eublepharis macularius*). *Dev Dyn* 2013;242:886-896.
5. Lynn SE, Borkovic BP, Russell AP. Relative apportioning of resources to the body and regenerating tail in juvenile leopard geckos (*Eublepharis macularius*) maintained on different dietary rations. *Physiol Biochem Zool* 2013;86:659-668.
6. Peacock HM, Gilbert EA, Vickaryous MK. Scar-free cutaneous wound healing in the leopard gecko, *Eublepharis macularius*. *J Anat* 2015;227:596-610.
7. Tousignant A, Crews D. Effect of exogenous estradiol applied at different embryonic stages on sex determination, growth, and mortality in the leopard gecko (*Eublepharis macularius*). *J Exp Zool* 1994;268:17-21.
8. Rhen T, Sakata JT, Zeller M, et al. Sex steroid levels across the reproductive cycle of female leopard geckos, *Eublepharis macularius*, from different incubation temperatures. *Gen Comp Endocrinol* 2000;118:322-331.
9. Rhen T, Sakata JT, Woolley S, et al. Changes in androgen receptor mRNA expression in the forebrain and oviduct during the reproductive cycle of female leopard geckos, *Eublepharis macularius*. *Gen Comp Endocrinol* 2003;132:133-141.
10. Edwards N, Kriegsfeld L, Crews D. Neural substrates for sexual and thermoregulatory behavior in the male leopard gecko, *Eublepharis macularius*. *Brain Res* 2004;1029:77-83.

11. Endo D, Park MK. Molecular characterization of the leopard gecko POMC gene and expressional change in the testis by acclimation to low temperature and with a short photoperiod. *Gen Comp Endocrinol* 2004;138:70-77.
12. Millichamp NJ, Jacobson ER, Wolf ED. Diseases of the eye and ocular adnexae in reptiles. *J Am Vet Med Assoc* 1983;183:1205-1212.
13. Sabater M, Perez M. Congenital ocular and adnexal disorders in reptiles. *Vet Ophthalmol* 2013;16:47-55.
14. Hausmann JC, Hollingsworth SR, Hawkins MG, et al. Distribution and outcome of ocular lesions in snakes examined at a veterinary teaching hospital: 67 cases (1985-2010). *J Am Vet Med Assoc* 2013;243:252-260.
15. Toplon DE, Terrell SP, Sigler L, et al. Dermatitis and cellulitis in leopard geckos (*Eublepharis macularius*) caused by the *Chrysosporium* anamorph of *Nannizziopsis vriesii*. *Vet Pathol* 2013;50:585-589.
16. Patterson-Kane JC, Redrobe SP. Colonic adenocarcinoma in a leopard gecko (*Eublepharis macularius*). *Vet Rec* 2005;157:294-295.
17. Deming C, Greiner E, Uhl EW. Prevalence of cryptosporidium infection and characteristics of oocyst shedding in a breeding colony of leopard geckos (*Eublepharis macularius*). *J Zoo Wildl Med* 2008;39:600-607.
18. Hall AJ, Lewbart GA. Treatment of dystocia in a leopard gecko (*Eublepharis macularius*) by percutaneous oocentesis. *Vet Rec* 2006;158:737-739.
19. Donoghue S. Nutrition. In: Mader DR, ed. *Reptile medicine and surgery*. Philadelphia: Saunders/Elsevier, 2006;251-298.
20. Elkan E, Zwart P. The ocular disease of young terrapins caused by vitamin A deficiency. *Pathol Vet* 1967;4:201-222.
21. Boyer T. Hypovitaminosis A and hypervitaminosis A. In: Mader DR, ed. *Reptile medicine and surgery*. Philadelphia: Saunders/Elsevier, 2006;831-835.
22. Kroenlein KR, Sleeman JM, Holladay SD, et al. Inability to induce tympanic squamous metaplasia using organochlorine compounds in vitamin A-deficient red-eared sliders (*Trachemys scripta elegans*). *J Wildl Dis* 2008;44:664-669.
23. Ariel E, Ladds PWBG. Concurrent gout and suspected hypovitaminosis A in crocodile hatchlings. *Aust Vet J* 1997;75:247-249.
24. Dierenfeld ES, Norkus EBCK, Ferguson GW. Carotenoid, vitamin A and vitamin E concentrations during egg development in panther chameleons (*Furcifer pardalis*). *Zoo Biol* 2002;21:295-303.
25. Ferguson GW. Indoor husbandry of the panther chameleon *Chamaeleo [Furcifer] pardalis*: effects of dietary vitamins A and D and ultraviolet irradiation on pathology and life-history traits. *Zoo Biol* 1996;15:275-299.
26. Hoby S, Wenker C, Robert N, et al. Nutritional metabolic bone disease in juvenile veiled chameleons (*Chamaeleo calyptratus*) and its prevention. *J Nutr* 2010;140:1923-1931.
27. Miller EA, Green SL, Otto GM, et al. Suspected hypovitaminosis A in a colony of captive green anoles (*Anolis carolinensis*). *Contemp Top Lab Anim Sci* 2001;40:18-20.
28. Holladay SD, Wolf JC, Smith SA, et al. Aural abscesses in wild-caught box turtles (*Terapene carolina*): possible role of organochlorine-induced hypovitaminosis A. *Ecotoxicol Environ Saf* 2001;48:99-106.
29. Finke M, Dunham SKC. Evaluation of four dry commercial gut loading products for improving the calcium content of crickets, *Acheta domesticus*. *J Herpetological Med Surg* 2005;15:7-12.
30. Dugas MB, Yeager J, Richards-Zawacki CL. Carotenoid supplementation enhances reproductive success in captive strawberry poison frogs (*Oophaga pumilio*). *Zoo Biol* 2013;32:655-658.
31. Ogilvy V, Fidgett AL, Preziosi RF. Differences in carotenoid accumulation among three feeder-cricket species: implications for carotenoid delivery to captive insectivores. *Zoo Biol* 2012;31:470-478.
32. Oonincx DG, van der Poel AF. Effects of diet on the chemical composition of migratory locusts (*Locusta migratoria*). *Zoo Biol* 2011;30:9-16.
33. Palmer DG, Rubel A, Mettler F, et al. Experimentally induced skin changes in tortoises by high parenteral doses of vitamin A [in German]. *Zentralbl Veterinarmed A* 1984;31:625-633.
34. Raila J, Schuhmacher A, Gropp J, et al. Selective absorption of carotenoids in the common green iguana (*Iguana iguana*). *Comp Biochem Physiol A Mol Integr Physiol* 2002;132:513-518.
35. Krohne SG, Gionfriddo J, Morrison EA. Inhibition of pilocarpine-induced aqueous humor flare, hypotony, and miosis by topical administration of anti-inflammatory and anesthetic drugs to dogs. *Am J Vet Res* 1998;59:482-488.