

UC Davis

Dermatology Online Journal

Title

Factitial panniculitis as a manifestation of self-imposed factitious disorder

Permalink

<https://escholarship.org/uc/item/9dx484qq>

Journal

Dermatology Online Journal, 25(5)

Authors

Yanes, Arianna F
Owen, Joshua L
Colavincenzo, Maria L

Publication Date

2019

DOI

10.5070/D3255044071

Copyright Information

Copyright 2019 by the author(s). This work is made available under the terms of a Creative Commons Attribution-NonCommercial-NoDerivatives License, available at <https://creativecommons.org/licenses/by-nc-nd/4.0/>

Peer reviewed

Factitial panniculitis as a manifestation of self-imposed factitious disorder

Arianna F Yanes BA, Joshua L Owen MD PhD, Maria L Colavincenzo MD

Affiliations: Department of Dermatology, Northwestern University, Feinberg School of Medicine, Chicago, Illinois, USA

Corresponding Author: Maria L. Colavincenzo MD, 676 North Saint Clair Street, Suite 1600, Chicago IL 60611, Tel: 312-695-8106, Email: Maria.Colavincenzo@nm.org

Abstract

Factitious disorder imposed on self is characterized by self-induction. Dermatitis artefacta, the cutaneous subtype of factitious disorder imposed on self, can have a variety of atypical presentations. A 36-year-old woman with an extensive past medical history presented with painful nodules on her abdomen, thighs, and arms. Histologic evaluation identified panniculitis with foreign body material seen under polarization. Chart review from previous hospital visits established a history of factitious disorder imposed on self and upon subsequent search of the hospital room, syringes with an unknown substance were found. Factitial panniculitis should be considered in cases with atypical lesions or locations that do not conform to the presentation of organic causes of panniculitis. Management should include a multidisciplinary approach that prioritizes patient safety and establishes a therapeutic patient-provider relationship.

Keywords: factitial panniculitis, panniculitis artefacta, factitious disorder, dermatitis artefacta, Munchausen syndrome, psychiatry

Introduction

Factitious disorder imposed on self is characterized by self-induced illness with the intention of assuming the patient role in the absence of obvious external rewards [1]. Cutaneous factitious disorder imposed on self, or dermatitis artefacta, can present in a variety of ways, including geometrically shaped and oddly distributed lesions. We present a patient

with panniculitis, later discovered to be the result of self-injection of an unknown substance.

Case Synopsis

A 36-year-old woman with an extensive past medical history, including type 1 diabetes mellitus, recurrent pancreatitis status-post pancreas transplant, Addison disease, and multiple hospitalizations for polymicrobial resistant gram-negative bacteremia and candidemia, presented with nodules on the bilateral thighs. Three days prior to admission, she noted the onset of painful, enlarging nodules on her thighs, abdomen, and arms. She reported pain with ambulation and denied drainage from the lesions. Five months prior, she had similar nodules on her abdomen that were debrided at another hospital. Review of systems was positive for subjective fever, sweats, dyspnea, chest pain, nausea, and vomiting.

Physical examination demonstrated multiple 2-4cm subcutaneous nodules on the thighs with overlying crusted papules, as well as tender nodules on the arms and abdomen (**Figure 1**).

Laboratory tests were notable for leukocytosis ($13,200/\text{mm}^3$), thrombocytosis ($807,000/\text{mm}^3$), and an elevated erythrocyte sedimentation rate ($75\text{mm}/\text{h}$). Computed tomography (CT) scan with contrast identified soft tissue density subcutaneous nodules in the bilateral thighs and ventral abdominal wall without drainable fluid collections. The patient was empirically started on intravenous vancomycin and meropenem with oral fluconazole.

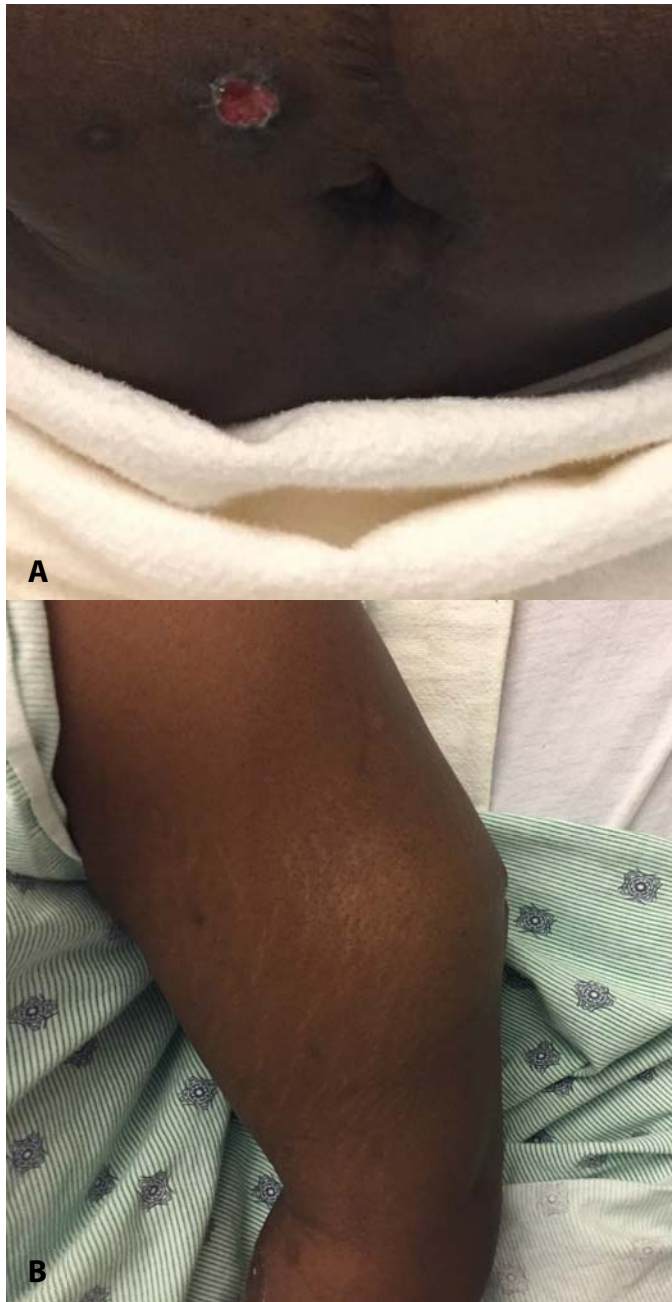


Figure 1: Clinical presentation. **A)** On a background of previous abdominal surgical scars are multiple 2-4cm subcutaneous nodules of the abdomen, some with an overlying crusted or ulcerated papule. **B)** Subcutaneous nodule with overlying ulceration of the upper lateral arm.

Skin punch biopsies were performed on the left arm and thigh; no purulence or drainage was seen. Bacterial, fungal, and mycobacterial cultures were negative for growth and special stains for microorganisms were negative. Biopsy demonstrated a lobular inflammatory process primarily composed of neutrophils with scattered

eosinophils and histiocytes (**Figure 2A**). Under polarization, foreign body material was identified (**Figure 2B**). The epidermis and dermis were unremarkable, and no vasculitis was noted. Taken together, the biopsy was read as lobular panniculitis with abscess and foreign body material, consistent with factitial panniculitis.

The patient's primary care provider was contacted and a history of factitious disorder imposed on self was obtained. Previous events included contamination of her peripherally inserted central catheter line and surreptitious injection of insulin. A team approach, including the consultant teams from dermatology, infectious diseases, and psychiatry, was utilized to discuss the skin biopsy findings with the patient. She vehemently denied self-injection and subsequently refused to speak to the psychiatry team. An observer was instituted for safety measures. Search of her hospital room revealed a syringe containing several milliliters of yellow fluid in her bathroom. Her antibiotics were narrowed to a 7-day course of clindamycin empirically for superinfection. Once afebrile, she was discharged with close outpatient follow-up.

Case Discussion

Factitious disorder imposed on self is the feigning of illness via self-induction of injury or disease, not for external rewards, but to be placed in the role of patient [1]. Munchausen syndrome, primarily a historic term not included in the DSM-5 [1], has sometimes been used to refer to a type of factitious disorder imposed on self, which is characterized by deception, use of aliases, and travel between hospitals or cities to seek care [2]. Patients with factitious disorder imposed on self frequently have a history of multiple hospitalizations, leading to familiarity with the medical system and medical terminology [2]. The skin, mucosa, and subcutaneous tissue are readily accessible for self-injury and are frequently involved in a condition referred to as dermatitis artefacta [3, 4]. Presentations on the skin can be unusual and perplexing in morphology and distribution.

Factitial panniculitis, also referred to as panniculitis artefacta, is inflammation of the subcutaneous adipose tissue produced by external actions. Factitial

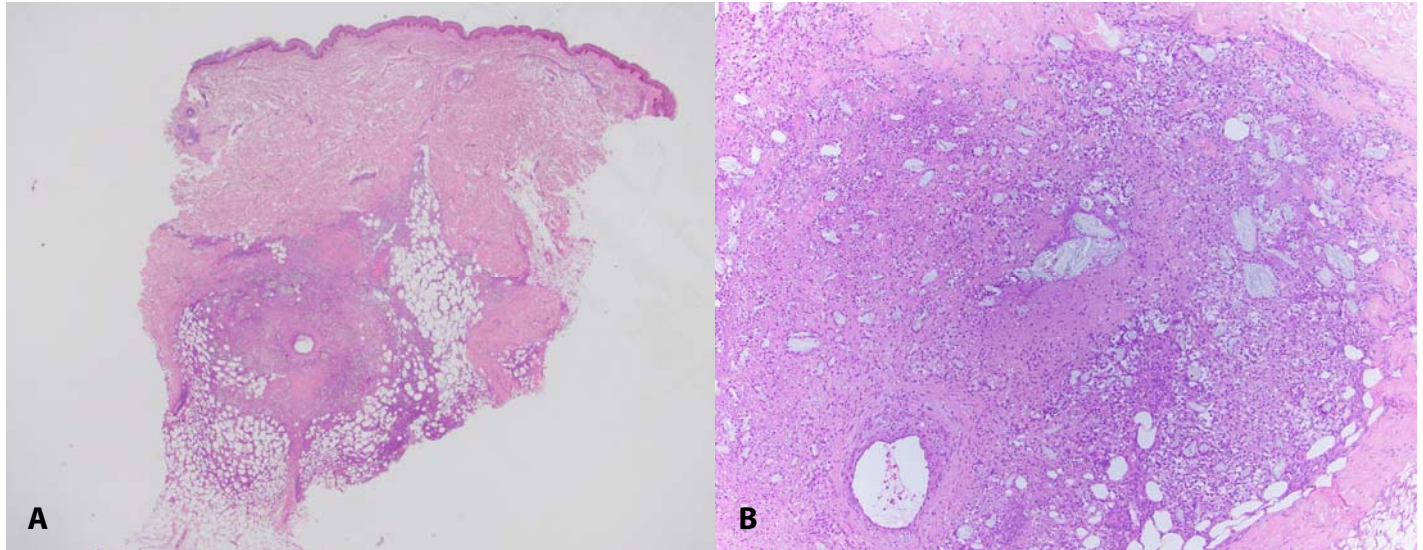


Figure 2: Histopathology of factitial panniculitis. **A)** Punch biopsy demonstrating a lobular inflammatory process primarily composed of neutrophils with scattered eosinophils and histiocytes. H&E, 20 \times . **B)** Foreign body material identified under polarization. H&E, 100 \times .

panniculitis is usually the result of self-injection of chemicals, such as drugs, oily materials, and organic materials, as a manifestation of psychiatric disease. This typically occurs in young adults or middle-aged women with a comorbid psychiatric disorder or substance abuse disorder, but can also be iatrogenic as a consequence of medication injections [5]. The condition can also be induced by mechanical causes, such as trauma, and physical causes, such as cold temperatures [6].

The clinical presentation of self-induced factitial panniculitis varies depending on the inciting agent and method of injury, but lesions are typically distributed in areas accessible for self-injection, such as the buttocks or thighs [5]. Previous cases in the literature have reported draining, ulcerated, purpuric, erythematous, or indurated nodules, as well as abscess formation and pyoderma gangrenosum-like lesions [5-8]. Factitial panniculitis should be considered in cases with atypical appearances or locations that do not conform to any organic cause of panniculitis.

Histopathology of factitial panniculitis classically demonstrates acute lobular inflammation with a predominantly neutrophilic infiltrate and possible fat necrosis. Vasculitis is not typically seen in factitial cases. Examination of panniculitis histopathology with a polarizing microscope can identify injected

foreign material, a finding more specific to factitial panniculitis [5].

As in this case, patients presenting with factitial panniculitis as a manifestation of factitious disorder imposed on self may have previous evidence of self-inflicted injury or illness [3]. Many patients will seek care at multiple institutions, making it critical to locate previous medical records if the diagnosis is suspected. Prompt diagnosis is imperative to prevent unnecessary testing and potential harm to the patient. Creating a care plan for the patient within the electronic medical record can alert future providers of the patient's history, indicating a need for close supervision and possible room search in the inpatient setting.

Treatment of factitial panniculitis in the hospital setting should include antibiotics if concurrent infection is suspected [5]. The use of bandaging and close supervision can help prevent further manipulation and development of new self-inflicted lesions [7]. A hospital room search may identify injected material, needles, or syringes that can aid in diagnosis. A multispecialty approach, including psychiatry consultation, helps to navigate difficult conversations and establish a supportive, nonjudgmental environment [4]. Psychiatric hospitalization has been suggested as appropriate therapy for patients with factitious disorder imposed

on self, but patients are often resistant to such a treatment and lost to follow up [2, 7].

Conclusion

We report a young woman who was diagnosed with factitial panniculitis upon discovery of polarizable foreign body material on skin biopsy. Factitious disorder imposed on self is important to include in the differential diagnosis for panniculitis, particularly

in unusual presentations that are not consistent with organic causes of panniculitis. Obtaining records from other hospitals can support the diagnosis as patients will often seek care at multiple institutions. A multidisciplinary approach involving expertise from psychiatry is desirable to establish a treatment plan and maintain patient safety.

Potential conflicts of interest

The authors declare no conflicts of interests.

References

1. *Diagnostic and Statistical Manual of Mental Disorders, Fifth Edition (DSM-5)*. Arlington, VA: American Psychiatric Association; 2013.
2. Boyd AS, Ritchie C, Likhari S. Munchausen syndrome and Munchausen syndrome by proxy in dermatology. *J Am Acad Dermatol*. 2014;71(2):376-381. [PMID: 24613506].
3. Falagas ME CM, Rosmarakis ES, Vlastou C. Munchausen's syndrome presenting as severe panniculitis. *Int J Clin Pract* 2004;58(7):720-722. [PMID: 15311731].
4. Kuhn H, Mennella C, Magid M, Stamu-O'Brien C, Kroumpouzou G. Psychocutaneous disease: Clinical perspectives. *J Am Acad Dermatol*. 2017;76(5):779-791. [PMID: 28411771].
5. Sanmartin O, Requena C, Requena L. Factitial panniculitis. *Dermatol Clin*. 2008;26(4):519-527, viii. [PMID: 18793986].
6. Forstrom L, Winkelmann RK. Factitial panniculitis. *Arch Dermatol*. 1974;110(5):747-750. [PMID: 4608423].
7. Tausche A HS, Tausche K, Unger S, Schroder H, Pietsch J. Case number 31: Nodular panniculitis as expression of Munchausen's syndrome (panniculitis artefacta). *Ann Rheum Dis*. 2004;63(10):1195-1196. [PMID: 15361370].
8. Oh CC MD, McLaren KM, Tidman MJ. Factitious panniculitis masquerading as pyoderma gangrenosum. *Clin Exp Dermatol* 2005;30(3):253-255. [PMID: 15807683].