

UCLA

Proceedings of UCLA Health

Title

Peeing Within, A Rare Cause of Pseudo-renal-failure

Permalink

<https://escholarship.org/uc/item/9dp4c5gw>

Journal

Proceedings of UCLA Health, 25(1)

Authors

Lin, Jonathan Kwong-Shing

Kahn, Daniel

Publication Date

2021-04-16

CLINICAL VIGNETTE

Peeing Within, A Rare Cause of Pseudo-renal-failure

Jonathan Kwong-Shing Lin, MD¹ and Daniel Kahn, MD²

¹Department of Medicine, UCLA Medical Center, Los Angeles, California

²Department of Medicine, UCLA Medical Center, David Geffen School of Medicine at UCLA, Los Angeles, California

Case Description

A 65-year-old male with a history of stage two chronic kidney disease and prostate cancer presented with abdominal distension and an elevated creatinine. One month prior, the patient underwent a total prostatectomy. Creatinine was initially 1.4 mg/dL on the day of surgery and remained persistently elevated between 1.7-1.9 mg/dL post-surgery. Cystogram one-week post-operation revealed an anterior leak at the urethrovesical anastomosis where the bladder neck was reconstructed. A post-operative foley was left in place for an additional week and then discontinued. In an outpatient assessment, the patient's nephrologist noted that the patient had new onset abdominal distention with ongoing elevated creatinine and recommended inpatient hospitalization for further evaluation.

At the time of admission, the patient complained of worsening abdominal distension and a "string-like pulling sensation" when his bladder was full. Exam was notable for abdominal distension with shifting dullness without evidence of liver disease or heart failure. Patient's creatinine was elevated at 1.96 mg/dL. BNP, hepatic panel, albumin and urine protein were within normal limits. Hepatic ultrasound was unremarkable. CT KUB showed moderate ascites and no hydronephrosis. Paracentesis revealed clear fluid with a serum ascites albumin gradient (SAAG) of 1.3, ascites:serum creatinine >1.0, and an ascites pH of 7.90. Urine pH was comparable at 7.0, consistent with a diagnosis of urinary ascites.

Urology was consulted for management of urinary ascites. A foley was placed and the patient's creatinine decreased to 1.71 mg/dL the next day. Patient was safely discharged with recommendations to keep the foley for two to three weeks with a repeat cystogram prior to removal.

Discussion

Urinary ascites is a rare cause of pseudo-renal failure, with few cases being reported in the literature. Urinary ascites often occurs in the setting of blunt trauma, radiation and recent gynecologic or abdominal surgery. Any conditions which increase bladder distension can also lead to an increased risk of rupture. These include urinary outflow obstruction, malignancy, and alcohol use - with decreased awareness of need to void. Chronic reabsorption of peritoneal urine leads to an elevated

serum creatinine and urea nitrogen as well as hyponatremia and hyperkalemia - often prompting an erroneous diagnosis of acute kidney injury as well as inappropriate therapies such as hemodialysis.¹⁻⁹

Patients with bladder perforation often present with non-specific symptoms similar to urinary tract infection – dysuria, hematuria, difficulty voiding as well as suprapubic or abdominal discomfort and distension. As ascites and abdominal distension worsens, patients may also develop respiratory distress as well as nausea and early satiety.^{2,8}

If uroperitoneum is suspected, abdominal ultrasound should confirm the presence of ascites. Ascites urea and creatinine levels should be obtained. An ascites to serum creatinine ratio greater than 1.0 is highly suggestive of urinary leakage into the peritoneal space.¹⁰ Of note, reabsorption of ascitic fluid through the peritoneal membrane can potentially lead to serum electrolyte abnormalities such as hyperkalemia and hyponatremia. Diagnosis should be confirmed with conventional retrograde cystography which has an accuracy of 85-100%. If the bladder perforation is small, it may not be readily identifiable on cystography in which CT cystogram should be pursued.²

Our patient's ascites creatinine was elevated at 5.2, and the ascites to serum creatinine ratio (5.2 vs 1.96 mg/dL) was greater than 1. The patient's ascites and urine pH were comparable at 7.0 and 7.90. Thus, given the patient's history, lack of an alternative cause of ascites and the aforementioned laboratory findings secured a diagnosis of urinary ascites.

The primary management of urinary ascites often involves bladder decompression with an indwelling foley catheter - this serves to treat the ascites, prevent further electrolyte derangements, and allow for self-repair of the perforated bladder if the lesion is small. Urology should be consulted as if conservative treatment fails, surgery may be required.^{1,9}

Urinary ascites should be considered on the differential in patients presenting with ascites and a recent history of trauma or surgery. If uroperitoneum is indeed suspected, ascites, urine, and serum creatinine, urea nitrogen, sodium, potassium should be obtained. Confirmation of the diagnosis can be achieved

through cystography. Early identification and treatment of urinary ascites can help prevent complications such as urinomas, sepsis, and abscess formation as well as inappropriate therapies which may cause undue anxiety or harm to the patient.⁵

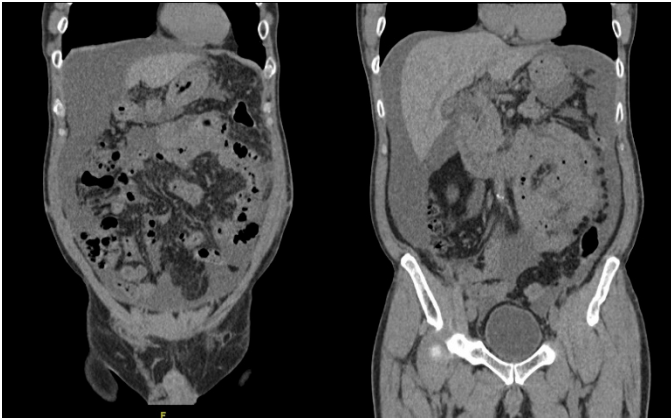


Figure 1. Non-contrast CT KUB revealed moderate ascites with diffuse peritoneal thickening. No evidence of hydro-ureteronephrosis.

Acknowledgements

We thank like to thank Dr. Ji Yeon Seon (UCLA) for her comments on the manuscript.

REFERENCES

1. **Abirami K, Sivaramakrishna G, Lakshmi AY, Sivakumar V.** Urinary ascites. *Indian J Nephrol.* 2012 Mar;22(2):143-4. doi: 10.4103/0971-4065.97140. PMID: 22787320; PMCID: PMC3391815.
2. **Al-Mandeel H, Qassem A.** Urinary ascites secondary to delayed diagnosis of laparoscopic bladder injury. *J Minim Access Surg.* 2010 Apr;6(2):50-2. doi: 10.4103/0972-9941.65165. PMID: 20814512; PMCID: PMC2924549.
3. **Arunkumar K, Selvakumar E, Vimalraj V, Jeswanth S, Jyotibas D, Surendran R.** An unusual case of urinary ascites presenting as postoperative acute oliguric renal failure. *Trop Gastroenterol.* 2013 Jan-Mar;34(1):52-3. doi: 10.7869/tg.2012.97. PMID: 23923381.
4. **Fujikawa T, Tokuda Y.** Ascites from intraperitoneal urine leakage after pelvic radiation. *Cleve Clin J Med.* 2018 Mar;85(3):188-189. doi: 10.3949/ccjm.85a.17028. PMID: 29522395.
5. **Ghosh S, Chatterjee N, Mukhopadhyay M, Brahmachari R, Maity P, Das AK.** Urinary Ascites - A Consequence of Intraoperative Injury. *J Assoc Physicians India.* 2015 Sep;63(9):77-8. PMID: 27608874.
6. **Goto S, Yamadori M, Igaki N, Kim JI, Fukagawa M.** Pseudo-azotaemia due to intraperitoneal urine leakage: a report of two cases. *NDT Plus.* 2010 Oct;3(5):474-6. doi: 10.1093/ndtplus/sfq107. Epub 2010 Jun 8. PMID: 25984058; PMCID: PMC4421708.
7. **Kivlin D, Ross C, Lester K, Metro M, Ginsberg P.** A Case Series of Spontaneous Rupture of the Urinary Bladder. *Curr Urol.* 2015 May;8(1):53-6. doi: 10.1159/000365690. Epub 2015 May 20. PMID: 26195965; PMCID: PMC4483303.
8. **Matsumura M, Ando N, Kumabe A, Dhaliwal G.** Pseudo-renal failure: bladder rupture with urinary ascites. *BMJ Case Rep.* 2015 Nov 20;2015:bcr2015212671. doi: 10.1136/bcr-2015-212671. PMID: 26590189; PMCID: PMC4680254.
9. **Ridinger HA, Kavitt RT, Green JK.** Urinary ascites and renal failure from unrecognized bladder rupture. *Am J Med.* 2012 Sep;125(9):e1-2. doi: 10.1016/j.amjmed.2012.01.019. Epub 2012 Jun 27. PMID: 22748402.
10. **Pintar TJ, Wilke RA.** Urinary ascites: spontaneous bladder rupture presenting as acute oliguric renal failure. *Am J Med.* 1998 Oct;105(4):347-9. doi: 10.1016/s0002-9343(98)00264-2. PMID: 9809697.