

UC Davis

UC Davis Previously Published Works

Title

Intraoperative Placement of Pectoral Nerve Block Catheters

Permalink

<https://escholarship.org/uc/item/9dg5b2n5>

Journal

Annals of Plastic Surgery, 78(5)

ISSN

0148-7043

Authors

Hinchcliff, Katharine M
Hylton, Jared R
Orbay, Hakan
et al.

Publication Date

2017-05-01

DOI

10.1097/sap.0000000000000954

Peer reviewed

Intraoperative Placement of Pectoral Nerve Block Catheters

Description of a Novel Technique and Review of the Literature

Katharine M. Hinchcliff, MD,* Jared R. Hylton, MD,† Hakan Orbay, MD, PhD,*
and Michael S. Wong, MD*

Abstract: Regional and neuraxial anesthesia for pain management after breast surgery is not widely used despite data showing improved postoperative pain control and patient satisfaction scores. We report a case of a 61-year-old woman who underwent bilateral mastectomies, and received postoperative analgesia via pectoral nerves 1 and 2 nerve blocks. This case highlights a previously undescribed technique of prolonged postoperative pain control by intraoperative placement of pectoral nerves 1 and 2 regional anesthesia catheters under direct visualization. Intraoperative placement has the potential benefits of more accurate plane targeting, time saving, and widening the scope of use to practitioners are not trained in the ultrasound guided technique. We also present a review of the regional block techniques and present a preliminary algorithm for the selection of block method in breast surgery.

Key Words: nerve block, anesthesia, regional, pectoral nerves, breast reconstruction

(*Ann Plast Surg* 2017;00: 00–00)

Regional nerve blockade improves postoperative analgesia with decreased anesthetic and opiate use, decreases hospital length of stay, and improves patient satisfaction scores.^{1–5} Using nerve blocks to limit general anesthesia (GA) and improve postoperative analgesia is additionally important due to the mounting evidence that volatile anesthetics and opioid analgesics impair immune function,^{6,7} and increase the risk of ileus, thromboembolism, and myocardial infarction.⁸ Despite these advantages, the use of regional nerve blockade is still limited to selected cases.

Regional nerve blockade for postoperative analgesia after breast surgery is most commonly achieved with thoracic epidural catheters and paravertebral blocks (PVB), although other blocks have also been reported.^{9–11} Pectoral nerve (Pecs) blocks are ultrasound guided interfascial plane blocks that target tissue planes between the pectoralis major and minor (Pecs I), and the pectoralis minor and serratus anterior muscles (Pecs II)^{12,13} Targeting these planes with local anesthetic blocks the medial and lateral pectoral nerves, anterior divisions of the thoracic intercostal nerves from T2 to T6, long thoracic nerve, and thoracodorsal nerves providing analgesia to the anterior and lateral thoracic walls with an extension into axilla (Fig. 1). Pecs blocks have shown excellent efficacy for analgesia after breast surgery.¹⁴ Drawbacks of the classic technique include the need for an ultrasound and an additional procedure before surgery.

Received July 24, 2016, and accepted for publication, after revision October 20, 2016. From the *Division of Plastic Surgery, Department of Surgery, and †Department of Anesthesiology and Pain Medicine, University of California-Davis Medical Center, Sacramento, CA.

Conflicts of interest and sources of funding: none declared.

This study was previously presented at the Annual Meeting of California Society of Plastic Surgeons, May 2016, Santa Monica, CA.

Reprints: Katharine M. Hinchcliff, MD, Division of Plastic Surgery, Cypress Building 2221 Stockton Blvd., Suite E, University of California-Davis Medical Center, Sacramento, CA 95817. E-mail: kmhinchcliff@ucdavis.edu

Copyright © 2017 Wolters Kluwer Health, Inc. All rights reserved.

ISSN: 0148-7043/17/0000-0000

DOI: 10.1097/SAP.0000000000000954

In this article, we present a novel technique for Pecs I and II blocks achieved by placement of infusion catheters under direct visualization during surgery. We also review the literature on regional anesthesia for breast surgery and propose a preliminary algorithm for block selection.

Case Report

A 61-year-old woman diagnosed with locally advanced stage IIB left breast cancer underwent a left modified radical mastectomy and a prophylactic right total mastectomy. After tissue resection, Pecs block catheters were placed intraoperatively under direct visualization by the surgical team with anesthesia assistance. We used an On-Q Pain Relief System (Kimberly-Clark, Roswell, Ga) with 20 gauge, 61-cm catheters. Separate catheters were placed into the Pecs I and II tissue planes on the patient's left side, and a single catheter was placed into the Pecs I tissue plane on the right side (Fig. 2). Approximately 5 cm of the catheter was placed within the corresponding tissue plane. After skin closure, catheters were bolused with 15 mL of 0.25% Ropivacaine. No breast reconstruction was performed per oncology and patient preference.

Postoperatively, 0.20% Ropivacaine was infused through the catheters at 6 mL/hour. Catheters were additionally bolused with a 10 mL of 0.25% Ropivacaine on postoperative days (POD) 1 and 2. The patient reported a pain score of "0" on a 0 to 10 analog scale in the post anesthesia care unit (PACU) and did not require any analgesic medication or anti-emetic medication while hospitalized. She was discharged to home on POD 2 with catheters and refilled medication pumps in place. The patient removed her catheters 48 hours after discharge per anesthesia instructions. She was healing well without complications at her follow-up visit on POD 10 and denied the use of any analgesics after discharge.

Literature Review

There are a number of regional nerve block techniques available for breast surgery (Table 1). Paravertebral blocks are well reported in major chest wall procedures and have been shown to decrease intraoperative and PACU opiate usage, postoperative nausea, and vomiting, as well as PACU and overall hospital stay.^{1,3–5,18} This neuraxial anesthetic technique is conducted with a bolus of local anesthetic injected into the paravertebral space and targets dermatomal spinal levels just lateral to the intervertebral foramina. Failure rates have been demonstrated at 6.1% using ultrasound, and 11.5% using the nerve stimulator.^{15,19}

Intercostal nerve blocks for breast surgery have been reported in both the anesthesia and plastic surgery literature for over 30 years.^{9,16} However, the last decade has brought a resurgence of interest in these blocks, to treat pain after traumatic rib fractures,²⁰ persistent postoperative pain,²¹ and for oncologic,²² and cosmetic breast surgery.^{17,23} The appeal of intercostal blocks can be partially attributed to the fact that the block sites are within the operative field, allowing intraoperative placement by the surgeon. Similar to PVB, retrospective studies have shown a decrease in postoperative opiate use and decreased hospital stay, although not all studies have shown a consistent benefit.²⁴ Intercostal blocks are placed at the mid to anterior axillary line, deep to the intercostal muscle fascia, and inferiorly to the corresponding rib.

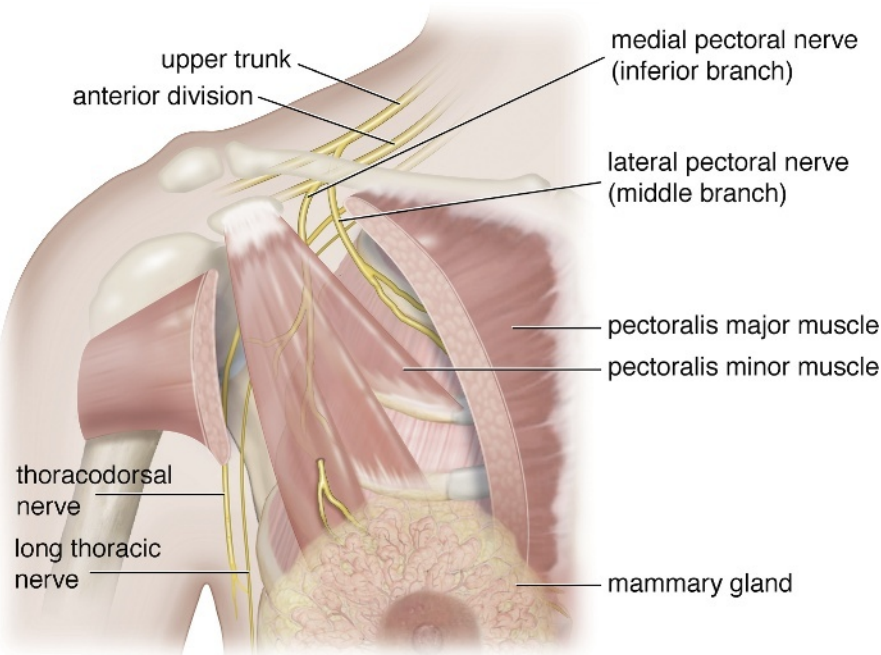


FIGURE 1. The illustration shows the anatomy relevant to Pecs blocks.

Blocks can be placed from T3 to T7. Unfortunately, specific failure rates have not been well reported in the literature. A retrospective study by Shimizu et al²³ did report a 12% rate of reported pain using intercostal blocks in addition to tumescent anesthesia for breast augmentation, although not severe enough to require conversion to a GA.

Pecs blocks were first described by Blanco in 2011.¹² The basic steps of the Pecs I block as described by Blanco involves: (i) identification of pectoralis major muscle, (ii) location of pectoral branch of the thoracoacromial artery between pectoralis muscles using color Doppler, (iii) infiltration of interfascial plane adjacent to the artery with 0.4 mg/kg 0.25% Bupivacaine using standard 50-mm block needles. Catheters can be placed, which can remain in place for up to 7 days. The Pecs II block is a modification of the original technique aimed at also providing regional anesthesia to the axilla and to the area overlying the serratus, thus improving pain control in patients with a wider lateral dissection (for example, tissue expander placement) and for those patients undergoing axillary dissections.¹³ The Pecs II block is achieved by initially performing Pecs I block in standard fashion, followed by a second injection of 10 to 20 mL of 0.25% Bupivacaine between the pectoralis minor and serratus anterior muscles.^{13,25} With the use of Bupivacaine, the onset of this block takes about 3 to 10 minutes, and lasts for approximately 8 to 12 hours. However, the literature illustrates decreased opiate consumption for up to 24 hours after surgery with Pecs II block. There are no studies on optimal catheter dosing, although 0.125% levobupivacaine at 5 mL/hour has been reported.¹³

Blanco noted the potential benefits of Pecs block to be a lower risk profile for ambulatory surgery and a particular analgesic benefit in patients with a subpectoral dissection for tissue expander placement.¹² Since its original description, both retrospective and prospective randomized studies have evaluated the efficacy of the Pecs block in breast surgery. All studies have demonstrated decreased intraoperative inhaled anesthetic requirements and lower postoperative pain score with the Pecs block combined with GA or PVB, as opposed to GA or PVB alone. The literature has also shown decreased intraoperative and postoperative opiate consumption for up to 24 hours after surgery, decreased length of stay in the PACU, decreased sedation scores, and decreased overall hospital stay all associated with Pecs 1 and 2 regional

blocks when used for breast surgery. No difference was seen in postoperative nausea and vomiting in retrospective studies, although prospective studies have demonstrated an improvement.^{14,26,27} Weaknesses of these studies include induction of anesthesia before assessing block success or failure and lack of specific reporting on complication rates.

When compared with the PVB for modified radical mastectomy, the Pecs blocks have demonstrated significantly lower subjective patient pain scores in the first 12 hours after surgery and a longer delay in the need for additional pain medications, although this finding was reversed at 18 and 24 hours. Similar satisfaction scores and rates of postoperative nausea and vomiting were seen in both groups.²⁸

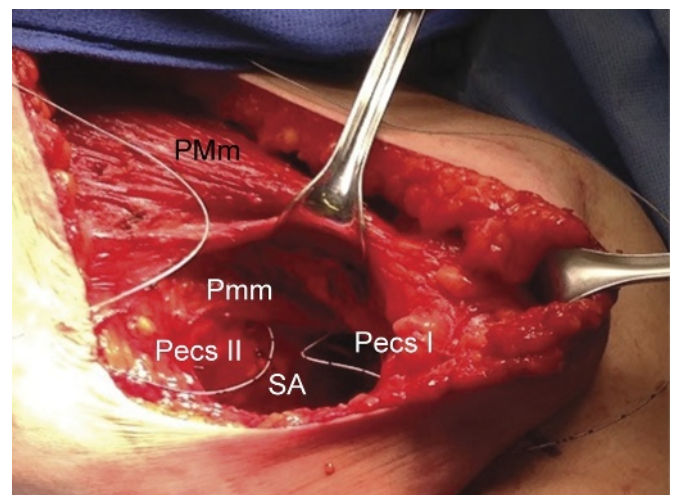


FIGURE 2. The picture shows the intraoperative placement of the catheters for Pecs I and II blocks on the patient's left breast. PMm, pectoralis major muscle; Pmm, pectoralis minor muscle; SA, serratus anterior muscle.

TABLE 1. Peripheral Nerve Blocks Used for Analgesia of Chest Wall

Block Type	Indications	Nerves Targeted	Advantages	Complications (%)*	Contraindications
Paravertebral	All breast and chest wall procedures	Spinal nerves	Well-tested efficacy without GA	Intrathecal spread (1) Sympathetic blockade (4) Intravascular injection (6.8) Pneumothorax (0.5)	Patient refusal Infection at injection site Anticoagulation
Pecs 1	Minor breast and chest wall procedures	MPN, LPN	Can be used as rescue block Ability to place intraoperatively Can leave catheters	Intra-arterial injection	Patient refusal Infection at injection site
Pecs 2	Breast and chest wall procedures, axillary dissection	MPN, LPN, intercostal nerves, intercostobrachial nerve, long thoracic nerve	Can be used as rescue block Ability to place intraoperatively Can leave catheters	Intra-arterial injection Pneumothorax	Patient refusal Infection at injection site
Intercostal	Minor breast and chest wall procedures, rib fractures	Intercostal nerves	Can use as rescue block Ability to place intraoperatively Can leave catheters	Intra-arterial injection (<1) Pneumothorax (<1)	Patient refusal Infection at injection site

*Data obtained from Naja and Lonnqvist,¹⁵ Moore and Bridenbaugh,¹⁶ and Vemula et al¹⁷ where percentages are not listed, there was no data available. MPN, medial pectoral nerve; LPN, lateral pectoral nerve.

Use of Pecs I block intraoperatively has been reported, with a single injection for submuscular implant placement.²⁹ Our study is the first to report postoperative analgesia by continuous infusion of local anesthetics through nerve block catheters placed into the Pecs 1 and Pecs 2 tissue planes.

Still lacking in the literature are reported failure and complication rates related to Pecs blocks. Complications currently are theoretical rather than reported, and include pneumothorax with the Pecs II block and risk of intravascular placement into the thoracoacromial artery with the Pecs I block. Cadaver studies have demonstrated that the risk of anesthetic spread to cause an iatrogenic brachial plexus block is unlikely.³⁰

Pectoralis Block Versus Pectoralis Muscle Infiltration

A confusing aspect of nomenclature is pectoralis major muscle infiltration versus pectoralis nerve block. There have been a number of case reports of pectoralis muscle infiltration, in which the cut end of the muscle is injected with a local anesthetic. In our estimation, this injection approximates a poorly targeted Pecs I block. The only prospective study on this infiltration technique compared pectoralis muscle infiltration with the intercostal block for use in submuscular breast augmentation in 28 patients and found no difference between the techniques.³¹

Liposomal Bupivacaine and Regional Anesthetic Adjunctive Medications

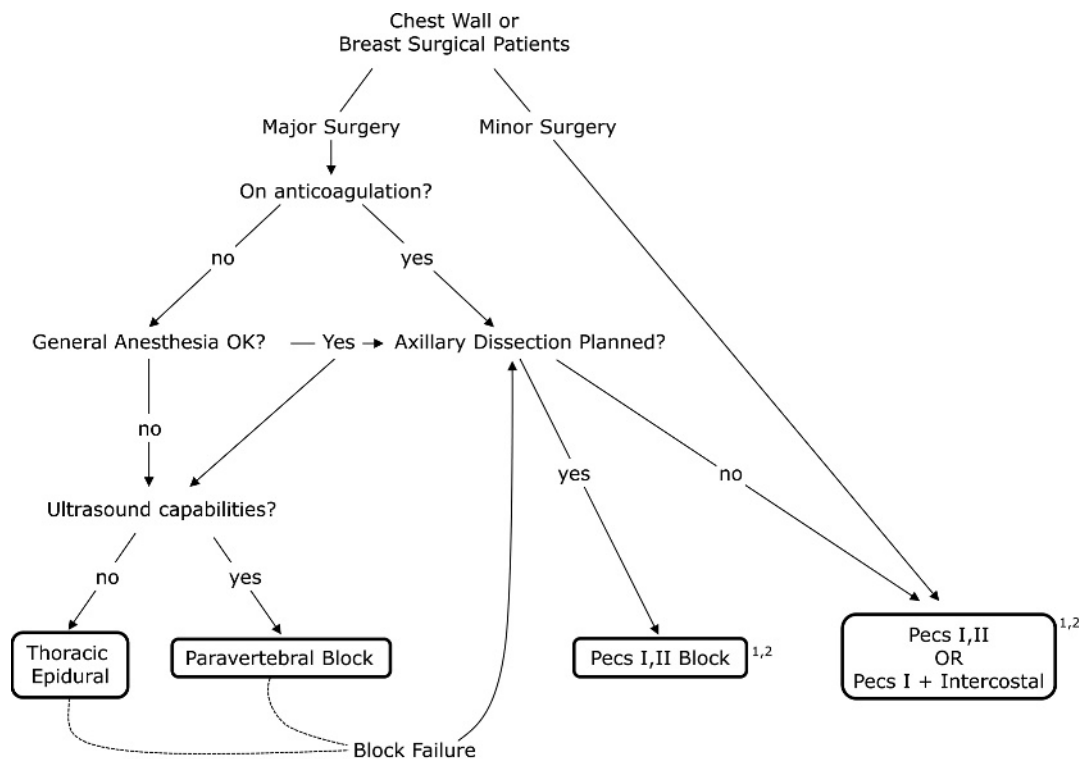
An area of active ongoing research within the regional anesthesia literature is improving block quality and block duration. Numerous medications have been investigated as adjuncts to the local anesthetic solution used for peripheral nerve blocks. Buprenorphine, ultralow dose naloxone, clonidine, dexamethasone, and magnesium have all been shown to increase block duration in a wide array of peripheral nerve blocks.³²⁻³⁵ Medication adjuncts for neuraxial anesthesia have also been extensively investigated. Dexmedetomidine added to local anesthetic has been shown to prolong sensory blockade with PVB compared with local anesthetic alone.³⁶ The use of clonidine with PVB has

showed variable but promising results that indicate it may also prolong the duration of sensory blockade.^{6,7} The unifying concept of how these adjunct medications complement the local anesthetic and prolong block duration centers around the concept of modulating ascending afferent sensory nerve transmission of noxious stimuli. Modulation is achieved by targeting other receptors involved in the ascending sensory pathways, beyond the Na-channel blockade provided by local anesthetic alone. An overview of the specific mechanism of action of each of the regional anesthetic block adjunctive medications is beyond the scope of this review.

Another development bearing mention is the use of liposomal bupivacaine (LB) (Exparel; bupivacaine liposome injectable suspension; Pacira Pharmaceuticals Inc, San Diego, Calif) in regional blocks. Liposomal bupivacaine offers longer acting analgesia than standard bupivacaine, with a gradual release of bupivacaine from liposomes over a few days. Case reports have demonstrated successful pain control and minimal narcotic requirements when used specifically with the Pecs I and II blocks.³⁷ Two retrospective studies comparing regional LB injection with paravertebral block³⁸ or bupivacaine pain pump³⁹ after mastectomy found some evidence of superiority of LB for postoperative pain control. However, multiple randomized controlled trials have failed to demonstrate an appreciable clinical difference when LB is compared with standard bupivacaine for breast surgery⁴⁰ or other general surgeries.⁴¹ Further prospective studies are needed to determine the utility of LB in targeted nerve blocks.

Algorithm for Block Selection in Breast Surgery

Based on the literature review and our experiences, we offer an algorithm for block selection. We propose that block selection depends mainly on the planned surgical procedure (Fig. 3). For minor chest wall procedures, Pecs I, II or a combination of Pecs I and intercostal blocks provide sufficient anesthesia and are our preferred methods considering the more serious adverse events with PVB.^{15,16,22,42} In case of major chest wall surgery, factors requiring consideration include: (i) use of



¹ Consider catheter placement or liposomal Bupivacaine if planned inpatient stay or chronic pain patient.

² Intraoperative block placement if no ultrasound capabilities or obese patient.

FIGURE 3. Algorithm for the selection of regional block method in breast surgery.

anticoagulant medication, (ii) planned axillary dissection, and (iii) availability of ultrasound and ultrasound trained personnel.

DISCUSSION/CONCLUSION

Regional nerve blocks are commonly used as accessory analgesic methods to limit the need for GA.^{25,36,43,44} To date, the use of Pecs blocks alone for breast surgery has mostly been limited to outpatient cosmetic breast surgery.^{17,23,45} No studies to date have detailed use of Pecs blocks alone for use in oncologic resections or reconstructions, although it seems likely that these reports are forthcoming in patients at high risk for GA.

The main disadvantages of the classic Pecs blocks are the need for ultrasound trained personnel, increased anesthesia wait times as well as the need for a secondary procedure. Placement of the blocks under direct visualization, as described in this article, addresses these limitations and allows more accurate plane targeting. Additionally, leaving catheters enables a prolonged and more controlled postoperative analgesia in comparison to single, ultrasound guided injections. However, planned placement of a permanent implant may make the use of an internal-external catheter less attractive.

In our case, the use of Pecs blocks provided an excellent postoperative analgesia to the point our patient required no additional analgesic medication. We believe that regional anesthesia will become a standard of care and may effectively replace GA for certain cases. However, prospective randomized controlled trials are required to truly elucidate the individualized indications for the different regional blocks in postoperative pain management after breast surgery. Other directions for future research include comparing different drugs and block additives, cost analyses, and better reporting of complication rates, likely in the form of multicenter data.

It is worth noting that the concept of a proactive approach to pain management extends far beyond regional blocks. In reality, focusing on pain management alone as a way to improve postoperative recovery is really an obsolete idea. Multimodal Enhanced Recovery After Surgery (ERAS) protocols have succeeded in decreasing the hospital length of stay and improving patient satisfaction in multiple surgical specialties, including plastic surgery. These protocols address factors that keep patients hospitalized after surgery, of which postoperative pain is just one component. The ERAS pain management protocols focus on the use of non-narcotic adjuncts, such as celecoxib and gabapentin, dosed even before surgery, in addition to nerve blocks.⁴⁶ We anticipate the wide adoption of ERAS protocols and foresee our algorithm as providing one piece to a comprehensive, proactive postoperative management plan.

In conclusion, our case highlights a previously undescribed technique of intraoperative placement of Pecs block catheters for prolonged postoperative analgesia after mastectomy. The modifications described here allow for more accurate plane targeting, time savings, and widens the scope of use to practitioners not trained in the ultrasound guided technique.

ACKNOWLEDGMENTS

Authors would like to thank Sarah A. StClaire for her technical assistance with the illustrations.

REFERENCES

1. Wu J, Buggy D, Fleischmann E, et al. Thoracic paravertebral regional anesthesia improves analgesia after breast cancer surgery: a randomized controlled multicentre clinical trial. *Can J Anaesth.* 2015;62:241–251.
2. Pei L, Zhou Y, Tan G, et al. Ultrasound-assisted thoracic paravertebral block reduces intraoperative opioid requirement and improves analgesia after breast

- cancer surgery: a randomized, controlled single-center trial. *PLoS One*. 2015; 10:e0142249.
3. Moller JF, Nikolajsen L, Rodt SA, et al. Thoracic paravertebral block for breast cancer surgery: a randomized double-blind study. *Anesth Analg*. 2007; 105:1848–1851, table of contents.
 4. Abdallah FW, Morgan PJ, Cil T, et al. Ultrasound-guided multilevel paravertebral blocks and total intravenous anesthesia improve the quality of recovery after ambulatory breast tumor resection. *Anesthesiology*. 2014;120:703–713.
 5. Wolf O, Clemens MW, Purugganan RV, et al. A prospective, randomized, controlled trial of paravertebral block versus general anesthesia alone for prosthetic breast reconstruction. *Plast Reconstr Surg*. 2016;137:660e–666e.
 6. Procopio MA, Rassias AJ, DeLeo JA, et al. The in vivo effects of general and epidural anesthesia on human immune function. *Anesth Analg*. 2001;93:460–5, 4th contents page.
 7. Gong L, Dong C, Ouyang W, et al. Regulatory T cells: a possible promising approach to cancer recurrence induced by morphine. *Med Hypotheses*. 2013;80: 308–310.
 8. Joshi GP, Ogunnaike BO. Consequences of inadequate postoperative pain relief and chronic persistent postoperative pain. *Anesthesiol Clin North America*. 2005;23:21–36.
 9. Huang TT, Parks DH, Lewis SR. Outpatient breast surgery under intercostal block anesthesia. *Plast Reconstr Surg*. 1979;63:299–303.
 10. Lynch EP, Welch KJ, Carabuena JM, et al. Thoracic epidural anesthesia improves outcome after breast surgery. *Ann Surg*. 1995;222:663–669.
 11. Pusch F, Freitag H, Weinstabl C, et al. Single-injection paravertebral block compared to general anaesthesia in breast surgery. *Acta Anaesthesiol Scand*. 1999; 43:770–774.
 12. Blanco R. The 'pecc block': a novel technique for providing analgesia after breast surgery. *Anaesthesia*. 2011;66:847–848.
 13. Blanco R, Fajardo M, Parras Maldonado T. Ultrasound description of Pecs II (modified Pecs I): a novel approach to breast surgery. *Rev Esp Anesthesiol Reanim*. 2012;59:470–475.
 14. Bashandy GM, Abbas DN. Pectoral nerves I and II blocks in multimodal analgesia for breast cancer surgery: a randomized clinical trial. *Reg Anesth Pain Med*. 2015; 40:68–74.
 15. Naja Z, Lonnqvist PA. Somatic paravertebral nerve blockade. Incidence of failed block and complications. *Anaesthesia*. 2001;56:1184–1188.
 16. Moore DC, Bridenbaugh LD. Intercostal nerve block in 4333 patients: indications, technique, and complications. *Anesth Analg*. 1962;41:1–11.
 17. Vemula R, Kutzin M, Greco G, et al. The use of intercostal nerve blocks for implant-based breast surgery. *Plast Reconstr Surg*. 2013;132:178e–80e.
 18. Fahy AS, Jakub JW, Dy BM, et al. Paravertebral blocks in patients undergoing mastectomy with or without immediate reconstruction provides improved pain control and decreased postoperative nausea and vomiting. *Ann Surg Oncol*. 2014;21:3284–3289.
 19. Naja ZM, Naccache N, Ziade F, et al. Multilevel nerve stimulator-guided paravertebral block as a sole anesthetic technique for breast cancer surgery in morbidly obese patients. *J Anesth*. 2011;25:760–764.
 20. Hwang EG, Lee Y. Effectiveness of intercostal nerve block for management of pain in rib fracture patients. *J Exerc Rehabil*. 2014;10:241–244.
 21. Wijayasinghe N, Duriand HM, Kehlet H, et al. Ultrasound guided intercostobrachial nerve blockade in patients with persistent pain after breast cancer surgery: a pilot study. *Pain Physician*. 2016;19:E309–E318.
 22. Shah A, Rowlands M, Krishnan N, et al. Thoracic intercostal nerve blocks reduce opioid consumption and length of stay in patients undergoing implant-based breast reconstruction. *Plast Reconstr Surg*. 2015;136:584e–91e.
 23. Shimizu Y, Nagasao T, Taneda H, et al. Combined usage of intercostal nerve block and tumescent anaesthesia: an effective anaesthesia technique for breast augmentation. *J Plast Surg Hand Surg*. 2014. 48:51–55.
 24. Hidalgo DA, Pusic AL. The role of methocarbamol and intercostal nerve blocks for pain management in breast augmentation. *Aesthet Surg J*. 2005;25:571–575.
 25. Bolin ED, Robert HN, Sylvia HW. Regional anesthesia for breast surgery: techniques and benefits. *Curr Anesthesiol Rep*, 2015.
 26. Morioka, Pectoral Nerve Block Combined with General Anesthesia for Breast Cancer Surgery: A Retrospective Comparison. *Journal of Clinical Reports*. 2015;1.
 27. Sopena-Zubiria LA, Fernández-Meré LA, Valdés Arias C, et al. Thoracic paravertebral block compared to thoracic paravertebral block plus pectoral nerve block in reconstructive breast surgery. *Rev Esp Anesthesiol Reanim*. 2012;59: 12–17.
 28. Sherif Samir Wahba SMK. Thoracic paravertebral block versus pectoral nerve block for analgesia after breast surgery. *Egypt J Anesth*. 2013;30:129–135.
 29. Haydon NB, van der Rijt R, Downs C, et al. A novel technique of intraoperative lateral pectoral nerve block during subpectoral breast implant placement. *Plast Reconstr Surg Glob Open*. 2016;4:e646.
 30. Desroches J, Grabs U, Grabs D. Selective ultrasound guided pectoral nerve targeting in breast augmentation: How to spare the brachial plexus cords? *Clin Anat*. 2013;26:49–55.
 31. Nasr MW, Habre SB, Jabbour H, et al. A randomized controlled trial of postoperative pain control after subpectoral breast augmentation using intercostal nerve block versus bupivacaine pectoralis major infiltration: a pilot study. *J Plast Reconstr Aesthet Surg*. 2015;68:e83–e84.
 32. Candido K, Winnie AP, Ghaleb AH, et al. Buprenorphine added to the local anesthetic for axillary brachial plexus block prolongs postoperative analgesia. *Reg Anesth Pain Med*. 2002;27:162–167.
 33. Movafegh A, Razazian M, Hajimaohamadi F, et al. Dexamethasone added to lidocaine prolongs axillary brachial plexus blockade. *Anesthesia & Analgesia*. 2006; 102:263–267.
 34. McCartney CJ, Duggan E, Apatu E. Should we add clonidine to local anesthetic for peripheral nerve blockade? A qualitative systematic review of the literature. *Reg Anesth Pain Med*. 2007;32:330–338.
 35. Movafegh A, Nouralishahi B, Sadeghi M, et al. An ultra-low dose of naloxone added to lidocaine or lidocaine-fentanyl mixture prolongs axillary brachial plexus blockade. *Anesth Analg*. 2009;109:1679–1683.
 36. Ueshima H, Kitamura A. Clinical experiences of ultrasound-guided transversus thoracic muscle plane block: a clinical experience. *J Clin Anesth*. 2015;27: 428–429.
 37. Leiman D, Barlow M, Carpin K, et al. Medial and lateral pectoral nerve block with liposomal bupivacaine for the management of postsurgical pain after submuscular breast augmentation. *Plast Reconstr Surg Glob Open*. 2014;2:e282.
 38. Abdelsattar JM, Boughey JC, Fahy AS, et al. Comparative study of liposomal bupivacaine versus paravertebral block for pain control following mastectomy with immediate tissue expander reconstruction. *Ann Surg Oncol*. 2016;23: 465–470.
 39. Butz DR, Shenaq DS, Rundell VL, et al. Postoperative pain and length of stay lowered by use of exparel in immediate, implant-based breast reconstruction. *Plast Reconstr Surg Glob Open*. 2015;3:e391.
 40. Nadeau MH, Saraswat A, Vasko A, et al. Bupivacaine versus liposomal bupivacaine for postoperative pain control after augmentation mammoplasty: a prospective, randomized, double-blind trial. *Aesthet Surg J*. 2016;36:Np47–52.
 41. Noviasky J, Pierce DP, Whalen K, et al. Bupivacaine liposomal versus bupivacaine: comparative review. *Hosp Pharm*. 2014;49:539–543.
 42. Lonnqvist PA, MacKenzie J, Soni AK, et al. Paravertebral blockade. Failure rate and complications. *Anaesthesia*. 1995;50:813–815.
 43. Fujiwara A, Komasa N, Minami T. Pectoral nerves (PECS) and intercostal nerve block for cardiac resynchronization therapy device implantation. *Springerplus*. 2014;3:409.
 44. Purcell N, Wu D. Novel use of the PECS II block for upper limb fistula surgery. *Anaesthesia*. 2014;69:1294.
 45. Colque A, Eisemann ML. Breast augmentation and augmentation-mastopexy with local anesthesia and intravenous sedation. *Aesthet Surg J*. 2012;32:303–307.
 46. Batdorf N, Lemaire V, Lovely JK, et al. Enhanced recovery after surgery in microvascular breast reconstruction. *J Plast Reconstr Aesthet Surg*. 2015;68:395–402.