

# UC Irvine

## UC Irvine Previously Published Works

### Title

Antivascular Endothelial Growth Factor Antibody for Treatment of Glioblastoma Multiforme

### Permalink

<https://escholarship.org/uc/item/9db4b7s8>

### Journal

The Permanente Journal, 17(4)

### ISSN

1552-5767

### Authors

Hanson, Joseph A  
Hsu, Frank PK  
Jacob, Arun T  
[et al.](#)

### Publication Date

2013-12-01

### DOI

10.7812/tpp/13-081

### Copyright Information

This work is made available under the terms of a Creative Commons Attribution License, available at <https://creativecommons.org/licenses/by/4.0/>

Peer reviewed

# Antivascular Endothelial Growth Factor Antibody for Treatment of Glioblastoma Multiforme

Joseph A Hanson; Frank P K Hsu, MD, PhD; Arun T Jacob, MD; Daniela A Bota, MD, PhD; Daniela Alexandru, MD

Perm J 2013 Fall;17(4):68-74

<http://dx.doi.org/10.7812/TPP/13-081>

## Abstract

Despite aggressive investigation, glioblastoma multiforme (GBM) remains one of the deadliest cancers, with low progression-free survival and high one-year mortality. Current first-line therapy includes surgery with adjuvant radiation therapy and cytotoxic chemotherapy, but virtually all tumors recur. Given the highly vascular nature of GBM and its high expression of vascular endothelial growth factor and other angiogenic factors, recent investigation has turned to bevacizumab, an antivascular endothelial growth factor monoclonal antibody, for treatment of recurrent GBM. Phase 2 studies demonstrated the efficacy and safety of bevacizumab therapy for recurrent GBM, which led to its approval by the US Food and Drug Administration in 2009 for use in recurrent GBM. Since then, several new Phase 2 studies and retrospective series have demonstrated that bevacizumab significantly increased six-month progression-free survival in patients with recurrent GBM and may do so in new-onset GBM. The objective of this review is to provide a collective resource for these materials, highlighting the efficacy and safety of bevacizumab and calling for increased investigation toward its optimal application in the management of high-grade glioma.

## Introduction

Glioblastoma multiforme (GBM) is a highly aggressive tumor with a rapid progression and poor prognosis. This tumor comprises nearly 50% of gliomas and 25% of all primary brain tumors.<sup>1-3</sup> According to the most recent report from the Central Brain Tumor Registry of the United States, there are approximately 10,000 new cases of GBM recorded annually in the US.<sup>3</sup> The development of GBM is positively correlated with age, reaching a peak in gross incidence at 45 to 64 years<sup>4</sup> and highest per capita incidence at ages 74 to 85 years.<sup>3</sup>

Unfortunately, GBM is the most deadly form of glioma, classified as Stage 4 infiltrative glioma by the World Health Organization.<sup>5</sup> The median overall survival is poor, ranging from 9 to 19 months in maximally treated patients,<sup>6,7</sup> and the 1-year survival rate has been recorded at approximately 32%.<sup>2</sup> Survival rates have historically increased with the advent of new surgical techniques and chemo-

therapeutic options,<sup>2</sup> and they continue to slowly rise.<sup>4</sup> GBM, however, recurs almost universally regardless of treatment regimen.

The extent of surgical resection is an independent risk factor for survival, with gross total resection increasing survival.<sup>6,8,9</sup> However, even those patients with radiographically demonstrated resection in excess of 98% tumor volume experience nearly 100% recurrence, presumably because of the persistence of quiescent glioblastoma tumorigenic stem cells.<sup>8,10</sup>

Standard therapy for GBM involves surgical resection to the maximal extent possible with adjuvant radiotherapy and chemotherapy. Initial studies examined nitrosourea-based compounds to target GBM because of their lipophilicity and ability to cross the blood-brain barrier. Large meta-analyses have revealed that lomustine and carmustine in combination with whole-brain radiation or stereotactic radiotherapy yielded only modest results, with 1-year survival up to 35%, a 6%

increase compared with radiotherapy alone.<sup>11</sup> Phase 2 trials for combinations of carboplatin, procarbazine, and fluorouracil were similarly unimpressive, reaching a 1-year survival proportion of 32%.<sup>12</sup>

Temozolomide (Temodar, Schering-Plough Corp, Kenilworth, NJ) is an alkylating agent approved by the US Food and Drug Administration (FDA) for use in newly diagnosed GBM,<sup>13</sup> which has been successfully used in the treatment of GBM. The Stupp protocol demonstrated increased survival of 2.5 months (12.2 months to 14.6 months) with the addition of temozolomide at dosages of 75 mg/m<sup>2</sup>/day for 7 days during radiotherapy and not exceeding 49 days.<sup>7,14,15</sup> Following a 4-week break in therapy, temozolomide was administered again for 5 days in 28-day cycles for between 1 and 6 cycles. The study demonstrated a survival benefit at 2 years of 27.2% for patients receiving adjuvant temozolomide after maximal surgical resection, up from 10.9% in patients with adjuvant radiotherapy alone.<sup>7</sup> The survival benefit at 5 years was 9.8% for patients with combination therapy compared with 1.9% for patients who received radiation therapy alone.<sup>7,14,15</sup>

With the advent of temozolomide for the treatment of GBM, a new gene product was identified that conferred survival advantage. Expression of O<sup>6</sup>-methylguanine-DNA methyltransferase (MGMT), an enzyme involved in DNA repair, was linked to shorter survival.<sup>16</sup> The epigenetic silencing of the MGMT expression by methylation of the promoter was linked with a survival advantage in patients receiving temozolomide, with an overall survival of 18.2 months in patients with MGMT methylation compared with 12.2 months in patients without MGMT methylation.<sup>16</sup>

**Joseph A Hanson** is a Medical Student in the Departments of Neurology and Neurosurgery at the University of California Irvine in the City of Orange. E-mail: jhanson1@uci.edu. **Frank P K Hsu, MD, PhD**, is a Professor in the Department of Neurosurgery at the University of California Irvine in the City of Orange. E-mail: fpkhsu@uci.edu. **Arun T Jacob, MD**, is a Neurosurgeon in the Department of Neurosurgery at Baptist Memorial Healthcare in Memphis, TN. E-mail: aruntjacob@gmail.com. **Daniela A Bota, MD, PhD**, is an Assistant Professor in the Department of Neurology at the University of California Irvine in the City of Orange. E-mail: dbota@uci.edu. **Daniela Alexandru, MD**, is a Neurosurgeon at the University of California Irvine Medical Center in Orange. E-mail: danielaa@uci.edu.

Despite chemotherapy and radiation, GBM universally recurs, and at recurrence the disease rapidly becomes lethal.<sup>12</sup> Some of the treatments considered at recurrence were repeated surgery, repeated irradiation, or other chemotherapies,<sup>17,18</sup> which all have yielded less than modest results. Because of the altered signaling pathways and frequent mutations found in GBM, the focus of therapy has shifted toward the use of biologics and target-specific molecular drugs for treatment.<sup>18</sup> Bevacizumab (Avastin, Genentech, South San Francisco, CA) is a humanized antivascular endothelial growth factor (anti-VEGF) immunoglobulin G1 monoclonal antibody that was granted accelerated FDA approval in 2009 as a single-agent therapy for use in recurrent

GBM refractory to prior chemotherapy or radiotherapy (Figure 1).<sup>19</sup> This review will evaluate the theoretical mechanism of bevacizumab and its use and efficacy in treating glioma, to demonstrate the benefits it yields for well-selected patients with newly diagnosed or recurrent GBM.

### Angiogenesis, Vascular Endothelial Growth Factor, and Glioblastoma

Angiogenesis, the process of creating new blood vessels and vascular branches from preexisting tissues, is a vital component of tumorigenesis; it is required for solid tumor growth beyond a 0.125-mm radius because of limitations in nutrient and oxygen diffusion capacity.<sup>20</sup> This process requires an abundance of unique

growth factors and cell adhesion molecules, which include different isoforms of VEGF (VEGF-A, VEGF-B, VEGF-C, and VEGF-D) as well as platelet-derived growth factor.<sup>21</sup> A receptor tyrosine kinase ligand, VEGF-A has been identified as a key promoter of tumor angiogenesis.<sup>22</sup> In tumor microenvironments such as GBM, VEGF secretion is increased to promote abnormal angiogenesis.<sup>23</sup> In GBM, the highest concentrations of VEGF are found in areas of necrosis and hypoxia in the tumor, because VEGF production is stimulated in tumorigenic glial cells by hypoxia and the concomitant upregulation of hypoxia inducible factor-1.<sup>24</sup> The resultant vasculature is often abnormal, creating the potential for the development of new areas of necrosis and hypoxia, thus

**Table 1. Bevacizumab for recurrent glioblastoma multiforme**

| Author                             | Trial         | Combination therapy                        | Use                  | Number | Median age, years (range) | KPS        | 6-month PFS (95% CI) | Median PFS  | Median OS   |
|------------------------------------|---------------|--|----------------------|--------|---------------------------|------------|----------------------|-------------|-------------|
| Friedman, <sup>32</sup> 2009       | Phase 2       | Irinotecan                                 | Adjuvant, recurrence | 85     | 54 (23-78)                | > 70       | 42.6% (29.6%-55.5%)  | 4.2 months  | 9.2 months  |
|                                    |               | None                                       | Adjuvant, recurrence | 82     | 57 (23-79)                | > 70       | 50.3% (36.8%-63.9%)  | 5.6 months  | 8.7 months  |
| Vredenburg, <sup>34</sup> 2007     | Phase 2       | Irinotecan                                 | Adjuvant, recurrence | 35     | 48 (18-66)                | 3% < 70    | 46% (32%-66%)        | 24 weeks    | 42 weeks    |
| Vredenburg, <sup>47</sup> 2012     | Phase 2       | Radiotherapy, temozolomide                 | Adjuvant             | 125    | 56.2 (19-80)              | > 70       | —                    | 13.8 months | —           |
| Norden, <sup>36</sup> 2009         | Phase 2       | Irinotecan                                 | Adjuvant, recurrence | 34     | 54.5 (31-74)              | > 70       | 40.0%                | 21.9 weeks  | 37.4 weeks  |
| Bokstein, <sup>35</sup> 2007       | Phase 2       | Irinotecan                                 | Adjuvant, recurrence | 17     | 56 (38-74)                | > 50       | 25.0%                | 4.2 months  | 7 months    |
| Kreisl, <sup>39</sup> 2009         | Phase 2       | None; irinotecan on disease progression    | Adjuvant, recurrence | 48     | 53 (21-69)                | > 60       | 29% (18%-48%)        | 16 weeks    | 31 weeks    |
| Lai, <sup>45</sup> 2011            | Phase 2       | Radiotherapy, temozolomide                 | Adjuvant             | 70     | 57.4 (31.3-75.8)          | > 60       | —                    | 13.6 months | 19.6 months |
| Cohen, <sup>19</sup> 2009          | Phase 2       | Irinotecan                                 | Adjuvant, recurrence | 85     | 54 (23-78)                | > 70       | 36.0% (25.0%-47.0%)  | 4.2 months  | —           |
|                                    |               | Irinotecan                                 | Adjuvant, recurrence | 56     | 54 (21-69)                | > 70       | —                    | 3.9 months  | —           |
| Ali, <sup>37</sup> 2008            | Case series   | Irinotecan                                 | Adjuvant, recurrence | 13     | 53 (32-76)                | —          | —                    | 24 weeks    | 27 weeks    |
| Hasselbalch, <sup>33</sup> 2010    | Phase 2       | Irinotecan, cetuximab                      | Adjuvant, recurrence | 43     | 54 (23-70)                | —          | 33% (19%-48%)        | 16 weeks    | 30 weeks    |
| Nghiempfu, <sup>50</sup> 2009      | Retrospective | None; irinotecan                           | Adjuvant, recurrence | 44     | —                         | —          | —                    | 4.25 months | 9.0 months  |
| Gutin, <sup>41</sup> 2009          | Phase 2       | Hypofractionated stereotactic radiotherapy | Adjuvant, recurrence | 20     | 56                        | —          | 65.0%                | —           | 12.5 months |
| Chamberlain, <sup>40</sup> 2010    | Retrospective | None                                       | Adjuvant, recurrence | 50     | 64 (36-70)                | > 60       | 42.0%                | 1 month     | 8.5 months  |
| Gilbert, <sup>38</sup> 2009        | Phase 2       | Irinotecan                                 | Adjuvant, recurrence | 57     | 57                        | Median: 80 | 37% (24-50%)         | —           | —           |
| Sathornsumetee, <sup>42</sup> 2010 | Phase 2       | Erlotinib                                  | Adjuvant, recurrence | 25     | 52.4 (24.1-70.4)          | > 70       | 29.2% (13.0%-47.6%)  | 18 weeks    | 44.6 weeks  |

CI = confidence interval; KPS = Karnofsky performance score; OS = overall survival; PFS = progression-free survival; (—) = none described.

continuing the cycle.<sup>24</sup> Both the density of the microvasculature and the level of VEGF secretion in glial tumors have been associated with tumor grade and clinical outcomes, with low overall survival scores for patients who expressed high levels of messenger RNA secretion.<sup>18,25-27</sup> Therefore, the development of an antiangiogenic biologic therapy targeting VEGF-A for highly vascular tumors such as glioblastoma gained popularity.<sup>28</sup> It is postulated that anti-VEGF-A immunoglobulin G acts by sequestering VEGF and therefore preventing the protein from initiating the signaling cascade, which will lead to recruitment of endothelial cells and proliferation of blood vessels (Figure 2).

In glioma models the preclinical data for the use of bevacizumab showed that the tumors exhibited microvascular regression, normalization of mature blood vessels, and inhibition of new vessel growth.<sup>29</sup> Clinical trials demonstrated efficacy of bevacizumab and led to FDA approval for use in malignant colorectal cancer in 2004 and recurrent glioblastoma in 2009.<sup>22</sup> Two independent, randomized, prospective trials of bevacizumab for recurrent GBM demonstrated an increase in progression-free survival (PFS) of 3.9 to 4.2 months in patients with recurrent disease already treated with prior surgery, radiotherapy, and temozolomide.<sup>19</sup> Bevacizumab received accelerated approval as single-agent therapy for recurrent GBM refractory to surgical treatment, chemotherapy, and radiotherapy.<sup>19</sup>

### Bevacizumab Use in Glioblastoma

Most investigations into bevacizumab therapy for GBM have consisted of Phase 2 trials to determine safety and efficacy of the biologic agent in patients who have recurrence of GBM after attempting first-line surgical resection followed by adjuvant radiotherapy and temozolomide chemotherapy. The primary endpoint for these studies was 6-month PFS<sup>30</sup>; the North American Brain Tumor Consortium uses 6-month PFS as the efficacy endpoint of therapeutic trials for adult patients with recurrent high-grade gliomas.<sup>31</sup> Historic evidence suggests that 6-month PFS in absence of treatment of recurrent GBM ranges from 9%<sup>30</sup> to 16%.<sup>31</sup> These findings are based on retrospective data from pooled trials of nonefficacious therapies; most investigators usually tailor their studies to demonstrate the presence or lack of a significant difference from this baseline.

Patient populations are typically selected on the basis of performance status, failure of first-line therapy with radiologic proof of disease progression, and lack of major comorbidities in light of a histologic diagnosis of Grade 4 glioma. Exclusion criteria generally include previous treatment with carmustine wafer or anti-VEGF agents; history of bleeding diathesis, intracranial hemorrhage, or coagulopathy; clinically significant cardiovascular disease; recent arterial thromboembolism; uncontrolled hypertension; and Karnofsky performance score less than 70.<sup>19,32,33</sup>

### Efficacy

In the first prospective Phase 2 trial of bevacizumab, Vredenburgh et al<sup>34</sup> administered irinotecan, a topoisomerase inhibitor, as conjunctive adjuvant therapy because of the combination's history of success in colorectal cancer. They observed partial or complete response in 20 (57%) of 35 patients, with a 6-month PFS rate of 46% (n = 16; 95% confidence interval [CI], 32%-66%),<sup>34</sup> in excess of the baseline 6-month PFS rate of 9% to 16% in 345 untreated patients with recurrent GBM.<sup>30,31</sup> A study sponsored by Genentech demonstrated similar findings, noting a 6-month PFS rate of 36.0% (n = 31; CI, 25.0%-47.0%) in a Phase 2 trial of bevacizumab and irinotecan in 85 patients.<sup>19</sup> Since that time, multiple authors have documented

6-month PFS rates for bevacizumab and irinotecan combination therapy between 25% and 40% (Table 1).<sup>35-38</sup> Friedman et al<sup>32</sup> performed a large trial both with and without combination irinotecan therapy. They found a 6-month PFS rate of 42.6% (CI, 29.6%-55.5%) in patients receiving combination irinotecan-bevacizumab therapy and a 6-month PFS rate of 50.3% (CI, 36.8%-63.9%) in those receiving single-agent bevacizumab, with no significant difference in 6-month PFS or median PFS between the 2 arms. Investigation into bevacizumab monotherapy has yielded similar results. Kreisl et al<sup>39</sup> recorded a 6-month PFS rate of 29% (n = 14; CI, 18%-48%) in a Phase 2 trial of 48 patients, and Chamberlain and Johnston<sup>40</sup> found a 6-month PFS rate of 42% (n = 21) in a retrospective review of 50 patients using bevacizumab monotherapy. Overall, the results between single-agent bevacizumab and combination therapy with cytotoxic agents, specifically irinotecan, have been similar to date, with no clear superiority among either regimen.

New combination therapies are currently under clinical investigation as well. Hasselbalch et al<sup>35</sup> combined adjuvant bevacizumab therapy with irinotecan and cetuximab, a monoclonal anti-epidermal growth factor antibody also used in colorectal cancer, and reported a 6-month PFS of 33% (n = 14; CI 19%-48%) among 43 patients. Gutin et al<sup>41</sup> administered hypofractionated stereotactic radiotherapy in combination with bevacizumab for treatment of recurrent GBM in 20 patients and reported a 65% (n = 13; CI unreported) 6-month PFS. Additionally, Sathornsumetee et al<sup>42</sup> combined bevacizumab with erlotinib, an epidermal growth factor receptor tyrosine kinase inhibitor, in 25 patients with recurrent GBM and found a 6-month PFS rate of 29.2% (n = 7).

These studies are noncomparative, Phase 2 safety studies, and there is no statistically significant evidence to indicate the comparative effectiveness of bevacizumab in single-agent or combination therapy for recurrent GBM. However, all studies in our literature search, regardless of combination therapy, reported 6-month PFS rates in excess of 25% (Table 1), suggesting that there may be benefit to bevacizumab therapy in delaying disease progression.

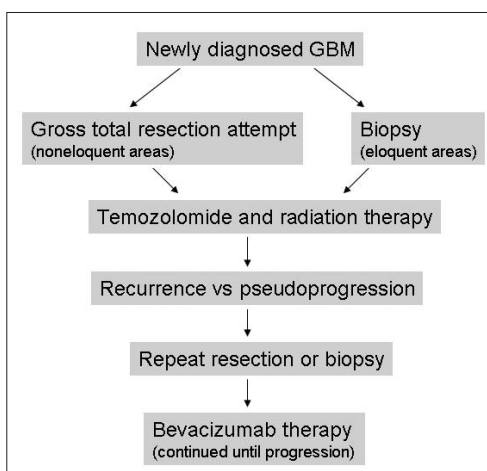
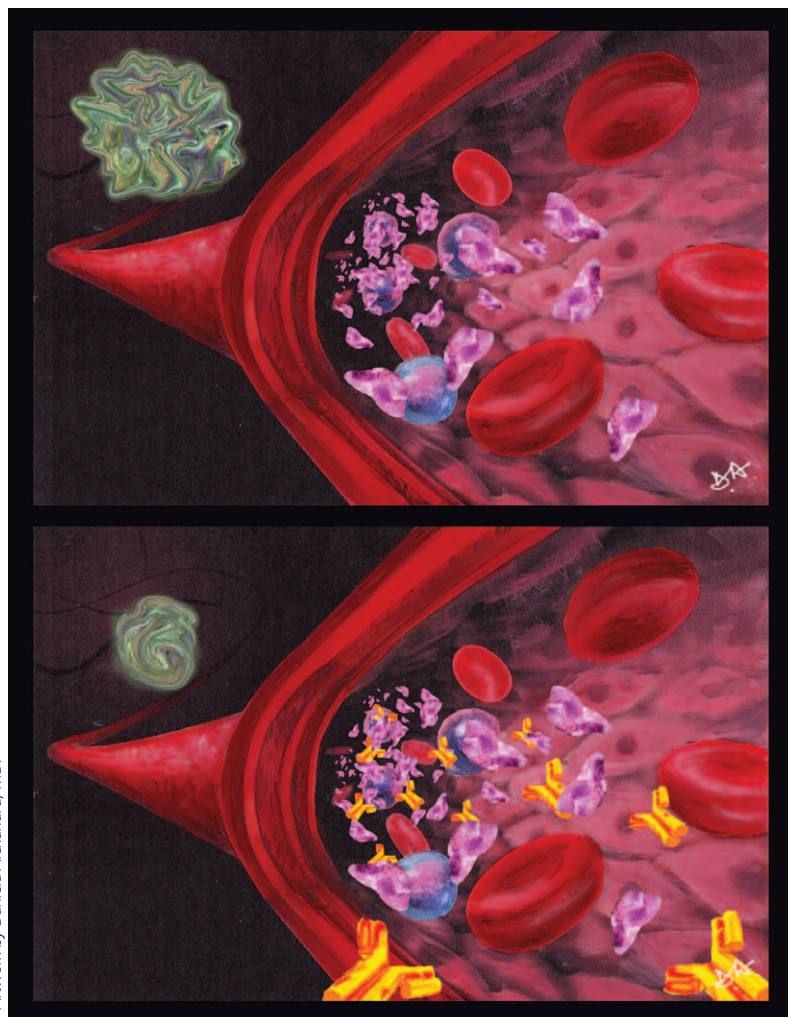


Figure 1. Treatment algorithm for glioblastoma multiforme (GBM).



Artwork by Daniela Alexandru, MD.

Figure 2. Artist's depiction of mechanism of action of bevacizumab. Tumor secretes vascular endothelial growth factor (VEGF) to promote proliferation of blood vessels (top). Bevacizumab sequesters VEGF, leading to decreased vascular proliferation and decreased tumor size (bottom).

### Safety

Bevacizumab is typically well tolerated by patients, and its side effect profile in those with GBM is equivalent to the adverse events encountered in patients receiving bevacizumab therapy for malignant colorectal cancer, non-small-cell lung cancer, and metastatic breast cancer.<sup>43</sup> In trials of bevacizumab for recurrent GBM, the most commonly encountered Grade 3 or 4 adverse events (graded according to the National Cancer Institute Common Terminology Criteria for Adverse Events, version 3.0)<sup>44</sup> include hypertension, hemorrhage (eg, epistaxis, intracranial), thromboembolic complications, and convulsions.<sup>32</sup> Other serious adverse events reported in the literature include proteinuria, gastrointestinal tract perforation, wound healing complications, reversible posterior leukoencephalopathic syndrome, intractable convulsion, and neutropenia,<sup>32</sup> but the frequency of such outcomes is generally very low (< 4% in large studies).<sup>19,32</sup>

The overall rate of Grade 3 or greater adverse events in studies of bevacizumab to date has ranged from 12% to 66%<sup>32,35</sup> (Table 2). These events are hypothesized to be caused by the incidental effect of anti-VEGF blockade on the vasculature of normal healthy tissues or caused by postoperative wound healing complications presumably caused by inhibition of neovascularization of wound tissue in neurosurgical patients.<sup>18</sup> Although there are no formal recommendations for the interval between surgery and initiation of bevacizumab therapy in patients after repeated surgical resection of GBM, most

| Table 2. Adverse outcomes in bevacizumab trials |                       |   |                                    |  |
|---|-----------------------|---|------------------------------------|--|
| Author  | Combination therapy   | Grade $\geq 3$ adverse events, percentage | Grade 5 adverse events, percentage | Description of Grade 5 adverse events                              |
| Friedman, <sup>32</sup> 2009                    | Irinotecan            | 65.8                                      | 1.3                                | Convulsion   |
|   | None                  | 46.4                                      | 2.5                                | Neutropenia/infection, pulmonary embolism                          |
| Vredenburgh, <sup>34</sup> 2007                 | Irinotecan            | 22.9                                      | 0.0                                | —  |
| Bokstein, <sup>35</sup> 2007                    | Irinotecan            | 11.8                                      | 0.0                                | —  |
| Kreisl, <sup>39</sup> 2009                      | None                  | 27.1                                      | 0.0                                | —  |
| Cohen, <sup>19</sup> 2009                       | Irinotecan            | 46.4                                      | 3.6                                | Neutropenia/infection, pulmonary embolism, operative complications |
| Ali, <sup>37</sup> 2008                         | Irinotecan            | 23.1                                      | 0.0                                | —  |
| Hasselbalch, <sup>33</sup> 2010                 | Irinotecan, cetuximab | 58.0                                      | 0.0                                | —  |
| Chamberlain, <sup>40</sup> 2010                 | None                  | 24.0                                      | 0.0                                | —  |
| Gilbert, <sup>38</sup> 2009                     | Irinotecan            | 49.0                                      | 2.0                                | Intracranial hemorrhage  |

(—) = none described.

studies in the literature cite 3 to 4 weeks as an appropriately safe interval.<sup>41,45</sup> Neurosurgeons and neuro-oncologists should be wary of the potential for adverse outcomes with premature repeated operation in patients using bevacizumab who require additional resection of tumor after initiation of adjuvant chemotherapy.

Grade 5 events (ie, those leading to death) are rare, occurring in less than 3.6% of patients (Table 2). Causes of mortality in clinical studies thus far include infection secondary to drug-induced neutropenia, pulmonary embolism, and intracranial hemorrhage.<sup>19,32,38</sup> Even in studies in which fatal intracranial hemorrhage occurred,<sup>38</sup> the rate of hemorrhage approaches the expected incidence of intracranial hemorrhage in patients with intracranial malignancy in the absence of treatment (approximately 2.5%).<sup>46</sup>

There is some evidence that single-agent bevacizumab is associated with lower rates of Grade 3 or higher adverse events than combination therapy with irinotecan.<sup>18,38,40</sup> Chamberlain et al<sup>40</sup> and Kreisl et al<sup>38</sup> noted Grade 3 or greater adverse events in only 24.0% to 27.1% of enrolled patients receiving single-agent bevacizumab therapy, whereas benchmark studies for combined bevacizumab and irinotecan treatment, such as by Friedman et al,<sup>32</sup> found rates of Grade 3 or greater adverse events as high as 65.8%. Regardless, these data are limited to cross-trial comparisons of different study populations. Friedman and colleagues' own single-agent bevacizumab arm had Grade 3 or greater adverse events in 46.4% of patients, and any differences in the safety profile of single-agent or combined therapies of bevacizumab are still speculative at this time.

#### Prospects for Future Use

More recent investigations have led to the experimental use of bevacizumab as combination therapy with first-line adjuvant radiotherapy and temozolomide after surgical resection of new-onset GBM. Vredenburgh et al<sup>47</sup> treated 125

patients with bevacizumab, radiotherapy, and temozolomide beginning 4 weeks after surgical resection and found no increase in patient dropout compared with similar trials of radiotherapy and temozolomide in the absence of bevacizumab. They found that 93% of patients were able to tolerate combined adjuvant therapy of irradiation, temozolomide, and bevacizumab compared with an 83% completion rate in similar trials of temozolomide and irradiation alone.<sup>47</sup> Importantly, less than 2% of patients enrolled experienced clinically significant intracranial hemorrhage or craniotomy wound dehiscence despite theoretical concerns of increased risks of wound healing complications.<sup>47</sup> Furthermore, the median PFS was measured at 13.8 months, which compared favorably with the median PFS of 6.9 months in similar temozolomide and radiotherapy trials.<sup>14</sup>

Lai et al<sup>45</sup> also treated 70 patients with adjuvant bevacizumab, temozolomide, and radiotherapy in new-onset GBM and recorded a statistically significant increase in 6-month PFS (range, 7.6 months to 13.6 months) without change in median overall survival compared with accumulated data of radiotherapy plus temozolomide without bevacizumab given at their institution.

These were noncomparative trials to determine the efficacy and safety of bevacizumab in combination with radiotherapy and temozolomide. Bevacizumab is currently labeled for use only in patients with recurrent GBM with progression after the options of surgical resection, radiotherapy, and temozolomide chemotherapy have been exhausted. Phase 2 studies of temozolomide have shown a 6-month PFS of 13% to 29% (95% CI) in temozolomide-treated patients<sup>48</sup>; these studies suggest that bevacizumab may provide clinical benefit above this benchmark. The potential safety of bevacizumab after a sufficient postoperative interval is theorized to increase the clinical benefit of angiogenic inhibition and to improve the clinical effect of bevacizumab.<sup>47</sup>

#### Discussion

Glioblastoma multiforme is a highly aggressive and deadly class of malignancy. Patients receiving this diagnosis have on average less than a year to live,

and even those who respond to first-line therapy will likely face most of that time neurologically impaired or debilitated. Furthermore, the financial expense of bevacizumab is daunting. One study estimated the cost per quality-adjusted life year for use in colorectal and breast cancer at approximately \$300,000.<sup>49</sup> Even for these neurologically intact patients, only 25% of surveyed oncologists believed that bevacizumab offered "good value."<sup>49</sup> However, most surveyed oncologists believe that patients should have access to high-quality care despite the financial costs of treatment, as it is difficult to place a price tag on extending life.<sup>49</sup>

Options for patients with GBM are limited at tumor recurrence. Often, repeated irradiation and repeated surgery are not suitable options, and the tumors have already demonstrated resistance to first-line cytotoxic alkylating therapy with temozolomide.<sup>18</sup> Despite the data supporting the safety and efficacy of bevacizumab (measured by increased 6-month PFS) in patients with recurrent GBM (Tables 1 and 2), some studies show only a very modest increase in median overall survival.<sup>36</sup> Lai et al,<sup>45</sup> in their study of bevacizumab in combination with adjuvant radiotherapy and temozolomide in new-onset GBM, also found a statistically significant difference in 6-month PFS among patients receiving bevacizumab compared with historic institutional data without corresponding change in median overall survival. This suggests that the use of bevacizumab delays progression. Although it has little effect on overall survival, bevacizumab therapy maintains the patient's Karnofsky performance score by increasing the PFS and consequently increasing the quality of life.

However, there exist no reliable a priori evaluations to determine whether a patient is suitable for bevacizumab therapy, or in which patients bevacizumab will provide optimal benefit.<sup>18</sup> Increased age (> 55 years) and lower performance (Karnofsky performance score < 80) has been associated with greater benefit from bevacizumab, possibly because of the higher VEGF expression in these patients.<sup>50</sup> Furthermore, patients treated with bevacizumab are able to maintain functional status longer than patients historically not

**Although it has little effect on overall survival, bevacizumab therapy maintains the patient's Karnofsky performance score by increasing the PFS and consequently increasing the quality of life.**

treated with bevacizumab.<sup>50</sup> Age at time of diagnosis is still the strongest prognostic indicator for survival in GBM, with median survival as low as 2 months in patients older than age 80 years.<sup>51</sup> Although overall survival for patients with GBM has increased since the 1990s, the youngest (aged 20 to 44 years) and most functional patients have received the greatest benefit, achieving 2-year survival rates as high as 39%; the most elderly patients (aged > 80 years) have experienced minimal benefit and have achieved a disappointing 2-year survival rate of 1%.<sup>4</sup>

Recent studies of bevacizumab threaten to change this trend by increasing the median PFS and prolonging the functional status of patients whose disease was previously resistant to traditional radiotherapy and cytotoxic adjuvant therapies. Furthermore, recent studies have begun experimental investigation into the use of bevacizumab as adjuvant therapy for new-onset GBM.<sup>45,47</sup> Given the antiangiogenic mechanism of bevacizumab, it is widely theorized that early administration of VEGF inhibitors will prevent wound healing and increase operative complications.<sup>52</sup> These studies suggest not only that postoperative administration of bevacizumab (after an appropriate time window) is safe, it may actually be efficacious in prolonging median PFS and increasing six-month PFS.<sup>45,47</sup> Preliminary results from the AVAglio study, the first prospective Phase 3 trial for the use of bevacizumab (Avastin) in recurrent glioma, were recently announced at the 2013 American Society of Clinical Oncology meeting. The study found that the addition of bevacizumab to treatment of newly diagnosed GBM did not improve overall survival, although it did improve the PFS but not to a significant statistical criterion.<sup>53</sup> The study also found that the MGMT methylation profile did not identify to be a selective benefit, but instead was a risk subset. To date, the results of this study suggest that bevacizumab should not be used as first-line therapy for the treatment of GBM.

Bevacizumab has been shown to be safe in new-onset and recurrent disease. This is especially important for older patients (age > 55 years) for whom the prognosis is worse and the benefits of bevacizumab more promising. More pro-

spective Phase 3 trials are needed to determine the appropriate patient population for bevacizumab therapy, the appropriate combination therapy, and the appropriate timing of therapy (adjuvant for new-onset vs recurrent disease). Although the effect on overall survival and the appropriate patient population is still unclear for bevacizumab, its ability to increase the number of patients who survive for 6 months without impairment should be cause for further investigation and clinical use. ❖

#### Disclosure Statement

*The author(s) have no conflicts of interest to disclose.*

#### Acknowledgment

*Kathleen Loudon, ELS, of Loudon Health Communications provided editorial assistance.*

#### References

- Hess KR, Broglio KR, Bondy ML. Adult glioma incidence trends in the United States, 1977-2000. *Cancer* 2004 Nov 15;101(10):2293-9. DOI: <http://dx.doi.org/10.1002/cncr.20621>
- Deorah S, Lynch CF, Sibenaller ZA, Ryken TC. Trends in brain cancer incidence and survival in the United States: Surveillance, Epidemiology, and End Results Program, 1973 to 2001. *Neurosurg Focus* 2006 Apr 15;20(4):E1. DOI: <http://dx.doi.org/10.3171/foc.2006.20.4.E1>
- Dolecek TA, Propp JM, Stroup NE, Kruchko C. CBTRUS statistical report: primary brain and central nervous system tumors diagnosed in the United States in 2005-2009. *Neuro Oncol* 2012 Nov;14 Suppl 5:v1-49. DOI: <http://dx.doi.org/10.1093/neuonc/nos218>  
Erratum in: *Neuro Oncol* 2013 May;15(5):646-7. DOI: <http://dx.doi.org/10.1093/neuonc/nos389>
- Darefsky AS, King JT Jr, Dubrow R. Adult glioblastoma multiforme survival in the temozolomide era: a population-based analysis of Surveillance, Epidemiology, and End Results registries. *Cancer* 2012 Apr 15;118(8):2163-72. DOI: <http://dx.doi.org/10.1002/cncr.26494>
- Fuller GN, Scheithauer BW. The 2007 Revised World Health Organization (WHO) Classification of Tumours of the Central Nervous System: newly codified entities. *Brain Pathol* 2007 Jul;17(3):304-7. DOI: <http://dx.doi.org/10.1111/j.1750-3639.2007.00084.x>
- Laws ER, Parney IF, Huang W, et al; Glioma Outcomes Investigators. Survival following surgery and prognostic factors for recently diagnosed malignant glioma: data from the Glioma Outcomes Project. *J Neurosurg* 2003 Sep;99(3):467-73. DOI: <http://dx.doi.org/10.3171/jns.2003.99.3.0467>
- Stupp R, Hegi ME, Mason WP, et al; European Organisation for Research and Treatment of Cancer Brain Tumour and Radiation Oncology Groups; National Cancer Institute of Canada Clinical Trials Group. Effects of radiotherapy with concomitant and adjuvant temozolomide versus radiotherapy alone on survival in glioblastoma in a randomised phase III study: 5-year analysis of the EORTC-NCIC trial. *Lancet Oncol* 2009 May;10(5):459-66. DOI: [http://dx.doi.org/10.1016/S1470-2045\(09\)70025-7](http://dx.doi.org/10.1016/S1470-2045(09)70025-7)

- Lacroix M, Abi-Said D, Fournay DR, et al. A multivariate analysis of 416 patients with glioblastoma multiforme: prognosis, extent of resection, and survival. *J Neurosurg* 2001 Aug;95(2):190-8. DOI: <http://dx.doi.org/10.3171/jns.2001.95.2.0190>
- Nitta T, Sato K. Prognostic implications of the extent of surgical resection in patients with intracranial malignant gliomas. *Cancer* 1995 Jun 1;75(11):2727-31. DOI: [http://dx.doi.org/10.1002/1097-0142\(19950601\)75:11<2727::AID-CNCR2820751115>3.0.CO;2-H](http://dx.doi.org/10.1002/1097-0142(19950601)75:11<2727::AID-CNCR2820751115>3.0.CO;2-H)
- Gilbertson RJ, Rich JN. Making a tumour's bed: glioblastoma stem cells and the vascular niche. *Nat Rev Cancer* 2007 Oct;7(10):733-6. DOI: <http://dx.doi.org/10.1038/nrc2246>
- Stewart LA. Chemotherapy in adult high-grade glioma: a systematic review and meta-analysis of individual patient data from 12 randomised trials. *Lancet* 2002 Mar 23;359(9311):1011-8. DOI: [http://dx.doi.org/10.1016/S0140-6736\(02\)08091-1](http://dx.doi.org/10.1016/S0140-6736(02)08091-1)
- Wong ET, Hess KR, Gleason MJ, et al. Outcomes and prognostic factors in recurrent glioma patients enrolled onto phase II clinical trials. *J Clin Oncol* 1999 Aug;17(8):2572-8.
- Friedman HS, Kerby T, Calvert H. Temozolomide and treatment of malignant glioma. *Clin Cancer Res* 2000 Jul;6(7):2585-97.
- Stupp R, Mason WP, van den Bent MJ, et al; European Organisation for Research and Treatment of Cancer Brain Tumor and Radiotherapy Groups; National Cancer Institute of Canada Clinical Trials Group. Radiotherapy plus concomitant and adjuvant temozolomide for glioblastoma. *N Engl J Med* 2005 Mar 10;352(10):987-96. DOI: <http://dx.doi.org/10.1056/NEJMoa043330>
- Stupp R, Hegi ME, Gilbert MR, Chakravarti A. Chemoradiotherapy in malignant glioma: standard of care and future directions. *J Clin Oncol* 2007 Sep 10;25(26):4127-36. DOI: <http://dx.doi.org/10.1200/JCO.2007.11.8554>
- Hegi ME, Liu L, Herman JG, et al. Correlation of O6-methylguanine methyltransferase (MGMT) promoter methylation with clinical outcomes in glioblastoma and clinical strategies to modulate MGMT activity. *J Clin Oncol* 2008 Sep 1;26(25):4189-99. DOI: <http://dx.doi.org/10.1200/JCO.2007.11.5964>
- Chamberlain MC. Emerging clinical principles on the use of bevacizumab for the treatment of malignant gliomas. *Cancer* 2010 Sep 1;116(17):3988-99. DOI: <http://dx.doi.org/10.1002/cncr.25256>
- Chamberlain MC. Bevacizumab for the treatment of recurrent glioblastoma. *Clin Med Insights Oncol* 2011;5:117-29. DOI: <http://dx.doi.org/10.4137/CMO.57232>
- Cohen MH, Shen YL, Keegan P, Pazdur R. FDA drug approval summary: bevacizumab (Avastin) as treatment of recurrent glioblastoma multiforme. *Oncologist* 2009 Nov;14(11):1131-8. DOI: <http://dx.doi.org/10.1634/theoncologist.2009-0121>
- Folkman J. Tumor angiogenesis: therapeutic implications. *N Engl J Med* 1971 Nov 18;285(21):1182-6. DOI: <http://dx.doi.org/10.1056/NEJM197111182852108>
- Bergers G, Benjamin LE. Tumorigenesis and the angiogenic switch. *Nat Rev Cancer* 2003 Jun;3(6):401-10. DOI: <http://dx.doi.org/10.1038/nrc1093>

22. Ferrara N, Kerbel RS. Angiogenesis as a therapeutic target. *Nature* 2005 Dec 15;438(7070):967-74. DOI: <http://dx.doi.org/10.1038/nature04483>
23. Salmaggi A, Eoli M, Frigerio S, et al. Intracavitary VEGF, bFGF, IL-8, IL-12 levels in primary and recurrent malignant glioma. *J Neurooncol* 2003 May;62(3):297-303.
24. Kaur B, Khwaja FW, Severson EA, Matheny SL, Brat DJ, Van Meir EG. Hypoxia and the hypoxia-inducible-factor pathway in glioma growth and angiogenesis. *Neuro Oncol* 2005 Apr;7(2):134-53. DOI: <http://dx.doi.org/10.1215/S1152851704001115>
25. Leon SP, Folkherth RD, Black PM. Microvessel density is a prognostic indicator for patients with astroglial brain tumors. *Cancer* 1996 Jan 15;77(2):362-72. DOI: [http://dx.doi.org/10.1002/\(SICI\)1097-0142\(19960115\)77:2<362::AID-CNCR20>3.0.CO;2-Z](http://dx.doi.org/10.1002/(SICI)1097-0142(19960115)77:2<362::AID-CNCR20>3.0.CO;2-Z)
26. Schmidt NO, Westphal M, Haged C, et al. Levels of vascular endothelial growth factor, hepatocyte growth factor/scatter factor and basic fibroblast growth factor in human gliomas and their relation to angiogenesis. *Int J Cancer* 1999 Feb 19;84(1):10-8. DOI: [http://dx.doi.org/10.1002/\(SICI\)1097-0215\(19990219\)84:1<10::AID-IJC3>3.3.CO;2-C](http://dx.doi.org/10.1002/(SICI)1097-0215(19990219)84:1<10::AID-IJC3>3.3.CO;2-C)
27. Zhou YH, Tan F, Hess KR, Yung WK. The expression of PAX6, PTEN, vascular endothelial growth factor, and epidermal growth factor receptor in gliomas: relationship to tumor grade and survival. *Clin Cancer Res* 2003 Aug 15;9(9):3369-75.
28. Lamszus K, Ulbricht U, Matschke J, Brockmann MA, Fillbrandt R, Westphal M. Levels of soluble vascular endothelial growth factor (VEGF) receptor 1 in astrocytic tumors and its relation to malignancy, vascularity, and VEGF-A. *Clin Cancer Res* 2003 Apr;9(4):1399-405.
29. Rubenstein JL, Kim J, Ozawa T, et al. Anti-VEGF antibody treatment of glioblastoma prolongs survival but results in increased vascular cooperation. *Neoplasia* 2000 Jul-Aug;2(4):306-14. DOI: <http://dx.doi.org/10.1038/sj.neo.7900102>
30. Ballman KV, Buckner JC, Brown PD, et al. The relationship between six-month progression-free survival and 12-month overall survival end points for phase II trials in patients with glioblastoma multiforme. *Neuro Oncol* 2007 Jan;9(1):29-38. DOI: <http://dx.doi.org/10.1215/15228517-2006-025>
31. Lamborn KR, Yung WA, Chang SM, et al; North American Brain Tumor Consortium. Progression-free survival: an important end point in evaluating therapy for recurrent high-grade gliomas. *Neuro Oncol* 2008 Apr;10(2):162-70. DOI: <http://dx.doi.org/10.1215/15228517-2007-062>
32. Friedman HS, Prados MD, Wen PY, et al. Bevacizumab alone and in combination with irinotecan in recurrent glioblastoma. *J Clin Oncol* 2009 Oct 1;27(28):4733-40. DOI: <http://dx.doi.org/10.1200/JCO.2008.19.8721>
33. Hasselbalch B, Lassen U, Hansen S, et al. Cetuximab, bevacizumab, and irinotecan for patients with primary glioblastoma and progression after radiation therapy and temozolomide: a phase II trial. *Neuro Oncol* 2010 May;12(5):508-16. DOI: <http://dx.doi.org/10.1093/neuonc/nop063>
34. Vredenburgh JJ, Desjardins A, Herndon JE 2nd, et al. Bevacizumab plus irinotecan in recurrent glioblastoma multiforme. *J Clin Oncol* 2007 Oct 20;25(30):4722-9. DOI: <http://dx.doi.org/10.1200/JCO.2007.12.2440>
35. Bokstein F, Shpigel S, Blumenthal DT. Treatment with bevacizumab and irinotecan for recurrent high-grade glial tumors. *Cancer* 2008 May 15;112(10):2267-73. DOI: <http://dx.doi.org/10.1002/cncr.23401>
36. Norden AD, Drappatz J, Muzikansky A, et al. An exploratory survival analysis of anti-angiogenic therapy for recurrent malignant glioma. *J Neurooncol* 2009 Apr;92(2):149-55. DOI: <http://dx.doi.org/10.1007/s11060-008-9745-8>
37. Ali SA, McHayle WM, Ahmad A, et al. Bevacizumab and irinotecan therapy in glioblastoma multiforme: a series of 13 cases. *J Neurosurg* 2008 Aug;109(2):268-72. DOI: <http://dx.doi.org/10.3171/JNS.2008.109.8.0268>
38. Gilbert MR, Wang M, Aldape K, et al. RTOG 0625: a phase II study of bevacizumab with irinotecan in recurrent glioblastoma (GBM). *J Clin Oncol (Meeting Abstracts)* 2009 May;27(15S):2011.
39. Kreisl TN, Kim L, Moore K, et al. Phase II trial of single-agent bevacizumab followed by bevacizumab plus irinotecan at tumor progression in recurrent glioblastoma. *J Clin Oncol* 2009 Feb 10;27(5):740-5. DOI: <http://dx.doi.org/10.1200/JCO.2008.16.3055>
40. Chamberlain MC, Johnston SK. Salvage therapy with single agent bevacizumab for recurrent glioblastoma. *J Neurooncol* 2010 Jan;96(2):259-69. DOI: <http://dx.doi.org/10.1007/s11060-009-9957-6>
41. Gutin PH, Iwamoto FM, Beal K, et al. Safety and efficacy of bevacizumab with hypofractionated stereotactic irradiation for recurrent malignant gliomas. *Int J Radiat Oncol Biol Phys* 2009 Sep 1;75(1):156-63. DOI: <http://dx.doi.org/10.1016/j.ijrobp.2008.10.043>
42. Sathornsumetee S, Desjardins A, Vredenburgh JJ, et al. Phase II trial of bevacizumab and erlotinib in patients with recurrent malignant glioma. *Neuro Oncol* 2010 Dec;12(12):1300-10. DOI: <http://dx.doi.org/10.1093/neuonc/noq099>
43. Hurwitz H, Saini S. Bevacizumab in the treatment of metastatic colorectal cancer: safety profile and management of adverse events. *Semin Oncol* 2006 Oct;33(5 Suppl 10):S26-34. DOI: <http://dx.doi.org/10.1053/j.seminoncol.2006.08.001>
44. Trotti A, Colevas AD, Setser A, et al. CTCAE v3.0: development of a comprehensive grading system for the adverse effects of cancer treatment. *Semin Radiat Oncol* 2003 Jul;13(3):176-81. DOI: [http://dx.doi.org/10.1016/S1053-4296\(03\)00031-6](http://dx.doi.org/10.1016/S1053-4296(03)00031-6)
45. Lai A, Tran A, Nghiemphu PL, et al. Phase II study of bevacizumab plus temozolomide during and after radiation therapy for patients with newly diagnosed glioblastoma multiforme. *J Clin Oncol* 2011 Jan 10;29(2):142-8. DOI: <http://dx.doi.org/10.1200/JCO.2010.30.2729>
46. Schrader B, Barth H, Lang EW, et al. Spontaneous intracranial haematomas caused by neoplasms. *Acta Neurochir (Wien)* 2000;142(9):979-85. DOI: <http://dx.doi.org/10.1007/s007010070052>
47. Vredenburgh JJ, Desjardins A, Kirkpatrick JP, et al. Addition of bevacizumab to standard radiation therapy and daily temozolomide is associated with minimal toxicity in newly diagnosed glioblastoma multiforme. *Int J Radiat Oncol Biol Phys* 2012 Jan 1;82(1):58-66. DOI: <http://dx.doi.org/10.1016/j.ijrobp.2010.08.058>
48. Yung WK, Albright RE, Olson J, et al. A phase II study of temozolomide vs procarbazine in patients with glioblastoma multiforme at first relapse. *Br J Cancer* 2000 Sep;83(5):588-93. DOI: <http://dx.doi.org/10.1054/bjoc.2000.1316>
49. Nadler E, Eckert B, Neumann PJ. Do oncologists believe new cancer drugs offer good value? *Oncologist* 2006 Feb;11(2):90-5. DOI: <http://dx.doi.org/10.1634/theoncologist.11-2-90>
50. Nghiemphu PL, Liu W, Lee Y, et al. Bevacizumab and chemotherapy for recurrent glioblastoma: a single-institution experience. *Neurology* 2009 Apr 7;72(14):1217-22. DOI: <http://dx.doi.org/10.1212/01.wnl.0000345668.03039.90>
51. Ohgaki H, Kleihues P. Epidemiology and etiology of gliomas. *Acta Neuropathol* 2005 Jan;109(1):93-108. DOI: <http://dx.doi.org/10.1007/s00401-005-0991-y>
52. Clark AJ, Butowski NA, Chang SM, et al. Impact of bevacizumab chemotherapy on craniotomy wound healing. *J Neurosurg* 2011 Jun;114(6):1609-16. DOI: <http://dx.doi.org/10.3171/2010.10.JNS101042>
53. Chinot OL, de La Motte Rouge T, Moore N, et al. AVAglio: phase 3 trial of bevacizumab plus temozolomide and radiotherapy in newly diagnosed glioblastoma multiforme. *Adv Ther* 2011 Apr;28(4):334-40. DOI: <http://dx.doi.org/10.1007/s12325-011-0007-3>

## Mystery

As long as our brain is a mystery, the universe, the reflection of the structure of the brain, will also be a mystery.

— Santiago Ramón y Cajal, 1852-1934, Spanish pathologist, histologist, neuroscientist, and 1906 Nobel Laureate for Physiology or Medicine