

# UCLA

## UCLA Previously Published Works

### Title

Chest wall sarcomas are accurately diagnosed by image-guided core needle biopsy.

### Permalink

<https://escholarship.org/uc/item/9d94w7dx>

### Journal

Journal of thoracic oncology : official publication of the International Association for the Study of Lung Cancer, 7(1)

### ISSN

1556-0864

### Authors

Kachroo, Puja  
Pak, Peter S  
Sandha, Harpavan S  
et al.

### Publication Date

2012

### DOI

10.1097/jto.0b013e3182307f4c

Peer reviewed

# Chest Wall Sarcomas are Accurately Diagnosed by Image-Guided Core Needle Biopsy

Puja Kachroo, MD,\* Peter S. Pak, MD,\* Harpavan S. Sandha, MD,\* Scott D. Nelson, MD,†  
Leanne L. Seeger, MD,‡ Robert B. Cameron, MD,\* Fritz C. Eilber, MD,§ and Jay M. Lee, MD\*

**Objective:** Sarcomas are rare mesenchymal malignancies. Accurate preoperative diagnosis is a prerequisite in considering investigational or institutional management algorithms that include neoadjuvant treatment. We reviewed our experience using core needle biopsy for chest wall sarcomas.

**Methods:** A retrospective review of our sarcoma databases revealed that 40 core needle biopsies and 35 tumor resections were performed in 34 patients, with chest wall musculoskeletal tumors, referred to the University of California, Los Angeles from 1991 to 2010. Primary, metastatic, or recurrent sarcomas involving the sternum, ribs, and soft tissues of the chest wall were evaluated for (1) adequacy of tissue from image-guided core needle biopsies and (2) accuracy in determining malignancy, histological subtype, and sarcoma grade.

**Results:** Twenty-eight of the 40 needle biopsy samples (70%) were adequate for histopathological analysis. Forty-two percent of nondiagnostic findings occurred due to insufficient tissue, whereas the remainder had sufficient tissue, but the pathologist was unable to determine specific histology. Excluding the nondiagnostic samples, the accuracy in determining malignancy, histological subtype, and grade in sarcomas was 100, 92, and 87%, respectively. The sensitivity and specificity of determining malignancy and high-grade sarcomas were 100, 100, 77, and 100%, respectively. There were no complications from the image-guided biopsies.

**Conclusions:** We demonstrated that image-guided core needle biopsy when performed and reviewed by experienced radiologists and musculoskeletal pathologists is a safe and accurate diagnostic technique for chest wall sarcomas. Core needle biopsy should be considered in the multidisciplinary approach to chest wall musculoskeletal tumors, especially when induction therapy is considered.

**Key Words:** Chest wall, Sarcoma, Core needle biopsy.

(*J Thorac Oncol.* 2012;7: 151–156)

\*Division of Cardiac and Thoracic Surgery, Department of Surgery, †Department of Pathology and Laboratory Medicine, ‡Department of Radiology, §Division of Surgical Oncology, Department of Surgery, David Geffen School of Medicine at University of California, Los Angeles, Los Angeles, California.

Disclosure: The authors declare no conflicts of interest.

Address for correspondence: Jay M. Lee, MD, Division of Cardiac and Thoracic Surgery, Department of Surgery, Ronald Reagan UCLA Medical Center, Box 957313, Room 64-128 CHS, 10833 Le Conte Ave, Los Angeles, CA 90095-7313. E-mail: jaymoonlee@mednet.ucla.edu

Copyright © 2011 by the International Association for the Study of Lung Cancer

ISSN: 1556-0864/12/0701-0151

Sarcomas are a heterogeneous group of uncommon tumors that arise from mesenchymal cells, accounting for less than 1% of adult malignancies.<sup>1</sup> Many histological subtypes have been identified and are broadly divided into soft tissue or bony types. In the United States, there are approximately 7000 reported cases of soft tissue and 2500 bony sarcomas per year.<sup>2</sup> Approximately 7% of primary sarcomas arise from the chest wall and account for a significant number of deaths from malignant tumors.<sup>3</sup>

Although surgical resection is the established standard treatment of soft tissue and bony sarcomas, the impact of chemotherapy and/or radiation on more aggressive tumors remains unclear. Histology and grade are important factors in determining the use of these adjuvant modalities. Furthermore, the use of neoadjuvant or preoperative therapy, particularly in soft tissue sarcomas, is an evolving field of investigation and remains controversial. An accurate preoperative diagnosis of sarcoma and grade are prerequisites to investigational or institutional treatment algorithms that apply neoadjuvant approaches.

Previously, open surgical biopsies have been considered the gold standard for diagnosis but have associated complications, including risks for seroma, infection, wound dehiscence, and tumor implantation. Additional disadvantages include the time and cost of operating room usage and inappropriately placed incisions that may compromise definitive resection or cosmesis. Mankin et al.<sup>4</sup> reported open biopsy complication rates of 19.3% that resulted in alteration of treatment plans in 10.1% of patients. Alternatively, image-guided core needle biopsies have shown accurate diagnostic results without the disadvantages of surgical biopsy in the extremity.<sup>5–9</sup> Although there have been many studies that evaluated the experience of needle biopsies in chest wall lesions, these studies included all types of malignancies, particularly carcinomas, as well as benign tumors and abscesses. As such, reports that address the efficacy of core needle biopsies in chest wall musculoskeletal tumors and specifically its application in chest wall sarcomas are limited. This study focuses on our experience with the use of core needle biopsy in primary, metastatic, and recurrent sarcomas involving the sternum, ribs, or soft tissues of the chest wall and specifically addresses (1) adequacy of tissue sample obtained by needle biopsy and (2) accuracy in determining malignancy, histological subtype, and high grade differentiation.

## PATIENTS AND METHODS

A retrospective review of our prospectively maintained sarcoma databases revealed that 40 core needle biopsies were performed in 34 patients, with chest wall musculoskeletal tumors, referred to the David Geffen School of Medicine at University of California, Los Angeles between 1991 and 2010. Patient and tumor characteristics were obtained following institutional review board approval.

Chest wall tumor was defined as any neoplasm involving the sternum, clavicle, ribs, or soft tissues overlying the ribs. The core needle biopsy procedures were performed by five thoracic or musculoskeletal radiologists, who attend a weekly, multidisciplinary musculoskeletal (sarcoma) tumor board at a tertiary referral center that averages more than 1200 new sarcoma cases per year. All biopsies were performed in the outpatient setting using ultrasound or computed tomography (CT) guidance.

The technique of image-guided core needle biopsies at University of California, Los Angeles is described. The chest wall was prepped and draped sterilely before being infiltrated with 1% lidocaine for local anesthesia. Intravenous sedation was not required for any patient. Under image guidance, a large (11 or 17–19-gauge outer cannula) introducer needle was advanced to the proximal margin of the tumor, and a smaller (14 or 18–20-gauge cutting needle) core biopsy system was placed through the introducer needle to obtain the tissue sample. Soft tissue, lytic bony tumors or bony tumors with soft tissue extensions were biopsied using an automated 14-gauge cutting needle (Quickcore, Cook, Bloomington, IN). Variations in technique reflect the individual radiologist performing the procedure with respect to imaging modality, needle type, and needle size. High-resolution scans (single versus multidetector CT) were not required to localize the tumor or to guide needle entry and trajectory when performing needle biopsies. The decision of preferred imaging technique was made by the performing radiologist. In general, either modality can be used in chest wall tumors, especially when there is a significant extrathoracic component. In these situations, the larger needles (11-gauge outer and 14-gauge inner) were used. CT guidance with smaller needles was preferred particularly in situations where the chest wall tumor had a predominant intrathoracic component or in locations adjacent to the mediastinum. An average of four to six core samples with a cutting needle was taken from the mass. Tissue samples for hematoxylin and eosin staining and immunohistochemical testing were placed in formalin, and samples for karyotyping were placed in saline. Pressure was maintained on the skin entry site to achieve hemostasis.

The pathologic review of the core needle biopsy specimens was performed by one of two designated musculoskeletal pathologists, who attend and participate in a multidisciplinary, weekly musculoskeletal (sarcoma) tumor board. Soft tissue sarcomas were graded using the French Federation of Cancer Centers Sarcoma Group grading system, and bony sarcomas were classified as grade 1, 2, or 3 as per convention.

Adequacy of biopsies was defined as samples with sufficient tissue and cellular architecture allowing the pathologist to make a histologic diagnosis. Nondiagnostic biopsies

included either samples with insufficient amount of tissue or samples with sufficient cellularity but inadequate for a definitive pathologic diagnosis. Accuracy was defined as the ability to correctly determine (1) presence of malignancy, (2) histological subtype, and (3) sarcoma grade. Sensitivity, specificity, positive predictive value, and negative predictive value (NPV) for distinguishing tumor histology and grade were calculated from only adequate samples based on standard statistical definitions.

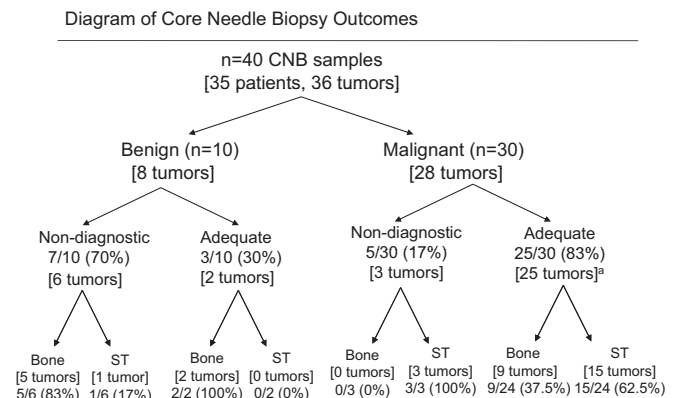
Based on pathologic findings from the core needle biopsy, patients with high-grade soft tissue and bony sarcomas sensitive to chemotherapy and/or radiation were selected to undergo neoadjuvant therapy. All patients subsequently underwent surgical extirpation. Most patients required full-thickness chest wall resection that included ribs. Forty core needle biopsy pathology findings were analyzed to determine adequacy of tissue sample obtained and were compared with the 35 surgically resected specimens to determine accuracy of diagnosis (benign versus malignant), histological subtype, and grade.

## RESULTS

Of the 34 patients referred to our institution for surgical management of their musculoskeletal chest wall tumors, a total of 40 core needle biopsies and 35 tumor resections were performed (Figure 1). Five patients had more than one core needle biopsy before surgical resection, and one patient with a recurrence underwent resection. There were no reported complications, including hemorrhage, pneumothorax, or neurovascular injury, from the image-guided needle biopsies.

### Patient Characteristics

Characteristics of the 34 patients that underwent surgical resection for chest wall tumors were evaluated (Table 1). Seven had benign (21%) and 27 (79%) had malignant tumors. There was even distribution by sex and wide range of ages; half of the patients (50%) were men with an average age of 54 years (range: 22–90 years). The most common examination finding was a palpable mass, and symptom was pain (Table 1).



**FIGURE 1.** Core needle biopsy outcomes. <sup>a</sup>One patient had a complete response; therefore, no malignant cells were present to classify bony versus soft tissue origin.

**TABLE 1.** Patient and Tumor Characteristics

	Benign	Malignant
Number of patients	7	27
Male	2	15
Female	5	12
Average age (yr)	50.4	55.1
Age range (yr)	22–81	28–90
Palpable mass	3 (43%)	13 (48%)
Pain symptoms	3 (43%)	10 (37%)
Number of resected tumors	7	28
Average size	8.4 cm	10.2 cm
Size range	4–15 cm	2–21 cm
Average volume <sup>a</sup>	254 cm <sup>3</sup>	524 cm <sup>3</sup>
Volume range	32–1200 cm <sup>3</sup>	11–2185 cm <sup>3</sup>
Low/intermediate grade <sup>b</sup>	NA	11/27 (41%)
High grade	NA	16/27 (59%)
Primary	7/7 (100%)	22/28 (79%)
Recurrent	NA	2/28 (7%)
Metastatic	NA	4/28 (14%)
Ribs resected	6/7 (86%)	24/28 (86%)
Number of ribs resected	0–6	0–8
Average ribs resected	2.1	3.0
Clavicle resected	0/8 (0%)	2/28 (7%)
Sternum resected	0/8 (0%)	7/28 (25%)

<sup>a</sup> Three malignant tumor volumes were unknown.

<sup>b</sup> One patient had a complete response, and no tumor was seen on final pathology. NA, not applicable.

## Core Needle Biopsy Outcomes

The results of the 40 core needle biopsy samples were analyzed (Figure 1). Ten samples were from benign and 30 were from malignant tumors. Most of the core needle biopsy samples from malignant neoplasms were adequate (83%), whereas in benign tumors, only 30% were adequate. The majority of the nondiagnostic samples from benign lesions were from bony tumors (80%), whereas the nondiagnostic samples from sarcomas were from soft tissue tumors (100%; Figure 1).

## Soft Tissue versus Bony Sarcomas

Of the 35 tumors, 19 (54%) were soft tissue and 15 (43%) were bony in origin (Figure 1). One patient diagnosed with treatment-related sarcoma (previously known as radiation associated sarcoma) on core needle biopsy had complete response to induction therapy and did not have any viable malignant cells on the resection specimen for pathologic comparison. There were six (86%) bony and one (14%) soft tissue tumors in the benign group. Among the sarcomas, nine (33%) were bony and 18 (67%) were soft tissue in origin (Figure 1).

## Detailed Tumor Characteristics

Tumor characteristics of the resected specimens are described (Table 1). Twenty-eight (80%) of the chest wall tumors were malignant, whereas seven (20%) were benign. The average size was large in both benign (8.4 cm) and malignant (10.2 cm) tumors. The majority of malignancies

were primary chest wall sarcomas (79%), whereas 14 and 7% were metastatic or recurrent, respectively. Most of the chest wall tumors required full thickness resection that included ribs in benign (86%) and malignant (86%) groups. Seven patients (25%) required partial or complete sternectomy for resection, and only two (7%) required concomitant clavicle resection.

The location of the tumors was widely distributed on the chest wall: 10 (29%) were anterior, 11 (31%) were posterior, and 10 (29%) were lateral. Four chest wall sarcomas arose in the sternum (14%). A vast array of different histological subtypes of chest wall musculoskeletal tumors was resected (Table 2).

## Nondiagnostic Core Needle Biopsies

There were 12 nondiagnostic core needle biopsy outcomes in eight patients. A detailed summary of the eight resected tumors are described (Table 3). Forty-two percent (5/12 biopsies) of nondiagnostic findings occurred due to insufficient tissue obtained at biopsy. The remainder had sufficient tissue, but the pathologist was unable to determine a specific histologic diagnosis (Table 3). Most of the nondiagnostic biopsy specimens were from benign musculoskeletal tumors. Five of the biopsies in the benign group occurred in bony tumors, suggesting a possible technical difficulty in needle penetration of the bony cortex. There was no identifiable age or gender predilection. All the tumors were at least 5 cm in size, and only one did not require rib resection.

**TABLE 2.** Final Histological Subtypes of Resected Specimens

	No. of Samples
Benign (n = 7)	
Periosteal chondroma	1
Chondroma	1
Polyostotic fibrous dysplasia	1
Giant cell tumor	1
Intraosseous hemangioma	1
Osteochondroma	1
Fibrolipoma	1
Malignant (n = 28) <sup>a</sup>	
Chondrosarcoma	5
Ewing sarcoma/PNET	4
Treatment-related sarcoma	4
Desmoid tumor	3
Leiomyosarcoma	2
Sarcoma not otherwise specified	2
Dedifferentiated liposarcoma	2
Solitary fibrous tumor	1
Malignant granular cell tumor	1
Synovial versus MPNST	1
Myxoid liposarcoma	1
Myxofibrosarcoma	1

<sup>a</sup> One patient had complete response to neoadjuvant therapy.

PNET, primitive neuroectodermal tumor; MPNST, malignant peripheral nerve sheath tumor.

**TABLE 3.** Nondiagnostic Core Needle Biopsies

Diagnosis	Age (yr)	Sex	Size (cm)	No. of Ribs	Grade	No. of CNB	Pathology Finding	Outcome
Benign								
Chondroma	78	M	6	2	NA	2	No. 1: Fibrofatty tissue, skeletal muscle No. 2: Low grade adipose tissue, fat necrosis	Resection
Periosteal chondroma	81	F	5.5	4	NA	2	No. 1: Hyaline cartilage No. 2: Insufficient tissue	Resection
Interosseous hemangioma	67	M	10	1	NA	1	Blood and inflammatory cells	Resection
Fibrolipoma	36	F	5	0	NA	1	Insufficient tissue	Resection
Giant cell tumor	31	F	13.5	1	NA	1	Giant cell rich lesion	Resection
Malignant								
Desmoid tumor	65	M	9.8	5	Low	3	No. 1: Unknown No. 2: Insufficient tissue No. 3: Insufficient tissue	Resection
Dedifferentiated liposarcoma	81	M	10	6	High	1	Insufficient tissue	Repeat CNB
Treatment-related sarcoma	38	F	8	1	High	1	Spindle cell proliferation	Open biopsy

CNB, core needle biopsy; NA, not applicable.

**TABLE 4.** Overall Accuracy of Core Needle Biopsy

	Benign	Malignant
Adequacy (%)	30	83
Correct malignancy (%)	NA	100
Correct grade (%)	NA	87
Correct histology (%)	100	92

NA, not applicable.

### Accuracy of Core Needle Biopsy

Diagnostic accuracy of core needle biopsy was evaluated in benign and malignant chest wall tumors (Table 4). Overall, 28 of the 40 core needle biopsy samples (70%) were adequate for histopathological diagnosis. The yield of core needle biopsy was better for malignant sarcomas compared with benign musculoskeletal tumors (Table 4). Of the adequate samples, the accuracy of determining malignancy versus benign was 100%. Of the malignant sarcomas, the accuracy for histologic subtype and grade was 92 and 87%, respectively. There was no difference in accuracy based on the location of the tumor on the chest wall.

The adequate core needle biopsy samples were evaluated for sensitivity and specificity (Table 5). With exclusion of the nondiagnostic samples, the sensitivity and specificity were both 100%. This demonstrates that a malignant diagnosis can be obtained confidently by core needle biopsy. The malignant core needle biopsy samples were evaluated for grade (Table 6). The sensitivity and specificity were 77 and 100%, respectively.

### COMMENT

Chest wall musculoskeletal tumors are comprised of many histological subtypes. Although certain bony sarcomas such as osteosarcoma or primitive neuroectodermal tumors (Ewing sarcoma) have accepted and established roles for chemotherapy and radiation, the application of multimodality approaches particularly in soft tissue sarcomas remains con-

**TABLE 5.** Accuracy of Malignancy from Adequate CNB Samples

CNB	Final Pathology		Total
	Benign	Malignant	
Benign	3	0	3
Malignant	0	24 <sup>a</sup>	24
Total	3	24	27 <sup>b</sup>
			<b>Excluding ND</b>
Sensitivity			24/24 (100%)
Specificity			3/3 (100%)
PPV			24/24 (100%)
NPV			3/3 (100%)

<sup>a</sup> Two specimens were correct for malignancy but incorrect for final histology.

<sup>b</sup> Of the 28 adequate samples, one patient was excluded because of complete response.

CNB, core needle biopsy; ND, nondiagnostic; PPV, positive predictive value; NPV, negative predictive value.

troversial. Several reports have evaluated the use of neoadjuvant regimens to guide treatment.<sup>10,11</sup> The potential advantages of preoperative therapy include (1) tumor reduction and improved likelihood of complete (R0) resection, (2) immediate systemic therapy for micrometastatic disease, and (3) pathologic evaluation of effectiveness of preoperative therapy after surgical resection. Preoperative diagnosis of sarcoma and grade are prerequisites to these investigational or institutional management approaches that apply neoadjuvant treatment. Also, determination of a benign tumor can guide the extent of surgical resection.

Given that chest wall sarcomas are rare mesenchymal tumors, a multidisciplinary team approach to musculoskeletal sarcomas has been advocated.<sup>5,7,9,12</sup> In our review of the literature, there is a paucity of articles that report the utilization of core needle biopsy as a diagnostic method specifically for chest wall sarcomas. Although there are numerous studies that reported the experience of needle biopsies in chest wall lesions, these studies focused mainly on epithelial malignan-

**TABLE 6.** Accuracy of Final High-Grade Sarcomas from Adequate CNB Samples

CNB	Final Grade		Total
	Low/Intermediate	High	
Low/intermediate	9	3	12
High	0	10	10
Total	9	13	22 <sup>a</sup>
<b>Excluding ND</b>			
Sensitivity			10/13 (77%)
Specificity			9/9 (100%)
PPV			10/10 (100%)
NPV			9/12 (75%)

<sup>a</sup> Of the 24 malignant samples, two patients had biopsy samples diagnostic for histology but nondiagnostic for grade.  
CNB, core needle biopsy; ND, nondiagnostic; PPV, positive predictive value; NPV, negative predictive value.

cies (i.e., carcinomas) with limited inclusion of chest wall sarcomas, and benign entities included not only tumors but also infection (i.e., chest wall abscesses). As such, reports that address the efficacy of core needle biopsies in chest wall musculoskeletal tumors and specifically its effectiveness in chest wall sarcomas are limited. Hau et al.<sup>6</sup> reported that the anatomical site has a significant effect on the accuracy of the biopsy. Nevertheless, in most studies, the experience with needle biopsy in the chest wall location was reported in the data as part of other body sites. To our knowledge, only the study from Walsh et al.<sup>9</sup> reported their 10-year experience in the management and treatment of chest wall sarcomas and briefly described the use of fine needle aspiration or Tru-Cut needle biopsy in 27 patients. Our study is unique in that it specifically addresses the use of core needle biopsy in chest wall sarcomas and focuses on the adequacy of tissue sample obtained by needle biopsy and accuracy in determining malignancy, histological subtype, and high grade differentiation.

The importance of image guidance in needle biopsies was demonstrated by Narvani et al.<sup>13</sup> who reported that biopsies obtained by image guidance are significantly more accurate compared with blind biopsies (95% versus 78%). Additionally, image guidance allows immediate evaluation for procedure-related complications, such as hemorrhage or pneumothorax. The reported incidence of needle biopsy-related complications is 0 to 1.1%.<sup>12,14–16</sup> In our series, all core needle biopsies were performed with ultrasound or CT guidance, and there were no procedure-related complications. Although several reports have advocated needle tracts from biopsies to be included within the field of surgical resection, in our experience, unlike incisional or excisional surgical biopsies, the use of core needle biopsy has eliminated the need to include the biopsy site at the time of tumor resection.<sup>8,12,15,17</sup> This practice has not resulted in chest wall recurrences after core needle biopsies. Presumably, the use of image guidance with an inner and outer core needle method may prevent tracking of tumor along the needle trajectory.

Core needle biopsy has been shown to be an accurate diagnostic modality for musculoskeletal tumors in various

body sites. Our series demonstrated a diagnostic adequacy of core needle biopsy specifically in chest wall musculoskeletal tumors to be 70%, which is comparable with the reported 79 to 100% in other body sites.<sup>13,18,19</sup> Tumor characteristics may impact the adequacy and diagnostic accuracy. In our series, the majority of nondiagnostic samples from benign lesions were from bony tumors (80%), whereas nondiagnostic malignant sarcomas were from soft tissue tumors (100%). Several studies reported decreased diagnostic yield for bony compared with soft tissue tumors, identifying cortex penetration as a possible hindrance to achieving adequate samples.<sup>5,6</sup> Furthermore, cystic or vascular tumors may be more difficult to obtain diagnostic tissue.<sup>7</sup> The use of positron emission tomography/CT may direct image-guided needle biopsy procedures to metabolically active areas with possibly higher diagnostic accuracy.<sup>20</sup> Additionally, several authors described tumor heterogeneity including areas of tumor necrosis, fibrosis, or hemorrhage, as a factor that may contribute to difficult diagnosis of soft tissue tumors.<sup>8,21,22</sup>

Our overall accuracy for determining a malignant sample was 100%, and the sensitivity and specificity of core needle biopsy to diagnose chest wall sarcomas were both 100%. These results are comparable with reports for musculoskeletal tumors in other body locations (sensitivity 82–100% and specificity 94–100%).<sup>12,15,16,18,19,23–25</sup> We reported accuracies for correct histology and grade in chest wall sarcomas to be 92 and 87%, respectively. Specifically, the sensitivity and specificity of using core needle biopsy to determine sarcoma grade in our study were 77 and 100%, respectively. Several authors have also reported decreased accuracy in identifying grade when compared with histological subtypes, citing ranges for sensitivity and specificity of 81 to 89 and 95 to 100%, respectively.<sup>12,24</sup> All our specimens were reviewed by dedicated musculoskeletal pathologists. The importance of specimen evaluation by an experienced sarcoma pathologist is emphasized in other series.<sup>23</sup>

Given these findings, our report demonstrates that image-guided core needle biopsy is a safe and highly accurate diagnostic modality to determine malignancy, histological subtype, and high grade differentiation of chest wall musculoskeletal tumors. Core needle biopsy is an important component in the multidisciplinary approach to the management of chest wall sarcomas, especially when induction therapy is considered and should ideally be used in the context of experienced radiologists and musculoskeletal pathologists to achieve highly accurate diagnostic results.

## REFERENCES

1. Jemal A, Siegel R, Xu J, et al. Cancer statistics, 2010. *CA Cancer J Clin* 2010;60:277–230.
2. Shmookler B, Bickels J, Jelinek J, et al. Bone and soft-tissue sarcomas: epidemiology, radiology, pathology and fundamentals of surgical treatment. In MM Malawer, PH Sugarbaker (Eds.), *Musculoskeletal Cancer Surgery. Treatment of Sarcomas and Allied Diseases*. Norwell, MA: Kluwer Academic Publishers, 2001. Pp. 3–35.
3. Fletcher CDM, Rydholm A, Singer S, et al. Soft tissue tumours: WHO classification, epidemiology, clinical features, histopathological typing and grading. In CDM Fletcher, KK Unni, F Mertens (Eds.), *World Health Organization Classification of Tumors. Pathology and Genetics of Tumours of Soft Tissue and Bone*. Lyon: International Agency for Research on Cancer, 2002. Pp. 12–22.

4. Mankin HJ, Mankin CJ, Simon MA. The hazards of the biopsy, revisited. Members of the Musculoskeletal Tumor Society. *J Bone Joint Surg Am* 1996;78:656–663.
5. Altuntas A, Slavin J, Smith P, et al. Accuracy of computed tomography guided core needle biopsy of musculoskeletal tumors. *ANZ J Surg* 2005;75:187–191.
6. Hau MA, Kim JJ, Kattapuram S, et al. Accuracy of CT-guided biopsies in 359 patients with musculoskeletal lesions. *Skeletal Radiol* 2002;31:349–353.
7. Issakov J, Flusser G, Kollender Y, et al. Computed tomography-guided core needle biopsy for bone and soft tissue tumors. *Isr Med Assoc J* 2003;5:28–30.
8. Logan PM, Connell DG, O'Connell JX, et al. Image-guided percutaneous biopsy of musculoskeletal tumors: an algorithm for selection of specific biopsy techniques. *AJR Am J Roentgenol* 1996;166:137–141.
9. Walsh GL, Davis BM, Swisher SG, et al. A single-institutional, multidisciplinary approach to primary sarcomas involving the chest wall requiring full-thickness resections. *J Thorac Cardiovasc Surg* 2001;121:48–60.
10. Eilber FC, Rosen G, Eckardt J, et al. Treatment-induced pathologic necrosis: a predictor of local recurrence and survival in patients receiving neoadjuvant therapy for high-grade extremity soft tissue sarcomas. *J Clin Oncol* 2001;19:3203–3209.
11. MacDermid DM, Miller LL, Peabody TD, et al. Primary tumor necrosis predicts distant control in locally advanced soft-tissue sarcomas after preoperative concurrent chemoradiotherapy. *Int J Radiat Oncol Biol Phys* 2010;76:1147–1153.
12. Strauss DC, Qureshi YA, Hayes AJ, et al. The role of core needle biopsy in the diagnosis of suspected soft tissue tumours. *J Surg Oncol* 2010;102:523–529.
13. Narvani AA, Tsiridis E, Saifuddin A, et al. Does image guidance improve accuracy of core needle biopsy in diagnosis of soft tissue tumours? *Acta Orthop Belg* 2009;75:239–244.
14. Jelinek JS, Murphey MD, Welker JA, et al. Diagnosis of primary bone tumors with image-guided percutaneous biopsy: experience with 110 tumors. *Radiology* 2002;223:731–737.
15. Mitsuyoshi G, Naito N, Kawai A, et al. Accurate diagnosis of musculoskeletal lesions by core needle biopsy. *J Surg Oncol* 2006;94:21–27.
16. Welker JA, Henshaw RM, Jelinek J, et al. The percutaneous needle biopsy is safe and recommended in the diagnosis of musculoskeletal masses. *Cancer* 2000;89:2677–2686.
17. Yao L, Nelson SD, Seeger LL, et al. Primary musculoskeletal neoplasms: effectiveness of core-needle biopsy. *Radiology* 1999;212:682–686.
18. Ray-Coquard I, Ranchere-Vince D, Thiesse P, et al. Evaluation of core needle biopsy as a substitute to open biopsy in the diagnosis of soft-tissue masses. *Eur J Cancer* 2003;39:2021–2025.
19. Soudack M, Nachtigal A, Vladovski E, et al. Sonographically guided percutaneous needle biopsy of soft tissue masses with histopathological correlation. *J Ultrasound Med* 2006;25:1271–1277.
20. Benz MR, Tchekmedyian N, Eilber FC, et al. Utilization of position emission tomography in the management of patients with sarcoma. *Curr Opin Oncol* 2009;21:345–351.
21. Skrzynski MC, Biermann JS, Montag A, et al. Diagnostic accuracy and charge-savings of outpatient core needle biopsy compared with open biopsy of musculoskeletal tumors. *J Bone Joint Surg Am* 1996;78:644–649.
22. Sung KS, Seo SW, Shon MS. The diagnostic value of needle biopsy for musculoskeletal lesions. *Int Orthop* 2009;33:1701–1706.
23. Hoerber I, Spillane AJ, Fisher C, et al. Accuracy of biopsy techniques for limb and limb girdle soft tissue tumors. *Ann Surg Oncol* 2001;8:80–87.
24. Heslin MJ, Lewis JJ, Woodruff JM, et al. Core needle biopsy for diagnosis of extremity soft tissue sarcoma. *Ann Surg Oncol* 1997;4:425–431.
25. Yeow KM, Tan CF, Chen JS, et al. Diagnostic sensitivity of ultrasound-guided needle biopsy in soft tissue masses about superficial bone lesions. *J Ultrasound Med* 2000;19:849–855.