

UCSF

UC San Francisco Previously Published Works

Title

Concomitant epicardial left atrial appendage ligation and left atrial ablation of atrial fibrillation: Safety, feasibility and outcome

Permalink

<https://escholarship.org/uc/item/9cn4k3tq>

Journal

Indian Pacing and Electrophysiology Journal, 21(2)

ISSN

2590-1753

Authors

Nentwich, Karin
Ene, Elena
Halbfass, Philipp
et al.

Publication Date

2021-03-01

DOI

10.1016/j.ipej.2021.01.001

Peer reviewed



Contents lists available at ScienceDirect

Indian Pacing and Electrophysiology Journal

journal homepage: www.elsevier.com/locate/IPEJ

Concomitant epicardial left atrial appendage ligation and left atrial ablation of atrial fibrillation: Safety, feasibility and outcome



Karin Nentwich^{a,*}, Elena Ene^a, Philipp Halbfass^a, Arthur Berkowitz^a, Kai Sonne^a, Sebastian Kerber^a, Randall Lee^b, Thomas Deneke^a

^a Campus Bad Neustadt, Department Cardiology and Invasive Electrophysiology, von Guttenbergstrasse 11, 97616, Bad Neustadt, Germany

^b Section of Cardiac Electrophysiology, Division of Cardiology, University of California, 500 Parnassus Ave, San Francisco, CA, 94143, USA

ARTICLE INFO

Article history:

Received 3 September 2020

Received in revised form

7 January 2021

Accepted 9 January 2021

Available online 15 January 2021

Keywords:

Atrial fibrillation

Left atrial appendage

Ligation

Lariat

ABSTRACT

Introduction: We present initial results of patients undergoing a combined procedure of epicardial LAA ligation in addition to left atrial ablation for AF.

Methods: 9 patients were included for additional use of LARIAT as an individual treatment approach for AF. First an epicardial LAA ligation was performed, in the same procedure left atrial ablations consisting of PVI and additional substrate based modifying ablations were performed. Follow-up at 3 months and 12 months was performed.

Results: There was only 1 minor procedural complication (11%) involving epicardial bleeding and 2 late adverse events of pericardial tamponade and stroke. At the final follow-up (median 20 months) 7 patients were in stable sinus rhythm (78%) and 2 pts had reduced AF burden.

Conclusion: Concomitant epicardial LAA ligation and ablation is feasible in selected patients with a reasonable risk profile. More prospective data are required to validate the safety and efficacy.

Copyright © 2021, Indian Heart Rhythm Society. Production and hosting by Elsevier B.V. This is an open access article under the CC BY-NC-ND license (<http://creativecommons.org/licenses/by-nc-nd/4.0/>).

1. Introduction

Atrial fibrillation (AF) is one of the most common arrhythmia and may require oral anticoagulation and many different forms of medical or interventional therapies. Pulmonary vein isolation (PVI) is a cornerstone of catheter ablation treatment of paroxysmal and persistent atrial fibrillation. Long term success has not been relevantly increased even with the latest developments of ablations techniques and mapping systems. In persistent and long-persistent AF, foci and substrate beyond the pulmonary veins may be involved as triggers and maintaining AF. Adding electrical isolation of the left atrial appendage (LAA) appears to improve arrhythmia freedom [1].

LAA occlusion has been used to decrease thrombus formation in at risk patients not eligible for oral anticoagulation. Electrical isolation of the LAA has been involved with mechanical dysfunction of the LAA and consequently higher thrombogenicity and stroke [2]. LAA occlusion has been shown not to be inferior to warfarin in the

endpoint of stroke prevention with additional reductions in major bleeding, particularly hemorrhagic stroke [3]. LAA ligation has the attractive advantage of electrical and mechanical elimination of the appendage in one procedure. Conversion to sinus rhythm has been documented in some persistent AF patients undergoing LAA ligation using the LARIAT device [4]. Effective elimination of atrial tachycardias deriving from the LAA has been published [5] as well as we have experienced (not published data).

As a consequence, combining left atrial AF ablation procedures with an additional LAA ligation may increase efficacy of rhythm stabilization and decrease risk of stroke during follow-up. In the present group of patients, an individual treatment approach of a concomitant AF ablation and LAA ligation was performed in a single procedure. Acute and chronic safety and efficacy were evaluated.

2. Methods

9 patients with highly symptomatic persistent AF were prospectively included. All patients signed for informed consent on the concomitant approach and the “off-label” use of epicardial ligation as an antiarrhythmic indication in 5 patients. A computed tomography (CT) scan was performed for topographic and anatomical depiction of the LAA and to rule out LAA thrombus. Anticoagulation

* Corresponding author. Campus Bad Neustadt, Department Cardiology/invasive Electrophysiology, Von Guttenbergstrasse 11 97616 Bad Neustadt Germany.

E-mail address: Karin.nentwich@campus-nes.de (K. Nentwich).

Peer review under responsibility of Indian Heart Rhythm Society.

Abbreviations	
PVI	Pulmonary vein isolation
AF	Atrial Fibrillation
LAA	Left atrial appendage
TEE	transesophageal echocardiography
Pt.	Patient
CT	Computer tomography
ACT	Activated clotting time
RF	Radiofrequency
SR	Sinus Rhythm
NOAC	novel oral anticoagulants
ECG	Electrocardiogram

was stopped before the procedure. Colchicine was started the day before the procedure with the dose of 1 mg/d, as it reduces the cumulative incidence of delayed complications [6].

The procedure was performed under consciousness sedation with Propofol in fastening patients. The procedural basic characteristics are shown in Table 1. After successful epicardial and transeptal puncture heparin was given to target an ACT of 250–300 s. As a first step epicardial ligation using the LARIAT System was performed as published before [7] (See Fig. 1). After ligation an 8 F pigtail catheter was placed in the pericardial space and continuous suction was applied.

Along the transeptal sheath a second steerable sheath was introduced into the left atrium. A left atrial substrate map during sinus rhythm (SR) generating the anatomy the left atrial anatomy was performed with the CARTO mapping system (Biosense Webster, Diamond Bar, CA, USA). Heparin was administered to increase ACT to 300–350 s before ablation.

In patients with no prior left atrial ablation wide circumferential PVI as a straight forward procedure was performed using point by point radiofrequency ablation (RF) as previously published [8]. In patients undergoing redo-ablation reconnections of the PVs were mapped and ablated segmentally. In all cases left atrial substrate ablation was performed, if left atrial low-voltage areas (<0.5 mV bipolar voltage during high-density mapping) were documented using linear ablations (see Table 2 and Fig. 2) like roofline, posterior lines or anterior isthmusline between the mitral annulus and the left or right superior vein.

Whereas in the first 2 cases protamine was administered only after prolonged epicardial bleeding (Table 2) all following patients received protamine to antagonizing the heparin after withdrawal of the transeptal sheaths. After achieving hemostasis low dose heparin was re-started with 500 IE/h on the day of the procedure. After the procedure the patients were monitored on the ICU. The epicardial drain was removed the next morning and oral anticoagulation with NOACs was initiated for 3 months. Colchicine was prescribed for 6 weeks.

Table 1
Patients characteristics.

Gender male	N = 5 (56%)
Age	67 ± 10 years (46–78 years)
Ejection fraction	61%
Long-persistent AF	9 (100%)
AF duration	2.7 ± 1.1years (range 1 to 7y)
CHA ₂ DS ₂ -VASc Score	4 ± 1.1
HASBLED Score	2,1 ± 0.78
classical indication for LAA occlusion	N = 4 (44%)
history of stroke	N = 4 (44%)
coronary artery disease	N = 1 (11%)

Follow up was performed after 3 and 12 months including 48-h holter ECG and transesophageal echocardiography to document effective LAA occlusion. Emptying function of the left atrium was not assessed as we focused on feasibility, safety and efficacy.

3. Results

All 9 patients underwent successful combined LAA ligation and catheter ablation. 4 patients had their first PVI, 5 patients had redo-PVI procedures (1 patient had a left atrial ablation procedure before, 2 patients had 2 and 3 procedures before). 8 patients had hypertensive heart disease with normal ejection fraction. 1 patient had ischemic heart disease with an ejection fraction of 40% under cardiac resynchronization therapy (see Table 2 for patient baseline characteristics).

Effective epicardial ligation without any documented flow into the LAA on intraprocedural TEE was achieved in all patients (100%). Mean total procedure duration was 185 ± 37.8 min, mean time for LAA ligation was 102 min and mean fluoroscopy time was 38 ± 17.8 min. In all patients, postprocedural epicardial drainage was observed without pericardial effusion during the early post-LAA-ligation monitoring which stopped after administering protamine to reverse the higher peri-procedural ACT at the end of the ablation procedure.

At 3 months anticoagulation was stopped in all patients but aspirin was initiated in 1 pt. (11%) because of coronary heart disease.

3.1. Acute complications

1 patient (11%) (2nd patient of the cohort not having early protamine administration) had prolonged epicardial bleeding without pericardial effusion which led to a decrease in hemoglobin but without the need for blood transfusion.

3.2. Follow-up at 3 months

After 3 months TEE showed complete occlusion of the LAA in all patients without any central leakage or thrombus.

3.3. Complications at 3 months follow-up

2 major complications (22%) occurred during the initial 3 months after the procedure: 1 stroke (11%) without any sign of thrombus and complete effective LAA ligation in the TEE at 14 weeks (anticoagulation with aspirin alone) was considered non-procedure related.

1 late pericardial tamponade (11%) after termination of colchicum at 6 weeks considered to be procedure-related. Pericardial drainage plus steroid i.v. led to complete resolution. The mechanism of this late tamponade was presumably ongoing pericardial inflammation after withdrawal of colchicine 6 weeks after the procedure with secondary bleeding under oral anticoagulation.

Minor complications: 1 Dressler syndrome (11%) after 3 weeks effectively treated with steroids.

3.4. Follow-Up a 12 months

After 12 months, TEE showed complete occlusion of the LAA in all patients without any central leakage or thrombus. No relevant late complications occurred during 3–12 months follow-up.

3.5. Rhythm outcome

At 12 months 7 (78%) patients were in stable SR. During the 3

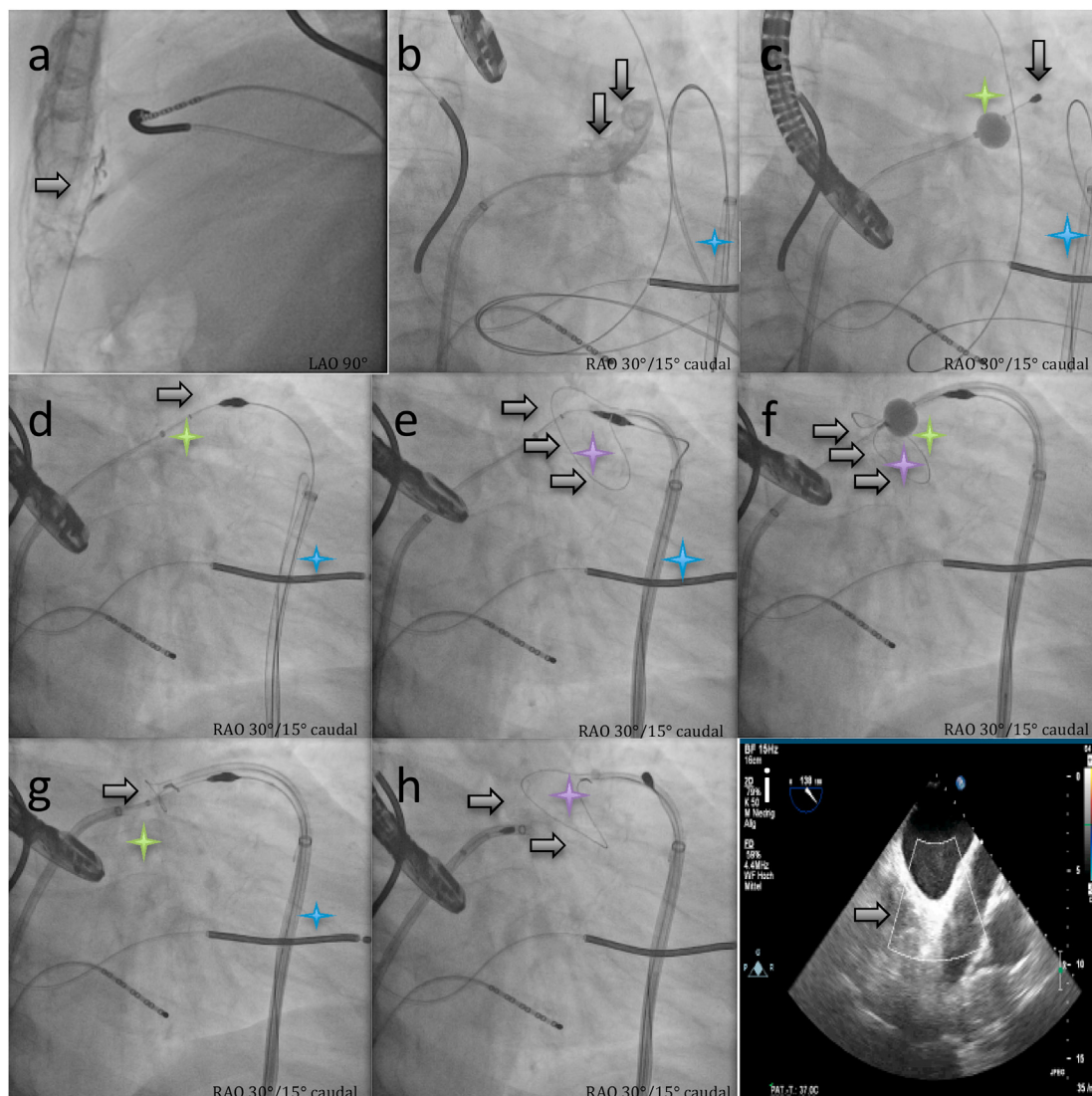


Fig. 1. Stepwise approach to epicardial ligation of the LAA in a patient undergoing concomitant procedure.

Table 2

Procedures characteristics.

Procedure time	185 ± 37.8 min (260 min–146 min)
fluoroscopy time	38 ± 17.8 min (83 min–23 min)
Median number of prior left atrial ablation procedures	2 (0–3)
Complete circumferential PVI	N = 4 (44%)
Segmental PVI for reconnections	N = 5 (56%)
Segmental Ablation and lines	N = 5 (56%)
	Anterior isthmus line n = 4
	Posterior line n = 1
	Roofline n = 4
	Boxlesion n = 1
	Isolation SVC n = 4
Acute complication	1 prolonged pericardial bleeding (11%) without need for blood transfusion
Follow-up complication	1 stroke
	1 hemorrhagic tamponade
	1 Dressler syndrome

months blanking period 1 patient had recurrence of a stable atrial tachycardia, which was effectively ablated after 2 months (stable SR later on) with a roof line. 1 patient was cardioverted after 3 months (stable SR later on), 1 patient was cardioverted twice and remained in stable SR under amiodarone medication. The 2 patients with recurrent AF had a significant decline of device-monitored AF

burden with brief episodes of atrial tachycardias between 10 min and 2 h. No changes of the p-wave morphology could be observed (Table 3).

At 12 months all patients had relevant clinical improvement of AF-related symptoms.

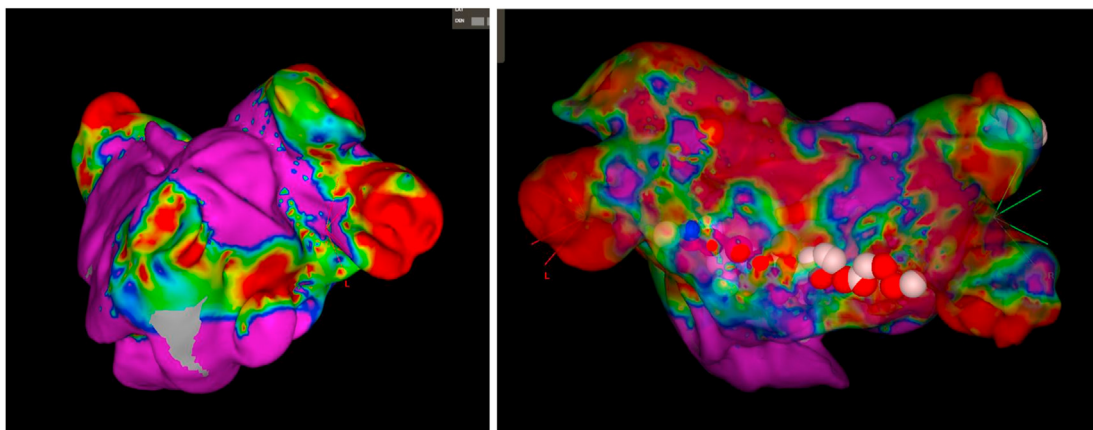


Fig. 2. LAO view: occluded LAA, PA view: posterior line through inhomogenous substrat with termination of the atypical flutter.

4. Discussion

This is the first series of using concomitant epicardial LAA ligation with the LARIAT device and additional left atrial AF ablation in a single procedure. Previous reports of LAA ligation and catheter ablation were performed as a staged procedure with LAA ligation first, followed by catheter ablation 1–3 months later [9,10].

In this small patient cohort, the concomitant procedure was effective (78% at 12-months in SR) and safe (minor acute complications in 1 and major procedure-related follow-up complications in 1 patient) when performed in an experienced center. Each procedure by itself is complex and requires skills acquired with learning curve and training in specialized centers. The complication rate of PVI ranges within 4–5% [11,12], the recent complication rate of epicardial ligation with the LARIAT device is published to be 1.2–2.2% [6,13], but early experiences had complication rates as high as 10–11.5% [14–16], providing a warning of the FDA using the LARIAT device. However the device received a FDA approval for the AMAZE trial [17] and the CE mark in Europe.

In our cohort of patients, combining both procedures into a single procedure did not lead to higher acute complication rates when performed in experienced centers.

Protamine was routinely given after withdrawal of the trans-septal sheaths and no further drainage from the pericardial drain or any thromboembolic complications were documented. The higher incidence of pericardial bleeding may be related to the higher ACT level targeted for left atrial ablation and/or an inflammatory response to catheter ablation. The incidence of non-clinically significant effusions with saline irrigated catheters have been reported between 2% and 16% [18,19] and thought to be due to inflammation. Future studies need to identify if lower ACT targets for AF ablation (around 250 s) are comparably safe and if this would decrease the pericardial bleeding incidences after concomitant

procedures without having to reverse heparinization.

During follow-up two patients developed relevant pericardial effusion: after 49 days one a hemorrhagic pericardial effusion on oral anticoagulants and needing a pericardial drainage plus steroids, the other after 10 days being treated with steroids for presumed Dressler syndrome without needing an intervention. Miller et al. [15] published early and late pericarditis of 28%. From our prior observation patients who underwent LAA ligation alone (unpublished data), pericarditis was observed in 3.6% of patients. In our small cohort of concomitant procedures 2 major complications occurred (1 stroke and 1 late tamponade). It remains unclear if these complications were truly related to the concomitant nature of the procedure. The case of the ischemic stroke at 14 weeks was not related to the procedure itself but it occurred after changing anticoagulation to aspirin. The case of secondary epicardial bleeding leading to tamponade was related to the anticoagulation that was instituted for 3 months after left atrial ablation and therefore was suspected to be procedure related.

The antiarrhythmic effect of additional elimination of the left appendage is still an issue of discussion. A recently published meta-analysis of 14 trials with additional electrical isolation of the LAA in persistent and long-persistent AF found significant relative reduction of AF recurrence of 56% and absolute reduction of 31% in patients treated with LAA isolation [20]. The way of isolating the LAA was not respected (with RF technique, with cryo technique or with LARIAT). Similar observation was documented in our small cohort: 78% of this complex cohort of patients (persistent AF as first intervention or multiple prior ablation procedures) was in stable sinus rhythm at 12 months follow-up. 2 patients with implanted devices had significant reduction of AF burden. All patients had clinical improvement of AF-related symptoms. Long-term follow-up over 12 months is needed for future evaluations.

Table 3
Summary of the type of ablation, Afib recurrence and complication.

Patient	Type of ablation	Afib recurrence	Complication
Patient 1	Box lesion, anterior isthmus line	>12 months	none
Patient 2	PVI, roof line, anterior isthmusline, spontaneous conversion to SR after ligation	>12 months	Minor stroke
Patient 3	PVI, roof line	>12 months	Atrial flutter
Patient 4	Roof line, SVC isolation	>12 months	none
Patient 5	PVI only	>12 months	Pericardial bleeding
Patient 6	Segmental reisolation right PV, roof line, anterior isthmusline	6 months, Cardioversion	none
Patient 7	Reisolation SVC, roof line, anterior isthmusline	>12 months	none
Patient 8	PVI only	>12 months	Late tamponade
Patient 9	Posterior line, reisolation RIPV und SVC	1 month, Amiodaron	Dressler Syndrome

5. Conclusion

In a small cohort of patients concomitant epicardial LAA ligation and AF ablation is feasible and safe in a center well trained for epicardial puncture and use of the LARIAT device. Postinterventional pericardial bleeding can be managed with post-procedural protamine antagonization without increasing the risk of an acute embolic event. An additive antiarrhythmic effect of the combined procedure can be suspected but larger patient groups are needed to verify this hypothesis.

References

- [1] Romero J, Michaud GF, Avendano R, Briceno DF, Kumar S, Diaz JC, Mohanty S, Trivedi C, Gianni C, Della Rocca D, Proietti R, Perrotta L, Bordignon S, Chun JKR, Schmidt B, Garcia M, Natale A, Di Biase L. Benefit of left atrial appendage electrical isolation for persistent and long-standing persistent atrial fibrillation: a systematic review and meta-analysis. *Europace* 2018;20:1268–78.
- [2] Rillig A, Tilz RR, Lin T, et al. Unexpectedly high incidence of stroke and left atrial appendage Thrombus formation after electrical Isolation of the left atrial Appendage for the Treatment of Atrial Tachyarrhythmias. *Circ Arrhythm Electrophysiol* 2016;9(5):e003461.
- [3] Reddy VY, Doshi SK, Kar S, Gibson DN, Price MJ, Huber K, Horton RP, Buchbinder M, Neuzil P, Homes Jr DR. PREVAIL and PROTECT AF investigators.; 5-years outcomes after left atrial appendage closure: from the PREVAIL and PROTECT AF trails. *J Am Coll Cardiol* 2017;70(24):2964–75.
- [4] Badhwar N, Mittal S, Rasekh A, Vasaiwala S, Musat D, Naeini P, Fang Q, Nentwich K, Deneke T, Chang J, Lakkireddy D, Wilber D, Lee RJ. Conversion of persistent atrial fibrillation to sinus rhythm after LAA ligation with the LARIAT device. *Int J Cardiol* 2016;15:120–2.
- [5] Atoui M, Pillarisetti J, Iskandar S, Earnest M, Lakkireddy D. Left atrial appendage tachycardia termination with a lariat suture ligation. *J Atr Fibrillation* 2015;8(4):1380.
- [6] Lakkireddy D, Afzal MR, Lee RJ, Nagaraj H, Tschopp D, Gidney B, Ellis C, Altman E, Lee R, Kar S, Bhadwar N, Sanchez M, Gadiyaram V, Evonich R, Rasekh A, Cheng J, Cuoco F, Chandhok S, Gunda S, Reddy M, Atkins D, Bommana S, Cuculich P, Gibson D, Nath J, Ferrell R, Matthew E, Wilber D. Short and long-term outcomes of percutaneous left atrial appendage suture ligation: results from a US multicenter evaluation. *Heart Rhythm* 2016 May;13(5):1030–6.
- [7] Bartus K, Han FT, Bednarek J, Myc J, Kapelak B, Sadowski J, Lelakowski J, Bartus S, Yakubov SJ, Lee RJ. Percutaneous left atrial appendage suture ligation using the LARIAT device in patients with atrial fibrillation: initial clinical experience. *J Am Coll Cardiol* 2013;9(2):108–18.
- [8] Deneke T, Nentwich K, Berkovitz A, Sonne K, Ene E, Pavlov B, Fochler F, Bötsch AK, Kuhn R, Halbfass. High-resolution infrared thermal imaging of the esophagus during atrial fibrillation ablation as a predictor of endoscopically detected thermal lesions. *Circ Arrhythm Electrophysiol* 2018;11(11):e006681.
- [9] Badhwar N, Lakkireddy D, Kawamura M, Han FT, Lyer SK, Moyers BS, Dewland TA, Woods C, Ferrell R, Nath J, Earnest M, Lee RJ. Sequential percutaneous LAA ligation and pulmonary vein isolation in patients with persistent AF: initials results of a feasibility study. *J Cardiovasc Electrophysiol* 2015;26:608–14.
- [10] Laddireddy D, Sridhar Mahankali A, Kanmanthareddy A, Lee R, Badhwar N, Bartus K, Atkins D, Bomana S, Cheng J, Rasekh A, Dibiase L, Natale A, Nath J, Ferrell R, Earnest M, Reddy YM. Left atrial appendage ligation and ablation for persistent atrial fibrillation: the LAALA-AF registry. *JACC Clin Electrophysiol* 2015;1(3):153–60.
- [11] Chen J, Dagnes N, Hocini M, Fauchier L, Bongiorni MG, Defaxe P, Hernandez-Madrid A, Estner H, Sciaraffia E, Blomström-Lundquist C. Scientific initiatives committee of the European heart rhythm association EHRA. Catheter ablation for atrial fibrillation: results from the first European snapshot survey on procedural routines for atrial fibrillation ablation (ESS-PRAFA) Part II. *Europace* 2015 Nov;17(11):1727–32.
- [12] Cappato R, Calkins H, Chen SA, Davies W, Isaka Y, Kalman J, Kim YH, Klein G, Natale A, Packer D, Skanes A, Abroggi F, Biganzoli E. Updates worldwide survey on the methods, efficacy and safety of catheter ablation for human atrial fibrillation. *Circ Arrhythm Electrophysiol* 2010;3(1):32–8. Feb.
- [13] Jazayeri MA, Vuddanda V, Turagam MK, Parikh V, Lavu M, Atkins D, Earnest M, Di Biase L, Natale A, Wilber D, Reddy YM, Lakkireddy DR. Safety profiles of percutaneous left atrial appendage closure devices: an analysis of the Food and Drug Administration Manufacturer and User Facility Device Experience (MAUDE) database from 2009 to 2016. *J Cardiovasc Electrophysiol* 2018 Jan;29(1):5–13.
- [14] Price Matthew J, Gibson Douglas N, Yakubov Steven J, Schultz Jason C, Di Biase Luigi, Andrea Natale, David Burkhardt J, Ashish Pershad, Byrne Timothy J, Gidney Brett, Aragon Joseph R, Goldstein Jeffrey, Kriegh Moulton, Patel Taral, Bradley Knight, Lin Albert C, Miguel Valderrábano. Early safety and efficacy of percutaneous left atrial appendage suture ligation: results from the U.S. transcatheter LAA ligation consortium. *J Am Coll Cardiol* 2014 Aug 12;64(6):565–72.
- [15] Miller Marc A, Gangireddy Sandeep R, Doshi Shephal K, Arash Aryana, Koruth Jacob S, Susie Sennhauser, d'Avila Andre, Dukkipati Srinivas R, Petr Neuzil, Reddy Vivek Y. Multicenter study on acute and long-term safety and efficacy of percutaneous left atrial appendage closure using an epicardial suture snaring device. *Heart Rhythm* 2014 Nov;11(11):1853–9.
- [16] Horst Sievert, Abdi Rasekh, Kryzstof Bartus, Morelli Remo L, Fang Qizhi, Jonas Kuroпка, Le Duong, Sameer Gafoor, Luisa Heuer, Payam Safavi-Naeini, Hue Trisha F, Marcus Gregory M, Nitish Badhwar, Ali Massumi, Lee Randall J. Left atrial appendage ligation in nonvalvular atrial fibrillation patients at high risk for embolic events with ineligibility for oral anticoagulation: initial report of clinical outcomes. *JACC Clin Electrophysiol* 2015 Dec;1(6):465–74.
- [17] aMAZE trial; [ClinicalTrials.gov Identifier: NCT02513797](https://clinicaltrials.gov/ct2/show/study/NCT02513797).
- [18] Cardoso R, Mendirichaga R, Fernandes G, Healy C, Lambrakos LK, Viles-Gonzalez JF, Goldberger JJ, Mitrani RD. Cryoballoon versus radiofrequency catheter ablation in atrial fibrillation: a meta-analysis. *J Cardiovasc Electrophysiol* 2016 Oct;27(10):1151–9.
- [19] Gb1 Chierchia, Capulzini L, Droogmans S, Sorgente A, Sarkozy A, Müller-Burri A, Paparella G, de Asmundis C, Yazaki Y, Kerkhove D, Van Camp G, Brugada P. Pericardial effusion in atrial fibrillation ablation: a comparison between cryoballoon and radiofrequency pulmonary vein isolation. *Europace* 2010 Mar;12(3):337–41.
- [20] Romero J, Michaud G, Avendano R, Briceno D, Kumar S, Diaz JC, Mohanty S, Trivedi C, Gianni C, Della Rocca D, Proietti R, Perrotta L, Bordignon S, Chun J, Schmidt B, Garcia M, Natale A, Di Biase L. Benefit of left atrial appendage electrical isolation for persistent and long-standing persistent atrial fibrillation: a systematic review and meta-analysis. *Europace* 2018;20:1268–78.