

UC Irvine

Journal of Education and Teaching in Emergency Medicine

Title

Bedside Ultrasound for the Rapid Diagnosis of Fournier's Gangrene

Permalink

<https://escholarship.org/uc/item/9bs8n1wr>

Journal

Journal of Education and Teaching in Emergency Medicine, 4(2)

Authors

Penalosa, Patrick
Alvarado, Maili
Han, Vy

Publication Date

2019

DOI

10.5070/M542043463

Copyright Information

Copyright 2019 by the author(s). This work is made available under the terms of a Creative Commons Attribution License, available at <https://creativecommons.org/licenses/by/4.0/>

Peer reviewed

Bedside Ultrasound for the Rapid Diagnosis of Fournier's Gangrene

Patrick Penalosa, BS*, Maili Alexandria Drachman, MD[^] and Vy Han, MD*

*University of California, Irvine, School of Medicine, Irvine, CA

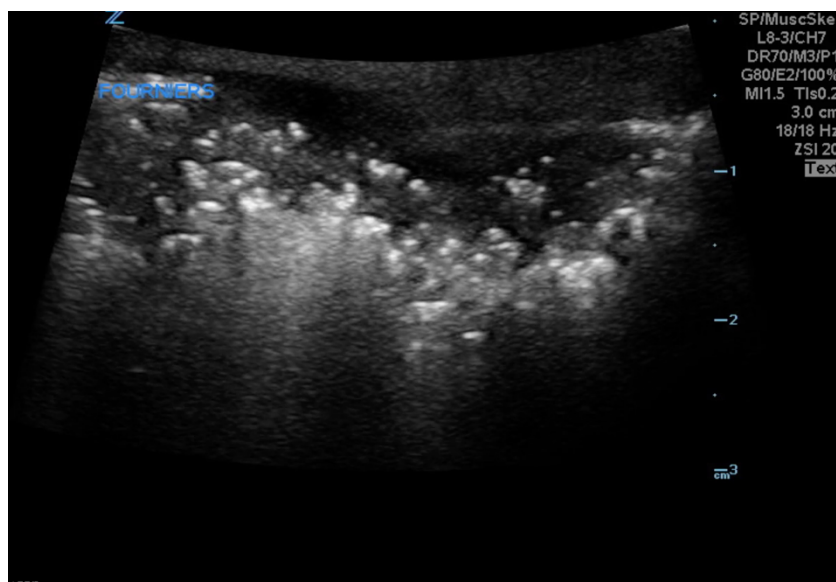
[^]University of Arizona, College of Medicine Tucson, Department of Emergency Medicine, Tucson, AZ

Correspondence should be addressed to Maili Drachman, MD at maili.alvarado@gmail.com

Submitted: June 8, 2018; Accepted: September 5, 2018; Electronically Published: April 15, 2019; <https://doi.org/10.21980/J8CP99>

Copyright: © 2019 Penalosa, et al. This is an open access article distributed in accordance with the terms of the Creative Commons Attribution (CC BY 4.0) License.

See: <http://creativecommons.org/licenses/by/4.0/>



Video Link: <https://youtu.be/8ImLIEiP-ck>

History of present illness: A 39-year-old male with a history of type 2 diabetes presented to the emergency department with subjective fevers and severe pain in his scrotum. On initial evaluation, the patient was tachycardic with significant swelling and tenderness to his scrotum with associated erythema surrounding a black necrotic plaque and palpable crepitus.

Significant findings: Point of care ultrasound (POCUS) utilizing a high-frequency linear probe revealed heterogeneous debris with subcutaneous air within the scrotal wall extending into the perineum consistent with necrotizing fasciitis of the perineum or Fournier's gangrene (FG). The video shows multiple foci of gas that appear as echogenic dots with "dirty shadows" posteriorly from reverberation artifact arising from gas within the soft tissue.

Discussion: Fournier's gangrene is a serious manifestation of necrotizing fasciitis of the perineal, genital, or perianal region.¹ Initially, Fournier's presents with genital discomfort associated with fevers, erythema, scrotal swelling, and crepitus.² These signs and symptoms together suggest the presence of soft tissue subcutaneous gas. In FG, the initial bacterial infection results in microthrombosis of subcutaneous vessels which leads to the rapid progression of gangrenous features of the overlying skin.³ Although clinical backgrounds may vary, diabetes mellitus, advanced age, end-stage liver disease, chronic alcoholism, and obesity are some risk factors that may place individuals at higher risk for development of FG.⁴

Diagnosis of Fournier's can be difficult due to the limitations of the physical exam and the wide variability of presentation of the disease. Currently, the gold standard for detecting necrotizing soft tissue infections is tissue biopsy.⁵ However, due to the rapidly progressive nature of FG, POCUS is a favorable initial test in making the diagnosis. POCUS has a sensitivity of 88.2%, a specificity of 93.3%, a positive predictive value of 83.3% and a negative predictive value of 95.4% in diagnosis necrotizing fasciitis.⁶ Key findings of FG on POCUS include a thickened scrotal wall with echogenic foci of gas with "dirty shadows." The testes and epididymis are spared due to their separate blood supply.⁷ POCUS can provide an accurate and more time efficient means of making the diagnosis compared to waiting for computed tomography when confronted with a potential case of FG.

In this case, the patient was hyperglycemic and had a leukocytosis with neutrophilic predominance. Bedside ultrasound was performed which showed evidence of Fournier's gangrene, and urology and general surgery were emergently consulted. Resuscitation with intravenous (IV) crystalloids and broad spectrum antibiotics was initiated, and the patient taken to the operating room for debridement and packing of his perineum.

Topics: Fournier's gangrene, necrotizing fasciitis, perineum, ultrasound, point of care ultrasound.

References:

1. Smith GL, Bunker CB, Dinneen MD. Fournier's Gangrene. *Br J Urol*. 1998;81:347-355.
2. Laor E, Palmer LS, Tolia BM, Reid RE, Winter HI. Outcome prediction in patients with Fournier's gangrene. *J Urol*. 1995;154(1):89-92.
3. Thwaini A, Khan A, Malik A, et al. Fournier's gangrene and its emergency management. *Postgrad Med J*. 2006;82(970):516-519. doi: 10.1136/pgmj.2005.042069
4. Oguz A, Gumus M, Turkoglu A. Fournier's Gangrene: a summary of 10 years of clinical experience. *Int Surg*. 2015;100(5):934-941. doi: 10.9738/INTSURG-D-15-00036.1.
5. Headley AJ. Necrotizing soft tissue infections: a primary care review. *Am Fam Physician*. 2003;68(2):323-328.
6. Kehrl T. Point-of-care ultrasound diagnosis of necrotizing fasciitis missed by computed tomography and magnetic resonance imaging. *J Emerg Med*. 2014;47(2):172-175. doi: 10.1016/j.jemermed.2013.11.087
7. Di Serafino M, Gullotto C, Gregorini C, Nocentini C. A clinical case of Fournier's gangrene: imaging ultrasound. *J Ultrasound*. 2014;17(4):303-306. doi: 10.1007/s40477-014-0106-5