

UC Davis

Dermatology Online Journal

Title

Nevoid hyperkeratosis of the nipple and the areola

Permalink

<https://escholarship.org/uc/item/9bp2r6pt>

Journal

Dermatology Online Journal, 22(2)

Authors

Alonso-Corral, Maria Jose
Garrido-Colmenero, Cristina
Martinez-Ortiz, Fernando
et al.

Publication Date

2016

DOI

10.5070/D3222030097

Copyright Information

Copyright 2016 by the author(s). This work is made available under the terms of a Creative Commons Attribution-NonCommercial-NoDerivatives License, available at <https://creativecommons.org/licenses/by-nc-nd/4.0/>

Peer reviewed

Photo vignette

Nevoid hyperkeratosis of the nipple and the areola

Maria Jose Alonso-Corral¹, Cristina Garrido-Colmenero², Fernando Martinez-Ortiz³, Ricardo Ruiz-Villaverde²

Dermatology Online Journal 22 (2): 12

¹**Dermatology Unit. Complejo Hospitalario Torrecardenas, Almeria, Spain**

²**Dermatology Unit. Hospital Universitario Virgen de las Nieves, Granada, Spain**

³**Pathology Unit. Complejo Hospitalario Torrecardenas, Almeria, Spain**

Correspondence:

Cristina Garrido Colmenero
Virgen de las Nieves Hospital
Avenida de las Fuerzas Armadas N°2. Postal Code 18014
Granada, Spain
Phone: 00 34 669 118 652

Abstract

A 25-year-old woman presented to our dermatology unit with progressive diffuse thickening of the both areolas. A skin biopsy was taken from the right areola showing irregular filiform acanthosis with elongation and anastomosis of rete ridges, irregular orthokeratotic hyperkeratosis, pseudocyst formation, and hyperpigmentation of the basal layer. The cause of nevoid hyperkeratosis of the nipple and areola is unknown. Eighty percent of cases occur in women and are often manifested during puberty or pregnancy. The disease may also occur in men receiving hormonal therapy. There is no uniformly effective treatment. Dermatologists, gynecologists, and general practitioners have an important part to play in recognizing this condition that may be underdiagnosed because of lack of awareness.

Keywords: Nevoid hyperkeratosis, nipple, areola.

Introduction

Nevoid hyperkeratosis of nipple and areola (NHNA) is an uncommon condition, in which the skin of the nipple and/or areola becomes diffusely thickened, hyperpigmented, and covered with filiform or papular warty excrescences.

Case synopsis

A 25-year-old woman presented to our dermatology unit with progressive diffuse thickening of both areolas. This appearance started 5 years prior to presentation, without any other symptoms apart from the local changes. Past personal and family medical history was not remarkable. There was no sign or history for any endocrine disease and no clinical evidence of dermatosis or lymphoma. She was not taking any regular medication. On examination there was bilateral diffuse brownish pigmentation and verrucous thickening of both areolae extending significantly onto breast skin, with a violaceous-erythematous mottled pattern (Figure 1A and 1B). No tenderness, discharge, or nipple retraction was observed. Blood cell count, general biochemistry, and viral serologies (HBV, HCV, HIV) showed no abnormalities. Imaging studies revealed no hepato-splenomegaly, enlarged lymph nodes, or abdominal or mediastinal masses. A skin biopsy was taken from the right areola showing irregular filiform acanthosis with elongation and anastomosis of rete ridges, irregular orthokeratotic hyperkeratosis (Figure 2A, HEx10), pseudocyst formation, and hyperpigmentation of the basal layer (Figure 2B, HEx40). The

papillary dermis showed mild fibrosis and lymphocytic infiltrate; all of these findings are typical of nevoid hyperkeratosis of the nipple and the areola (NHNA).

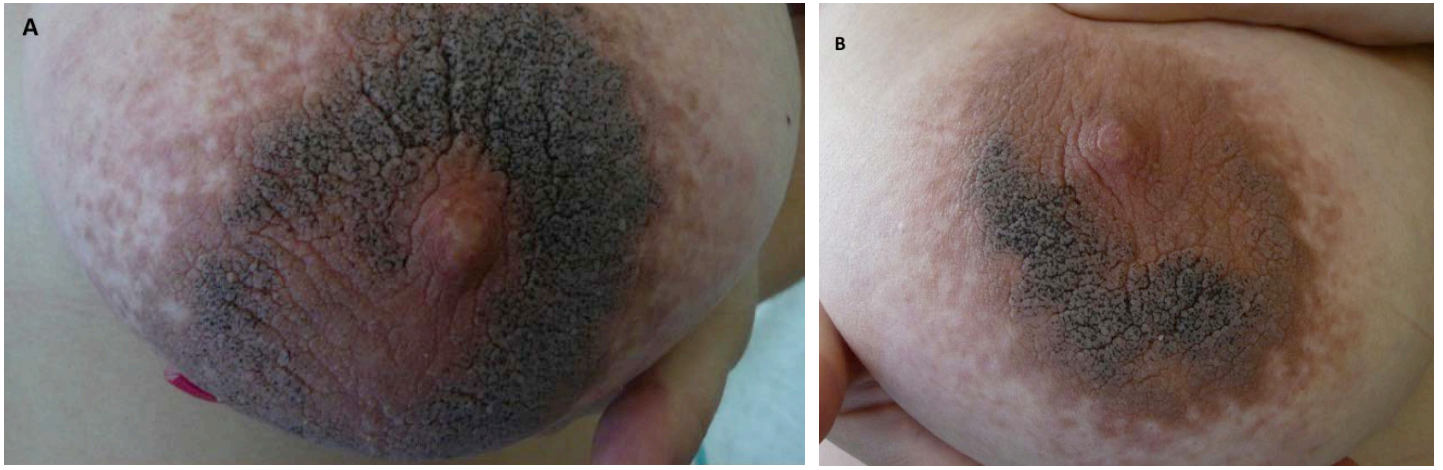


Figure 1 (A and B). Bilateral diffuse brownish pigmentation and verrucous thickening of both areolae

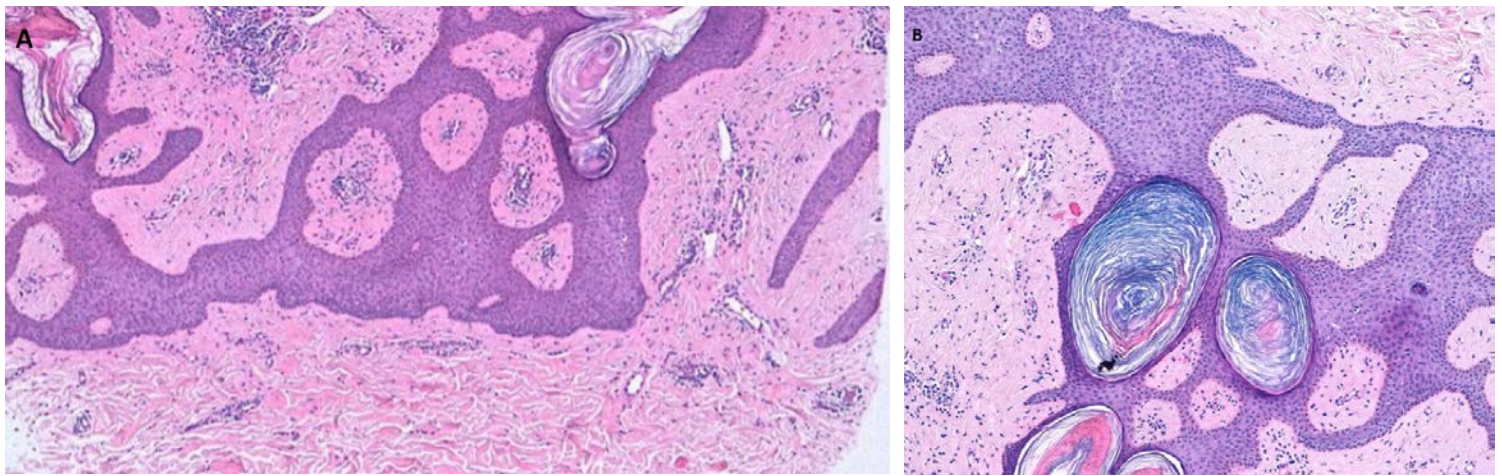


Figure 2. (A) Irregular filiform acanthosis with elongation and anastomosis of rete ridges, irregular orthokeratotic hyperkeratosis (HEx10)
(B) Pseudocyst formation and hyperpigmentation of the basal layer (HEx40)

Discussion

The cause of NHNA is unknown. According to some authors, it may appear at puberty or during pregnancy in women and in men treated with diethylstilbestrol for prostate carcinoma. It may also be the result of hormonal disturbance [1]. NHNA can pose a serious aesthetic and psychologic problem to the patient. It is believed that it is more common than in the past; no evident explanation is provided for that, but it may related to more accurate diagnosis [2].

The diagnosis of NHNA is based on clinical and histopathological features. The differential diagnosis includes Paget disease, superficial basal cell carcinoma, dermatophytosis, and Bowen disease.

There is no uniformly effective treatment. Conservative approaches include keratolysis as salicylic acid 6%, lactic acid lotion, topical steroids, topical tretinoin, oral vitamin A, and calcipotriol. Non-conservative methods are cryotherapy, laser and surgery. In treating NHNA, one has to consider the need for restoring the aesthetic appearance of the breast [3].

Conclusion

In conclusion, we report a patient with breast areola plaques diagnosed as NHNA. Dermatologists, gynecologists, and general practitioners have an important part to play in recognizing this condition that may be underdiagnosed because of lack of awareness.

References

1. Fenniche S, Badri T. Images in clinical medicine. Nevoid hyperkeratosis of the nipple and areola. *N Engl J Med.* 2010;362:1618. [PMID: 20427810]

2. Higgins HW, Jenkins J, Horn TD, Kroumpouzou G. Pregnancy-associated hyperkeratosis of the nipple: a report of 25 cases. *JAMA Dermatol* 2013;149: 722-6. [PMID: 23616176]
3. Foustanos A, Panagiotopoulos K, Ahmad D, Konstantopoulos K. Surgical Approach for Nevoid Hyperkeratosis of the Areola. *J Cutan Aesthet Surg*. 2012;5:40-2. [PMID: 22557856]