

# UC Davis

## Dermatology Online Journal

### Title

Review of onychocryptosis: epidemiology, pathogenesis, risk factors, diagnosis and treatment

### Permalink

<https://escholarship.org/uc/item/9985w2n0>

### Journal

Dermatology Online Journal, 25(9)

### Authors

Geizhals, Solomon  
Lipner, Shari R

### Publication Date

2019

### DOI

10.5070/D3259045583

### Copyright Information

Copyright 2019 by the author(s). This work is made available under the terms of a Creative Commons Attribution-NonCommercial-NoDerivatives License, available at <https://creativecommons.org/licenses/by-nc-nd/4.0/>

Peer reviewed

# Review of onychocryptosis: epidemiology, pathogenesis, risk factors, diagnosis and treatment

Solomon Geizhals<sup>1</sup> BA, Shari R Lipner<sup>2</sup> MD PhD

Affiliations: <sup>1</sup>SUNY Downstate Medical School, Brooklyn, New York, USA, <sup>2</sup>Department of Dermatology, Weill Cornell Medicine, New York, New York, USA

Corresponding Author: Shari R. Lipner MD, PhD, 1305 York Avenue, New York, NY 10021, Tel: 646-962-3376, Fax: 646-962-0033, Email: [shl9032@med.cornell.edu](mailto:shl9032@med.cornell.edu)

## Abstract

Ingrown toenail, or onychocryptosis, is a highly prevalent nail condition that occurs when the nail edge grows into the periungual dermis. It most frequently affects the hallux and has a biphasic presentation, being most common in the second and fifth decades. It is often painful and may be debilitating in severe cases. Risk factors include trauma, weight changes, poor nail-cutting technique, and hyperhidrosis. Both conservative and surgical treatments have been described, and choice of therapy is dependent on patient co-morbidities, severity, and associated symptoms. This review covers the epidemiology, risks factors, pathogenesis, evaluation, and staging of ingrown toenails, as well as, treatment options. Although there is an unmet need for clinical trials comparing therapies, current recommendations are to treat conservatively and then proceed to surgical therapies if symptoms persist.

*Keywords: nails, ingrown toenails, ingrowing toenails, onychocryptosis, onychodystrophy, nail surgery, taping, phenol, matricectomy, nail avulsion*

## Introduction

An ingrown toenail or *unguis incarnates*, commonly referred to as onychocryptosis, is a common and often painful nail condition [1]. It is characterized by penetration of the periungual dermis by its contiguous nail plate (**Figure 1**) and often results in a cascade of foreign body, inflammatory, infectious, and reparative processes that can become both chronic and cyclical [2]. In severe cases,

onychocryptosis may be debilitating and adversely affect daily living [3]. Simple measures, such as the use of soaks and proper trimming technique, may relieve symptoms with arrest of the progressive pathology. However, more definitive care is often required [4].

## Discussion

### Epidemiology

Ingrowing toenail prevalence and epidemiological data is sparse. It is likely under-reported because patients are unlikely to seek medical care if they have mild symptoms [3]. The 1990 United States (US) National Health Survey reported increased prevalence in advanced age, in those earning less than \$10,000 per year, and in residents of the southern US. This study also showed that onychocryptosis is more common in Caucasians than African Americans in nearly every age group [4]. However, other studies did not show any significant difference in race or ethnicity [5]. There is a wide range of data regarding gender prevalence, various studies show a higher pervasiveness in females, a higher incidence in males, or no sex predilection [3-5].

Ingrown nails are believed to have a bimodal presentation, presenting between the first and third decades and then in the elderly [1, 2]. One study reported that nearly 40% of 21-year-olds with a nail disorder had onychocryptosis [6]. However, in a recent cross-sectional study performed in Spain, prevalence was 15.7% in a podiatric population with an average age of 54 years old, countering prevailing thought [7]. Prevalence in the general population ranges from 2.5%-5% and is more common in

diabetics (13%-32%), [8]. Diabetics, and others suffering from impaired arterial circulation and decreased sensation, may present with more severe cases (i.e. secondary infection, gangrene), [9].

Onychocryptosis of the feet is most often localized to the great toe (70%), which is likely related to increased trauma during ambulation [7]. This hypothesis correlates with the fact that ingrown nails commonly form at the distal-lateral margin of the nail, which often bears the brunt of weight-bearing [10]. There is little propensity for the left or right foot [7].

*1. Risk Factors and Pathogenesis*

Multiple risk factors for ingrown toenails have been reported including improper nail trimming technique, onychotillomania, trauma, history of nail surgery, constricting footwear, obesity, bony abnormalities, hyperhidrosis, and onychomycosis, most often there are multifactorial etiologies [11, 12].

Improper nail trimming technique is a well-known risk factor for ingrown toenails [6]. While attempting to “round off” nail corners (nails should be cut straight across), patients may inadvertently create barbs and spicules. Toe compression can cause the

distal nail bed to shrink and impede the re-growing nail. A spicule of the lateral or distal nail can anchor itself into the periungual tissue and penetrate deeply as the nail plate grows. Pain relief is often difficult to achieve, because trimming the spicule necessitates cutting soft tissue as well. A vicious cycle of pain with unsuccessful attempts at relief often aggravates the condition [10].

Trauma is another recognized risk for ingrown nails [8]. Blunt force during ambulation, in conjunction with constricting footwear or expanding feet (owing to edema or weight gain), can cause an existing nail barb to penetrate the nail fold [13]. Decreased incidence has been observed in barefoot populations [14]. Patients with a second toe length equal to or greater than their ipsilateral hallux had increased onychocryptosis incidence related to increased laterodistal pressure on the hallux nail fold pushing against footwear, mimicking skin hypertrophy [4, 14].

Obesity may facilitate onychocryptosis with increased soft tissue in the entire habitus and lower extremity, simulating periungual hypertrophy and increasing constriction by the shoes. A wider gait and larger habitus can accentuate pressure on nail folds

**Table 1.** General measures for treatment and prevention of onychocryptosis.

General Measures
<i>Address underlying etiology-</i> evaluate and treat for obesity, pedal edema, onychomycosis, <sup>8</sup> paronychia, diabetes mellitus, subungual neoplasms, nail abnormalities (shape of the nail plate), thickened nail folds, hallux eversion, medications (indinavir, ritonavir, retinoids, docetaxel, cyclosporine, and oral antifungals). <sup>1</sup>
<i>Suitable footwear-</i> Use of “wide toe box” or “open toe” shoes should be encouraged as increased constriction can mimic nail hypertrophy. Hence, patients should avoid high heeled or pointy shoes that are too narrow, but with suitable support (cushioning, laces) to prevent feet sliding forward and being compressed by the front of the shoe. <sup>1</sup>
<i>Proper nail cutting technique education-</i> Patients are advised to trim toenails by cutting straight across the nail plate without rounding the edges. Incorrectly rounding off the nail plate corners promotes barbs or spicules that may anchor into the periungual soft tissue. <sup>10</sup>
<i>Warm soaks-</i> soaking the affected toe and foot for 10 to 20 minutes daily in warm, soapy water often provides symptomatic relief. Hydrogen peroxide and iodine can be used for cleaning. <sup>1</sup>
<i>+/- Topicals –</i> Treating the nail folds with topical antibiotics, such as polymyxin/neomycin or a mid- to high-potency steroid cream or ointment, twice daily for a week has been suggested, but is controversial and clinical trial data is lacking. <sup>14</sup> Application of silver nitrate to the granulation tissue may decrease inflammation and expedite healing. <sup>1</sup>
<i>Podiatry referral-</i> Older patients and patients with poor compliance, visibility, or flexibility may need help with proper nail trimming. Debridement may relieve symptoms by reducing thickened nails, which predispose to onychocryptosis. Additionally, custom orthotics and toe spacers can be useful in relieving pressure on the nail folds. <sup>4</sup>

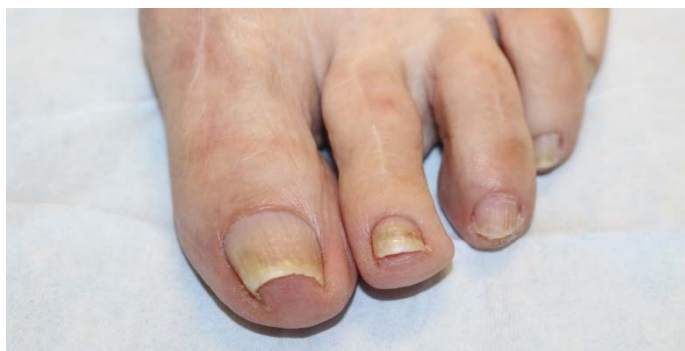causing surreptitious trauma and onychocryptotic progression. Similarly, diabetes, as well as, thyroid, cardiac, and renal disorders can increase lower extremity edema mimicking the effect of obesity on the nail unit [8].

Nail matrix shape is closely related to morphology of the distal phalanx dorsum. An upturned distal phalanx may traumatize the nail matrix and deepen the nail groove, thereby creating a mismatched nail plate relative to the lateral or distal nail fold and contributing to onychocryptosis development. Recalcitrant ingrown toenails have been successfully treated by transecting a portion of the bony distal phalanx [15]. Additionally, abnormal hallux interphalangeal angles correlate with a higher prevalence of onychocryptosis [16].

Hyperhidrosis may contribute to the development of ingrowing toenails, as periungual skin integrity may be compromised via maceration. This is especially notable in adolescents in whom perspiration of the feet is more commonplace, increasing nail plate malleability and facilitating skin perforation [13]. Onychomycosis with accompanying hyperkeratosis may result in a crumbling nail plate with nail spicules that may anchor into the surrounding skin [1]. Nail thickness may be a risk factor owing to decreased flexibility, but it has also been proposed that increased malleability of thin and flattened nails heightens the risk of onychocryptosis [6, 17].

### 2. History and Physical Examination

When evaluating onychocryptosis, patients are questioned about chronology, prior trauma, footwear, occupation, sports activities, and hobbies.



**Figure 1.** Onychocryptosis of the left first toenail in an 80-year-old woman. The lateral aspect of the nail plate is penetrating the periungual dermis of the lateral nail fold.

The presence of pain should be assessed at rest, standing, and ambulating. Physical examination includes all 10 toenails, plantar and dorsal surfaces of the feet, and web spaces. All nail polish should be removed to facilitate a complete examination. The nail folds and nail plate (color, thickness, curvature, degree of onycholysis if present) are examined with the toes on a flat surface and spread apart. The nails are also evaluated with the patient upright and during the gait.

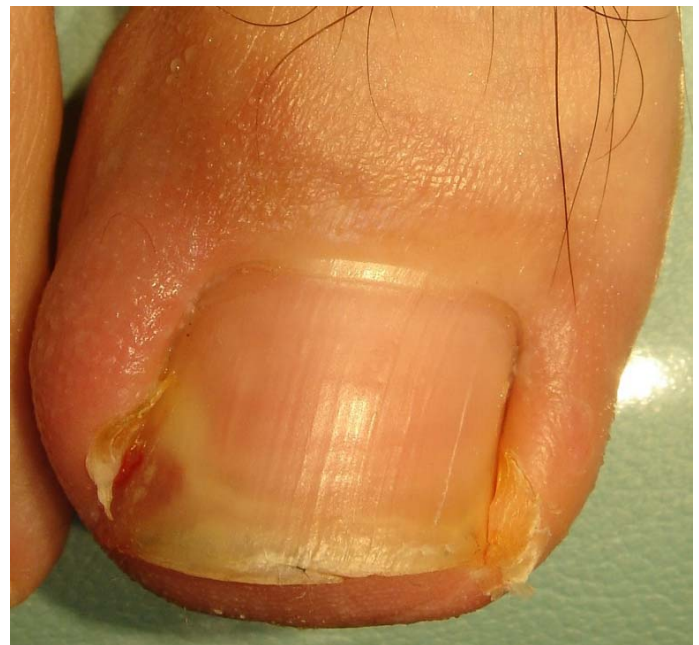### 3. Staging

Traditionally, classification of ingrown toenails is divided into three stages [18]:

Mild (Stage I) - nail fold swelling, edema, erythema, and pain exacerbated by pressure (**Figure 1**).

Moderate (Stage II) - Stage I features coupled with an active or acute infection. Presents as granulation tissue, seropurulent discharge, or ulceration of the nail fold (**Figure 2**).

Severe (Stage III) - chronic inflammation with formation of epithelialized granulation tissue with marked nail fold hypertrophy (**Figure 3**).



**Figure 2.** Stage II onychocryptosis of the left first toenail. Note the Stage I features (edema, erythema) coupled with ulceration of the lateral nail fold. Credit: Dr. Alfonso Martínez Nova, Centro Universitario de Plasencia, Universidad de Extremadura, Extremadura, Spain.



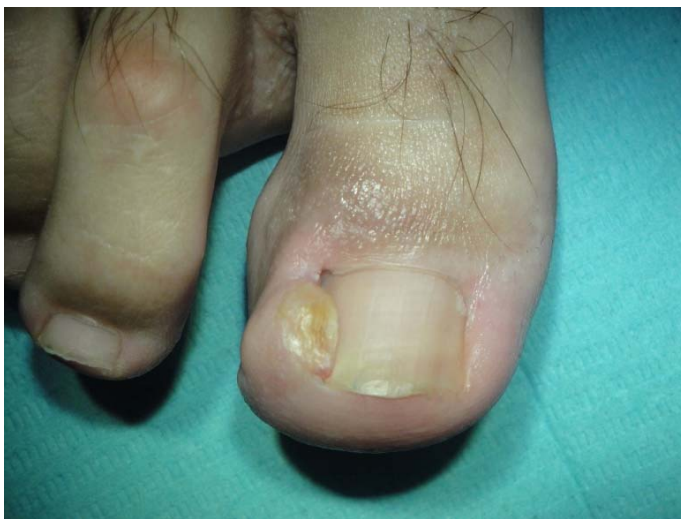Other staging systems have been proposed, however, assessing the exact stage can be subjective. Therefore, staging is more often used for research purposes, rather than in clinical practice [10, 19-21].

#### 4. Treatment

Treatment can be approached either conservatively (non-surgical) or surgically. Conservative treatment is often effective for stage I, whereas stages II and III often require surgical intervention [22, 23]. A 2012 Cochrane systematic review concluded that surgical interventions were more effective in preventing recurrence, especially when coupled with phenol application, but more evidence-based research was required [2]. Although staging may guide therapy, treatment is dictated by etiology, clinical presentation, symptoms, impact on daily living, and likelihood of patient compliance. Regardless of approach, some general measures can be recommended to all patients regardless of stage as primary or adjunctive therapy (**Table 1**).

#### 5.1 Non-surgical Approaches

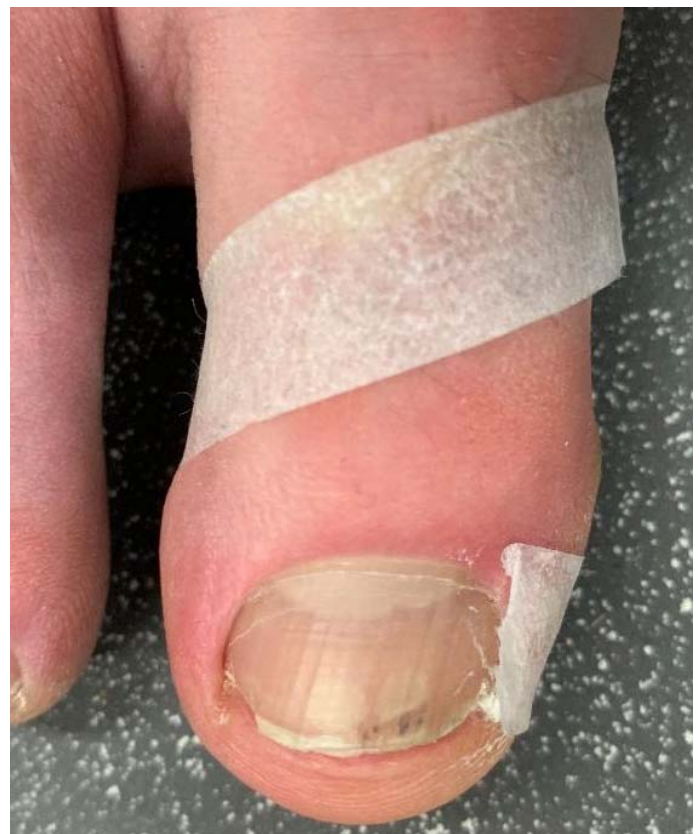Conservative approaches are used first-line because they are cost effective and may circumvent the need for an invasive procedure with risk of more severe adverse effects [1]. The objective is to relieve symptoms, prevent the ingrown toenail from



**Figure 3.** Stage III onychocryptosis of the right first toenail. Note the formation of epithelialized granulation tissue and marked nail fold hypertrophy on the lateral aspect of the nail plate. Credit: Dr. Alfonso Martínez Nova, Centro Universitario de Plasencia, Universidad de Extremadura, Extremadura, Spain.

worsening, address the underlying problem, and prevent recurrences. These treatments require excellent patient compliance and include, but are not limited to, taping, packing, dental floss, gutter treatment, nail braces, and super-elastic wiring.

Multiple taping methods exist, with the goal of separating the nail fold from the offending nail edge [24]. The most basic taping method involves daily application of a strip of tape, pulling the offending nail fold away from the nail plate in oblique and proximal directions while preventing circulation constriction (**Figure 4**). Additional securing may be required owing to moisture, use of cyanoacrylate adhesive, acetone, mastisol, and a second anchoring tape have all been described [10, 25, 26]. An elegant variation is the “split tape-strap procedure” in which the nail is positioned between an adhesive with a midline slit and the tape pulled toward the plantar surface to separate the nail fold from the nail edge

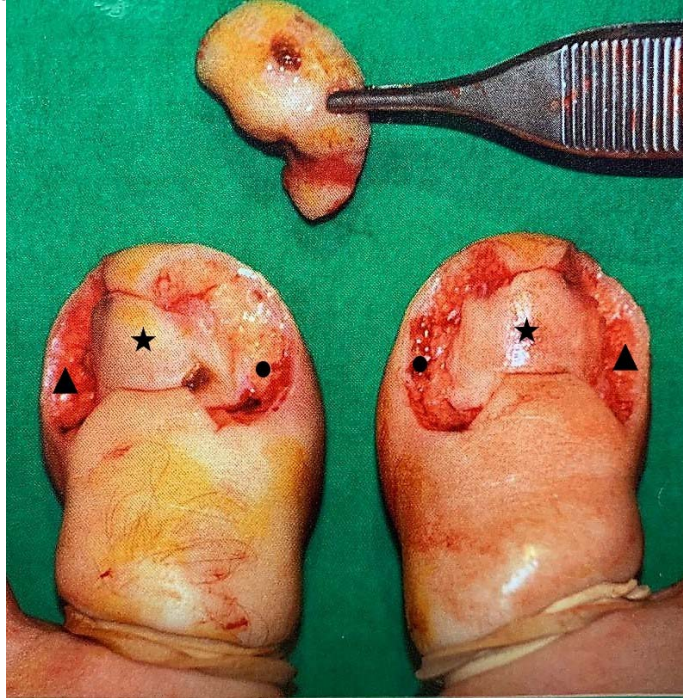


**Figure 4.** Illustration of the basic taping procedure using medical tape to treat onychocryptosis of the right first toenail. The tape is placed on the medial aspect of the lateral nail fold and pulled in an oblique and proximal direction around the toe dorsally, separating the nail fold from the intruding nail plate.

[27]. Most patients can tape their nails at home after proper education.

Cotton packing entails the daily home-insertion of a cotton wisp, sometimes soaked with antiseptic, between the corner of the nail plate and the nail fold. It is replaced daily, with progressively more cotton inserted until sufficient separation is achieved to mitigate symptoms [28]. Alternatively, a "rolled cotton padding" or "cotton-nail cast" with cyanoacrylate can be applied in the office and left in place for up to 2 months [29, 30]. Cotton packing has been successful in treating stage I, II, and III patients [31]. Dental floss can be substituted for cotton. The patient places dental floss obliquely under the offending nail edge and inserts a new floss daily until sufficient separation is achieved [32].

Gutter treatment refers to the use of a sterile plastic tube, from an IV drip infusion or butterfly needle, with a vertical slit that is inserted into the nail groove, using stitches, cyanoacrylate, or acrylic resin after



**Figure 5.** Intra-operative view of the Vandembos procedure on the bilateral great toenails. Note the soft tissue that was resected currently in the grip of the forceps. The procedure was performed on both medial and lateral aspects of the nail fold owing to onychocryptosis of both edges of the patient's toenails. For reference, the underlying nail plate is starred, the medial nail folds contain circles, and the lateral nail folds contain triangles. Credit: Dr. Henry Chapeskie. Thorndale Lions Medical Center, Thorndale, Ontario.

appropriate anesthesia [1, 33]. Gutter application with acrylic resin (N=106) had a 100% cure rate, even for more severe stages. The sleeve protects the lateral nail groove and results in faster resolution of granulation tissue [34]. Treatment duration is dependent on the time required for normal nail growth, which is approximately 2-12 weeks, after which the tube is easily removed [13].

Orthonyxia, or nail correction, is performed to rectify nail overcurvature. A nail brace (a metal brace is hooked around the lateral edges of the nail plate under tension) or super-elastic wiring (a wire that is drilled into the distal lateral edges of the nail under tension) may be utilized [35-37]. Nail bracing resulted in significant symptomatic improvement compared to partial matrix excision in both adults and children (N=105) with comparable recurrence rates [23, 35, 36].

### 5.2 Surgical Approaches

Surgery is indicated if conservative care fails, for recurrences, or for significant infection. There have been many techniques described, this review will focus on techniques that dermatologists can easily perform as well as some advanced techniques. Surgery is used to treat either the hypertrophic soft tissue substrate or the discordance of the wider nail plate relative to a narrow nail bed, with most techniques focusing on the latter [1, 10].

Partial nail avulsion is a common and effective method to treat onychocryptosis. Anesthesia is first administered and a tourniquet is applied to the affected toe to create a bloodless field [38]. An English nail-splitter is used to cut the ingrown part of the nail plate along the longitudinal axis, cutting all the way back under the proximal nail fold. A clamp is then used to detach the longitudinal strip of nail [39].

Partial nail avulsion is generally used concurrently with surgical, electrocautery, or chemical matricectomy to prevent recurrences [40]. Chemical matricectomy is most commonly employed and may utilize phenol, sodium hydroxide, or trichloroacetic acid (TCA), [41]. Advantages of this technique are low recurrence rates, short healing times, and excellent cosmetic results, these may be the procedure of choice in diabetics [1, 42]. However, the chemicals



are challenging to contain, and risks of the procedure include unexpected matrix loss and risk of infection. Better precision is achieved by using a urethral swab as opposed to bulkier gauze [43, 44].

Phenol matricectomy is the most commonly used chemical method, owing to ease of execution and low recurrence rates (0-11%), [45]. Phenol is a cauterant and powerful disinfectant with local anesthetic activity. Adverse effects include chemical burns and inflammatory changes in adjacent areas, which can be minimized by applying petrolatum to protect the nail folds [1]. Phenol, 88-90%, is applied for 30 seconds to 4 minutes (1-3 cycles) with alcohol or saline lavages for neutralization following each cycle [10, 42, 45-48]. Healing coupled with soaks to promote drainage generally takes 2-6 weeks. Post-phenol matricectomy healing times may be longer in smokers owing to delayed wound healing [49]. A recent study showed a higher risk for recurrence with phenol (17.8%) relative to surgical matricectomy (8.2%), [41].

Recently, the use of sodium hydroxide, TCA, and bichloroacetic acid have been used as alternatives to phenol with encouraging results, although further research is still needed [46, 50, 51]. Sodium hydroxide (10%) is applied once for one minute with similar efficacy to phenol, but with shorter healing times (1-2 weeks), [46]. Trichloroacetic (100%) is applied for a one-minute single cycle with healing as early as two weeks to as late as four weeks, with low recurrence rates [42, 48, 50].

The Vandembos procedure involves radical resection of the affected nail fold down to the bone with healing by secondary intention (**Figure 5**). Since the nail plate, matrix, and nail bed are not manipulated excellent cosmetic results are achieved with low recurrence rates and high patient satisfaction. Healing can take up to 6 weeks with risk of post-operative bleeding [52, 53]. Loss of cutaneous innervation is a rare postoperative complication [1]. Variations range from the extreme Super-U technique (ideal for severe cases) to minor wedge resections with judiciously placed sutures, these techniques separate the nail from soft tissue or specifically cause adherence of the nail plate to the nail fold [54-56].

The Zadik technique focuses on total nail avulsion coupled with matrix destruction [57]. Matricectomy can be accomplished surgically, chemically, or via electrocautery, [2]. In a prospective clinical trial (N=105), the Zadik group had a statistically significant improvement in returning to normal activity and footwear relative to the chemical matricectomy group. However, their recurrence rate was 34.2% relative to 4.4% in the total chemical ablation group ( $P<0.05$ ), [58].

The Winograd procedure involves a wedge excision of the lateral nail fold coupled with a partial removal of the nail plate and partial matricectomy [59]. Wound healing may take up to 6 weeks, increasing the risk of infection [10]. Recurrence rates are 5-29% but are significantly decreased when coupled with electrocoagulation of the germinal matrix [60]. One prospective case-series (N=189) showed that surgical matrix destruction without wedge excision had similar recurrence rates to those with wedge excisions [59].

More recently, CO<sub>2</sub> laser has been used for matricectomy with a success rate of 50-100% [1]. This method employs rapid, targeted destruction of the nail matrix with limited damage to surrounding tissues with little bleeding or inflammation [61]. However, its prolonged healing time with poor cosmetic outcomes may limit its usage [62].

## Conclusion

Ingrowing toenails are a highly prevalent nail condition that may cause pain and affect daily living. After diagnosis, underlying etiologies are addressed and general measures (proper trimming technique, supportive footwear, podiatry referral) are employed. Non-surgical techniques, including taping and gutter treatment can be used first-line. Surgical therapies are generally reserved for more severe cases or for recurrences after conservative treatment. Randomized clinical trials are needed to adequately compare efficacy, adverse effects, and recurrence rates of different techniques.

## Potential conflicts of interest

The authors declare no conflicts of interests.

## References

1. Khunger N, Kandhari R. Ingrown toenails. *Indian J Dermatol Venereol Leprol*. 2012;78:279-89. [PMID: 22565427].
2. Eekhof JA, Van Wijk B, Knuistingh Neven A, van der Wouden JC. Interventions for ingrowing toenails. *Cochrane Database Syst Rev*. 2012;Cd001541. [PMID: 22513901].
3. Borges APP, Pelafsky VPC, Miot LDB, Miot HA. Quality of Life With Ingrown Toenails: A Cross-Sectional Study. *Dermatol Surg*. 2017;43:751-3. [PMID: 28291066].
4. DeLauro NM, DeLauro TM. Onychocryptosis. *Clin Podiatr Med Surg*. 2004;21:617-30. [PMID: 15450901].
5. Dunn JE, Link CL, Felson DT, et al. Prevalence of foot and ankle conditions in a multiethnic community sample of older adults. *Am J Epidemiol*. 2004;159:491-8. [PMID: 14977645].
6. Pico AM, Verjano E, Mayordomo R. Relation Between Nail Consistency and Incidence of Ingrown Toenails in Young Male Runners. *J Am Podiatr Med Assoc*. 2017;107:137-43. [PMID: 28394683].
7. Mosquera-Fernandez A, Diaz-Rodriguez M, Gonzalez-Martin C, et al. Habititos podologicos en personas con alteraciones ungueales. *Gac Med Mex*. 2017;153:810-7. [PMID: 29414977].
8. Vural S, Bostanci S, Kocyigit P, et al. Risk Factors and Frequency of Ingrown Nails in Adult Diabetic Patients. *J Foot Ankle Surg*. 2018;57:289-95. [PMID: 29329712].
9. Perper M, Tosti A. Chapter 6: Nail Diseases in the Elderly. In: Nail disorders. Tosti A, Piraccini BM, editors. 1<sup>st</sup> ed. Elsevier; 2018. p. 52-53.
10. Haneke E. Controversies in the treatment of ingrown nails. *Dermatol Res Pract*. 2012;2012:783924. [PMID: 22675345].
11. Erdogan FG, Guven M, Erdogan BD, Gurler A. Previous nail surgery is a risk factor for recurrence of ingrown nails. *Dermatol Surg*. 2014;40:1152-4. [PMID: 25255279].
12. Yang G, Yanchar NL, Lo AY, Jones SA. Treatment of ingrown toenails in the pediatric population. *J Pediatr Surg*. 2008;43:931-5. [PMID: 18485969].
13. Heidelbaugh JJ, Lee H. Management of the ingrown toenail. *Am Fam Physician*. 2009;79:303-8. [PMID: 19235497].
14. Gunal I, Kosay C, Veziroglu A, et al. Relationship between onychocryptosis and foot type and treatment with toe spacer. A preliminary investigation. *J Am Podiatr Med Assoc*. 2003;93:33-6. [PMID: 12533554].
15. Li J, Chen J, Hong G, et al. Clinical study of treatment for recalcitrant ingrown toenail by partial distal phalanx removal. *J Plast Reconstr Aesthet Surg*. 2009;62:1327-30. [PMID: 18678536].
16. Cordoba-Fernandez A, Montano-Jimenez P, Cohena-Jimenez M. Relationship between the presence of abnormal hallux interphalangeal angle and risk of ingrown hallux nail: a case control study. *BMC Musculoskelet Disord*. 2015;16:301. [PMID: 26472543].
17. Langford DT, Burke C, Robertson K. Risk factors in onychocryptosis. *Br J Surg*. 1989;76:45-8. [PMID: 2917259].
18. Heifetz CJ. Operative management of ingrown toenail. *Mo Med*. 1945;42:213-6. [PMID: 21007315].
19. Al Kline D. Onychocryptosis: a simple classification system. *Foot Ankle J*. 2008;1:6. [DOI: 10.3827/foaj.2008.0105.0006]
20. Mozena JD. The Mozena Classification System and treatment algorithm for ingrown hallux nails. *J Am Podiatr Med Assoc*. 2002;92:131-5. [PMID: 11904324].
21. Martinez-Nova A, Sanchez-Rodriguez R, Alonso-Pena D. A new onychocryptosis classification and treatment plan. *J Am Podiatr Med Assoc*. 2007;97:389-93. [PMID: 17901344].
22. Tian J, Li J, Wang F, Chen Z. A new perspective on the nail plate for treatment of ingrown toenail. *Dermatol Pract Concept*. 2018;8:22-7. [PMID: 29445570].
23. Park DH, Singh D. The management of ingrowing toenails. *BMJ*. 2012;344:e2089. [PMID: 22491483].
24. Manca D. Practice tips. Taping toes. Effective treatment for ingrown toenails. *Can Fam Physician*. 1998;44:275. [PMID: 9512830].
25. Nishioka K, Katayama I, Kobayashi Y, et al. Taping for embedded toenails. *Br J Dermatol*. 1985;113:246-7. [PMID: 4027192].
26. Tsunoda M, Tsunoda K. Patient-controlled taping for the treatment of ingrown toenails. *Ann Fam Med*. 2014;12:553-5. [PMID: 25384818].
27. Watabe A, Yamasaki K, Hashimoto A, Aiba S. Retrospective evaluation of conservative treatment for 140 ingrown toenails with a novel taping procedure. *Acta Derm Venereol*. 2015;95:822-5. [PMID: 25669233].
28. Senapati A. Conservative outpatient management of ingrowing toenails. *J R Soc Med*. 1986;79:339-40. [PMID: 3723536].
29. d'Almeida LF, Nakamura R. Onychocryptosis Treatment Pearls: The "Rolled Cotton Padding" Maneuver and the "Artificial Resin Nail" Technique. *Dermatol Surg*. 2016;42:434-6. [PMID: 26849088].
30. Gutierrez-Mendoza D, De Anda Juarez M, Avalos VF, et al. "Cotton nail cast": a simple solution for mild and painful lateral and distal nail embedding. *Dermatol Surg*. 2015;41:411-4. [PMID: 25738445].
31. Du JF, Xi XY, Liu ZH. Successful conservative treatment with cotton wisp for ingrown toenail with granulation. *Dermatol Ther*. 2016;29:486-7. [PMID: 27543365].
32. Woo SH, Kim IH. Surgical pearl: nail edge separation with dental floss for ingrown toenails. *J Am Acad Dermatol*. 2004;50:939-40. [PMID: 15153897].
33. Taheri A, Mansoori P, Alinia H, et al. A conservative method to gutter splint ingrown toenails. *JAMA Dermatol*. 2014;150:1359-60. [PMID: 25188750].
34. Arai H, Arai T, Nakajima H, Haneke E. Formable acrylic treatment for ingrowing nail with gutter splint and sculptured nail. *Int J Dermatol*. 2004;43:759-65. [PMID: 15485537].
35. Kruijff S, van Det RJ, van der Meer GT, et al. Partial matrix excision or orthonyxia for ingrowing toenails. *J Am Coll Surg*. 2008;206:148-53. [PMID: 18155581].
36. Shih YH, Huang CY, Lee CC, Lee WR. Nail Brace Application: A Noninvasive Treatment for Ingrown Nails in Pediatric Patients. *Dermatol Surg*. 2019;45:323-6. [PMID: 29757859].
37. Moriue T, Yoneda K, Moriue J, et al. A simple therapeutic strategy with super elastic wire for ingrown toenails. *Dermatol Surg*. 2008;34:1729-32. [PMID: 19076901].
38. Lipner SR. Pain-minimizing strategies for nail surgery. *Cutis*. 2018;101:76-7. [PMID: 29554159].
39. Bryant A, Knox A. Ingrown toenails: the role of the GP. *Aust Fam Physician*. 2015;44:102-5. [PMID: 25770573].
40. Zuber TJ. Ingrown toenail removal. *Am Fam Physician*. 2002;65:2547-52, 2554. [PMID: 12086244].
41. Romero-Perez D, Betilloch-Mas I, Encabo-Duran B. Onychocryptosis: a long-term retrospective and comparative



- follow-up study of surgical and phenol chemical matricectomy in 520 procedures. *Int J Dermatol*. 2017;56:221-4. [PMID: 27734499].
42. Kim SH, Ko HC, Oh CK, et al. Trichloroacetic acid matricectomy in the treatment of ingrowing toenails. *Dermatol Surg*. 2009;35:973-9. [PMID: 19397660].
  43. Richert B. Surgical management of ingrown toenails - an update overdue. *Dermatol Ther*. 2012;25:498-509. [PMID: 23210749].
  44. Kocyigit P, Bostanci S, Ozdemir E, Gurgey E. Sodium hydroxide chemical matricectomy for the treatment of ingrown toenails: comparison of three different application periods. *Dermatol Surg*. 2005;31:744-7. [PMID: 16029698].
  45. AlGhamdi KM, Khurram H. Nail tube splinting method versus lateral nail avulsion with phenol matricectomy: a prospective randomized comparative clinical trial for ingrown toenail treatment. *Dermatol Surg*. 2014;40:1214-20. [PMID: 25322163].
  46. Bostanci S, Kocyigit P, Gurgey E. Comparison of phenol and sodium hydroxide chemical matricectomies for the treatment of ingrowing toenails. *Dermatol Surg*. 2007;33:680-5. [PMID: 17550444].
  47. Rahn ML, Lazar LG. Phenol matricectomy in patients with diabetes. *J Foot Ankle Surg*. 1997;36:464-5. [PMID: 9430004].
  48. Andre MS, Caucanas M, Andre J, Richert B. Treatment of Ingrowing Toenails With Phenol 88% or Trichloroacetic Acid 100%: A Comparative, Prospective, Randomized, Double-Blind Study. *Dermatol Surg*. 2018;44:645-50. [PMID: 29701619].
  49. Alvarez-Jimenez J, Cordoba-Fernandez A. Influence of smoking on wound healing in patients undergoing nail matrix phenolization: a prospective randomized clinical study. *Adv Skin Wound Care*. 2014;27:229-36; quiz 37-8. [PMID: 24732127].
  50. Terzi E, Guvenc U, Tursten B, et al. The Effectiveness of Matrix Cauterization With Bichloroacetic Acid in the Treatment of Ingrown Toenails. *Dermatol Surg*. 2017;43:728-33. [PMID: 28362670].
  51. Terzi E, Guvenc U, Tursten B, et al. The effectiveness of matrix cauterization with trichloroacetic acid in the treatment of ingrown toenails. *Indian Dermatol Online J*. 2015;6:4-8. [PMID: 25657908].
  52. Livingston MH, Coriolano K, Jones SA. Nonrandomized assessment of ingrown toenails treated with excision of skinfold rather than toenail (NAILTEST): An observational study of the Vandembos procedure. *J Pediatr Surg*. 2017;52:832-6. [PMID: 28190555].
  53. Chapeskie H. Ingrown toenail or overgrown toe skin?: Alternative treatment for onychocryptosis. *Can Fam Physician*. 2008;54:1561-2. [PMID: 19005128].
  54. Ince B, Dadaci M, Altuntas Z. Knot technique: a new treatment of ingrown nails. *Dermatol Surg*. 2015;41:250-4. [PMID: 25627634].
  55. Mousavi SR, Khoshnevice J. A new surgical technique for ingrown toenail. *ISRN Surg*. 2012;2012:438915. [PMID: 22655208].
  56. Uygur E, Carkci E, Senel A, et al. A new and simple suturing technique applied after surgery to correct ingrown toenails may improve clinical outcomes: A randomized controlled trial. *Int J Surg*. 2016;34:1-5. [PMID: 27514456].
  57. Zadik F. Obliteration of the nail bed of the great toe without shortening the terminal phalanx. *Bone Joint J*. 1950;32:66-7 [DOI: 10.1302/0301-620x.32b1.66].
  58. Shaath N, Shea J, Whiteman I, Zarugh A. A prospective randomized comparison of the Zadik procedure and chemical ablation in the treatment of ingrown toenails. *Foot Ankle Int*. 2005;26:401-5. [PMID: 15913526].
  59. Camurcu Y, Sofu H, Issin A, et al. Operative Treatment of the Ingrown Toenail With a Less-Invasive Technique: Flashback to the Original Winograd Technique. *Foot Ankle Spec*. 2018;11:138-41. [PMID: 28587478].
  60. Acar E. Winograd Method Versus Winograd Method With Electrocoagulation in the Treatment of Ingrown Toenails. *J Foot Ankle Surg*. 2017;56:474-7. [PMID: 28242214].
  61. Cocunubo-Blanco HA, Gonzalez-Sixto B, Perez-Paredes G, Rodriguez-Prieto MA. Partial nail matricectomy with carbon dioxide laser. *Actas Dermosifiliogr*. 2014;105:418-9. [PMID: 24626101].
  62. Serour F. Recurrent ingrown big toenails are efficiently treated by CO2 laser. *Dermatol Surg*. 2002;28:509-12. [PMID: 12081681].