

UCSF

UC San Francisco Previously Published Works

Title

Idiopathic AIDS Enteropathy and Treatment of Gastrointestinal Opportunistic Pathogens

Permalink

<https://escholarship.org/uc/item/9739w5w3>

Journal

Gastroenterology, 136(6)

ISSN

0016-5085

Authors

Cello, John P
Day, Lukejohn W

Publication Date

2009-05-01

DOI

10.1053/j.gastro.2008.12.073

Peer reviewed



Since January 2020 Elsevier has created a COVID-19 resource centre with free information in English and Mandarin on the novel coronavirus COVID-19. The COVID-19 resource centre is hosted on Elsevier Connect, the company's public news and information website.

Elsevier hereby grants permission to make all its COVID-19-related research that is available on the COVID-19 resource centre - including this research content - immediately available in PubMed Central and other publicly funded repositories, such as the WHO COVID database with rights for unrestricted research re-use and analyses in any form or by any means with acknowledgement of the original source. These permissions are granted for free by Elsevier for as long as the COVID-19 resource centre remains active.

Idiopathic AIDS Enteropathy and Treatment of Gastrointestinal Opportunistic Pathogens



John P. Cello



Lukejohn W. Day

Gastroenterology Division, Department of Medicine, University of California, San Francisco, San Francisco General Hospital, San Francisco, California

Diarrhea in patients with acquired immune deficiency syndrome (AIDS) has proven to be both a diagnostic and treatment challenge since the discovery of the human immunodeficiency virus (HIV) virus more than 30 years ago. Among the main etiologies of diarrhea in this group of patients are infectious agents that span the array of viruses, bacteria, protozoa, parasites, and fungal organisms. In many instances, highly active antiretroviral therapy remains the cornerstone of therapy for both AIDS and AIDS-related diarrhea, but other targeted therapies have been developed as new pathogens are identified; however, some infections remain treatment challenges. Once identifiable infections as well as other causes of diarrhea are investigated and excluded, a unique entity known as AIDS enteropathy can be diagnosed. Known as an idiopathic, pathogen-negative diarrhea, this disease has been investigated extensively. Atypical viral pathogens, including HIV itself, as well as inflammatory and immunologic responses are potential leading causes of it. Although AIDS enteropathy can pose a diagnostic challenge so too does the treatment of it. Highly active antiretroviral therapy, nutritional supplementation, electrolyte replacements, targeted therapy for infection if indicated, and medications for symptom control all are key elements in the treatment regimen. Importantly, a multidisciplinary approach among the gastroenterologist, infectious disease physician, HIV specialists, oncology, and surgery is necessary for many patients.

More than 100 million people worldwide currently are infected with the human immunodeficiency virus (HIV). Moreover, many have perished from this devastating disease. Beginning in the mid-1980s, a new disease entity, which ultimately would be named the acquired immune deficiency syndrome (AIDS), was described among patients in rural Uganda, Zaire, Tanzania,

and in the United States. Because major symptom complexes involved the digestive tract with profound weight loss, malnutrition, and severe watery diarrhea, this disease was named by the indigenous African population slim disease. African patients with this poorly understood illness literally wasted away. Serwadda et al¹ reported that slim disease appeared to occur predominantly in a heterosexual promiscuous population in Africa. At that time, they believed there were no clear indications to implicate other modes of transmission such as insect vectors or injection drug use.

An uncertain, but high, percentage of HIV-infected patients worldwide initially present with or ultimately develop diarrhea with or without highly active antiretroviral therapy (HAART). Currently, substantial diarrhea occurs in about 50% of the HIV-infected individuals in the United States. In the developing world, however, diarrhea may occur with a much higher prevalence, in as many as 80% of HIV-infected individuals. Specific enteric pathogens can be isolated (if patients undergo exhaustive and intensive standard gastrointestinal [GI] evaluation) in most individuals with severe diarrhea. Currently, in areas of the world with access to sophisticated endoscopic evaluation, specific but atypical pathogens likely will be found in nearly 50% of patients with severe stool-study-negative diarrhea. Indeed, colonoscopy with intubation and biopsy of the terminal ileum together with endoscopy of the upper GI tract successfully identifies pathogens in 46% of patients with previously termed idiopathic diarrhea (Table 1).² However, not every patient

Abbreviations used in this paper: AIDS, acquired immune deficiency syndrome; CMV, cytomegalovirus; GALT, gut-associated lymphoid tissue; GI, gastrointestinal; HAART, highly active antiretroviral therapy; HIV, human immunodeficiency virus; MAC, *Mycobacterium avium* complex; OI, opportunistic infection; TB, tuberculosis.

© 2009 by the AGA Institute

0016-5085/09/\$36.00

doi:10.1053/j.gastro.2008.12.073

Table 1. Prospective Endoscopic Evaluation of 71 Patients With Stool-Study–Negative AIDS Diarrhea

Procedures	Sensitivity
Flexible sigmoidoscopy	21/37 (57%)
Duodenum	17/37 (46%)
Duodenum + flexible sigmoidoscopy	29/37 (78%)
Duodenum + full colonoscopy	34/37 (92%)
Full colonoscopy	28/37 (76%)
Full colonoscopy + ileum	35/37 (95%)
Colonoscopy + ileum + duodenum	37/37 (100%)

NOTE. Reprinted from Kearney DL, Koch J., Cello JP. Am J Gastro 1999;94:596–602.

with HIV-associated diarrhea needs a complete endoscopic evaluation. A full endoscopic work-up is necessary in patients with a functionally disabling diarrhea in which the etiology is unclear.

In many patients, diarrhea leads to a diminished quality of life. Small-bowel mucosal diseases routinely are associated with profound malnutrition and are a common manifestation of the HIV disease in the developing world. Diarrhea is an early and pervasive manifestation of HIV disease and is associated with increased morbidity and mortality. Diarrhea also substantially increases health care costs for many patients, particularly those with severe secretory diarrhea and malabsorption/malnutrition necessitating repeat hospitalizations.

Clinical presentations vary among patients with HIV-associated diarrhea depending on the principal area of the GI tract involved. Small-bowel diarrhea tends to produce large, bulky, postprandial stools. If patients with small-bowel diarrhea fast from nutrients they do not have significant amounts of diarrhea. Conversely, after a meal, patients with small-bowel diarrhea report that almost immediately they have postprandial paraumbilical abdominal pain and voluminous diarrhea. Weight loss is characteristic of small-bowel diarrhea. On the other hand, large intestinal diarrhea, so-called *colitic diarrhea*, is associated with frequent, small-volume stools. These patients do not commonly become dehydrated. Colonic diarrhea also may be associated with the presence of visible blood and mucous. These patients with large-bowel diarrhea often have lower-quadrant abdominal pain and/or will have the sensation of rectal urgency. In many instances it is difficult to distinguish between large- and small-bowel diarrhea based on clinical presentation alone, thus highlighting the need for further and more exhaustive diagnostic evaluation.

Idiopathic AIDS Enteropathy

Over the past 2 decades a well-defined subset of HIV/AIDS patients with profound diarrhea, malnutrition, and wasting, with no infectious pathogen identified as the causative agent, has emerged. In 1987, Kotler et al³ noted alterations in intestinal plasma cells of AIDS pa-

tients without identifiable (at that point in time) intestinal pathogens (Figure 1). In HIV-infected patients with AIDS-related complex or fully expressed AIDS, the mean villus/height and mean villus/crypt ratios were significantly lower than those of normal controls (Figure 2). By using immunofluorescence staining, the researchers observed a decrease in immunoglobulin (Ig)A plasma cells and a relative increase in IgM plasma cells in the small bowel and in the colon. There also was decreased quantitative plasma cell fluorescence in samples that were stained for IgA and IgM, implying less cytoplasmic immunoglobulin per cell. However, the depletion of IgA from plasma cells did not always correlate with altered serum IgA concentrations. Kotler et al³ also noted that the lymphoid depletion in patients with AIDS might be patchy and might involve many cells in addition to the plasma cells.

Initial speculation that HIV itself was infecting cells directly, both within the epithelium and the lamina propria, has been tempered by the identification of atypical viruses that rarely were searched for in the GI tract of patients with AIDS-related diarrhea. In 1998, Cunningham et al⁴ first identified rotaviruses and adenoviruses by enzyme-linked immunosorbent assay, electron microscopy, and/or cell culture analyses. These 2 viruses were found in more than 50% of HIV-positive symptomatic patients with diarrhea, but in less than 15% of HIV-negative patients, and in less than 20% of HIV-positive asymptomatic patients without diarrhea. It appeared, therefore, that these viruses occasionally were associated with a high excretion rate in HIV-infected patients with diarrhea and might be associated with acute episodes or relapses of diarrhea. Cunningham et al⁴ also postulated

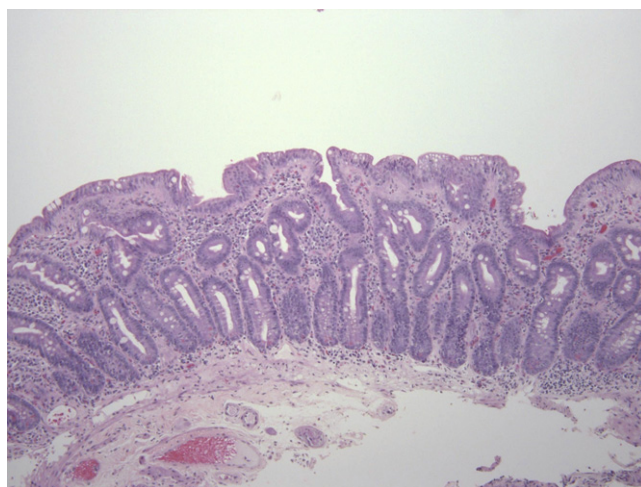


Figure 1. Biopsy of small bowel from a patient with AIDS and pathogen-negative diarrhea. Note the prominent villus atrophy, crypt architectural distortion, decrease in crypt/villus ratio, and the significant influx of lymphocytes within the lamina propria. Figure courtesy of Dr James P. Grenert from the Department of Pathology, University of California, San Francisco.

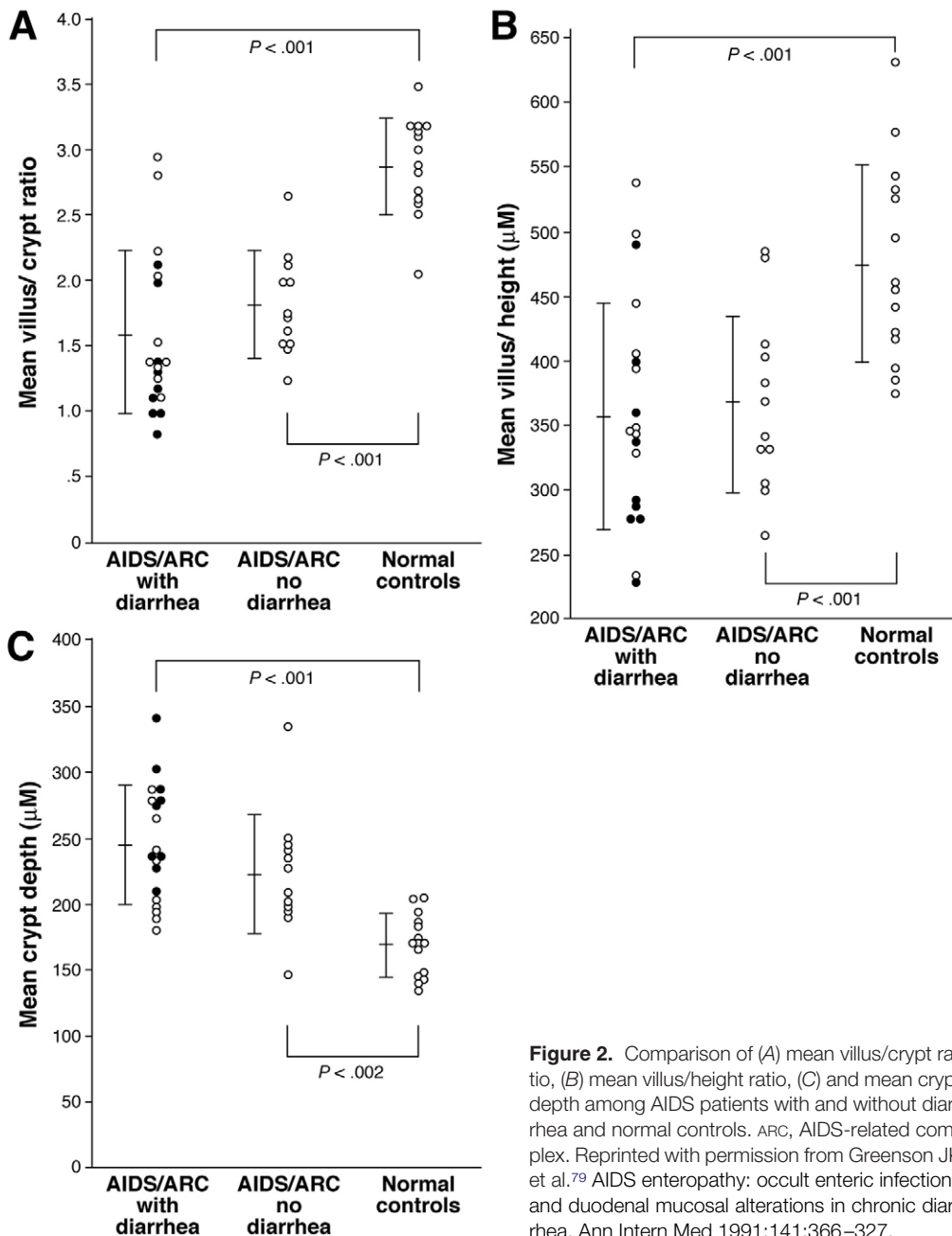


Figure 2. Comparison of (A) mean villus/crypt ratio, (B) mean villus/height ratio, (C) and mean crypt depth among AIDS patients with and without diarrhea and normal controls. ARC, AIDS-related complex. Reprinted with permission from Greenson JK et al.⁷⁹ AIDS enteropathy: occult enteric infections and duodenal mucosal alterations in chronic diarrhea. *Ann Intern Med* 1991;141:366-327.

that there may be additional, yet to be identified, pathogens in patients with chronic or relapsing acute diarrhea.

Grohmann et al,⁵ from the Centers for Disease Control, reported in 1993 on the prevalence of a wide range of enteric viruses in HIV-infected patients with and without diarrhea. Sixty-five HIV-positive patients were grouped into those with diarrhea and those without diarrhea. Adenovirus, astrovirus, and picobirnavirus, but not chronovirus, Caliciviridae, or featureless small round viruses were noted in the stools of HIV-positive patients with diarrhea compared with HIV-infected patients without diarrhea. Overall, 35% of the fecal specimens in patients with AIDS and refractory diarrhea harbored 1 or more of these viruses,

compared with only 12% of the stools of patients without diarrhea (Table 2). Thus, studies and reports of so-called AIDS enteropathy always should be tempered by the reality that these viruses, as well as other infectious agents, ultimately may be found in patients with so-called idiopathic AIDS-related diarrhea. One need only recall belatedly identified pathogens such as mycobacterium-avium complex, cryptosporidium, or microsporidium in patients with previously termed idiopathic AIDS diarrhea.

Recognizing the real potential for unsuspected or unidentified pathogens in the bowel, many investigators have found that HIV itself infects enterocytes, lamina propria cells, and submucosa. Nelson et al⁶ in 1988,

Table 2. Viral Agents Detected in 222 Fecal Specimens From HIV-Infected Patients, According to Whether Diarrhea Was Present

Virus	Diarrhea, n (%)		No diarrhea, n (%)		<i>P</i> value ^a	
	Specimens (N = 109)	Patients (N = 65)	Specimens (N = 113)	Patients (N = 65)	Specimens	Patients
Adenovirus	10 (9)	10 (15)	3 (3)	3 (5)	.047	.076
Astrovirus ^b	13 (12)	9 (14)	2 (2)	2 (3)	.003	.054
Coronavirus-like particle	3 (3)	2 (3)	2 (2)	2 (3)	.679	1.00
Small round viruses						
SRSV ^c	4 (4)	4 (6)	1 (1)	1 (2)	.206	.365
Calicivirus ^c	2 (2)	2 (3)	0	0	.24	.496
Featureless	3 (3)	2 (3)	3 (3)	3 (5)	.621	.619
Picobirnavirus ^d	10 (9)	6 (9)	2 (2)	1 (2)	.017	.115
Total ^e	38 (35)	24 (37)	13 (12)	8 (12)	<.001	.002
Infection with 1 virus	31 (28)	—	13 (12)	—	.002	—
Mixed infection ^f	7 (6)	—	0	—	.006	—

NOTE. A total of 110 patients contributed 222 specimens: 59 patients provided only 1 specimen and 51 patients provided 2 or more specimens. The patients who provided more than 1 specimen were those enrolled early in the study who, at different times, had either new onset of diarrhea (case patients) or a 3-month period without diarrhea (controls).

^aThe 2-tailed *P* value was calculated by the Fisher exact test.

^bThree patients had acute episodes of astrovirus-associated diarrhea on more than one occasion.

^cSRSVs, or Norwalk-like viruses, are considered to be members of the family Caliciviridae along with human caliciviruses. Taken together, the Caliciviridae were associated marginally with diarrhea (*P* = .062 for specimens, *P* = .115 for patients).

^dThe 2 patients without diarrhea who shed picobirnavirus at different times had picobirnavirus-associated diarrhea. Only in this category was a patient included as both a case patient and control.

^eThe total number of specimens with virus present as a single or mixed infection. Some patients were infected with more than one type of virus.

^fThe mixed infections consisted of 4 cases of adenovirus and astrovirus, 2 cases of calicivirus and coronavirus-like particle, and 1 case of adenovirus and coronavirus-like particle.

using in situ hybridization of biopsied specimens obtained from the rectum and duodenum, showed HIV-infected cells in both the base of the crypts and within the lamina propria. They postulated that the association of in situ labeling of HIV RNA in argentaffin cells strongly suggested that enterochromaffin cells derive from the neural crest tissue and may in fact be among the primary target cells of HIV. Along the same lines, Batman et al⁷ described jejunal enteropathy associated with HIV; the degree of villus atrophy in the jejunal mucosa was estimated using a Widal eye piece graticule. Jejunal villus enterocytes showed mild, nonspecific abnormalities with crypt hyperplasia recurring in all stages of HIV disease, even in the absence of pathogens. They suggested that the pathogenesis of villus atrophy was actually an immune reaction within the lamina propria against cells infected with HIV. Delezay et al⁸ reported the findings from an in vitro study on the differentiation of an epithelial cell clone HT-29-D4. They noted that HIV impaired cellular differentiation of both barrier function and sodium-glucose co-transport. In this epithelial cell line, HIV massively disrupted microtubules, revealed by α -tubulin indirect immunofluorescence staining. The investigators suggested that HIV perturbs intestinal function with or without infecting the epithelial cells themselves.

Once opportunistic disorders are excluded in patients with refractory diarrhea, HIV enteropathy can exist in a small but definite percentage of the population. Batman

et al⁹ have studied crypt, stem, and transit cell proliferation. In a study on the kinetics of stem and transit cell lines, they noted definite villus atrophy induced by both microsporidia and HIV itself. Both these infections provoke crypt cell hypertrophy, including encroachment of the crypt cells onto the villi by stimulating cell mitoses in both stem and transit cells. Dandekar¹⁰ clarified the pathogenesis of HIV disease in the GI tract, noting that the gut-associated lymphoid tissue (GALT) was clearly an early site of HIV replication and CD4+ T-cell depletion. Additional studies have supported that HIV destroys GALT in the early stages of HIV infection.¹¹ Initiation of HAART did not lead to complete suppression of viral replication and there was only partial restoration of CD4+ T-cells in the GALT, compared with the peripheral blood. It appeared that persistent HIV replication in GALT leads to crypt alterations and maintenance of the HIV reservoirs.

Knox et al¹² described the functional disruption of the GI tract caused by HIV in 2000. Among 671 patients with HIV infection, 39% had diarrhea; stool pathogens were identified in only 12% of these patients. Despite this, 48% of all patients had an abnormal D-xylose test, 22.5% had borderline or low serum B-12 levels, and 7.2% had a depressed albumin level. The investigators suggested that abnormalities of the GI tract are common even in the era of modern HAART, so the clinician therefore carefully must exclude identifiable pathogens, even in patients who are on HAART. Monkemuller et al¹³ noted that since

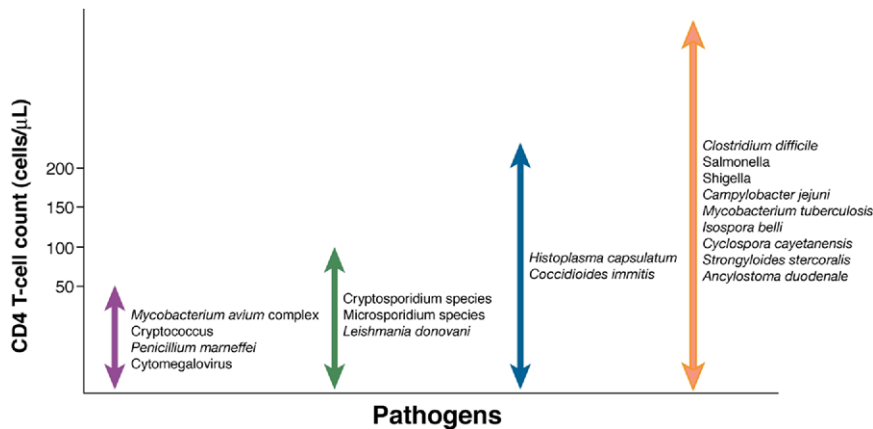


Figure 3. Association between gastrointestinal infections as a result of a specific pathogen and CD4+ T-cell count ranges in HIV-positive patients.

the widespread use of HAART, there has been a dramatic decrease in the prevalence of identifiable opportunistic infections of the GI tract, but that opportunistic infections still occurred. They examined a population of 294 patients treated with HAART; 88% of the patients were men, with a mean age of 36.5 years. In this study patients had a mean CD4+ T-cell count of 64 and a mean RNA viral load of 40,357 copies per mL. Despite all being treated with HAART, 9% of patients had identifiable opportunistic disorders of the GI tract. In careful questioning, however, they identified approximately 40% of these patients with new or persistent opportunistic disorders of the GI tract as being likely or definitely non-compliant with administered HAART. Thus, GI opportunistic disorders still can occur in HIV-positive patients, including those allegedly taking HAART and especially in those with low CD4+ T-cell counts and high HIV viral loads. Unfortunately, these opportunistic disorders still can occur in patients with near-normal CD4+ T-cell counts and low HIV viral loads.

Thus, HIV enteropathy is associated with increases in inflammation and immune activation and decreases in mucosal repair and regeneration—these all contribute to the presence of HIV enteropathy. In 2008, Sankaran et al¹¹ highlighted once again the importance of GALT as an early target for HIV infection and the site of severe CD4+ T-cell depletion. They noted that viral replication occurred very early in primary HIV infection in the GALT CD4+ T cells and macrophages. There was also a decrease in the expression levels of genes that regulate epithelial barrier maintenance and digestive metabolic function. These changes coincided with a decrease in transcription of immune activation, inflammation, and apoptosis-associated genes. Consequently, HIV infection in GALT occurs at both a molecular and a cellular level even before seroconversion.

Although HIV enteropathy encompasses an idiopathic, pathogen-negative diarrhea, there is an array of opportunistic infections (OIs) that invade the GI tracts of patients with advanced HIV. GI OIs include a complex milieu of bacteria, fungus, viruses, and protozoa that

typically exert their devastating effects when a patient's CD4+ T-cell count decreases to less than 200 cells/ μ L (Figure 3). The study of GI OIs has undergone an astonishing transformation over the past 25 years, and has been marked by periods of remarkable discovery and innovation in terms of identifying new pathogens and suitable treatments. Similar to the evolving treatment of these infections, the role of the gastroenterologist under these circumstances has changed over time as well. In many cases, a multidisciplinary approach among gastroenterology, infectious disease, HIV specialists, oncology, and surgery not only is encouraged, but in many cases is required for treating HIV patients with GI OIs.

The advent of HAART revolutionized the treatment of HIV and resulted in striking declines in HIV-related infections and associated mortality.¹⁴ In addition, HAART marked a sustained and continued decline in the incidence and prevalence of GI OIs.¹⁵ This dramatic decline was illustrated superbly by Monkemuller et al¹⁵ in a prospective study at the University of Alabama in Birmingham. In examining 166 AIDS patients undergoing dual endoscopy for GI complaints at 3 time periods in the 1990s (2-year intervals), they discovered the incidence of GI OIs decreased from a peak of 69% to a nadir of 13%, whereas at the same time HAART use in their patients increased from 37% to 87%. Several multifactor theories have been proposed to explain this decline of GI OIs. One is that the re-establishment of the patient's own natural immunity, with the repopulation of T cells in the enteric mucosa, combats various opportunistic pathogens that it previously could not fight. A second explanation may be the direct effect of the HAART regimen itself on specific pathogens. Within combinational HAART, protease inhibitors have been observed both in vivo and in vitro to have inhibitory properties on specific organisms via the degradation of aspartyl proteases.^{16,17} Regardless of the mechanism, HAART has had extraordinary success in treating HIV-associated GI OIs since its introduction.

The success of HAART spans across an entire assortment of GI OIs. For example, multiple studies uniformly have shown a decrease in the incidence of cryptospor-

ridium and microsporidium in response to HAART.^{18,19} Likewise, an influential 1998 study by Carr et al²⁰ discovered that HIV patients infected with *Cryptosporidium parvum* or *Enterocytozoon bieneusi* (most of which had failed previous antimicrobial therapy) had a full clinical, histologic, and microbiological response to HAART. In addition, a majority of patients remained symptom free for more than 1 year and those with recurrent symptoms had declining CD4+ T-cell counts. However, this interplay between HAART and the treatment of GI OIs is not limited to parasitic and fungal organisms. This story was unraveled eloquently in several studies on the treatment of patients with cytomegalovirus (CMV) infections. HIV patients on combination HAART consistently have greater rates of survival, compared with HAART-naive patients, even when adjusting for CMV therapy.²¹ Accordingly, the profound effect of HAART on treating GI OIs is unquestionable and should be front-line therapy for many GI OIs. Although the effects of HAART are compelling, some researchers have noted the occurrence of GI OIs despite the use of HAART.¹³ In this subset of patients, factors such as medication noncompliance, resistant strains of HIV, late initiation of HAART, or poor bioavailability of HAART all could have a role in its inability to always treat OIs. These situations underscore the need for continued targeted therapy of OIs in some circumstances despite the use of HAART (Table 3).

Treatment of OIs of the GI Tract

Although the rates of GI parasitic infections have declined over time, 3 pathogens (*Cryptosporidia*, *Isospora*, and *Cyclospora*) continue to contribute to the morbidity and mortality among AIDS patients with diarrhea. Of these, cryptosporidiosis has been a challenge to treat over the years. Its intracellular location within enterocytes and innate resistance has been responsible for this dilemma.^{22,23} Although HAART has reduced the incidence of cryptosporidiosis among HIV patients, leading to complete resolution of diarrhea and pathogen eradication on many occasions,^{20,24} unfortunately, in many parts of the world patient access to HAART is limited.

Over the years, 2 main therapies have emerged as potential treatments for cryptosporidiosis: nitazoxanide and paromomycin. However, clinical studies on both these agents have been limited by their small sample sizes, the lack of enrollment of patients with HIV, the small number of randomized controlled trials, and conflicting results. A 2007 Cochrane meta-analysis attempted to address and resolve these issues.²⁵ The meta-analysis of studies of nitazoxanide therapy compared with placebo indicated that nitazoxanide effectively cured the parasitic infection in patients overall, but the data for patients with HIV was not statistically significant; HIV patients tended to have less resolution of their diarrheal illness. Interestingly, the only 2 randomized studies that were included in this meta-analysis and that examined

nitazoxanide therapy in HIV patients had several striking differences. An initial study by Rossignol et al²⁶ in 1998 showed that HIV patients with cryptosporidial diarrhea and CD4+ T-cell counts of 50 cells/ μ L or more had a greater than 60% cure rate compared with placebo after 2 weeks of nitazoxanide therapy. Conversely, 3 years later, Amadi et al²⁷ examined children with AIDS and found that a short, 3-day course of nitazoxanide therapy resulted in reduced stool volume, increased fecal oocyte clearance, and improved mortality in HIV-negative children, but did not show similar results for HIV-positive children. One could argue that the treatment duration of 2 weeks compared with 3 days as well as the patient population (adult vs pediatric) makes comparing and drawing cohesive conclusions from these 2 studies challenging. Fueling this debate was a 2006 multicenter prospective evaluation of 365 AIDS patients with cryptosporidiosis treated with nitazoxanide. This has been the largest study to date on nitazoxanide therapy for HIV-related cryptosporidiosis and more than 94% of the study subjects were adults. This study showed that 59% of patients achieved a clinical response with culture-negative stool cultures while on nitazoxanide therapy and that patients with higher CD4+ T-cell counts were more likely to achieve a continued clinical response.²⁸ Further, larger randomized placebo-controlled trials with nitazoxanide therapy in HIV patients are warranted before definitive recommendations for treatment can be made; although current evidence appears to support the use of nitazoxanide in HIV adult patients for a prolonged course with a better response rate observed in patients with more robust cellular immunity.

Along the same lines, paromomycin has had equivocal results over time. Studies of paromomycin have included far fewer HIV patients compared with studies of nitazoxanide. The 2007 Cochrane meta-analysis showed a slight trend toward effective treatment using paromomycin, but the overall relative risks for decreased stool frequency and oocyte clearance were modest and not statistically significant.²⁵ Compared with randomized trials for nitazoxanide, paromomycin therapy had appreciably more disappointing and contradictory results. Hewitt et al²⁹ showed that paromomycin therapy did not result in more partial or complete clinical responses than placebo and concluded that paromomycin was ineffective in treating symptomatic cryptosporidial diarrheal disease. An earlier study by White et al³⁰ reported that paromomycin might result in some clinical improvements in patients with AIDS cryptosporidial diarrhea, but these improvements were short lived and associated with a high relapse rate, approaching 33% once therapy was discontinued. Unfortunately, there are no trials comparing paromomycin and nitazoxanide therapies directly. Thus, paromomycin might have some efficacy in treating symptomatic cryptosporidial diarrhea, but it appears to

Table 3. Specific Treatment Regimens for Gastrointestinal Opportunistic Infections in HIV-Infected Patients

Infection	Initial treatment	Alternative treatment(s)
Protozoa		
Cryptosporidia	Combination antiretroviral therapy	Nitazoxanide 500–1000 mg PO BID for 2 wk Paromomycin 25–35 mg/kg PO daily for 2 wk Paromomycin 1 g PO BID + Azithromycin 600 mg PO daily for 4 wk
<i>Cyclospora cayentanensis</i>	Trimethoprim/sulfamethoxazole 160/800 mg PO QID for 1 wk ^a	Ciprofloxacin 500 mg PO BID for 1 wk Nitazoxanide 500 mg PO BID for 3 days
<i>Isospora belli</i>	Trimethoprim/sulfamethoxazole 160/800 mg PO QID for 10 days ^a	Ciprofloxacin 500 mg PO BID for 1 wk Nitazoxanide 500 mg PO BID for 3 days Pyrimethamine 50–75 mg PO daily for 3–4 wk
Fungus		
Microsporidia		
<i>Encephalitozoon intestinalis</i>	Combination antiretroviral therapy + Albendazole 400 mg PO BID ^b	
<i>Enterocytozoon bieneusi</i>	Combination antiretroviral therapy	Fumagillin 60 mg PO daily for 2 wk ^c
<i>Histoplasma capsulatum</i>	Initial phase ^d : liposomal amphotericin B 3 mg/kg IV daily for 2 weeks Continuation phase ^e : itraconazole 200 mg PO TID for 3 days, then BID for 12 mo	Initial phase ^d : amphotericin B deoxycholate 0.7 mg/kg IV daily for 2 wk
Cryptococcus	Initial phase: Amphotericin B deoxycholate 0.7 mg/kg IV daily (or liposomal amphotericin B 4–6 mg/kg IV daily) + Flucytosine 25 mg/kg PO QID for 2 wk Continuation phase: Fluconazole 400 mg PO daily for 8 wk	Initial phase: Amphotericin B + Fluconazole 400 mg PO/IV daily for 2 wk Amphotericin B alone Fluconazole 400–800 mg PO/IV daily + Flucytosine 25 mg/kg PO QID for 4–6 wk Continuation phase: Itraconazole 200 mg PO BID for 8 wk
Virus		
CMV		
	Combination antiretroviral therapy + Ganciclovir 5 mg/kg IV BID for 3–6 wk OR Foscarnet 90 mg/kg IV BID for 3–6 wk	Valganciclovir 900 mg PO BID for 3–4 wk or until resolution of symptoms ^f
Bacteria		
MAC		
	Clarithromycin 500 mg PO BID + Ethambutol 15 mg/kg PO daily (± Rifabutin 300 mg PO daily)	See 2008 NIH/CDC/HIVMA/IDSA guidelines for alternative regimens and additional fourth drug options
<i>Mycobacterium tuberculosis</i>	Initial phase: Isoniazid 5 mg/kg PO daily + Rifampin 10 mg/kg PO daily (or Rifabutin 300 mg PO daily) + Pyrazinamide 15–30 mg/kg PO daily + Ethambutol 15–25 mg/kg PO daily for 2 mo Continuation phase: Isoniazid 5 mg/kg PO daily + Rifampin 10 mg/kg PO daily (or Rifabutin 300 mg PO daily) for 6 mo	See 2008 NIH/CDC/HIVMA/IDSA guidelines for alternative regimens, treatment for multidrug-resistant TB, patients with liver disease, and/or interactions with HAART
<i>Campylobacter jejuni</i>	Ciprofloxacin 500 mg PO BID for 1–2 wk ^g	Azithromycin 500 mg PO daily for 1–2 wk ^g
Salmonella	Ciprofloxacin 500–750 mg PO BID for 1–6 wk ^h	Trimethoprim/sulfamethoxazole 160/800 mg PO BID for 1–6 wk ^h
Shigella	Ciprofloxacin 500 mg PO BID for 1–2 wk ^g	Trimethoprim/sulfamethoxazole 160/800 mg PO BID for 1 wk Azithromycin 500 mg PO on day 1, then 250 mg PO daily for 4 days

BID, twice a day; CDC, Centers for Disease Control; HIVMA, HIV Medicine Association; IDSA, Infectious Diseases Society of America; NIH, National Institutes of Health; PO, per os (by mouth); QID, 4 times a day; TID, 3 times a day.

Modified from Table 2 of the 2008 Guidelines for Prevention and Treatment of Opportunistic Infections in HIV-Infected Adults and Adolescents.³⁷

^aMay require secondary prophylaxis with trimethoprim/sulfamethoxazole 160/800 mg PO three times weekly in patients with CD 4 T-cell counts <200 cells/ μ L.

^bContinue until CD4 T-cell count >200 cells/ μ L for more than 6 months after initiation of HAART.

^cCurrently not approved for use in the United States.

^dBegin with Amphotericin B for initial phase if infection is severely disseminated or patient is critically ill.

^eDrug regimen can be used for both the initial and continuation phases if disseminated disease is not severe.

^fCan be considered initial therapy if symptoms are not severe enough to interfere with oral absorption.

^gPatients with mild/moderate disease are treated for 1 week, and patients with bacteremia are treated for 2 weeks.

^hPatients with CD4 T-cell count \geq 200 cells/ μ L are treated for 1–2 weeks, and patients with CD4 T-cell count <200 cells/ μ L are treated for 2–6 weeks.

be less consistent than nitazoxanide and does not always lead to a sustained response.

A plethora of other agents have been studied for the treatment of HIV cryptosporidial diarrhea. Spiramycin, bovine dialyzable leukocyte extract, and bovine hyperimmune colostrums all have been investigated rigorously in randomized controlled clinical trials and also were included in the Cochrane meta-analysis.²⁵ All 3 drugs, when compared with placebo, were ineffective in either reducing stool volume or curing patients of the parasite infection. Clarithromycin, octreotide, and atovaquone all have been tried, with limited success.^{31,32} On the horizon, a combination of paromomycin plus azithromycin,³³ as well as using rifaximin^{23,34,35} alone, have shown encouraging results in improving symptoms and decreasing cryptosporidial oocyte excretion, especially in HIV patients refractory to other therapies. Thus, current evidence strongly supports the use of HAART (with a protease inhibitor as part of the regimen) as initial therapy for patients with cryptosporidiosis; HAART clearly has shown persistent clinical effects and the ability to cure parasite infections in many HIV-infected patients. For patients who continue to have severe diarrheal disease despite HAART and improved CD4+ T-cell function the addition of nitazoxanide therapy should be considered; however, nitazoxanide therapy alone is inappropriate without HAART.³⁶

The treatment options for isosporiasis are more definitive. The mainstay of therapy is trimethoprim/sulfamethoxazole (160/800 mg) orally 4 times a day for 10 days.³⁷ Given the high relapse rate of nearly 50%, this regimen usually is followed by secondary prophylaxis—especially in patients for whom HAART cannot be started or when CD4+ T-cell counts continue to remain less than 200 cells/ μ L. Although ciprofloxacin is less effective, when compared directly with trimethoprim/sulfamethoxazole, it does have a success rate greater than 70% in resolving symptoms and curing HIV patients of isosporiasis infection.³⁸ Alternative regimens for patients who cannot tolerate or have failed trimethoprim/sulfamethoxazole and/or ciprofloxacin include nitazoxanide or pyrimethamine.^{39,40}

Similarly, cyclosporiasis is treated with trimethoprim/sulfamethoxazole (160/800 mg) orally 4 times a day for 7 days with similar efficacy as isosporiasis.^{41,42} Again, secondary prophylaxis with trimethoprim/sulfamethoxazole may be necessary in patients not on HAART or with low CD4+ T-cell counts. Other less-effective regimens include ciprofloxacin and nitazoxanide.^{38,40}

Microsporidium, now reclassified as a fungus, has long been associated with infection of the small bowel in patients with advanced HIV. *Encephalitozoon intestinalis* and *Enterocytozoon bieneusi* are the 2 most prevalent species encountered in immunocompromised patients. Similar to the treatment of cryptosporidiosis, restoration of the patient's innate immune system with HAART is of paramount importance in

treating HIV patients who have microsporidium infections. HAART alone can result in a cessation of diarrhea, considerable weight gain in wasting patients, and a complete eradication of the organism, determined through microbiological and histologic analyses, in many patients.^{19,20,43} In addition to immune reconstitution, several therapies have evolved over time to treat microsporidium. Treatment for *Encephalitozoon intestinalis* has remained unchanged for the past several years and includes albendazole, a benzimidazole that inhibits tubulin polymerization. Albendazole therapy for *Encephalitozoon intestinalis* consistently results in complete organism eradication in HIV-positive patients.^{44,45}

In contrast, *Enterocytozoon bieneusi* has proven to be a more challenging and difficult entity to treat. Some success has been achieved with albendazole, although pathogen suppression is incomplete and inconsistent.⁴⁶ Fumagillin, an antibiotic with anti-angiogenic properties, showed encouraging results in early studies in improving HIV symptoms and fecal clearance of the organism.⁴⁷ Unfortunately, high rates of bone marrow toxicity have limited the use of this drug within the United States and it has never received Food and Drug Administration approval. Consequently, an analogue, TNP-470, was developed, but showed success only in in vivo and in vitro studies and has not made its way to human clinical trials for the treatment of *Enterocytozoon bieneusi*.⁴⁸ A host of other agents either have had limited success or disappointing results. Studies of these potential agents are limited by the fact that their efficacy was shown only in case reports or a small series of patients, or only in in vitro or in vivo studies. These therapies include nitazoxanide, atovaquone, itraconazole, metronidazole, octreotide, thalidomide, and trimethoprim/sulfamethoxazole.⁴³ Overall, once the diagnosis of microsporidium is confirmed, treatment should begin promptly with combination HAART as well as electrolyte replacement and symptom management. *Encephalitozoon intestinalis* can be treated successfully with albendazole, although at the moment there is no available effective therapy in the United States for *Enterocytozoon bieneusi*.

There are an array of other fungal organisms that can infect the GI tract and cause severe morbidity and mortality. These organisms usually are rare, geographically distinct, and mostly occur when disease is disseminated. Fungal OIs that may be encountered in the United States include histoplasmosis and cryptococcosis. In many cases, GI signs and symptoms are obscured by widespread infection (usually of the pulmonary or central nervous systems); it is unusual for these infections to be localized specifically to the GI tract, although this has been reported.^{49,50} Given the strong interaction between systemic disease and GI involvement, the mainstay of therapy for these infections focuses on treatment for disseminated disease. GI and systemic infections are similar in that they are treated originally with an induction phase to control clinical signs followed by a prolonged maintenance phase for relapse prevention. Commonly, am-

photicin B (either the deoxycholate or liposomal formulation) is used in the induction phase followed by maintenance therapy either with fluconazole or itraconazole. Long-term maintenance therapy could be required for patients not on HAART or with persistently low CD4⁺ T-cell counts. Lastly, it is important to treat GI OIs by restoring the patient's immune system with HAART.

Viral Pathogens of the GI Tract

Several viruses have been implicated in HIV esophagitis/enteritis/colitis over the years, most notably CMV. The vast majority of patients with viral pathogens that infect the GI tract are treated with HAART as well as supportive care for electrolyte imbalances and symptom control. However, CMV GI disease has proven to be a unique challenge compared with other viruses. Nearly 15% of CMV infections occur in the GI tract⁵¹ and the prevalence of CMV colitis in HIV patients with diarrhea ranges from 13% to 45%.^{52,53} Although there are some data available on the treatment of CMV GI disease, the vast majority of studies have focused on CMV retinitis; treatment recommendations for CMV GI disease have come from these studies. It is important to treat CMV promptly, given its poor prognosis and high rates of recurrence.

Treatment for CMV infection of the GI tract should commence with either ganciclovir or foscarnet for 3–6 weeks. This time frame for therapy can vary and patients should be monitored for signs of clinical improvement to determine the length of treatment time required. Clinical trials support the use of either ganciclovir or foscarnet as initial treatment^{54,55}; an open, randomized study of patients with CMV GI disease treated with either foscarnet or ganciclovir showed that either drug led to similar improvements in clinical symptoms, resolution of endoscopic findings, and disappearance of inclusion bodies on biopsy.⁵⁶ Although a subsequent maintenance regimen is required therapy for CMV retinitis, there is debate about continued maintenance therapy for patients with GI CMV. Relapse rates of 9 weeks to 1 year for CMV GI tract disease have been reported fueling this controversy, but limited studies have shown no benefit for maintenance therapy.⁵⁶ Maintenance therapy is considered if patients continue to have symptoms despite a complete course of therapy or if a patient has recurring disease. The need for maintenance therapy may be negated with the introduction of HAART to the patient's medication regimen. AIDS patients with CMV retinitis on HAART have been shown to have fewer relapses, continued CMV viral suppression, and in most cases have been able to discontinue maintenance therapy completely.⁵⁷ All of these factors, coupled with improved survival, point to HAART's integral position in the treatment of CMV infection of the GI tract. The appropriate time for initiating HAART in patients with GI CMV disease is a source of controversy. Unfortunately, there are limited data available on this

subject. Given the theoretical risk of developing immune reconstitution syndrome many clinicians advocate delaying HAART until the acute symptoms of disease resolve with CMV therapy. Conversely, some clinicians argue that starting HAART alone in patients with mild to moderate CMV GI disease is a safe and reasonable first step rather than initially starting with directed CMV therapy. Once again, data on this therapeutic strategy are lacking.³⁷ The timing of HAART and/or CMV therapy should be made after careful consideration of the patient's clinical status as well as communicating with the patient's primary HIV physician about potential HAART initiation.

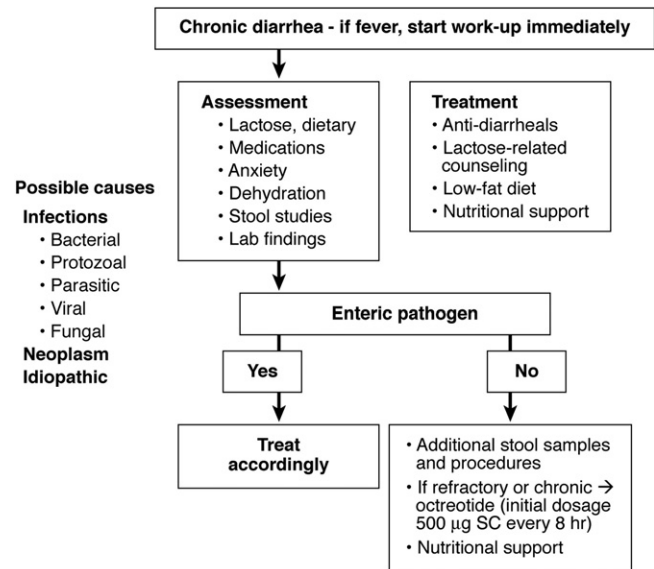
In the past several years, oral valganciclovir has appeared as an attractive regimen in place of the intravenous forms of ganciclovir and foscarnet. Currently, no randomized controlled trials comparing valganciclovir with either ganciclovir or foscarnet for treatment of CMV GI disease have been performed. Encouraging evidence for the treatment of CMV retinitis⁵⁸ and CMV disease in solid organ transplantation⁵⁹ has prompted some physicians to consider using it as initial therapy. Given this indirect evidence some societies have recommended the use of oral valganciclovir for therapy unless symptoms prevent a patient from taking oral medications and/or if symptoms are severe enough to result in intestinal malabsorption and thus decrease drug bioavailability.³⁷ Lastly, there are limited data on approaches to patients with treatment failures for GI CMV; again, the majority of studies on this topic deal with CMV retinitis. Potential options include beginning chronic maintenance therapy with the initial drug used or valganciclovir, optimizing HAART to ensure adequate restoration of cellular immunity, changing to an alternative drug that was not used in the initial regimen, and as a last resort using combination therapy of ganciclovir and foscarnet.^{37,60}

There are numerous bacterial infections that occur more frequently and with a more virulent pattern in HIV patients. These include Salmonella, Shigella, *Campylobacter jejuni*, and, in the age of HIV prophylaxis and widespread use of antibiotics, *Clostridium difficile*. In fact, *C difficile*-associated diarrhea now ranks as the most common bacterial infection observed in HIV patients with diarrhea.⁶¹ However, in the realm of GI OIs, mycobacterial diseases, specifically *Mycobacterium avium* complex (MAC) and *Mycobacterium tuberculosis* (TB), have a predominant role.

An HIV-infected patient with GI MAC usually has disseminated disease, a very low CD4⁺ T-cell count, and a limited survival time. With the introduction of HAART as well as prophylaxis, the incidence and prevalence of disseminated MAC has decreased.⁶² Over the years, MAC treatment has evolved into a multidrug course of antibiotics with a prolonged, and at times indefinite, period of therapy. Initial, first-line treatment for MAC consists of 2 antibiotics: clarithromycin and ethambutol. Each agent

alone has high rates of drug resistance, whereas a combination of the 2 results in complete microbiologic response, lower relapse rates, improved clinical symptoms, and overall better survival.^{63,64} The addition of a third agent, rifabutin, has shown increased survival times, with the added benefit of less resistance and also can be added to the earlier-described treatment armamentarium.⁶⁵ Lastly, the 2008 National Institutes of Health/Centers for Disease Control/HIV Medicine Association of the Infectious Diseases Society of America guidelines recommend the addition of either injectable amikacin or streptomycin to therapy for patients at high risk of death from MAC, which include patients with CD4+ T-cell counts of 50 cells/ μ L or less, high mycobacterial loads, or in the absence of HAART.³⁷ Unfortunately, MAC treatment is lifelong or until immune function has improved with HAART. Many clinicians and societies advocate delaying the initiation of HAART (in a patient who is HAART-naive) until a few weeks after MAC therapy has begun. The goal in delaying HAART therapy is several-fold and includes reducing drug interactions, increasing medication compliance, and avoiding complications of the immune reconstitution syndrome (for a more thorough review of the immune reconstitution syndrome and its role in MAC therapy as well as other opportunistic infections please see the 2008 National Institutes of Health/Centers for Disease Control/HIV Medicine Association/Infectious Diseases Society of America TB treatment guidelines for OI infections).^{37,66,67} Lastly, newer adjuvant regimens consisting of interferon- γ injections in pulmonary MAC patients have had promising results. The addition of interferon- γ results in higher response rates, earlier improvement in symptoms, and significantly less disease-related deaths compared with the current standard of care.⁶⁸ Unfortunately, there have not been any clinical trials to test the effects of interferon- γ in patients with disseminated MAC.

TB of the GI tract can affect both the immunocompromised and immunocompetent patient. GI TB accounts for 1%–3% of all TB cases worldwide, but represents less than 1% of all TB cases in the United States.⁶⁹ Commonly found in the region of the ileocecal valve, TB of the GI tract can be found almost anywhere, coexists 50% of the time with pulmonary TB, and mimics a variety of other infectious and inflammatory conditions of the GI tract.⁷⁰ The treatment of intestinal TB is similar to that of pulmonary and other extrapulmonary forms of TB in terms of the regimen used, testing for drug susceptibility, and ensuring complete patient adherence to the treatment regimen. Although there have been only a few studies on abdominal TB treatment, they have confirmed that a multidrug regimen for a minimum of 6 months is effective therapy in terms of a microbiological and clinical response.^{71,72} The current recommended regimen for HIV-positive patients consists of ethambutol, rifampin (or rifabutin), isoniazid, and pyrazinamide for a 2-month initiation phase followed by a



Adapted from Cello JP. *Adv Gastroenterol Hepatol Clin Nutr.* 1997;2:1-9.

Figure 4. Proposed treatment algorithm for patients with AIDS and chronic diarrhea.

4-month continuation phase with isoniazid and rifampin (or rifabutin).^{37,73} The duration of therapy can vary in HIV patients, depending on the functionality of their immune system, drug susceptibility, and improvement in clinical symptoms. Although surgery was common in the past, today it is reserved for patients with complications that do not respond to medical therapy and include obstruction, strictures, abscesses, and perforations. Other alternative regimens and medications have been studied and proposed for patients with medication intolerance, drug susceptibility, HAART-TB drug interactions, initiation of HAART, treatment failure regimens, and recurrence of disease (see the 2008 National Institutes of Health/Centers for Disease Control/HIV Medicine Association/Infectious Diseases Society of America TB treatment guidelines for a more comprehensive discussion).³⁷

Nonspecific Treatments for AIDS-Related Diarrhea

What can we offer patients with AIDS-associated diarrhea when all specific targeted therapies have been exhausted? Wilcox and Saag⁷⁴ have shown that HAART can suppress patients' viral load to an undetectable range and stop further destruction of CD4+ T lymphocytes. The course of diarrheal disease is reversed dramatically in most, but not all, patients who are compliant with treatment. However, for many patients, HAART does not reverse the course of the diarrhea and a systematic reasonable algorithm should be undertaken (Figure 4).

Many patients with AIDS-related diarrhea are severely malnourished and/or have recurrent dehydration. Elemental diets are sometimes helpful, particularly those that contain medium-chain triglycerides. The use of short-term hy-

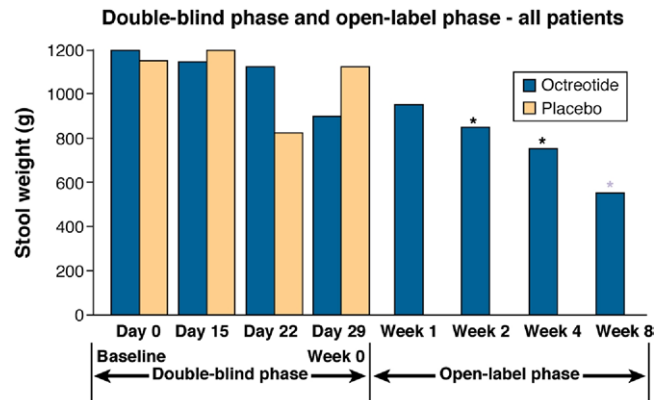
peralimentation, whether by alimentary or intravenous routes, may be needed early in treatment programs regardless of initiation of HAART. Occasionally, multivitamin and mineral deficiencies are detected and likewise need to be corrected by proper supplementation.

A careful analysis of stool samples is an essential and obligatory first diagnostic step. If an enteric pathogen is isolated, the patient should be treated as appropriately as possible with available agents, as outlined earlier (Table 3). If after exhaustive stool studies no pathogen is isolated, and no other factors are believed to be contributing to the diarrheal disease, then there is clearly a role for additional, invasive endoscopic evaluations, particularly in those patients who have very severe refractory, dehydrating diarrhea. The decision to perform a complete GI evaluation, consisting of upper endoscopy, small-bowel biopsies, and colonoscopy with biopsies, must be made in conjunction with the patient and their primary care providers. Given the innumerable endoscopic modalities available in gastroenterology and the sophistication of most pathology laboratories, there is little reason to avoid or refuse invasive diagnostic testing in patients who could benefit from targeted therapy.

Surprisingly, but rarely, patients with profound watery diarrhea and malnutrition will be found to be ingesting agents, either inadvertently or surreptitiously, that are associated with diarrhea. These cathartics include lactose, sorbitol, mannitol, or even over-the-counter cathartics in their diet. These agents clearly should be considered, proscribed, and their intake must be eliminated. Also, it is worthwhile to extensively review a patient's HAART regimen because many HAART medications, and in particular the protease inhibitors such as nelfinavir, fosamprenavir, and ritonavir, are well known to cause diarrhea.

Antimotility agents (loperamide, diphenoxylate, codeine) and adsorbents (bismuth subsalicylate and kaolin/pectin) are widely available, generally attempted, and somewhat helpful in treating mild to moderate diarrhea.⁷⁵ The GI antimotility agents are universally opioids, which decrease stool output by decreasing GI motility and increase transit time, thus generally promoting fluid and electrolyte absorption.⁷⁵ These antimotility and adsorbent drugs are all reasonably helpful in patients with mild to moderate pathogen-negative diarrhea. There is insufficient evidence to support the routine use of probiotics and/or herbal remedies in AIDS patients with severe diarrhea.⁷⁶ Most patients will have tried several or all of the agents described earlier before seeking medical attention. Additional nonstandard therapies run the gamut of nonsteroidal anti-inflammatory drugs, clonidine, tincture of opium, and octreotide.

Many clinical studies have evaluated octreotide in patients with AIDS-related diarrhea.^{77,78} These studies have ranged in size from 4 to 125 patients. The overall clinical response rates to subcutaneous octreotide range from 25% to 40% in most studies. In our study of 129 patients



*Significant difference from baseline ($P < .001$).

Simon DM, Cello JP, Valenzuela J, et al. *Gastroenterology*. 1995;108:1753-1760.

Figure 5. Change in stool weight of patients with AIDS and refractory diarrhea using octreotide vs placebo in a double-blind phase and open-label phase clinical trial. Reprinted with permission from Simon et al.⁷⁸

who had extensive investigations of their refractory diarrhea, one third of patients ultimately were found to have *Cryptosporidium* infections, again highlighting how important this organism is in the development of refractory diarrhea. Nearly one third of the patients in this study had true idiopathic diarrhea in which no pathogen was identified by stool studies or by endoscopic examination. In a double-blind, placebo-controlled trial, patients were assigned randomly to groups that were given octreotide 100 mcg, 200 mcg, or 300 mcg, or placebo 3 times a day. At the end of the trial, there were arithmetic, but not statistically significant, differences between the groups. Patients with idiopathic diarrhea appeared to fare better than those with an identifiable pathogen, although the difference was not statistically significant. In patients who were given octreotide, 45% had achieved control of their diarrheal symptoms, compared with 33% of the placebo group. Nor was there a significant difference between groups with respect to stool frequency during the double-blind phase. When the trial was extended to 8 weeks during an open-label phase (Figure 5), there was a significant reduction in stool weight between weeks 1 and 8. With respect to stool frequency, there was no difference observed between the groups given octreotide and those given placebo during the controlled trial, but when the trial was extended during the open-label phase, and the patient data were compared with their own baseline statistics, there was a significant decrease in stool frequency.⁷⁸

In conclusion, refractory diarrhea is a complex problem among patients with HIV disease. Investigations should occur early in the disease course and include a careful medical history and physical examination, as well as stool studies, basic laboratory analyses of infection, nutritional status, and electrolyte derangements, and potentially more-invasive endoscopic and radiographic evaluations. The etiology of AIDS refrac-

tory diarrhea is vast and can encompass the same spectrum of chronic diarrheal diseases that inflict non-HIV-infected patients as well as other etiologies such as infections and medications that are specific to HIV or immunocompromised patients. An interesting entity known as AIDS enteropathy has emerged and evolved over the years and reflects an idiopathic, pathogen-negative diarrhea whose underlying cause might involve undiscovered infectious pathogen(s), inflammatory changes within the GI tract caused by HIV or other environmental/infectious agents, HIV itself, or a complex interplay among any one of these etiologies. AIDS refractory diarrhea can pose diagnostic and treatment challenges. HAART, nutritional supplementation, electrolyte replacements, targeted therapy for specific infections, and alleviation of symptoms are all key elements in the treatment regimen for these patients. The overall care of these challenging patients, from diagnosis to treatment, also involves effective communication and teamwork among a variety of medical and surgical specialties.

References

- Serwadda D, Mugerwa RD, Sewankambo NK, et al. Slim disease: a new disease in Uganda and its association with HTLV-III infection. *Lancet* 1985;2:849–852.
- Kearney DJ, Steuerwald M, Koch J, et al. A prospective study of endoscopy in HIV-associated diarrhea. *Am J Gastroenterol* 1999; 94:596–602.
- Kotler DP, Scholes JV, Tierney AR. Intestinal plasma cell alterations in acquired immunodeficiency syndrome. *Dig Dis Sci* 1987;32:129–138.
- Cunningham AL, Grohman GS, Harkness J, et al. Gastrointestinal viral infections in homosexual men who were symptomatic and seropositive for human immunodeficiency virus. *J Infect Dis* 1988;158:386–391.
- Grohmann GS, Glass RI, Pereira HG, et al. Enteric viruses and diarrhea in HIV-infected patients. Enteric Opportunistic Infections Working Group. *N Engl J Med* 1993;329:14–20.
- Nelson JA, Wiley CA, Reynolds-Kohler C, et al. Human immunodeficiency virus detected in bowel epithelium from patients with gastrointestinal symptoms. *Lancet* 1988;1:259–262.
- Batman PA, Miller AR, Forster SM, et al. Jejunal enteropathy associated with human immunodeficiency virus infection: quantitative histology. *J Clin Pathol* 1989;42:275–281.
- Delezay O, Yahi N, Tamalet C, et al. Direct effect of type 1 human immunodeficiency virus (HIV-1) on intestinal epithelial cell differentiation: relationship to HIV-1 enteropathy. *Virology* 1997;238: 231–242.
- Batman PA, Kotler DP, Kapembwa MS, et al. HIV enteropathy: crypt stem and transit cell hyperproliferation induces villous atrophy in HIV/Microsporidia-infected jejunal mucosa. *AIDS* 2007; 21:433–439.
- Dandekar S. Pathogenesis of HIV in the gastrointestinal tract. *Curr HIV/AIDS Rep* 2007;4:10–15.
- Sankaran S, George MD, Reay E, et al. Rapid onset of intestinal epithelial barrier dysfunction in primary human immunodeficiency virus infection is driven by an imbalance between immune response and mucosal repair and regeneration. *J Virol* 2008;82: 538–545.
- Knox TA, Spiegelman D, Skinner SC, et al. Diarrhea and abnormalities of gastrointestinal function in a cohort of men and women with HIV infection. *Am J Gastroenterol* 2000;95: 3482–3489.
- Monkemuller KE, Lazenby AJ, Lee DH, et al. Occurrence of gastrointestinal opportunistic disorders in AIDS despite the use of highly active antiretroviral therapy. *Dig Dis Sci* 2005;50:230–234.
- d'Arminio Monforte A, Sabin CA, Phillips A, et al. The changing incidence of AIDS events in patients receiving highly active antiretroviral therapy. *Arch Intern Med* 2005;165:416–423.
- Monkemuller KE, Call SA, Lazenby AJ, et al. Declining prevalence of opportunistic gastrointestinal disease in the era of combination antiretroviral therapy. *Am J Gastroenterol* 2000;95:457–462.
- Hommer V, Eichholz J, Petry F. Effect of antiretroviral protease inhibitors alone, and in combination with paromomycin, on the excystation, invasion and in vitro development of *Cryptosporidium parvum*. *J Antimicrob Chemother* 2003;52:359–364.
- Pozio E, Morales MA. The impact of HIV-protease inhibitors on opportunistic parasites. *Trends Parasitol* 2005;21:58–63.
- Maggi P, Larocca AM, Ladisa N, et al. Opportunistic parasitic infections of the intestinal tract in the era of highly active antiretroviral therapy: is the CD4(+) count so important? *Clin Infect Dis* 2001;33:1609–1611.
- Miao YM, Awad-El-Kariem FM, Franzen C, et al. Eradication of cryptosporidia and microsporidia following successful antiretroviral therapy. *J Acquir Immune Defic Syndr* 2000;25:124–129.
- Carr A, Marriott D, Field A, et al. Treatment of HIV-1-associated microsporidiosis and cryptosporidiosis with combination antiretroviral therapy. *Lancet* 1998;351:256–261.
- Sungkanuparph S, Chakriyanuyok T, Butthum B. Antiretroviral therapy in AIDS patients with CMV disease: impact on the survival and long-term treatment outcome. *J Infect* 2008;56:40–43.
- Deng M, Rutherford MS, Abrahamsen MS. Host intestinal epithelial response to *Cryptosporidium parvum*. *Adv Drug Deliv Rev* 2004;56:869–884.
- Smith HV, Corcoran GD. New drugs and treatment for cryptosporidiosis. *Curr Opin Infect Dis* 2004;17:557–564.
- Le Moing V, Bissuel F, Costagliola D, et al. Decreased prevalence of intestinal cryptosporidiosis in HIV-infected patients concomitant to the widespread use of protease inhibitors. *AIDS* 1998; 12:1395–1397.
- Abubakar I, Aliyu SH, Arumugam C, et al. Prevention and treatment of cryptosporidiosis in immunocompromised patients. *Cochrane Database Syst Rev* 2007;1:CD004932.
- Rosignol JF, Hidalgo H, Feregrino M, et al. A double-blind placebo-controlled study of nitazoxanide in the treatment of cryptosporidial diarrhoea in AIDS patients in Mexico. *Trans R Soc Trop Med Hyg* 1998;92:663–666.
- Amadi B, Mwiya M, Musuku J, et al. Effect of nitazoxanide on morbidity and mortality in Zambian children with cryptosporidiosis: a randomised controlled trial. *Lancet* 2002;360:1375–1380.
- Rosignol JF. Nitazoxanide in the treatment of acquired immune deficiency syndrome-related cryptosporidiosis: results of the United States compassionate use program in 365 patients. *Aliment Pharmacol Ther* 2006;24:887–894.
- Hewitt RG, Yiannoutsos CT, Higgs ES, et al. Paromomycin: no more effective than placebo for treatment of cryptosporidiosis in patients with advanced human immunodeficiency virus infection. *AIDS Clinical Trial Group. Clin Infect Dis* 2000;31:1084–1092.
- White AC Jr, Chappell CL, Hayat CS, et al. Paromomycin for cryptosporidiosis in AIDS: a prospective, double-blind trial. *J Infect Dis* 1994;170:419–424.
- Griffiths JK. Treatment for AIDS-associated cryptosporidiosis. *J Infect Dis* 1998;178:915–916.
- Hoepelman AI. Current therapeutic approaches to cryptosporidiosis in immunocompromised patients. *J Antimicrob Chemother* 1996;37:871–880.

33. Smith NH, Cron S, Valdez LM, et al. Combination drug therapy for cryptosporidiosis in AIDS. *J Infect Dis* 1998;178:900–903.
34. Gathe JC Jr, Mayberry C, Clemmons J, et al. Resolution of severe cryptosporidial diarrhea with rifaximin in patients with AIDS. *J Acquir Immune Defic Syndr* 2008;48:363–364.
35. Jiang ZD, DuPont HL. Rifaximin: in vitro and in vivo antibacterial activity—a review. *Chemotherapy* 2005;51(Suppl 1):67–72.
36. Huang DB, White AC. An updated review on *Cryptosporidium* and *Giardia*. *Gastroenterol Clin North Am* 2006;35:291–314, viii.
37. Adult Prevention and Treatment of Opportunistic Infections Guidelines Working Group. Guidelines for prevention and treatment of opportunistic infections in HIV-infected adults and adolescents [draft]. June 18, 2008:1–289. Available at: http://aidsinfo.nih.gov/contentfiles/Adult_OI.pdf. Accessed: October 25, 2008.
38. Verdier RI, Fitzgerald DW, Johnson WD Jr, et al. Trimethoprim-sulfamethoxazole compared with ciprofloxacin for treatment and prophylaxis of *Isospora belli* and *Cyclospora cayentanensis* infection in HIV-infected patients. A randomized, controlled trial. *Ann Intern Med* 2000;132:885–888.
39. Farthing MJ. Treatment options for the eradication of intestinal protozoa. *Nat Clin Pract Gastroenterol Hepatol* 2006;3:436–445.
40. Lewthwaite P, Gill GV, Hart CA, et al. Gastrointestinal parasites in the immunocompromised. *Curr Opin Infect Dis* 2005;18:427–435.
41. Hoge CW, Shlim DR, Ghimire M, et al. Placebo-controlled trial of co-trimoxazole for *Cyclospora* infections among travellers and foreign residents in Nepal. *Lancet* 1995;345:691–693.
42. Pape JW, Verdier RI, Boncy M, et al. *Cyclospora* infection in adults infected with HIV. Clinical manifestations, treatment, and prophylaxis. *Ann Intern Med* 1994;121:654–657.
43. Contreas CN, Berlin OG, Ash LR, et al. Therapy for human gastrointestinal microsporidiosis. *Am J Trop Med Hyg* 2000;63:121–127.
44. MacDonald LM, Armson A, Thompson AR, et al. Characterisation of benzimidazole binding with recombinant tubulin from *Giardia duodenalis*, *Encephalitozoon intestinalis*, and *Cryptosporidium parvum*. *Mol Biochem Parasitol* 2004;138:89–96.
45. Molina JM, Chastang C, Goguel J, et al. Albendazole for treatment and prophylaxis of microsporidiosis due to *Encephalitozoon intestinalis* in patients with AIDS: a randomized double-blind controlled trial. *J Infect Dis* 1998;177:1373–1377.
46. Tremoulet AH, Avila-Aguero ML, Paris MM, et al. Albendazole therapy for *Microsporidium* diarrhea in immunocompetent Costa Rican children. *Pediatr Infect Dis J* 2004;23:915–918.
47. Molina JM, Tourneur M, Sarfati C, et al. Fumagillin treatment of intestinal microsporidiosis. *N Engl J Med* 2002;346:1963–1969.
48. Coyle C, Kent M, Tanowitz HB, et al. TNP-470 is an effective antimicrosporidial agent. *J Infect Dis* 1998;177:515–518.
49. Martin Relloso MJ, Sanchez-Fayos P, Gonzalez Guirado A, et al. Colonic histoplasmosis in AIDS. *Endoscopy* 2005;37:1036.
50. Washington K, Gottfried MR, Wilson ML. Gastrointestinal cryptosporidiosis. *Mod Pathol* 1991;4:707–711.
51. Yust I, Fox Z, Burke M, et al. Retinal and extraocular cytomegalovirus end-organ disease in HIV-infected patients in Europe: a EuroSIDA study, 1994–2001. *Eur J Clin Microbiol Infect Dis* 2004;23:550–559.
52. Marques O Jr, Averbach M, Zanoni EC, et al. Cytomegaloviral colitis in HIV positive patients: endoscopic findings. *Arq Gastroenterol* 2007;44:315–319.
53. Mentec H, Leport C, Leport J, et al. Cytomegalovirus colitis in HIV-1-infected patients: a prospective research in 55 patients. *AIDS* 1994;8:461–467.
54. Dieterich DT, Kotler DP, Busch DF, et al. Ganciclovir treatment of cytomegalovirus colitis in AIDS: a randomized, double-blind, placebo-controlled multicenter study. *J Infect Dis* 1993;167:278–282.
55. Nelson MR, Connolly GM, Hawkins DA, et al. Foscarnet in the treatment of cytomegalovirus infection of the esophagus and colon in patients with the acquired immune deficiency syndrome. *Am J Gastroenterol* 1991;86:876–881.
56. Blanshard C, Benhamou Y, Dohin E, et al. Treatment of AIDS-associated gastrointestinal cytomegalovirus infection with foscarnet and ganciclovir: a randomized comparison. *J Infect Dis* 1995;172:622–628.
57. Tural C, Romeu J, Sirera G, et al. Long-lasting remission of cytomegalovirus retinitis without maintenance therapy in human immunodeficiency virus-infected patients. *J Infect Dis* 1998;177:1080–1083.
58. Martin DF, Sierra-Madero J, Walmsley S, et al. A controlled trial of valganciclovir as induction therapy for cytomegalovirus retinitis. *N Engl J Med* 2002;346:1119–1126.
59. Len O, Gavalda J, Aguado JM, et al. Valganciclovir as treatment for cytomegalovirus disease in solid organ transplant recipients. *Clin Infect Dis* 2008;46:20–27.
60. Dieterich DT, Poles MA, Lew EA, et al. Concurrent use of ganciclovir and foscarnet to treat cytomegalovirus infection in AIDS patients. *J Infect Dis* 1993;167:1184–1188.
61. Sanchez TH, Brooks JT, Sullivan PS, et al. Bacterial diarrhea in persons with HIV infection, United States, 1992–2002. *Clin Infect Dis* 2005;41:1621–1627.
62. Karakousis PC, Moore RD, Chaisson RE. *Mycobacterium avium* complex in patients with HIV infection in the era of highly active antiretroviral therapy. *Lancet Infect Dis* 2004;4:557–565.
63. Chaisson RE, Keiser P, Pierce M, et al. Clarithromycin and ethambutol with or without clofazimine for the treatment of bacteremic *Mycobacterium avium* complex disease in patients with HIV infection. *AIDS* 1997;11:311–317.
64. Dube MP, Sattler FR, Torriani FJ, et al. A randomized evaluation of ethambutol for prevention of relapse and drug resistance during treatment of *Mycobacterium avium* complex bacteremia with clarithromycin-based combination therapy. California Collaborative Treatment Group. *J Infect Dis* 1997;176:1225–1232.
65. Benson CA, Williams PL, Currier JS, et al. A prospective, randomized trial examining the efficacy and safety of clarithromycin in combination with ethambutol, rifabutin, or both for the treatment of disseminated *Mycobacterium avium* complex disease in persons with acquired immunodeficiency syndrome. *Clin Infect Dis* 2003;37:1234–1243.
66. Horsburgh CR Jr, Gettings J, Alexander LN, et al. Disseminated *Mycobacterium avium* complex disease among patients infected with human immunodeficiency virus, 1985–2000. *Clin Infect Dis* 2001;33:1938–1943.
67. Kirk O, Reiss P, Uberti-Foppa C, et al. Safe interruption of maintenance therapy against previous infection with four common HIV-associated opportunistic pathogens during potent antiretroviral therapy. *Ann Intern Med* 2002;137:239–250.
68. Milanes-Virelles MT, Garcia-Garcia I, Santos-Herrera Y, et al. Adjuvant interferon gamma in patients with pulmonary atypical *Mycobacteriosis*: a randomized, double-blind, placebo-controlled study. *BMC Infect Dis* 2008;8:17.
69. Rasheed S, Zinicola R, Watson D, et al. Intra-abdominal and gastrointestinal tuberculosis. *Colorectal Dis* 2007;9:773–783.
70. Horvath KD, Whelan RL. Intestinal tuberculosis: return of an old disease. *Am J Gastroenterol* 1998;93:692–696.
71. Balasubramanian R, Nagarajan M, Balambal R, et al. Randomised controlled clinical trial of short course chemotherapy in abdominal tuberculosis: a five-year report. *Int J Tuberc Lung Dis* 1997;1:44–51.
72. Kapoor VK. Abdominal tuberculosis. *Postgrad Med J* 1998;74:459–467.

73. Blumberg HM, Burman WJ, Chaisson RE, et al. American Thoracic Society/Centers for Disease Control and Prevention/Infectious Diseases Society of America: treatment of tuberculosis. *Am J Respir Crit Care Med* 2003;167:603–662.
74. Wilcox CM, Saag MS. Gastrointestinal complications of HIV infection: changing priorities in the HAART era. *Gut* 2008;57:861–870.
75. Nwachukwu CE, Okebe JU. Antimotility agents for chronic diarrhoea in people with HIV/AIDS. *Cochrane Database Syst Rev* 2008;4:CD005644.
76. Liu JP, Manheimer E, Yang M. Herbal medicines for treating HIV infection and AIDS. *Cochrane Database Syst Rev* 2005;3:CD003937.
77. Cello JP, Grendell JH, Basuk P, et al. Effect of octreotide on refractory AIDS-associated diarrhea. A prospective, multicenter clinical trial. *Ann Intern Med* 1991;115:705–710.
78. Simon DM, Cello JP, Valenzuela J, et al. Multicenter trial of octreotide in patients with refractory acquired immunodeficiency syndrome-associated diarrhea. *Gastroenterology* 1995;108:1753–1760.
79. Greenson JK, Belitsos PC, Yardley JH, et al. AIDS enteropathy: occult enteric infections and duodenal mucosal alterations in chronic diarrhea. *Ann Intern Med* 1991;114:366–372.

Received October 30, 2008. Accepted December 22, 2008.

Reprint requests

Address requests for reprints to: John P. Cello, MD, 3D-GI Unit, San Francisco General Hospital, 1001 Potrero Avenue, San Francisco, California 94110. e-mail: john.cello@ucsf.edu.

Conflicts of interest

The authors disclose no conflicts.