

UC Davis

UC Davis Previously Published Works

Title

Small cell carcinoma of the ovary, hypercalcemic type, displays frequent inactivating germline and somatic mutations in SMARCA4

Permalink

<https://escholarship.org/uc/item/95j0m3tn>

Journal

Nature Genetics, 46(5)

ISSN

1061-4036

Authors

Ramos, Pilar
Karnezis, Anthony N
Craig, David W
et al.

Publication Date

2014-05-01

DOI

10.1038/ng.2928

Peer reviewed

Published in final edited form as:

Nat Genet. 2014 May ; 46(5): 427–429. doi:10.1038/ng.2928.

Small cell carcinoma of the ovary, hypercalcemic type, displays frequent inactivating germline and somatic mutations in *SMARCA4*

Pilar Ramos^{1,2,15}, Anthony N Karnezis^{3,4,15}, David W Craig¹, Aleksandar Sekulic^{1,5}, Megan L Russell¹, William P D Hendricks¹, Jason J Corneveaux¹, Michael T Barrett¹, Karey Shumansky⁶, Yidong Yang⁶, Sohrab P Shah^{3,6}, Leah M Prentice⁴, Marco A Marra⁷, Jeffrey Kiefer¹, Victoria L Zismann¹, Troy A McEachron¹, Bodour Salhia¹, Jaime Prat⁸, Emanuela D'Angelo⁸, Blaise A Clarke⁹, Joseph G Pressey¹⁰, John H Farley¹¹, Stephen P Anthony¹², Richard B S Roden¹³, Heather E Cunliffe^{1,14}, David G Huntsman^{3,4,16}, and Jeffrey M Trent^{1,16}

¹Division of Integrated Cancer Genomics, Translational Genomics Research Institute (TGen), Phoenix, Arizona, USA ²School of Life Sciences, Arizona State University, Tempe, Arizona, USA ³Department of Pathology and Laboratory Medicine, University of British Columbia, Vancouver, British Columbia, Canada ⁴Centre for Translational and Applied Genomics, British Columbia Cancer Agency, Vancouver, British Columbia, Canada ⁵Department of Dermatology, Mayo Clinic, Scottsdale, Arizona, USA ⁶Department of Molecular Oncology, British Columbia Cancer Agency, Vancouver, British Columbia, Canada ⁷Canada's Michael Smith Genome Sciences Centre, British Columbia Cancer Agency, Vancouver, British Columbia, Canada ⁸Department of Pathology, Hospital de la Santa Creu i Sant Pau, Autonomous University of Barcelona, Barcelona, Spain ⁹Department of Pathology, University Health Network, Toronto, Ontario, Canada ¹⁰Department of Pediatric Hematology-Oncology, Children's Hospital of Alabama, University of Alabama at Birmingham, Birmingham, Alabama, USA ¹¹Division of Gynecologic Oncology, Department of Obstetrics and Gynecology, Creighton University School of Medicine and St. Joseph's Hospital and Medical Center, Phoenix, Arizona, USA ¹²Evergreen Hematology and Oncology, Spokane, Washington, USA ¹³Department of Pathology, Johns Hopkins University, Baltimore, Maryland, USA ¹⁴Department of Pathology, University of Otago, Dunedin, New Zealand

Abstract

©2014 Nature America, Inc. All rights reserved.

Reprints and permissions information is available online at <http://www.nature.com/reprints/index.html>

Correspondence should be addressed to D.G.H. (dhuntsma@bccancer.bc.ca) or J.M.T. (jtrent@tgen.org).

¹⁵These authors contributed equally to this work.

¹⁶These authors jointly directed this work.

Note: Any Supplementary Information and Source Data files are available in the online version of the paper.

Author Contributions: Study concept and design: P.R., A.N.K., H.E.C., J.M.T. and D.G.H. Acquisition of data: P.R., A.N.K., M.L.R., J.J.C., B.S. and H.E.C. Sample contribution: J.P., E.D., B.A.C., J.G.P., J.H.F., S.P.A. and R.B.S.R. Data analysis: P.R., A.N.K., A.S., W.P.D.H., M.T.B., J.K., V.L.Z., B.S., T.A.M., J.M.T. and D.G.H. Bioinformatics data analysis: D.W.C., M.L.R., J.J.C., K.S., Y.Y., S.P.S., L.M.P. and M.A.M. Drafting of the manuscript: P.R., A.N.K., A.S., W.P.D.H., J.M.T. and D.G.H.

Competing Financial Interests: The authors declare no competing financial interests.

Small cell carcinoma of the ovary of hypercalcemic type (SCCOHT) is an extremely rare, aggressive cancer affecting children and young women. We identified germline and somatic inactivating mutations in the SWI/SNF chromatin-remodeling gene *SMARCA4* in 69% (9/13) of SCCOHT cases in addition to *SMARCA4* protein loss in 82% (14/17) of SCCOHT tumors but in only 0.4% (2/485) of other primary ovarian tumors. These data implicate *SMARCA4* in SCCOHT oncogenesis.

SCCOHT occurs in young adult and pediatric patients (mean age of 24, range of 14 months to 58 years)¹⁻⁴. Most patients with SCCOHT are diagnosed at an advanced stage and do not respond to chemotherapy. More than 65% of patients succumb to their disease within 1–2 years of diagnosis¹. SCCOHT is distinguished from more common types of ovarian cancer by its histological appearance, immunophenotype and cytogenetic characteristics¹. Histologically, SCCOHT is composed of sheets of small, tightly packed cells with scant cytoplasm and hyperchromatic nuclei frequently interrupted by follicle-like structures¹. SCCOHT shows a unique immunoprofile that includes expression of Wilms tumor suppressor gene 1 (WT1), epithelial membrane antigen (EMA), vimentin and cytokeratins alongside lack of expression of inhibin, chromogranin, thyroid transcription factor 1 (TTF1), S100 calcium-binding protein A1 and α -fetoprotein (AFP)⁵. Unlike most poorly differentiated, highly malignant tumors, SCCOHT is characteristically diploid, but its cellular and molecular mechanisms of pathogenesis remain poorly understood¹.

To analyze the genetic etiology of SCCOHT, we performed next-generation sequencing on a series of tumors and germline samples from 12 SCCOHT cases (9 tumors with 4 matched germline samples and 3 additional germline samples) and on the SCCOHT cell line BIN-67 (ref. 6). DNA from tumor and blood specimens was analyzed using whole-genome sequencing (two matched tumor-normal pairs and the BIN-67 cell line) and whole-exome sequencing (remaining samples; Supplementary Table 1). Stringent variant-calling methods were used to identify single-base substitutions and indels (see the Online Methods and Supplementary Table 2 for a list of the variants identified in each tumor). *SMARCA4*, a gene previously implicated in SCCOHT⁷, was the only recurrently mutated gene, bearing inactivating mutations in six of nine tumors and in BIN-67 cells (Table 1). Two tumors harbored two mutations each in *SMARCA4*, suggesting biallelic inactivation. The majority of the mutations affected the ATPase domain and are expected to result in truncated proteins (Fig. 1a).

Given that SCCOHT has been reported to occur in families^{1,8,9} and that germline mutations of SWI/SNF complex genes have also previously been reported in highly malignant pediatric cancers¹⁰, we evaluated SCCOHT germline samples for *SMARCA4* mutations. We discovered truncating mutations in two of the seven cases examined (Fig. 1a and Table 1), diagnosed at ages 9 and 10 years. The case diagnosed at 9 years bore the germline heterozygous nonsense mutation c.2935C>T (p.Arg979*), which truncates the *SMARCA4* protein upstream of the helicase domain and bromodomain. Similarly, germline DNA from the case diagnosed at 10 years carried a frameshift mutation in exon 4, c.722_735delGTCCCGGCCCGCA (p.Gly241fs), removing all essential *SMARCA4* functional domains. Because we did not have matching germline DNA for five of the

sequenced tumors, four of which had *SMARCA4* mutations, we cannot exclude the possibility that some of the detected tumor mutations might also be present in the germ line of these cases.

To evaluate the possible functional effects of mutations on the *SMARCA4* gene product, we assessed SMARCA4 protein expression in SCCOHT tumors (Supplementary Table 3). Immunohistochemical analysis of 17 tumors (8 overlapping with the 12 cases sequenced above and an additional 9 validation cases) showed that 14 of 17 (82%) lacked SMARCA4 protein (Fig. 1b). SMARCA4 staining was seen in only two tumors, both from pediatric cases. One of these cases had no germline *SMARCA4* mutations by exome sequencing, and the mutational status of the second case was unknown. All samples with *SMARCA4* mutation lacked detectable SMARCA4 protein. We also noted loss of SMARCB1 protein expression in one SCCOHT tumor (SCCO-010) that had no *SMARCA4* mutations and retained SMARCA4 protein expression (Supplementary Table 3). SMARCA4 loss was specific to tumor cells, as normal cells within the same sections showed robust SMARCA4 staining (Fig. 1b). The antibody to SMARCA4 recognizes an epitope comprising amino acids 240–277. Excepting the p.Gly241fs alteration encoded in the germ line of SCCO-017, all alterations were predicted to yield proteins detectable by this antibody. Thus, the complete loss of SMARCA4 protein observed might be consistent with nonsense-mediated decay of mutant transcripts. Although loss of SMARCA4 protein in tumors with wild-type *SMARCA4* and in tumors without multiple *SMARCA4* mutations suggests that other mechanisms lead to SMARCA4 loss, neither DNA methylation nor loss of heterozygosity (LOH) contribute to *SMARCA4* inactivation in these cases (Supplementary Figs. 1–3 and Supplementary Note).

To determine the specificity of SMARCA4 loss to SCCOHT, we performed immunohistochemistry for SMARCA4 in 485 primary ovarian epithelial, sex cord stromal and germ cell tumors (Supplementary Table 4) as well as in normal premenopausal ovary and fallopian tube (Supplementary Fig. 4). Only two tumors (0.4%), both clear cell carcinomas, were negative for SMARCA4 staining. Notably, the tumors that most closely resembled SCCOHT histologically, including all granulosa cell tumors of juvenile ($n = 8$) and adult ($n = 36$) types, maintained SMARCA4 expression. In addition, representative cell lines from four ovarian carcinoma subtypes as well as immortalized granulosa cells (SVOGs) and adult granulosa tumor cells (KGNs) all maintained SMARCA4 expression as determined by protein blotting (Fig. 1c). In contrast, the BIN-67 SCCOHT cell line, which harbored two splice-site mutations in *SMARCA4*, showed complete absence of SMARCA4 protein (Fig. 1c). These results demonstrate that SMARCA4 loss is highly specific to SCCOHT.

We have identified frequent germline and somatic *SMARCA4* mutations and SMARCA4 protein loss in SCCOHT. These data suggest a tumor suppressor role for SMARCA4, reminiscent of data in which mice with conditional loss of *Smarca4* develop ovarian cysts and uterine tumors¹¹. The loss of normal SWI/SNF complex function might therefore represent a key tumorigenic step in SCCOHT and might further constitute a key therapeutic vulnerability in SMARCA4-deficient cells^{12–14}. Finally, we have shown that loss of

SMARCA4 protein expression is extremely specific to SCCOHT and can facilitate the differential diagnosis of SCCOHT.

URLs

Small cell carcinoma of the ovary (SCCO) research study, <https://www.tgen.org/research/research-divisions/genetic-basis-of-human-disease/scco-research-study.aspx>.

Methods

Methods and any associated references are available in the online version of the paper.

Online Methods

Clinical samples

At TGen, we established a web-based IRB-approved Health Insurance Portability and Accountability Act-compliant protocol to facilitate the collection of biospecimens from consenting patients with SCCOHT, their legal proxy if under 18 years of age or the loved ones of deceased individuals. Self-reported demographic and medical history data were also collected. At the University of British Columbia, we collected biospecimens from the Ovarian Cancer Research Program (OvCaRe) tissue bank in Vancouver, British Columbia, Canada; the University of Toronto in Toronto, Ontario, Canada; the Children's Oncology Group at Nationwide Children's Hospital in Columbus, Ohio, USA; and the Hospital de la Santa Creu i Sant Pau at the Autonomous University of Barcelona in Barcelona, Spain, using an IRB-approved protocol. All patients signed consent forms according to IRB-approved protocols. All of the specimens were SCCOHT, with four cases (SCCO-009, SCCO-010, SCCO-017 and SCCO-019) classified as large cell variants of SCCOHT in their pathology reports. Cases of small cell carcinoma of pulmonary type were excluded from the study.

Genomic DNA isolation

Genra Puregene kits (Qiagen) or AllPrep kits (Qiagen) were used for DNA isolation. Fresh-frozen tissue was disrupted and homogenized in Buffer RLT plus (Qiagen), using the Bullet Blender (Next Advance), and transferred to a microcentrifuge tube containing Buffer RLT plus and 1.6-mm stainless steel beads. Blood leukocytes (buffy coat) were isolated from whole blood by centrifugation at room temperature and were resuspended in Buffer RLT plus. All samples were homogenized and centrifuged at full speed, and lysates were transferred to Qiagen AllPrep DNA spin columns. Genomic DNA was purified following the manufacturer's protocol. DNA was quantified using the Nanodrop spectrophotometer on the basis of 260 nm/280 nm and 260 nm/230 nm absorbance ratios and using Qubit assays (Life Technologies).

Exome library preparation

Briefly, ~3 µg of high-quality genomic DNA was fragmented to a target size of 150 to 200 bp on the Covaris E210 system. Fragmentation was verified on a 2% Tris-acetate-EDTA (TAE) gel, and fragmented samples were end repaired using the NEBNext kit (New England

BioLabs). Repaired samples were purified using Ampure XP beads, polyadenylated at the 3' end using the NEBNext kit and purified again with Ampure XP beads. Illumina index adaptors were then ligated onto polyA-tailed fragments, and products were purified with Ampure XP beads. Samples were then PCR amplified using Herculanase II polymerase (Agilent). Samples were next run on an Agilent Bioanalyzer to verify amplification and to quantify them. Samples were adjusted to 147 ng/μl for a 16-h hybridization with exonic probes using the SureSelect All Exon 50Mb Plus kit (Agilent). Captured products were then selected for, purified and PCR amplified. Final libraries were verified and quantified using an Agilent Bioanalyzer.

PCR-free whole-genome library preparation

Genomic DNA (3 μg) from each sample was fragmented to a target size of 300–350 bp. Overhangs in the fragmented samples were repaired, and fragments were polyadenylated. Diluted paired-end Illumina adaptors were then ligated onto the polyadenylated products. After ligation, samples were run on a 3% TAE gel to separate products. Ligation products of 300 bp and 350 bp were selected for each sample, isolated from gel punches and purified. Products were quantified using the High-Sensitivity DNA chip (Agilent) on an Agilent 2100 Bioanalyzer.

Paired-end next-generation sequencing

Tumor and normal libraries were prepared for 100-bp paired-end sequencing. Clusters were generated using the Illumina cBot and HiSeq Paired-End Cluster Generation kits and sequenced on an Illumina HiSeq 2000 using the Illumina HiSeq Sequencing kit.

Mapping and variant analysis

For whole-genome and whole-exome sequencing, fastq files were aligned with Burrows-Wheeler Aligner (BWA) 0.7.5a to hs37d5, and the SAM output file was converted into a sorted BAM file using SAMtools 0.1.19. BAM files underwent indel realignment, duplicate marking and recalibration steps in this order with the Genome Analysis Toolkit (GATK) 2.8-1, where dpsnp137 was used for known SNPs and Mills_and_1000G_gold_standard.indels.b37.vcf was used for known indels. Lane-level sample BAM files were then merged with Picard 1.91 if samples were sequenced across multiple lanes. Variant calling was carried out with Unified Genotyper, and output VCF files were recalibrated with VariantRecalibrator from GATK 2.8-1. SnpEff 3.2 and SnpSift 1.9c were then used to annotate these VCF files with database version GRCh37.70. Only variants with a minimum quality score of 20 were extracted. Thereafter, we excluded somatic coding variants (SNVs) that either appeared in the 1000 Genomes Project database, the dbSNP database or the National Heart, Lung, and Blood Institute (NHLBI) Exome Sequencing Project database, assuming that these SNVs might be of less importance for tumorigenesis. All *SMARCA4* mutations were validated by Sanger sequencing.

Immunohistochemistry

A tissue microarray (TMA) representing nine SCCOHT cases was fabricated at TGen for this study as previously described¹⁵. At least two representative core punches of 0.6 mm in

diameter were included for each case. Although no case-matched normal ovary tissue was available, two cases were obtained with uninvolved fallopian tube tissue and were included in the TMA. Whole slide sections from six additional SCCOHT tumor cases were used for an immunohistochemical validation cohort. Paraffin blocks were also prepared from formalin-fixed A549 (American Type Culture Collection) and BIN-67 cells. TMAs of ovarian epithelial, sex cord stromal and germ cell tumors were constructed and stained at the Genetic Pathology Evaluation Centre in British Columbia, Canada. At least two representative core punches of 0.6 mm in diameter were included for each case. Histological sections of normal premenopausal ovaries and fallopian tubes were obtained from the Vancouver General Hospital Pathology archives. Unstained slides were processed using the Ventana Discovery Ultra system (Ventana Medical Systems), using a rabbit monoclonal antibody to SMARCA4 (BRG1; Abcam, ab110641; 1:25 dilution) and mouse monoclonal antibody to SMARCB1 (INI1; BD Transduction Laboratories, 612110; 1:50 dilution). The antibody to SMARCB1 was used to confirm the antigenic reactivity of the tumor cells and cell lines that were negative for SMARCA4 expression. Tumors were scored positive if any tumor cell nuclei showed moderate to strong (definite) positive nuclear staining. Tumors were scored negative when tumor cells showed no nuclear staining only if there was adequate nuclear staining of an internal positive control (endothelial cells, fibroblasts or lymphocytes). No cytoplasmic staining was seen for SMARCA4.

Protein blot analysis

Whole-cell extracts were prepared in RIPA buffer containing protease and phosphatase inhibitors. Lysates were electrophoresed by 8% SDS-PAGE, blotted onto nitrocellulose, probed overnight with primary antibodies to SMARCA4 (see above; 1:1,000 dilution) and vinculin (Sigma, V9131; 1:60,000 dilution) incubated for 1 h with horseradish peroxidase (HRP)-conjugated secondary antibodies (Sigma) and visualized using ECL-Plus (GE Life Sciences). The lung cancer cell line A549, previously shown to lack SMARCA4 protein¹³, was used as a negative control. All cell lines were confirmed to be negative for mycoplasma contamination.

Supplementary Material

Refer to Web version on PubMed Central for supplementary material.

Acknowledgments

We particularly thank the families and patients who joined this institutional review board (IRB)-approved study for their critical contributions. We also thank the faculty and staff at TGen from the Macromolecular Analysis & Processing Center (G. Hostetter and J. LoBello) and the Office of Research Compliance & Quality Management (L. Nordstrom, S. Althoff and S. Buchholtz); the Children's Oncology Group for their samples; and B. Vanderhyden (University of Ottawa and Ottawa Hospital Research Institute) for BIN-67 cells. This study was supported by grants from the Marsha Rivkin Center for Ovarian Cancer Research, the Anne Rita Monahan Foundation, the Ovarian Cancer Alliance of Arizona, the Small Cell Ovarian Cancer Foundation and philanthropic support to the TGen Foundation. Further support was provided to A.N.K. and D.G.H. by the Terry Fox Research Initiative New Frontiers Program in Cancer and to A.N.K. by the Molecular Oncologic Pathology Fellowship of the Canadian Institutes of Health Research.

References

1. Young RH, Oliva E, Scully RE. *Am J Surg Pathol*. 1994; 18:1102–1116. [PubMed: 7943531]
2. Florell SR, Bruggers CS, Matlak M, Young RH, Lowichik A. *Med Pediatr Oncol*. 1999; 32:304–307. [PubMed: 10102028]
3. Shrimali RK, Correa PD, Reed NS. *Med Oncol*. 2011; 28:766–770. [PubMed: 20361360]
4. Estel R, Hackethal A, Kalder M, Munstedt K. *Arch Gynecol Obstet*. 2011; 284:1277–1282. [PubMed: 21298438]
5. McCluggage WG, Oliva E, Connolly LE, McBride HA, Young RH. *Int J Gynecol Pathol*. 2004; 23:330–336. [PubMed: 15381902]
6. Gamwell LF, et al. *Orphanet J Rare Dis*. 2013; 8:33. [PubMed: 23433318]
7. Kupryja czyk J, et al. *Pol J Pathol*. 2013; 64:238–246. [PubMed: 24375037]
8. Martinez-Borges AR, et al. *Pediatr Blood Cancer*. 2009; 53:1334–1336. [PubMed: 19621450]
9. McDonald JM, et al. *J Pediatr Surg*. 2012; 47:588–592. [PubMed: 22424359]
10. Eaton KW, Tooke LS, Wainwright LM, Judkins AR, Biegel JA. *Pediatr Blood Cancer*. 2011; 56:7–15. [PubMed: 21108436]
11. Serber DW, et al. *PLoS ONE*. 2012; 7:e31346. [PubMed: 22363625]
12. Wilson BG, et al. *Mol Cell Biol*. 2014; 34:1136–1144. [PubMed: 24421395]
13. Oike T, et al. *Cancer Res*. 2013; 73:5508–5518. [PubMed: 23872584]
14. Hoffman GR, et al. *Proc Natl Acad Sci USA*. 2014; 111:3128–3133. [PubMed: 24520176]
15. Kononen J, et al. *Nat Med*. 1998; 4:844–847. [PubMed: 9662379]

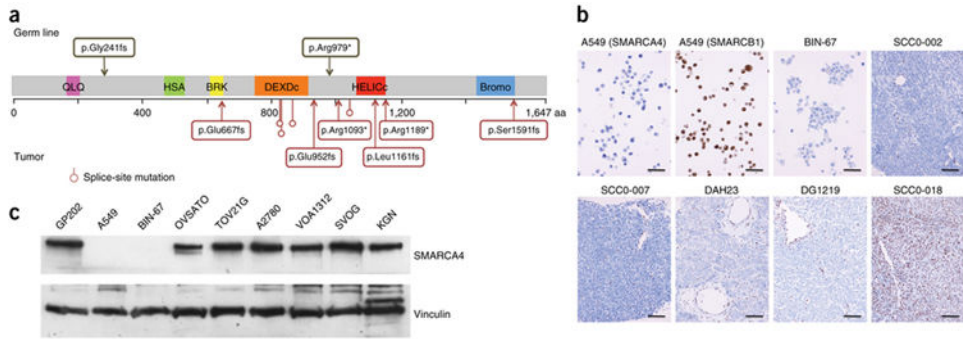


Figure 1. Inactivating germline and somatic *SMARCA4* mutations identified in SCCOHT. **(a)** Schematic of the *SMARCA4* protein showing the location of the alterations identified in SCCOHT germline and tumor DNA samples. QLQ, Gln, Leu, Gln motif; HSA, helicase/SANT-associated domain; BRK, brahma and kismet domain; DEXDc, DEAD-like helicase superfamily domain; HELICc, helicase superfamily C-terminal domain; Bromo, bromodomain. **(b)** *SMARCA4* immunohistochemistry analysis. Representative images of *SMARCA4*-negative SCCOHT tumors. Only two tumor cases showed positive nuclear staining for *SMARCA4* (SCCO-018 shown). 200× magnification; scale bars, 100 μm. Immunohistochemistry of A549 cells for *SMARCA4* and *SMARCB1* was used for negative and antibody specificity controls, respectively. 400× magnification; scale bars, 50 μm. **(c)** *SMARCA4* protein expression in representative cell lines from five major ovarian carcinoma subtypes (small cell, BIN-67; high-grade serous, OVSAYO; clear cell, TOV21G; endometrioid, A2780; low-grade serous, VOA1312), immortalized granulosa cells (SVOG) and an adult granulosa cell tumor cell line (KGN). Lung (A549) and gastric (GP202) carcinoma cell lines were included as negative and positive *SMARCA4* expression controls, respectively.

Table 1
SMARCA4 mutations identified in germline and tumor DNA from SCCOHT cases

Sample	Age at diagnosis (years)	Sequencing analysis performed	SMARCA4 mutation in germline DNA	SMARCA4 mutation in tumor DNA (total predicted SNVs) ^b	Predicted protein alteration	SMARCA4 IHC
SCCO-002 ^a	26	Exome	None	None (2)	None	Negative
SCCO-008	9	Exome	c.2935C>T	NA	p.Arg979*	NA
SCCO-010	6	Exome	None	NA	None	Positive
SCCO-017	10	Exome	c.722_735delGTCCCGCCCGGCA	NA	p.Gly241fs	Negative
SCCO-012	21	Exome	NA	None	None	Negative
SCCO-014	33	Exome	NA	c.[200]delG(:) 348]delC]	p.Glu667fs p.Leu1161fs	NA
SCCO-015	27	Exome	NA	c.3565C>T	p.Arg1189*	NA
DAH23	30	Exome	NA	c.2438+1_2438+2insTGA	Splice-site mutation	Negative
DAH456 ^a	39	Exome	None	None (5)	None	Positive
DAH457	23	Exome	NA	c.3277C>T	p.Arg1093*	NA
DG1006 ^a	34	Whole genome	None	c.[2855delA(:) 4771_4774delAAGCG] (19)	p.Glu952fs p.Ser1591fs	Negative
DG1219 ^a	37	Whole genome	None	c.3168+1G>A (12)	Splice-site mutation	Negative
BIN-67	Tumor cell line	Whole genome	NA	c.[2438+1G>A(:) 2439-2A>T]	2 splice-site mutations	Negative

NA, sample not available; IHC, immunohistochemistry.

^aCases with a sequenced tumor-normal pair.

^bThe number of total single-nucleotide variants (SNVs) is indicated only for tumors with a matching normal sample.