

UCSF

UC San Francisco Previously Published Works

Title

Propionibacterium acnes infections in patients with idiopathic scoliosis: a case-control study and review of the literature

Permalink

<https://escholarship.org/uc/item/9496h4zb>

Journal

Journal of Children's Orthopaedics, 12(2)

ISSN

1863-2521

Authors

Swarup, I
Gruskay, J
Price, M
[et al.](#)

Publication Date

2018-04-01

DOI

10.1302/1863-2548.12.170212

Copyright Information

This work is made available under the terms of a Creative Commons Attribution-NonCommercial License, available at <https://creativecommons.org/licenses/by-nc/4.0/>

Peer reviewed

Propionibacterium acnes infections in patients with idiopathic scoliosis: a case-control study and review of the literature

I. Swarup¹
J. Gruskay¹
M. Price¹
J. Yang²
J. Blanco¹
S. Perlman³
R. Widmann¹

Abstract

Purpose Surgical site infection (SSI) caused by *Propionibacterium acnes* is an infrequent but devastating complication after spinal fusion. The purpose of this study was to identify risk factors for SSI with *Propionibacterium acnes* after spinal fusion for juvenile and adolescent idiopathic scoliosis (JIS and AIS).

Methods A case-control study was performed. Each case was matched 2:1 for age, gender and diagnosis. Retrospective chart review was performed to obtain relevant demographic, surgical and clinical data for all cases and controls. Statistical analysis included paired *t*-test and McNemar test, as well as exact logistic regression and robust regression models.

Results This study included ten infection cases (eight AIS, two JIS) and 20 controls (16 AIS, four JIS). In total, six infected cases presented within two weeks of the index procedure (acute infection) and four infected cases presented more than one year from the index procedure (delayed infection). The most common presentation for acute infections was wound drainage, while back pain was more common in delayed infections. All infections were successfully treated with surgical irrigation and debridement and postoperative antibiotics. Hardware was removed for patients with delayed infections. The strongest risk factor for infection was increased require-

ment for blood transfusion, but it did not reach statistical significance.

Conclusion SSI with *Propionibacterium acnes* is an important complication after spinal fusion for idiopathic scoliosis. These infections can be successfully treated, but larger studies are needed to further identify risk factors and establish standardized guidelines for the treatment and prevention of this complication.

Level of Evidence Level III

Cite this article: Swarup I, Gruskay J, Price M, Yang J, Blanco J, Perlman S, Widmann R. *Propionibacterium acnes* infections in patients with idiopathic scoliosis: a case-control study and review of the literature. *J Child Orthop* 2018;12:173-180. DOI 10.1302/1863-2548.12.170212

Keywords: Adolescent idiopathic scoliosis; juvenile idiopathic scoliosis; infection; spinal fusion; *Propionibacterium acnes*

Introduction

Spinal fusion is a common treatment for correcting and preventing the progression of spinal deformity for juvenile idiopathic scoliosis (JIS) and adolescent idiopathic scoliosis (AIS). However, this procedure is associated with various postoperative complications, and adverse events following surgery may occur in 3% to 23% of cases.¹⁻⁶ Surgical site infection (SSI) is an infrequent but devastating complication, and it is the most common reason for readmission following spinal fusion surgery for idiopathic scoliosis.^{1,7}

Several studies have reported the incidence of SSI following surgery for idiopathic scoliosis. Incidence has been reported to range from 0.2% to 9%, but can vary based on patient population, study parameters and definition for SSI (deep *versus* superficial, acute *versus* delayed).^{3,4,6,8,9} A recent study using a large, national, multi-centre database reported a 1.6% incidence of infection (0.6% deep, 1.0% superficial) within 30 days of surgery.¹ While the incidence of acute infection is low, delayed infection is an important but under-recognized complication in the AIS population. Two studies reported a 4.7% to 6.7% incidence of late infection (more than six months after index procedure),^{8,9} and interestingly, low virulence skin-flora such as *Propionibacterium acnes* and *Staphylococcus epidermidis*

¹ Division of Paediatric Orthopaedic Surgery, Hospital for Special Surgery, New York, NY, USA

² Healthcare Research Institute, Hospital for Special Surgery, New York, NY, USA

³ Division of Paediatric Perioperative Medicine, Hospital for Special Surgery, New York, NY, USA

Correspondence should be sent to R. Widmann, Division of Paediatric Orthopaedic Surgery, Hospital for Special Surgery, 535 East 70th Street, New York, NY 10021, United States.
E-mail: widmannr@hss.edu

were cultured in many of these cases. Other investigations reported similar findings.¹⁰⁻¹³ In a recent study from our institution, we reported a deep infection rate of 1% for AIS patients over a 12 year period.¹⁴ Furthermore, the most common pathogen implicated in infections in patients with idiopathic scoliosis was *Propionibacterium acnes*.¹⁴ Even though *Propionibacterium acnes* is traditionally associated with delayed infections, it is now recognized as an important cause for acute infections as well.¹⁴

Many studies have focused on risk factors and prevention of SSI following surgery for idiopathic scoliosis. More specifically, factors such as American Society of Anesthesiologist (ASA) grade,¹⁵ obesity,^{1,15} use of allograft,¹⁶ length of surgery,¹ number of levels fused,¹ blood transfusion,¹¹ surgeon factors,¹⁶ prior medical history¹⁶ and use of post-operative drain¹⁶ have been associated with SSIs. However, there is a paucity of literature focusing on risk factors and best practice guidelines for preventing infections with low virulent organisms, particularly *Propionibacterium acnes*. The purpose of this study is to assess for independent risk factors for the development of SSI with *Propionibacterium acnes* and to describe the current literature and treatment recommendations for the prevention of these infections.

Patients and methods

We performed a case-control study to identify risk factors associated with the development of *Propionibacterium acnes* infections in patients with idiopathic scoliosis. First, we identified all patients that underwent spinal fusion for idiopathic scoliosis at our institution between 2000 and 2012 and subsequently developed a SSI. We previously published the details of this cohort, including the overall incidence of SSIs and proportion of SSIs with *Propionibacterium acnes* in idiopathic scoliosis.¹⁴ We queried our paediatric medicine division and paediatric spine surgeons, and identified additional patients with idiopathic scoliosis that presented with a SSI between 2012 and 2015. Inclusion criteria included age < 21 years at time of index procedure, spinal fusion for JIS or AIS at our institution and treatment for a postoperative SSI at our institution. To ensure a minimum follow-up period of at least one year, patients presenting with a SSI through 2015 were included. All patients underwent posterior spinal fusion, and implant density was determined by patient factors, spinal deformity and surgeon preference. Patients presenting from an outside facility following index procedure for management of postoperative infection were excluded. This study was approved by our institutional review board.

Chart review

We reviewed the charts of all patients that developed a postoperative SSI with *Propionibacterium acnes* to collect

demographic, surgical, infection and microbiology data. A 2:1 control cohort matched by age, gender and diagnosis was also obtained from the initial group of patients described above. These control patients did not develop a SSI after surgery, and chart review was performed to collect demographic and surgical data for these patients as well. We compared the following variables between the cases and controls: body mass index (BMI), surgeon, number of levels fused, ASA grade, length of surgery, use of perioperative antibiotics, surgical site preparation, estimated blood loss, transfusion requirement, use of vancomycin powder, type of lavage (with or without antibiotics), implant material, use of cross-links, use of post-operative drain, length of drain use and length of stay. All of these variables were determined after a literature review of risk factors for SSI after spinal fusion.^{1,11,15-18} We further reviewed the literature to identify and summarize studies focusing on the diagnosis, prevention and management of *Propionibacterium acnes* infections in orthopaedic surgery.

Statistical analysis

Descriptive statistics were summarized using means and sds for continuous variables, and frequencies and percentages for categorical variables. The cases and controls were matched for age, gender and diagnosis. Paired *t*-test and McNemar test were performed to compare continuous and categorical variables between both groups, respectively. Exact logistic regression and robust regression models were used to examine if there are associations between variables and risk of infection. Statistical significance was set to 0.05, and all analyses were performed using Stata 14.0 (StataCorp, College Station, Texas).

Results

Our study included ten patients with SSI after spinal fusion surgery (Table 1). More specifically, six cases of infection were identified from the previous study,¹⁴ and between 2012 and 2015, four additional cases of infection with *Propionibacterium acnes* were managed at our institution. There were no other cases of infection after spinal deformity surgery in patients with JIS or AIS between 2012 and 2015. In our cohort, nine patients had culture-positive infections with *Propionibacterium acnes* and one patient had a culture-negative infection that was treated as a presumed *Propionibacterium acnes* infection. In addition, eight patients had a diagnosis of AIS and two patients had a diagnosis of JIS. The mean age at time of surgery was 15 years (range 13 to 18 years) and there were an equal number of male and female patients. Our control group was comprised of 20 patients (16 AIS, four JIS) matched for age, gender and diagnosis.

Table 1 Cases of surgical site infection after spinal fusion surgery

Patient Number	Gender	Age at operation (yrs)	Diagnosis	Body mass index	Surgeon (coded)	Number of levels fused	ASA grade	Length of Surgery (hrs +mins)	Use of perioperative abx (type)	Surgical site preparation	Estimated blood loss (cc)	Transfusion volume (1 unit = 250 cc)
1	M	17	ALS	20.4	A	11	1	4+20	Ancef	3	1800	3
2	F	18	ALS	21.3	D	8	1	3+32	Ancef	1	800	2
3	F	14	ALS	18.5	A	5	1	2+25	Ancef	3	400	0
4	F	14	ALS	19.7	B	11	3	4+56	Ancef	1	800	1
5	M	16	ALS	23.3	B	12	2	3+11	Ancef	1	3400	0
6	F	15	JIS	24.5	D	13	2	3+20	Ancef	1	1800	0
7	M	16	ALS	19.8	D	14	2	7+15	Ancef	2	2000	1
8	F	13	ALS	16.7	D	12	1	4+47	Ancef	1	1000	2
9	M	14	JIS	18.4	C	13	2	6+37	Ancef	3	1500	0
10	M	15	ALS	18.7	F	11	2	3	Ancef	2	600	0

Patient Number	Intraoperative use of vancomycin powder	Use of lavage with abx	Implant material**	Cross-link use	Use of postoperative drain	Duration of hospital stay	Pathogen	Postoperative day of infection	Removal of hardware	Length of postoperative abx
1	N	Y	1	N	N	N/A	P. acnes	6	N	6 wks
2	N	Y	2	N	Y	POD 2	P. acnes	7	N	6 wks
3	N	Y	3	N	Y	POD 2	P. acnes	12	N	10 days
4	N	Y	2	N	Y	POD 2	-	13	N	6 wks
5	N	Y	1	Y	Y	POD 2	P. acnes	1424	Y	6 wks
6	N	Y	2	N	Y	POD 2	P. acnes	1229	N	1 yr
7	Y	Y	3	Y	Y	POD 4	P. acnes	382	Y	9 wks
8	N	Y	2	N	Y	POD 4	P. ances	2093	Y	6 wks
9	Y	Y	3	N	Y	POD 1	P. acnes	2	N	4 wks
10	Y	Y	3	N	Y	POD 3	P. acnes	14	N	6 wks

*1 = Betadine only, 2 = chlorhexidine gluconate only, 3 = Betadine + chlorhexidine gluconate

**1 = titanium, 2 = stainless steel, 3 = cobalt chrome

N/A, not applicable; ASA, American Society of Anesthesiologists; Abx, antibiotics; ALS, adolescent idiopathic scoliosis; JIS, juvenile idiopathic scoliosis; POD, postoperative day

Infection data

Patients with SSI had surgery between 2006 and 2015. Infections were noted in six patients within two weeks of the index procedure (acute infection), and four patients developed infections over one year from the index procedure (delayed infection). No patients had notable back acne or dermatological complaints at the time of their surgical consultation or preoperative visit. The presenting complaint was wound drainage for all acute infections. On the other hand, delayed infections typically presented with complaints of back pain. The most common laboratory abnormalities included leukocytosis in two out of four patients (12 700 and 14 810 white blood cells per mL) and elevated inflammatory markers in two out of four patients (c-reactive protein (CRP)) 3.6 mg/dl and 6.7 mg/dl, normal < 1 mg/dl). The work-up for delayed infections was comprised of laboratory tests, advanced imaging, and in one case, bone culture and aspiration.

Regardless of acute or delayed presentation, all patients were treated with operative management and postoperative antibiotics. Acute infections were treated with irrigation and debridement, and two patients with acute infections had this procedure during their index admission. Delayed infections were treated with irrigation and debridement as well as removal of hardware in three out of four cases. A robust fusion mass was confirmed on CT scans and intraoperatively in all patients that underwent hardware removal. Intraoperative findings were significant for a hypertrophic soft-tissue reaction around the implant in one patient with a delayed infection; a deep sinus tract with frank purulence in another patient with delayed infection; superficial purulence in one patient with an acute infection; and seroma formation in two other patients with acute infections.

Postoperative antibiotic treatment for acute infections included cephalexin, ampicillin-sulbactam or ciprofloxacin and clindamycin, and duration of treatment was most commonly six weeks, but ranged from ten days to six weeks. Antibiotic treatment for delayed infections was a short course of intravenous antibiotics followed by oral antibiotics (cephalexin or amoxicillin), and the duration of treatment ranged from six weeks to one year. Treatment was successful in all patients in this study.

Variables

Univariate logistic regression analysis was performed to determine any significant risk factors for infection (Table 2). There were no significant differences in BMI, surgeon and number of levels fused between cases and controls (p > 0.05). Similarly, the length of surgery, surgical site preparation and estimated blood loss did not significantly differ between groups (p > 0.05). However, 3/10 infection cases

Table 2 Risk factors for surgical site infection after spinal fusion surgery

	Control (n = 20)	Case (n = 10)	p-value
Gender			0.796
Male	9 (45%)	5 (50%)	
Female	11 (55%)	5 (50%)	
Age, mean (sd)	15.2 (1.48)	15.2 (1.55)	0.932
Body Mass Index			0.540
Underweight/normal	18 (90%)	10 (100%)	
Overweight/obese	2 (10%)	0	
Surgeon			0.914
A	3 (15%)	2 (20%)	
B	5 (25%)	2 (20%)	
C	3 (15%)	1 (10%)	
D	7 (35%)	4 (40%)	
E	0	1 (10%)	
F	1 (5%)	0	
G	1 (5%)	0	
Number of levels fused			0.314
4	1 (5%)	0	
5	0	1 (10%)	
8	0	1 (10%)	
10	4 (20%)	0	
11	4 (20%)	3 (30%)	
12	6 (30%)	2 (20%)	
13	4 (20%)	2 (20%)	
14	0	1 (10%)	
15	1 (5%)	0	
ASA grade			0.513
1	9 (45%)	4 (40%)	
2	11 (55%)	5 (50%)	
3	0	1 (10%)	
Length of surgery (mins), mean (sd)	288.3 (65)	284.3 (90.5)	0.900
Perioperative antibiotics			N/A
No	0	0	
Yes	20 (100%)	10 (100%)	
Surgical site preparation			0.651
Betadine only	13 (65%)	5 (50%)	
Chloraprep only	3 (15%)	2 (20%)	
Chloraprep+betadine	4 (20%)	3 (30%)	
Blood loss (cc), mean (sd)	1327.5 (791.1)	1410 (895)	0.805
Intraoperative blood transfusion (units)			0.343
0	16 (80%)	6 (60%)	
1	4 (20%)	3 (30%)	
3	0	1 (10%)	
Postoperative blood transfusion (units)			0.670
0	14 (70%)	8 (80%)	
1	5 (25%)	1 (10%)	
2	1 (5%)	1 (10%)	
Total blood transfusion (units)			0.152
0	10 (50%)	5 (50%)	
1	9 (45%)	2 (20%)	
2	1 (5%)	2 (20%)	
3	0	1 (10%)	
Vancomycin powder			0.372
No	17 (85%)	7 (70%)	
Yes	3 (15%)	3 (30%)	
Lavage type			0.615
No antibiotics	1 (5%)	0	
Yes (bacitracin, polymyxin)	17 (85%)	9 (90%)	
Yes (polymyxin)	2 (10%)	0	
Yes (bacitracin)	0	1 (10%)	
Implant material			0.880
Cobalt chrome	6 (30%)	4 (40%)	
Stainless steel	10 (50%)	4 (40%)	
Titanium	4 (20%)	2 (20%)	
Use of cross-link			0.234
No	10 (50%)	8 (80%)	
Yes	10 (50%)	2 (20%)	
Drain use			0.333
No	0	1 (10%)	
Yes	20 (100%)	9 (90%)	
Drain removal			0.256
N/A	0	1 (10%)	
POD 1	1 (5%)	1 (10%)	
POD 2	12 (60%)	5 (50%)	
POD 3	6 (30%)	1 (10%)	
POD 4	1 (5%)	2 (20%)	
Length of stay (days), mean (sd)	5.25 (1.3)	563 (1.3)	0.266

ASA, American Society of Anesthesiologists; POD, postoperative day

Paired t-test was used to compare continuous variables and McNemar test was used to compare categorical variables.

and 1/20 controls required two or more units of blood in the perioperative period ($p = 0.15$).

Furthermore, all patients received cefazolin for perioperative antibiotic prophylaxis, and there were no significant differences in vancomycin powder use and antibiotic lavage between groups ($p > 0.05$). There was also no significant difference in implant material and the use of cross-links between groups ($p > 0.05$). Drains were placed in almost all cases, and these drains were typically removed on postoperative day (POD) 2 for cases and controls ($p > 0.05$). After excluding infection cases that underwent irrigation and debridement during the index admission, the mean length of stay did not differ between groups ($p > 0.05$).

All variables were dichotomized based on their distribution, and odds ratios (OR) were calculated (Fig. 1). ASA grade (Grades 2 and 3) (OR 1.22, 95% confidence interval (CI) 0.21 to 7.85), surgical site preparation (both betadine and chlorhexidine gluconate) (OR 1.68, 95% CI 0.19 to 13.2), use of vancomycin powder (OR 2.35, 95% CI 0.25 to 22.31), intraoperative blood transfusion (OR 2.57, 95% CI 0.36 to 19.25) and length of stay (greater than five

days) (OR 2.66, 95% CI 0.36 to 23.88) had the largest ORs for infection. We re-analyzed the data after excluding the patient with a culture-negative infection and found no other significant associations.

Discussion

SSI is an infrequent but devastating complication of spinal fusion surgery for idiopathic scoliosis. *Propionibacterium acnes* is a well described cause of infection in these patients, however, there is limited data on its presentation, risk factors and management. In this study, the most common presentation for acute infections with *Propionibacterium acnes* was wound drainage, while back pain was more common in delayed infections. All infections were successfully treated with surgical irrigation and debridement followed by antibiotics. We did not find any significant risk factor for the development of infection with *Propionibacterium acnes* with our sample size. However, factors such as transfusion requirement, surgical site preparation, use of vancomycin powder and length of stay may be implicated, and require additional study.

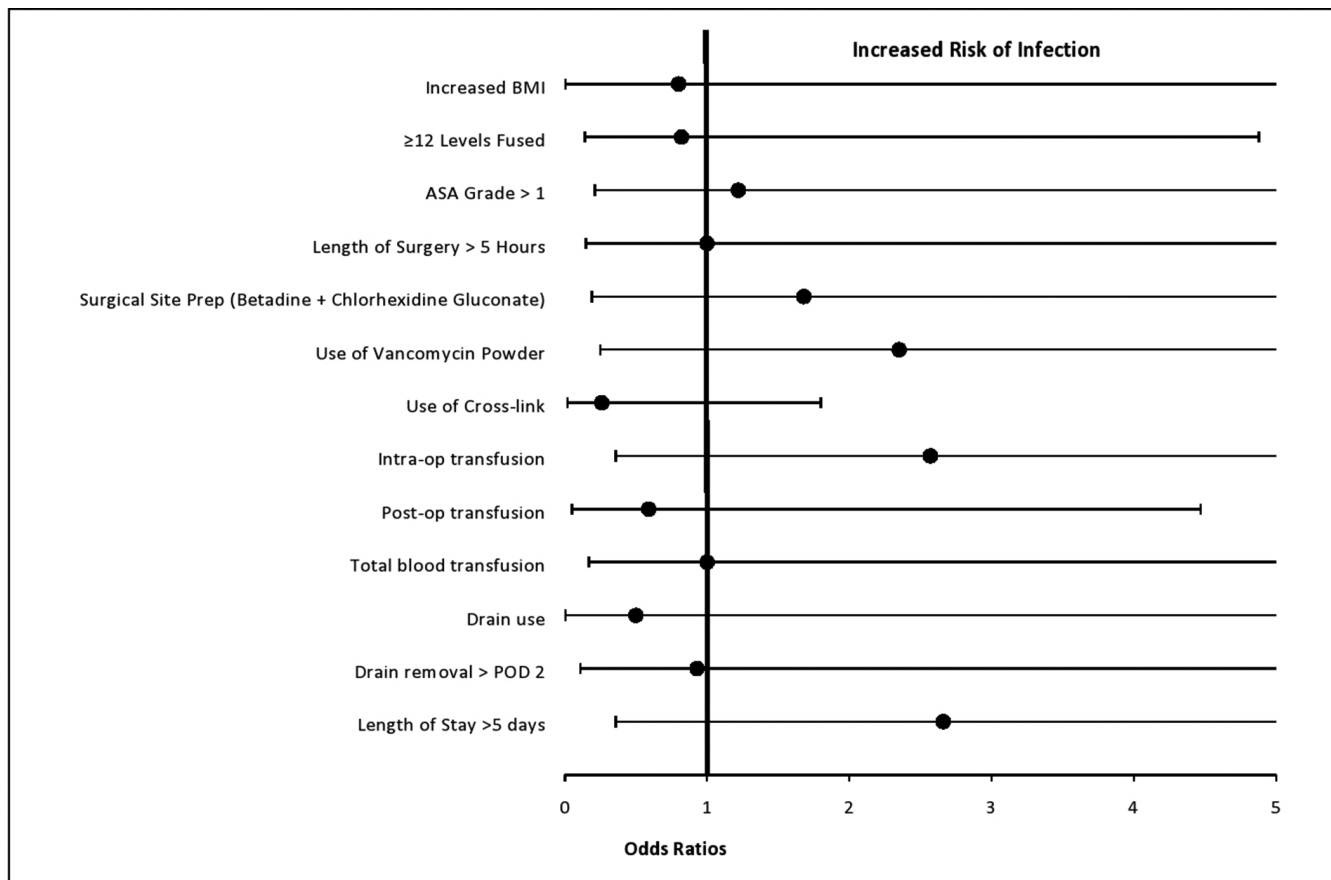


Fig. 1 Odds ratios and associated 95% confidence interval for risk factors of infection with *Propionibacterium acnes* (BMI, body mass index; ASA, American Society of Anesthesiologists; POD, postoperative day).

Propionibacterium acnes is a gram-positive, facultative anaerobe with a slow growth rate and low virulence.¹⁹⁻²¹ It is part of the skin flora populating the oily pilosebaceous glands of the chest, back, manubrium and ear,²²⁻²⁴ and it is considered an important pathogen in infections following various orthopaedic procedures, particularly in spine and shoulder surgery.^{8,20,22,25} Due to its deep dermal location, *Propionibacterium acnes* is relatively sheltered from the standard perioperative antibiotic regimen²⁶ and surgical skin preparations.²⁷ Furthermore, it forms a polysaccharide matrix biofilm in the presence of implanted materials, making its eradication difficult without surgical intervention.^{28,29} Inoculation into the deep wound is believed to occur with skin incision,^{25,27,30,31} however, other routes such as hematogenous spread, introduction by prior procedure or surgical instrument and provider contamination have also been proposed.²⁵

Data regarding prevention strategies for *Propionibacterium acnes* is mostly anecdotal and observational. Strategies suggested in both the spine and shoulder arthroplasty literature include dermatology referral and treatment for skin acne until cleared prior to surgery; adequate skin preparation; tailored prophylactic antibiotics with effectiveness against *Propionibacterium acnes*; using a new knife for deep dissection; copious irrigation of the field with antibiotic containing saline; usage of titanium implants that may decrease biofilm formation; insertion of implants with new gloves; avoidance of implant contact with skin edge; and avoidance of cross-links that lead to bursa formation.^{8,25,27,32,33} Our general strategy includes preoperative dermatological referral in the setting of back acne; surgical site preparation with either betadine or chlorhexidine; perioperative antibiotic prophylaxis; meticulous hemostasis; copious irrigation with saline containing antibiotic; and routine use of postoperative drains.

In our study, blood transfusion during the perioperative period trended towards a significant relationship with SSI. Blood transfusion is a recognized risk factor for infection in orthopaedic and non-orthopaedic surgery. A greater number of patients with infections in our study required two or more units of blood in the perioperative period. Our findings are consistent with Ho et al,¹¹ who found that blood transfusion and increasing units of blood transfusion were associated with infections following posterior spinal fusion for AIS. The increased risk of infection may be due to transfusion-induced immunomodulation, which refers to the relative immunosuppressive effects of blood transfusion.³⁴ Furthermore, surgical site preparation, vancomycin powder use and length of stay had large ORs but their CIs crossed 1. While previous studies have implicated some of these factors,^{11,35} larger studies are needed to better understand the relationship between blood transfusion and SSI with *Propionibacterium acnes*, as well as better elucidate the role of surgical site preparation, vancomycin

powder use and length of stay in the pathogenesis of SSIs with *Propionibacterium acnes*.

Diagnosis of acute infection in our cohort was relatively straightforward as all patients presented with active wound drainage within two weeks of surgery. Meanwhile, delayed infection can present a diagnostic challenge. Each of our patients with delayed infections presented with increasing back pain, necessitating further work-up including labs and advanced imaging to evaluate for collection and fusion mass. This presentation is consistent with the previously described 'honeymoon period' of expected prolonged recovery and function, followed by onset of stiffness, pain and spasms.^{10,25,28} Wound drainage and/or fever are rare presentations for delayed infections.^{10,36,37} Elevation of white blood cell count and inflammatory markers (erythrocyte sedimentation rate and CRP) were seen in 50% of our patients, but this was variable and has been reported in less than 50% of cases.^{10,38} Diagnostic imaging modalities, such as MRI and CT, can be invaluable in determining the presence of a collection and assessing bony fusion prior to operative intervention.^{37,39}

Established literature on treatment for *Propionibacterium acnes* infection in idiopathic scoliosis is sparse. In a study on delayed postoperative infection, Richards et al⁸ recommended irrigation and debridement, implant removal, primary wound closure and short-term postoperative parental antibiotic therapy (first generation cephalosporin) followed by oral antibiotics for one to two weeks. Eradication of the protective biofilm was of primary concern and the authors suggested removal of hardware for all delayed infections.^{8,40} As biofilm formation appears to occur slowly, removal of hardware may not be required in acute infection.⁴¹ Meanwhile, treatment in the total shoulder arthroplasty literature typically consists of irrigation and debridement, intravenous or oral antibiotic treatment and suppression for four to six weeks and one- or two-stage revision.⁴² Regional resistance to various antibiotics has been noted, leading investigators to use multidrug programmes often including penicillin or cephalosporin and rifampin.⁴³ Vancomycin and clindamycin demonstrate only 'fair' activity.⁴⁴

At our institution, routine perioperative antibiotics are given intravenously within one hour of skin incision, re-dosed after four hours for long cases, and continued for 24 hours after surgery. In the setting of SSI after spinal deformity surgery, our treatment algorithm consists of surgical irrigation and debridement for all acute infections, and removal of hardware for delayed infections. At least four cultures are taken at the time of surgery, and prolonged incubation is performed for all cultures. In the literature, final cultures reported at 72 hours have been found to miss the causative organism, especially for low virulent skin flora like *Staphylococcus epidermidis* and *Propionibacterium acnes*.^{8,9,12} Current recommendations

advise culture incubation for at least ten days,⁸ and at our institution, we commonly utilize liquid media (thioglycolate) and incubate cultures for 14 days. Postoperative antibiotic coverage and duration is determined in consultation with an infectious disease specialist and is based on culture data, sensitivities, regional microbiodata and relevant literature. In acute infections with *Propionibacterium acnes*, we typically treat with aminopenicillins or first generation cephalosporins for one to six weeks; and in delayed infections, we treat with intravenous cephalosporins followed by oral aminopenicillins or first generation cephalosporins for a minimum of six weeks. There is considerable variation in the duration of antimicrobial therapy, and additional study is needed to determine the optimal duration of treatment.

Limitations of this study include its retrospective nature and small sample size. However, we employed a case-control study design, which is the optimal design to study rare events, and our study identifies several risk factors to guide future study. Additionally, this study was completed at a single institution, which raises questions about the generalizability of our microbiodata on a regional and national level. Similarly, we did not control for other factors such as the number of levels fused. However, we did not find any significant difference in factors between groups. Furthermore, we compared our cases of *Propionibacterium acnes* infection with patients without infection, which counts as a drawback of this study. Additional studies comparing cases of infection with *Propionibacterium acnes* to infection with other pathogens may provide additional insight into risk factors and pathogenesis. Of note, we have had only one SSI in patients with idiopathic scoliosis that has been caused by a pathogen other than *Propionibacterium acnes* over the study period. This study derives its strengths from the case-control study design with 2:1 controls matched for age, gender and diagnosis, as well as its focus on several risk factors that have been previously hypothesized in the literature. Additionally, it is to our knowledge the first study to describe the diagnosis and treatment of a cohort of patients with idiopathic scoliosis and specifically *Propionibacterium acnes* infections.

Many advances have been made in the prevention of postoperative infection following surgery for idiopathic scoliosis. However, SSI with low-virulent organisms such as *propionibacterium acnes* continues to remain an important complication. In this study, we describe the presentation and treatment of a series of acute and delayed infections with *propionibacterium acnes*. We found no significant risk factors for SSI with *propionibacterium acnes*, likely due to our limited sample size. SSI with *propionibacterium acnes* can be successfully treated, however larger studies are needed to better describe risk factors for infection and establish standardized guidelines for the treatment and prevention of this complication.

Received 16 December 2017; accepted after revision 19 February 2018.

COMPLIANCE WITH ETHICAL STANDARDS

FUNDING STATEMENT

No benefits in any form have been received or will be received from a commercial party related directly or indirectly to the subject of this article.

OA LICENCE TEXT

This article is distributed under the terms of the Creative Commons Attribution-Non Commercial 4.0 International (CC BY-NC 4.0) licence (<https://creativecommons.org/licenses/by-nc/4.0/>) which permits non-commercial use, reproduction and distribution of the work without further permission provided the original work is attributed.

ETHICAL STATEMENT

Ethical approval: All procedures performed in studies involving human participants were in accordance with the ethical standards of the institutional and/or national research committee and with the 1964 Helsinki declaration and its later amendments or comparable ethical standards.

REFERENCES

1. **Basques BA, Bohl DD, Golinvaux NS, Smith BG, Grauer JN.** Patient factors are associated with poor short-term outcomes after posterior fusion for adolescent idiopathic scoliosis. *Clin Orthop Relat Res* 2015;473:286-294.
2. **Murphy RF, Mooney JF III.** Complications following spine fusion for adolescent idiopathic scoliosis. *Curr Rev Musculoskelet Med* 2016;9:462-469.
3. **Coe JD, Arlet V, Donaldson W, et al.** Complications in spinal fusion for adolescent idiopathic scoliosis in the new millennium. A report of the Scoliosis Research Society Morbidity and Mortality Committee. *Spine* 2006;31:345-349.
4. **Reames DL, Smith JS, Fu KM, et al.** Scoliosis Research Society Morbidity and Mortality Committee. Complications in the surgical treatment of 19,360 cases of pediatric scoliosis: a review of the Scoliosis Research Society Morbidity and Mortality database. *Spine* 2011;36:1484-1491.
5. **Lykissas MG, Jain VV, Nathan ST, et al.** Mid- to long-term outcomes in adolescent idiopathic scoliosis after instrumented posterior spinal fusion: a meta-analysis. *Spine* 2013;38:E113-E119.
6. **Carreon LY, Puno RM, Lenke LG, et al.** Non-neurologic complications following surgery for adolescent idiopathic scoliosis. *J Bone Joint Surg [Am]* 2007;89:2427-2432.
7. **Martin CT, Pugely AJ, Gao Y, Weinstein SL.** Causes and risk factors for 30-day unplanned readmissions after pediatric spinal deformity surgery. *Spine* 2015;40:238-246.
8. **Richards BR, Emara KM.** Delayed infections after posterior TSRH spinal instrumentation for idiopathic scoliosis: revisited. *Spine* 2001;26:1990-1996.
9. **Richards BS.** Delayed infections following posterior spinal instrumentation for the treatment of idiopathic scoliosis. *J Bone Joint Surg [Am]* 1995;77:524-529.
10. **Viola RW, King HA, Adler SM, et al.** Delayed infection after elective spinal instrumentation and fusion. A retrospective analysis of eight cases. *Spine (Phila Pa 1976)* 1997;22:2444-2451.
11. **Ho C, Sucato DJ, Richards BS.** Risk factors for the development of delayed infections following posterior spinal fusion and instrumentation in adolescent idiopathic scoliosis patients. *Spine* 2007;32:2272-2277.

12. **Clark CE, Shufflebarger HL.** Late-developing infection in instrumented idiopathic scoliosis. *Spine* 1999;24:1909-1912.
13. **Di Silvestre M, Bakaloudis G, Lolli F, Giacomini S.** Late-developing infection following posterior fusion for adolescent idiopathic scoliosis. *Eur Spine J* 2011;20:S121-S127.
14. **Warner SJ, Uppstrom TJ, Miller AO, et al.** Epidemiology of deep surgical site infections after pediatric spinal fusion surgery. *Spine* 2017;42:E163-E168.
15. **Linam WM, Margolis PA, Staat MA, et al.** Risk factors associated with surgical site infection after pediatric posterior spinal fusion procedure. *Infect Control Hosp Epidemiol* 2009;30:109-116.
16. **Aleissa S, Parsons D, Grant J, Harder J, Howard J.** Deep wound infection following pediatric scoliosis surgery: incidence and analysis of risk factors. *Can J Surg* 2011;54:263-269.
17. **Myung KS, Glassman DM, Tolo VT, Skaggs DL.** Simple steps to minimize spine infections in adolescent idiopathic scoliosis. *J Pediatr Orthop* 2014;34:29-33.
18. **Sweet FA, Roh M, Sliva C.** Intrawound application of vancomycin for prophylaxis in instrumented thoracolumbar fusions: efficacy, drug levels, and patient outcomes. *Spine* 2011;36:2084-2088.
19. **Nisbet M, Briggs S, Ellis-Pegler R, Thomas M, Holland D.** Propionibacterium acnes: an under-appreciated cause of post-neurosurgical infection. *J Antimicrob Chemother* 2007;60:1097-1103.
20. **Rihn JA, Lee JY, Ward WT.** Infection after the surgical treatment of adolescent idiopathic scoliosis: evaluation of the diagnosis, treatment, and impact on clinical outcomes. *Spine* 2008;33:289-294.
21. **Viraraghavan R, Jantusch B, Campos J.** Late-onset central nervous system shunt infections with Propionibacterium acnes: diagnosis and management. *Clin Pediatr (Phila)* 2004;43:393-397.
22. **Grice EA, Segre JA.** The skin microbiome. *Nat Rev Microbiol* 2011;9:244-253.
23. **Oh J, Byrd AL, Deming C, et al.** NISC Comparative Sequencing Program. Biogeography and individuality shape function in the human skin metagenome. *Nature* 2014;514:59-64.
24. **Roth RR, James WD.** Microbial ecology of the skin. *Annu Rev Microbiol* 1988;42:441-464.
25. **Hsu JE, Bumgarner RE, Matsen FA III.** Propionibacterium in shoulder arthroplasty: what we think we know today. *J Bone Joint Surg [Am]* 2016;98:597-606.
26. **Amin K, Riddle CC, Aires DJ, Schweiger ES.** Common and alternate oral antibiotic therapies for acne vulgaris: a review. *J Drugs Dermatol* 2007;6:873-880.
27. **Saltzman MD, Nuber GW, Gryzlo SM, Marecek GS, Koh JL.** Efficacy of surgical preparation solutions in shoulder surgery. *J Bone Joint Surg [Am]* 2009;91:1949-1953.
28. **Pottinger P, Butler-Wu S, Neradilek MB, et al.** Prognostic factors for bacterial cultures positive for Propionibacterium acnes and other organisms in a large series of revision shoulder arthroplasties performed for stiffness, pain, or loosening. *J Bone Joint Surg [Am]* 2012;94-A:2075-2083.
29. **Shiono Y, Ishii K, Nagai S, et al.** Delayed propionibacterium acnes surgical site infections occur only in the presence of an implant. *Sci Rep* 2016;6:32758.
30. **Lee MJ, Pottinger PS, Butler-Wu S, et al.** Propionibacterium persists in the skin despite standard surgical preparation. *J Bone Joint Surg [Am]* 2014;96:1447-1450.
31. **Matsen FA III, Butler-Wu S, Carofino BC, et al.** Origin of propionibacterium in surgical wounds and evidence-based approach for culturing propionibacterium from surgical sites. *J Bone Joint Surg [Am]* 2013;95:e1811-e1817.
32. **Nandyala SV, Schwend RM.** Prevalence of intraoperative tissue bacterial contamination in posterior pediatric spinal deformity surgery. *Spine* 2013;38:E482-E486.
33. **Soultanis KC, Pyrovolou N, Zahos KA, et al.** Late postoperative infection following spinal instrumentation: stainless steel versus titanium implants. *J Surg Orthop Adv* 2008;17:193-199.
34. **Sheehan EPJ.** Blood transfusions can increase the risk of infection in orthopedic patients. <http://www.healio.com/orthopedics/infection/news/print/orthopedics-today/%7Bd4d3445c-8422-4d69-bfoo-ea735938c461%7D/blood-transfusions-can-increase-the-risk-of-infection-in-orthopedic-patients> (date last accessed 04 April 2017).
35. **Subramanyam R, Schaffzin J, Cudilo EM, Rao MB, Varughese AM.** Systematic review of risk factors for surgical site infection in pediatric scoliosis surgery. *Spine J* 2015;15:1422-1431.
36. **Chaudhary SB, Vives MJ, Basra SK, Reiter MF.** Postoperative spinal wound infections and postprocedural diskitis. *J Spinal Cord Med* 2007;30:441-451.
37. **Bose B.** Delayed infection after instrumented spine surgery: case reports and review of the literature. *Spine J* 2003;3:394-399.
38. **Collins I, Wilson-MacDonald J, Chami G, et al.** The diagnosis and management of infection following instrumented spinal fusion. *Eur Spine J* 2008;17:445-450.
39. **Luzzati R, Giacomazzi D, Danzi MC, et al.** Diagnosis, management and outcome of clinically-suspected spinal infection. *J Infect* 2009;58:259-265.
40. **Gristina AG, Costerton JW.** Bacterial adherence to biomaterials and tissue. The significance of its role in clinical sepsis. *J Bone Joint Surg [Am]* 1985;67:264-273.
41. **Howlin RP, Winnard C, Angus EM, et al.** Prevention of Propionibacterium acnes biofilm formation in prosthetic infections in vitro. *J Shoulder Elbow Surg* 2017;26:553-563.
42. **Saper D, Capiro N, Ma R, Li X.** Management of Propionibacterium acnes infection after shoulder surgery. *Curr Rev Musculoskelet Med* 2015;8:67-74.
43. **Lorenzetti AJ, Wongworawat MD, Jobe CM, Phipatanakul WP.** Cyanoacrylate microbial sealant may reduce the prevalence of positive cultures in revision shoulder arthroplasty. *Clin Orthop Relat Res* 2013;471:3225-3229.
44. **Furustrand Tabin U, Corvec S, Betrisey B, Zimmerli W, Trampuz A.** Role of rifampin against Propionibacterium acnes biofilm in vitro and in an experimental foreign-body infection model. *Antimicrob Agents Chemother* 2012;56:1885-1891.