

UC Davis

UC Davis Previously Published Works

Title

Dental and Temporomandibular Joint Pathology of the Kit Fox (*Vulpes macrotis*).

Permalink

<https://escholarship.org/uc/item/94398767>

Authors

Yanagisawa, N

Wilson, RE

Kass, PH

et al.

Publication Date

2019-02-01

DOI

10.1016/j.jcpa.2019.01.001

Peer reviewed



DISEASE IN WILDLIFE OR EXOTIC SPECIES

Dental and Temporomandibular Joint Pathology of the Kit Fox (*Vulpes macrotis*)

N. Yanagisawa^{*}, R. E. Wilson^{*}, P. H. Kass[†] and F. J. M. Verstraete^{*}

^{*} Department of Surgical and Radiological Sciences and [†] Department of Population Health and Reproduction, School of Veterinary Medicine, University of California, Davis, California, USA

Summary

Skull specimens from 836 kit foxes (*Vulpes macrotis*) were examined macroscopically according to predefined criteria; 559 specimens were included in this study. The study group consisted of 248 (44.4%) females, 267 (47.8%) males and 44 (7.9%) specimens of unknown sex; 128 (22.9%) skulls were from young adults and 431 (77.1%) were from adults. Of the 23,478 possible teeth, 21,883 teeth (93.2%) were present for examination, 45 (1.9%) were absent congenitally, 405 (1.7%) were acquired losses and 1,145 (4.9%) were missing artefactually. No persistent deciduous teeth were observed. Eight (0.04%) supernumerary teeth were found in seven (1.3%) specimens and 13 (0.06%) teeth from 12 (2.1%) specimens were malformed. Root number variation was present in 20.3% (403/1,984) of the present maxillary and mandibular first premolar teeth. Eleven (2.0%) foxes had lesions consistent with enamel hypoplasia and 77 (13.8%) had fenestrations in the maxillary alveolar bone. Periodontitis and attrition/abrasion affected the majority of foxes (71.6% and 90.5%, respectively). Nine-hundred and fifty-eight (4.4%) teeth were fractured, a large proportion (41.8%) of which were characterized as complicated crown fractures. Sixty-six periapical lesions from 52 (9.3%) skulls were found. A considerable portion of foxes (5.9%) showed evidence of low-grade temporomandibular joint osteoarthritis. Overall, kit foxes share dental pathology similar to that of the grey fox (*Urocyon cinereoargenteus*).

© 2019 Elsevier Ltd. All rights reserved.

Keywords: dental pathology; kit fox; temporomandibular joint pathology; *Vulpes macrotis*

Introduction

The kit fox (*Vulpes macrotis*) is an arid land fox found in the southwestern USA and extending into northern Mexico (Clark, 2011). Averaging 2.3 kg in weight for males and 2.1 kg for females, the kit fox is the smallest canid found in North America (US Fish and Wildlife Service, 1998). Individuals reach sexual maturity at 1 year and will usually have their first litters during their second year of adulthood. Reproduction of this species is highly dependent on prey abundance and therefore on annual rainfall (US Fish and Wildlife Service, 1998). The kit fox predated primarily on small mammals, ground-nesting birds, insects and reptiles (Clark, 2011). Rodents such as

kangaroo rats (*Dipodomys* spp.) and ground squirrels (*Xerinae* spp.) are of particular preference (Cypher and List, 2014). Significant sources of mortality of kit foxes are predation by coyotes (*Canis latrans*) and red foxes (*Vulpes vulpes*), as well as vehicular accidents and rodenticide ingestion (Meaney et al., 2006).

According to the International Union for Conservation of Nature (IUCN), subspecific classification of *V. macrotis* has yet to be agreed on, with some sources classifying up to eight subspecies (Cypher and List, 2014). However, due to the geographical isolation and distinct population of kit foxes inhabiting the San Joaquin Valley of California, the San Joaquin kit fox (*V. macrotis mutica*) has remained a subspecific classification that has withstood conflicting opinions, while other subspecies have been grouped together

Correspondence to: F.J.M. Verstraete (e-mail: fjverstraete@ucdavis.edu).

under the name *V. macrotis macrotis* (Cypher and List, 2014).

While *V. macrotis* as a species is considered of ‘least concern’ by the IUCN, *V. m. mutica* is recognized federally by the US Fish and Wildlife Service (USFWS) as an endangered species and as a threatened species by the state of California (US Fish and Wildlife Service, 1998). Although the kit fox has little direct economic value, this animal holds a central niche in local food webs as a predator, prey animal and competitor for territorial and food resources (Meaney *et al.*, 2006). The USFWS analysed this central importance in its 1998 recovery plan for the San Joaquin Valley, recognizing *V. m. mutica* as an ‘umbrella species’ whose protection efforts will indirectly protect many other species (US Fish and Wildlife Service, 1998).

As with other canids, the dental formula of *V. macrotis* is I 3/3, C 1/1, P 4/4, M 2/3, totalling 42 permanent teeth (Fig. 1). To date, there have been no studies on dental pathology in *V. macrotis*. Most studies regarding this species delve into the ecology and behaviour of the animal, as well as the effects of urbanization on the species (Koopman *et al.*, 1999; Meaney *et al.*, 2006). While urbanization and

climate change pose the biggest threat to *V. macrotis*, continual decline in the population size of the endangered *V. m. mutica* increases the importance of evaluating all possible contributing factors to the survivability of the animal (US Fish and Wildlife Service, 1998). With the accumulation of comparative dental pathology studies, dialogue can be broadened to the role of oral health in the mortality and morbidity of wildlife. The aim of this study was to evaluate dental pathology in the kit fox, determining what diseases occur in this species and in what frequency.

Materials and Methods

Of the 836 kit fox skeletal specimens at the Museum of Vertebrate Zoology, University of California, Berkeley (MVZ), 559 skulls were examined macroscopically for this study; the remaining 277 were excluded because these specimens were either partial or juvenile (i.e. having mixed deciduous and permanent dentition). Study subjects were categorized as either ‘young adult’ or ‘adult’ based on the prominence of cranial sutures, with a particular focus on the basisphenoid–basioccipital suture, which has

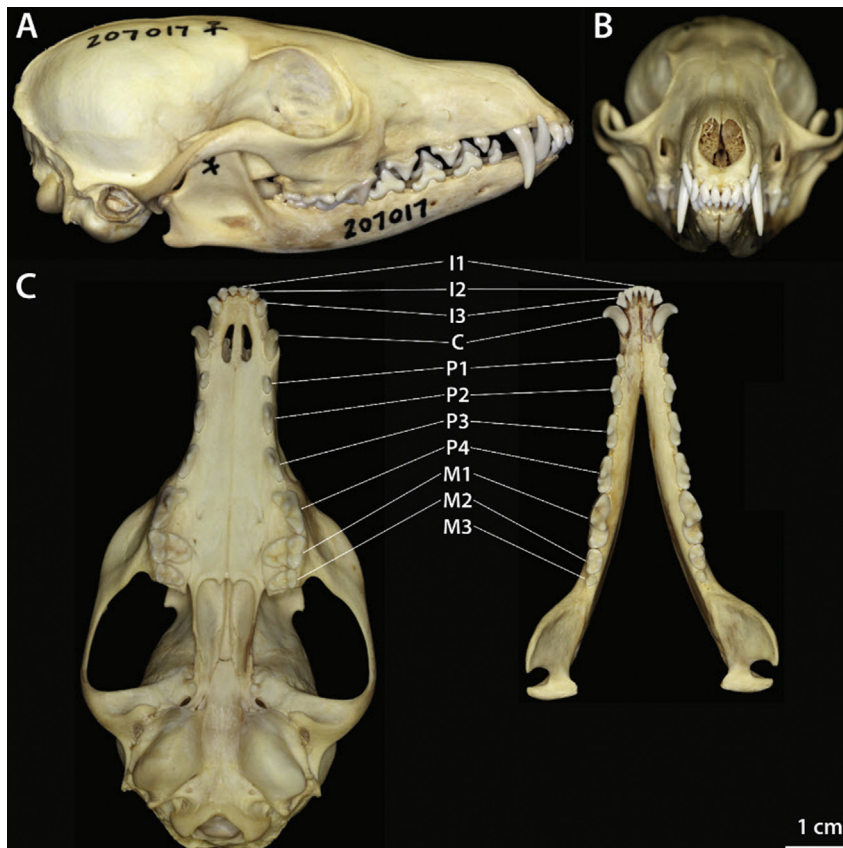


Fig. 1. (A–C) Representative dentition of a young adult kit fox (MVZ 207017).

previously been used as a determinant of adult age (Waithman and Roest, 1977). Any additional known information (collection date and location, subspecies) was also recorded for analysis.

Specimens were evaluated systematically for abnormalities using previously determined criteria (Table 1). This method has proven to be efficient and effective at consistently detecting signs of dental pathology and other osteological abnormalities such as temporomandibular osteoarthritis in other mammalian carnivores (Aalderink *et al.*, 2015; Aghashani *et al.*, 2016; Clark *et al.*, 2017; Doring *et al.*, 2018; Evenhuis *et al.*, 2018). Presence of teeth

was recorded and any missing teeth were categorized as artefactual loss, congenital absence or acquired loss. Lack of alveoli without any signs of osseous remodelling was considered congenital absence, while empty alveoli with clean, well-defined edges were considered to represent artefactual loss *post mortem*. Acquired loss was defined as ante-mortem loss of a tooth with evidence of pathological change to the empty alveolus.

All present teeth and surrounding bone were then assessed for congenital and developmental abnormalities, including supernumerary teeth, persistent deciduous teeth, aberrant root numbers, malformed crowns,

Table 1
Inclusion criteria of congenital, developmental and acquired abnormalities

<i>Observation</i>	<i>Criteria</i>
Tooth absent artefactually	Jaw fragment missing or tooth absent, but a well-defined, sharp-edged, normally shaped, empty alveolus present; tooth presumed lost during preparation or post-mortem manipulation of the skull
Tooth absent – presumably congenital	Tooth and alveolus absent; smooth, morphologically normal bone present at the site; no physical space for that tooth to have occupied
Tooth absent – presumably acquired	Tooth absent; alveolus or remnant alveolus visible; alveolar bone shows pathological signs (i.e. rounding of the alveolar margin, shallow alveolus, periosteal reaction on alveolar bone, increased vascular foramina)
Persistent deciduous tooth	A persistent deciduous tooth adjacent to an erupted or unerupted permanent tooth
Supernumerary tooth	Presence of a supernumerary tooth adjacent to an expected tooth (or alveolus)
Malformed tooth	Presence of an abnormally shaped crown
Number of roots	The number of roots, inspected directly or inferred from an empty alveolus or from the portion of root(s) visible within the alveolus (if the tooth is glued in place)
Enamel hypoplasia	Irregular pitting or a band-shaped absence or thinning of the enamel, consistent with the clinical signs of enamel hypoplasia
Fenestration	Lack of buccal/labial or palatal/lingual alveolar bone, which results in exposure of the root surface
Periodontitis stage 2	Evidence of increased vascularity at the alveolar margin (more prominent vascular foramina in and slightly rougher texture of; the bone of the alveolar margin); <25% alveolar bone loss
Periodontitis stage 3	Rounding of the alveolar margin; moderate (25–50%) horizontal or vertical bone loss and/or furcation involvement
Periodontitis stage 4	Widening of the periodontal space; severe (>50%) horizontal or vertical bone loss and/or furcation exposure (through-and-through)
Attrition/abrasion stage 1	Mild wear of enamel, without dentine exposure
Attrition/abrasion stage 2	Exposure of dentine on the cuspal tip, without tertiary dentine formation
Attrition/abrasion stage 3	Exposure of dentine on the cuspal tip, with tertiary dentine formation
Attrition/abrasion stage 4	Pulp cavity exposure secondary to attrition/abrasion
Uncomplicated crown fracture	A fracture involving enamel and dentine, but not exposing the pulp
Complicated crown fracture	A fracture involving enamel and dentine, with pulp exposure
Uncomplicated crown–root fracture	A fracture involving enamel, dentine and cementum, but not exposing the pulp
Complicated crown–root fracture	A fracture involving enamel, dentine and cementum, with pulp exposure
Root fracture	A fracture affecting dentine, cementum and the pulp
Periapical lesion	Macroscopically visible periapical bone loss, root tip resorption, sinus tract formation originating periapically or obvious focal periosteal reaction overlying the apex
Mild TMJ osteoarthritis	Early periarticular new bone formation/osteophytes and/or minimal subchondral bone change; mandibular head or fossa affected, but not both
Moderate TMJ osteoarthritis	Periarticular new bone formation and/or subchondral bone changes; mandibular head and/or fossa affected
Severe TMJ osteoarthritis	All previously described signs are present and more pronounced; subchondral bone lysis present; both mandibular head and fossa affected

TMJ, temporomandibular joint.

enamel hypoplasia and fenestrations in alveolar bone. Fenestrations were defined as lack of bone resulting in a window exposing the root; locations of these fenestrations were also noted (i.e. mesial versus distal root and lingual versus palatal side). Additionally, specimens were examined for acquired pathological abnormalities. Periodontal staging of individual teeth was performed using the classification system adapted for dry skulls (Verstraete *et al.*, 1996). Periodontitis stage 1 refers to gingivitis, which cannot be determined on a skull specimen and was therefore excluded. Stage 2 was defined as increased vascularity around the alveolar margin and/or <25% loss of the surrounding alveolar bone. Stage 3 was defined as rounding of the alveolar margin with 25–50% horizontal or vertical bone loss and/or involvement of the root furcation. Finally, stage 4 indicated widening of the alveolar margin with >50% loss of the alveolar bone and/or through-and-through furcation exposure.

Although abrasion and attrition result from distinct causes, these cannot be differentiated on skull specimens; therefore, these were categorized together and staged according to a four-point severity scale. Stage 1 shows wear of the cuspal enamel without dentine exposure. Stage 2 and stage 3 both show dentine exposure, with tertiary dentine formation in stage 3. Finally, stage 4 shows pulp cavity exposure. Fractures were differentiated according to the World Health Organization classification of human dental fractures, as modified for carnivores (Verstraete, 2003). Care was taken to exclude any artefactual fractures, which occurred at physiologically impossible angles and/or had sharp edges, indicative of post-mortem change. Fracture types included crown fractures (i.e. fracture line involvement of dentine and enamel only), crown–root fractures (i.e. involvement of dentine, enamel and cementum) and root fractures (i.e. involvement of dentine and cementum only, with no crown enamel present). These were further classified as either uncomplicated (i.e. no pulp exposure) or complicated (i.e. pulp exposure). Periapical lesions, defined as osseous remodelling of the bone surrounding the apex of a tooth with pulp cavity exposure, were also documented.

The temporomandibular joint (TMJ) was evaluated for signs of osteoarthritis. The mandibular heads (condylar processes of the mandible) and mandibular fossae were inspected for changes, such as osteophyte formation and subchondral bone change (including lesions consistent with osteochondrosis dissecans [OCD]). Joints were only considered if both the head and fossa were present and complete. Each affected joint was then scored on a semisubjective scale of mild (i.e. early signs of osteophyte formation and/or minimal subchondral bone change on either

the mandibular head or fossa, but not both), moderate (i.e. periarticular new bone formation and/or subchondral bone change on the mandibular head and/or fossa) or severe (i.e. pronounced periarticular bone formation and/or subchondral bone change on both the mandibular head and fossa).

Missing teeth were not included in the calculations for the prevalence of these abnormalities. Teeth were pooled according to tooth type to compare relative prevalence of congenital absences, acquired losses, periodontitis, fractures and attrition/abrasion using mixed effects logistic regression; teeth were nested within the skull, with an individual skull serving as the random effect. Prevalences of each abnormality were analysed for associations with sex, age, subspecies and decade of collection with univariate logistic regression, using female as the reference for sex, young adult for age, *V. m. mutica* for subspecies and the 1980s for decade. Results are presented as prevalence odds ratios and 95% confidence intervals (CI).

Results

Of the 836 kit fox skeletal specimens available in the museum collection, 559 had adult dentition that was complete enough for examination and inclusion in the study (see Supplementary Data for complete list of specimens included). Specimen collection dates ranged from 1903 to 2014. The study group consisted of 128 (22.9%) young adults and 431 (77.1%) adults. The sex representation was roughly even with 248 (44.4%) females, 267 (47.8%) males and 44 (7.9%) specimens of unknown sex. The majority of the study group ($n = 491$, 87.8%) was of the subspecies *V. m. mutica*. The remaining specimens were of *V. m. arsipus* ($n = 45$, 8.1%), *V. m. nevadensis* ($n = 15$, 2.7%), *V. m. velox* ($n = 4$, 0.7%), *V. m. neomexicana* ($n = 3$, 0.5%) and *V. m. zinzeri* ($n = 1$, 0.2%); as per the IUCN, these specimens were pooled together under *V. m. mutica* ($n = 68$, 12.2%) for statistical analysis. Specimens were collected from California, New Mexico, Nevada, Utah, Texas, Arizona and northern Mexico; location generally correlated with subspecies and was therefore not analysed separately. Association with age, sex, subspecies and decade is reported only when statistically significant; tooth type comparisons are also only reported when statistically significant.

Presence of Teeth

Only 78 (13.6%) skulls had all teeth present. In total, 21,883 teeth (93.2% of the maximum possible number (23,478)) were present for evaluation. Of all potential teeth, 45 (0.2%) were absent congenitally, 405 (1.7%) were acquired losses and 1,145 (4.9%) were

missing artefactually. Of the congenitally absent teeth, 24 (53.3%) were molar teeth, 11 (24.4%) were premolar teeth, nine (20.0%) were incisor teeth and one (2.2%) was a canine tooth. When compared against the maximum possible corresponding teeth, molar teeth were the most often absent congenitally (0.4%), followed by incisor teeth and premolar teeth (each 0.1%). The prevalence odds of congenital absence of molar teeth was 3.2 times the prevalence odds of congenital absence of incisor teeth (95% CI [1.5, 6.9]). Of note, mandibular third molar teeth represented 53.3% ($n = 24$) of all congenital absences, affecting 2.1% of all potential mandibular third molar teeth. Specimens collected during the 1990s and 2000s had a higher prevalence of congenital absences when compared with those collected during the 1980s (prevalence odds ratio = 3.5 and 3.6, respectively; 95% CI [1.2, 9.6] and [1.3, 10.0], respectively).

Of the acquired tooth losses, 229 (56.6%) were premolar teeth, 100 (24.7%) were incisor teeth, 49 (12.1%) were molar teeth and 27 (6.7%) were canine teeth. Based on the number of corresponding teeth present, premolar teeth were the most often lost *ante mortem* (2.6%), followed by incisor teeth (1.5%), canine teeth (1.2%) and molar teeth (0.9%). Of these, acquired premolar tooth loss was significantly higher (prevalence odds ratio = 1.7, 95% CI [0.6, 1.4]) and acquired

molar tooth loss was significantly lower (prevalence odds ratio = 0.5, 95% CI [0.4, 0.8]) than that of incisor teeth. Adult age was significantly associated with an increased prevalence of acquired tooth loss (prevalence odds ratio = 14.0, 95% CI [6.0, 32.6]). Specimens collected during the 1930s had a lower prevalence of acquired losses than those from the 1980s (prevalence odds ratio = 0.4, 95% CI [0.2, 0.9]).

Persistent Deciduous Teeth

None of the specimens displayed persistent deciduous teeth.

Supernumerary Teeth

Eight (0.04%) supernumerary teeth were found in seven (1.3%) specimens (Fig. 2). The maxillary third premolar tooth was the most common site to have an associated supernumerary tooth ($n = 5$, 62.5%). One supernumerary tooth was found at the right maxillary third incisor and another specimen had bilateral supernumerary maxillary fourth premolar teeth.

Tooth Form

Thirteen (0.06%) teeth from 12 (2.1%) specimens were malformed. Of these, the most common

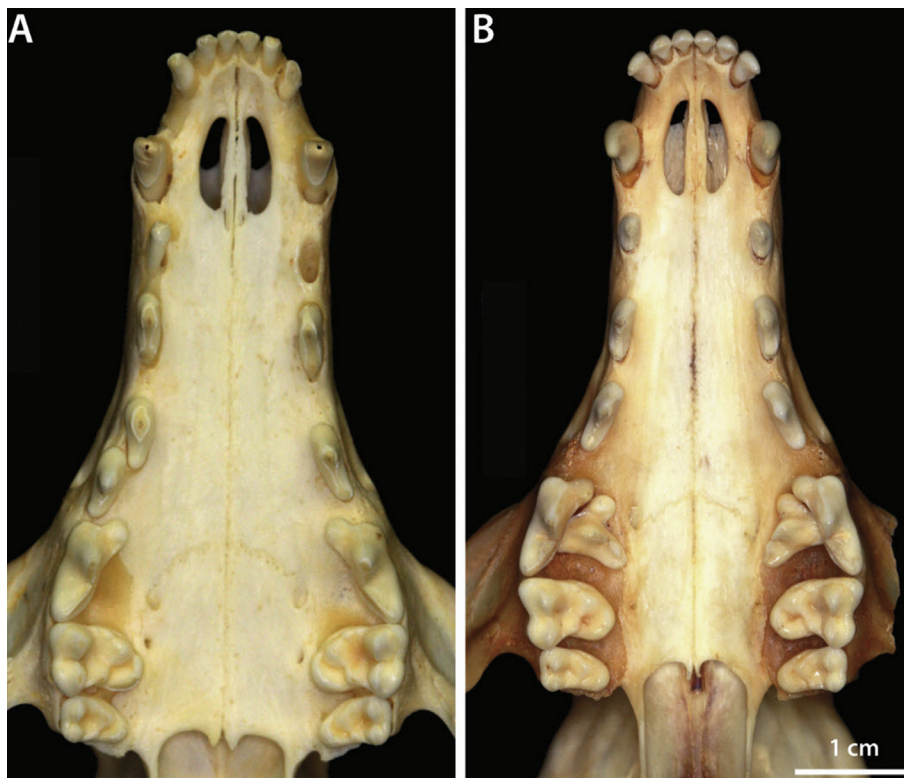


Fig. 2. Supernumerary tooth associated with (A) the right maxillary third premolar tooth (MVZ 195427) and (B) the left and right maxillary fourth premolar teeth (MVZ 61938).

malformation was the presence of an accessory cusp, with five (38.5%) teeth exhibiting an extra cusp in varying locations. The only specimen with more than one malformed tooth had an accessory cusp on each of its maxillary first molars. Of the remaining malformed teeth, three (23.1%) were microdont, one (7.7%) was macrodont, one (7.7%) was odontodysplastic and two (15.4%) exhibited bigeminy. The two cases of bigeminy were both concluded to be the fusion of the maxillary third premolar tooth and an adjacent supernumerary tooth, resulting in a single tooth with two cusps and three roots (Fig. 3A).

Root Number Variation

Root number variation was found to be fairly common amongst the maxillary and mandibular first premolar teeth. Of the 1,984 first premolar teeth present, 403 (20.3%) were found to have a pseudo-double root; to be counted, they had to exhibit a groove extending down the visible portion of the root and evidence of an additional alveolus forming (Fig. 3B). Two-hundred and eight (37.2%) skulls exhibited at least one double-rooted first premolar tooth. None of these first premolar teeth showed a complete separation of the root. One first premolar tooth that

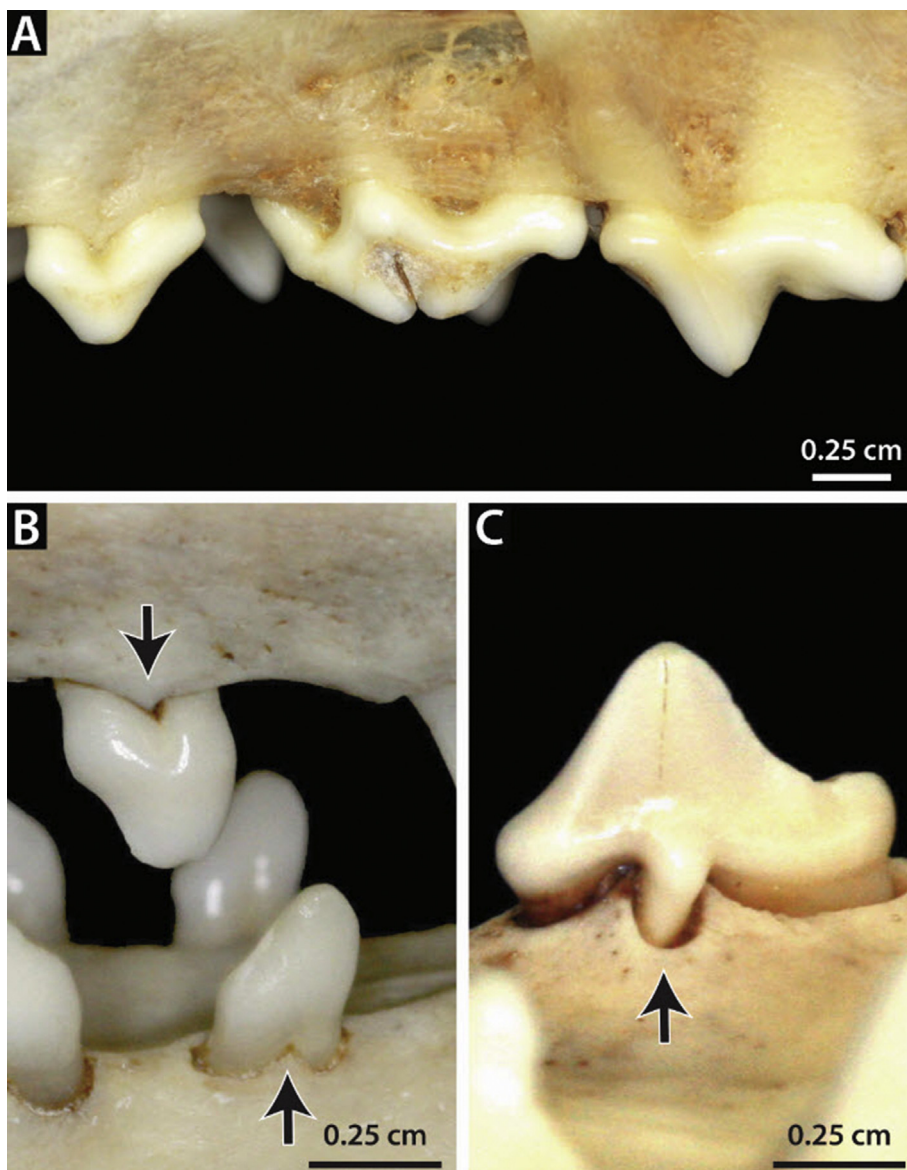


Fig. 3. (A) Malformed left maxillary third premolar tooth (bigeminy) (MVZ 195384). Extra roots associated with (B) the right maxillary and mandibular first premolar teeth (MVZ 229717) and (C) the left maxillary third premolar tooth (MVZ 195447).

exhibited the double root also had an additional root on the lingual side, totalling three roots. Double-rooted first premolar teeth were less prevalent in adults than in young adults (prevalence odds ratio = 0.5, 95% CI [0.3, 0.7]) and more commonly found in *V. m. macrotis* specimens than in *V. m. mutica* specimens (prevalence odds ratio = 2.7, 95% CI [1.6, 4.6]). Specimens collected during the 1910s and 1930s had higher prevalence of double-rooted first premolar teeth compared with those from the 1980s (prevalence odds ratio = 7.1 and 3.6, respectively; 95% CI [1.4, 34.8] and [1.8, 7.3], respectively). Additionally, 14 (0.06%) teeth from 10 (1.8%) specimens displayed an excess root in other teeth; five maxillary second premolar teeth, eight maxillary third premolar teeth and one mandibular second premolar tooth had an additional root in between the normal mesial and distal roots (Fig. 3C).

Enamel Hypoplasia

Twelve (0.05%) teeth in 11 (2.0%) specimens were found to have lesions consistent with enamel hypoplasia. All lesions were focal lesions with diameters ≤ 1 mm. One specimen showed multifocal lesions of varying sizes (≤ 1 mm) around the mesial and lingual aspects of the maxillary fourth premolar tooth. Prevalence of enamel hypoplasia was higher in specimens collected during the 1940s when compared with those from the 1980s (prevalence odds ratio = 22.1, 95% CI [3.4, 144.8]).

Fenestration

Seventy-seven (13.8%) foxes had fenestrations in the maxillary alveolar bone, affecting 109 (0.5%) teeth (Fig. 4). The most commonly affected tooth was the maxillary fourth premolar tooth ($n = 80$, 73.4%), followed by the maxillary first molar tooth ($n = 29$, 26.6%). Fenestrations were usually found at the mesiobuccal root of the tooth, accounting for 100

(91.7%) of the fenestrations. Five (4.6%) of the teeth had fenestrations at the distobuccal root and four (3.7%) at both mesiobuccal and distobuccal roots. Fenestrations were twice as prevalent in males than in females (prevalence odds ratio = 2.0, 95% CI [1.2, 3.3]). Prevalence of fenestrations was significantly higher in specimens collected during the 2000s compared with those from the 1980s (prevalence odds ratio = 5.0, 95% CI [2.6, 9.8]).

Periodontitis

Four hundred (71.6%) foxes displayed evidence of periodontitis of any stage, affecting 2,824 (12.9%) teeth; of these, 74.2% ($n = 2,096$) were consistent with stage 2 periodontitis, 20.3% ($n = 574$) with stage 3 and 5.4% ($n = 154$) with stage 4 (Fig. 5). Adult age was significantly associated with an increased prevalence of periodontitis of any stage (prevalence odds ratio = 8.6, 95% CI [5.6, 13.4]) compared with young age. Of all the teeth affected by periodontitis of any stage, 1,712 (60.6%) were incisor teeth, 626 (22.2%) were premolar teeth, 251 (8.9%) were molar teeth and 235 (8.3%) were canine teeth. Based on the number of corresponding teeth present, incisor teeth were significantly more affected than any other tooth type (27.6%); 12.9% of canine teeth were affected by periodontitis, 7.3% of premolar teeth were affected and 4.8% of molar teeth were affected (prevalence odds ratios relative to incisor teeth = 0.25, 95% CI [0.21, 0.30]; 0.11, 95% CI [0.099, 0.13]; and 0.061, 95% CI [0.052, 0.072], respectively). Specimens collected during the 1930s had a higher prevalence of periodontitis of any stage compared with those collected during the 1980s (prevalence odds ratio = 2.9, 95% CI [1.2, 7.1]).

Attrition and Abrasion

Attrition or abrasion was observed on 11,379 (52.0%) teeth in 506 (90.5%) specimens; 17.9% ($n = 2,033$) of

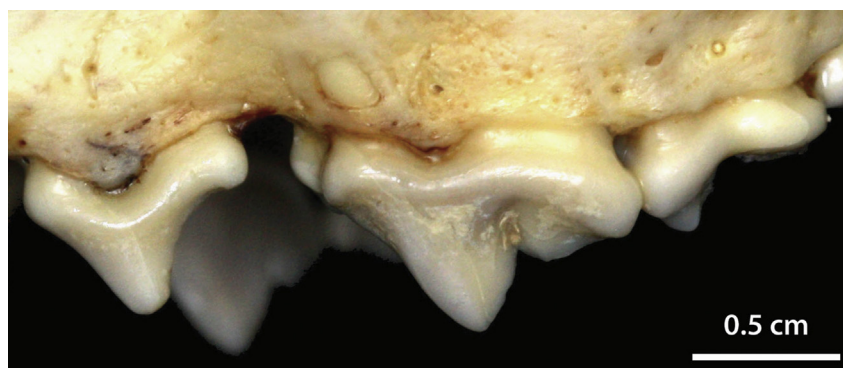


Fig. 4. Fenestration of the mesiobuccal root of the left maxillary fourth premolar tooth (MVZ 195555).

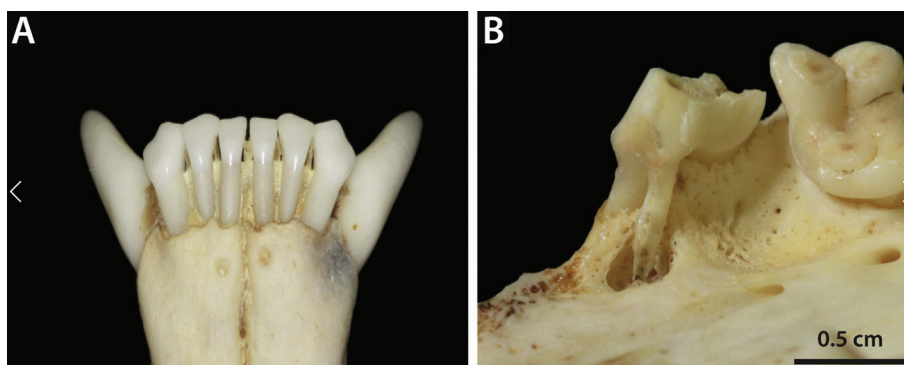


Fig. 5. (A) The mandibular incisor teeth with periodontitis stage 2 (MVZ 229722). (B) Periodontitis stage 4 of the left maxillary fourth premolar tooth (MVZ 195536).

the affected teeth were consistent with stage 1 attrition/abrasion, 51.5% ($n = 5,860$) with stage 2, 29.6% ($n = 3,369$) with stage 3 and 1.0% ($n = 117$) with stage 4 (Fig. 6). Of the affected teeth, 4,583 (39.9%) were premolar teeth, 3,379 (29.7%) were incisor teeth, 2,991 (26.3%) were molar teeth and 471 (4.1%) were canine teeth. Based on the number of corresponding teeth present, molar teeth were the most affected by attrition/abrasion (56.7%), followed by incisor teeth (54.4%), premolar teeth (52.9%) and canine teeth (25.9%). Of these, the prevalence of attrition/abrasion in canine teeth and premolar teeth was significantly lower when compared with incisor teeth (prevalence odds ratio = 0.1, 95% CI [0.1, 1.2] and 0.9, 95% CI [0.8, 1.0], respectively). The prevalence of attrition/abrasion was significantly higher in adults than young adults (prevalence odds ratio 11.7, 95% CI [6.2, 22.2]) and lower in males than in females (prevalence odds ratio = 0.4, 95% CI [0.2, 0.8]). Specimens collected during the 2000s had a significantly lower prevalence of attrition/abrasion than those from the 1980s (prevalence odds ratio = 0.5, 95% CI [0.2, 1.0]).

Tooth Fractures

Nine-hundred and fifty-eight (4.4%) teeth from 314 (56.2%) specimens were fractured. Of all fractured teeth, complicated crown fractures were most common ($n = 400$, 41.8%), followed by complicated crown–root fractures ($n = 258$, 26.9%), root fractures ($n = 193$, 20.1%), uncomplicated crown fractures ($n = 96$, 10.0%) and uncomplicated crown–root fractures ($n = 11$, 1.1%) (Fig. 7). Four-hundred and forty-seven (46.7%) fractured teeth were premolar teeth, 401 (41.9%) were canine teeth, 61 (6.4%) were incisor teeth and 49 (5.1%) were molar teeth. Based on the number of corresponding teeth present, canine teeth were the most often fractured (22.0%), followed by premolar teeth (5.2%), incisor teeth

(1.0%) and molar teeth (0.9%). Of these, the prevalence of fractures amongst canine teeth and premolar teeth was significantly higher than that of incisor teeth (prevalence odds ratio = 44.2, 95% CI [33.1, 59.0] and 5.7, 95% CI [4.4, 7.4], respectively). Adult age was significantly associated with an increased prevalence of fractures (prevalence odds ratio 25.2, 95% CI [13.1, 48.3]) compared with young age in foxes.

Periapical Lesions

Sixty-six periapical lesions from 52 (9.3%) skulls were found (Fig. 8). Adults had a higher prevalence of periapical lesions than young adults (prevalence odds ratio 3.9, 95% CI [1.3, 11.0]). The prevalence of periapical lesions was higher in specimens collected during the 2010s compared with those from the 1980s (prevalence odds ratio = 17.2, 95% CI [1.5, 196.0]).

Temporomandibular Joint

Of the potential 1,118 TMJs, 1,086 were complete enough for evaluation. Thirty-three (5.9%) specimens showed evidence of TMJ osteoarthritis (TMJ-OA), affecting 40 (3.7%) joints. Seven (1.3%) specimens displayed bilateral TMJ-OA; right and left joints were equally affected. The majority of affected joints ($n = 33$, 82.5%) had mild OA, with only five (12.5%) moderate cases of OA and two (5.0%) severe cases of OA (Figs. 9). One of the two specimens with severe TMJ-OA exhibited similar lesions at various joints throughout its skeleton, consistent with septic polyarthritis (Fig. 9E and F). Lesions were found more commonly on the mandibular heads than the fossae ($n = 37$ and $n = 10$, respectively). The most common location for lesions affecting the mandibular head was the medial aspect of the condylar process ($n = 23$, 62.2%), followed by the lateral aspect

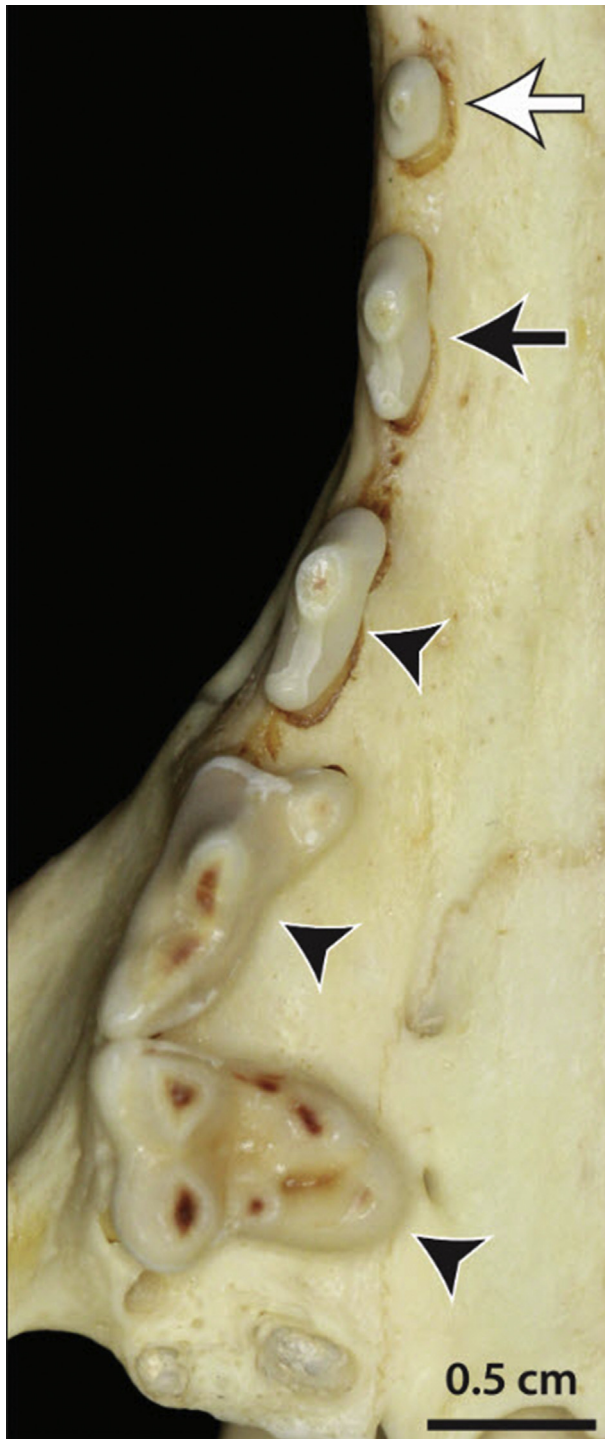

Fig. 6. Attrition/abrasion stage 1 (white arrow), stage 2 (black arrow) and stage 3 (black arrowhead) (MVZ 195786).

($n = 10$, 27.0%); three (8.1%) lesions affected the mandibular head diffusely and one (2.7%) lesion was centrally located. Of the 10 lesions affecting the mandibular fossa, four (40%) were centrally located, five (50%) were medially located and one (10%) affected the fossa diffusely. Seven (17.5%) affected

joints exhibited OCD-type lesions, occurring on four fossae and three heads. The prevalence of TMJ-OA was significantly higher in adults than in young adults (prevalence odds ratio = 10.9, 95% CI [1.5, 80.2]).

Trauma

Two hundred (37.7%) specimens showed evidence of traumatic skull injuries that were likely the cause of the animal's death. While the aetiologies of some of these injuries were known from cause-of-death notes on specimen identification tags, the causes of most injuries were unknown. Some specimens had distinct puncture wounds that were indicative of bite wounds, while others had shattered crania indicative of vehicular accidents. Additionally, 35 (6.3%) skulls had broken tympanic bullae and/or zygomatic arches with no other fractures; these lesions were particularly difficult to differentiate as occurring *post mortem* or *ante mortem*. Only twelve (6.0%) of the skull injuries showed evidence of healing (Fig. 10).

Discussion

Investigation of prevalence and characteristics of dental pathology in kit foxes was accomplished using a museum collection of skulls. The most prevalent congenital/developmental abnormality was tooth root variation, specifically that of the maxillary and mandibular first premolar teeth. This abnormality was also the only one that showed significantly different prevalence between the two subspecies, with *V. m. macrotis* being 2.7 times more likely to have the variation (95% CI [1.6, 4.6]). The aetiology is likely genetic, and it can be speculated that the mutation responsible for the change is less frequently expressed in *V. m. mutica*.

Acquired lesions were more common than congenital/developmental abnormalities. Adult age was associated with higher prevalence of acquired tooth loss, periodontitis, fractures, attrition/abrasion, periapical lesions and TMJ-OA when compared with young adult age; these associations are to be expected because as an animal ages, the likelihood of it developing one of these acquired lesions increases. As with the grey fox (*Urocyon cinereoargenteus*), the most common pathology was attrition/abrasion, affecting 90.5% of foxes and a total of 52.0% of all teeth present (Evenhuis *et al.*, 2018). The *U. cinereoargenteus* study showed that attrition/abrasion affected 85.6% of specimens and 47.1% of teeth; this difference could reflect a difference in behaviour or diet between the two species. Because *U. cinereoargenteus* are more opportunistic in their feeding behaviour, they have a higher tendency towards an omnivorous diet; given

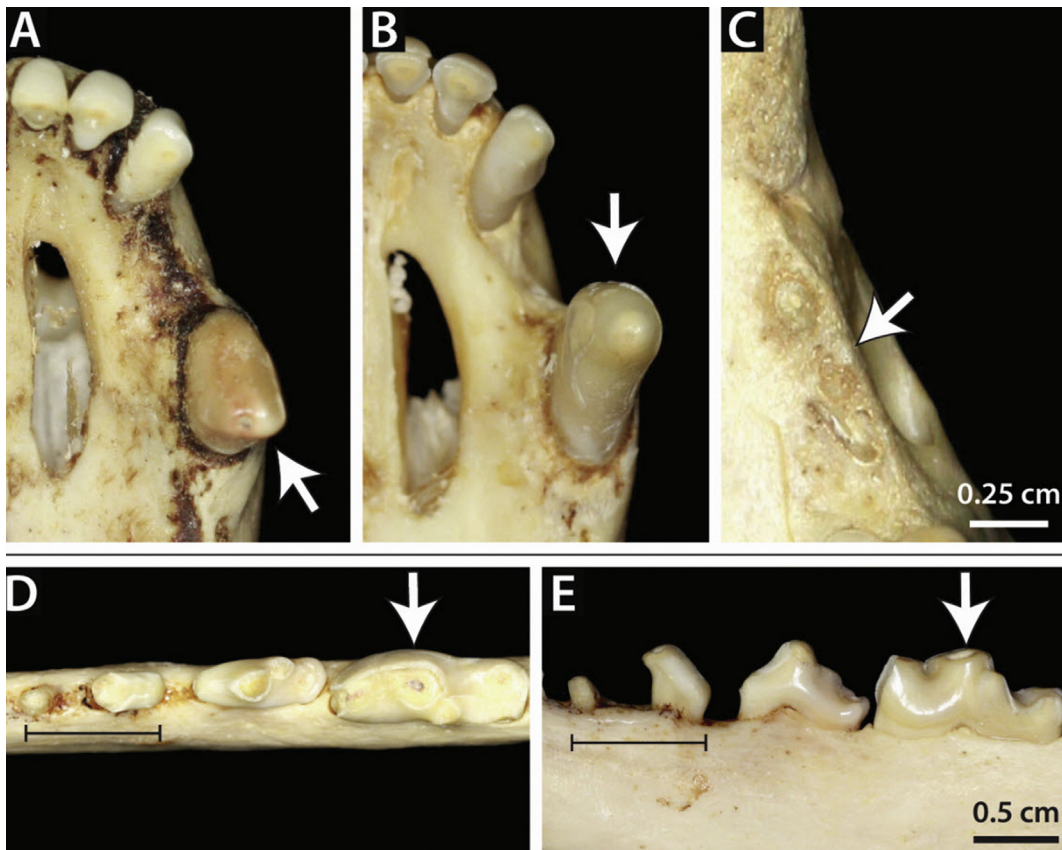


Fig. 7. (A) Uncomplicated crown fracture (MVZ 195825) and (B) complicated crown fracture (MVZ 195557) of the left maxillary canine tooth. (C–D) Complicated crown fracture of the right mandibular first molar tooth and complicated crown–root fracture of the right mandibular third premolar tooth (MVZ 195463). (E) Root fracture of the left maxillary third premolar tooth (MVZ 206969).

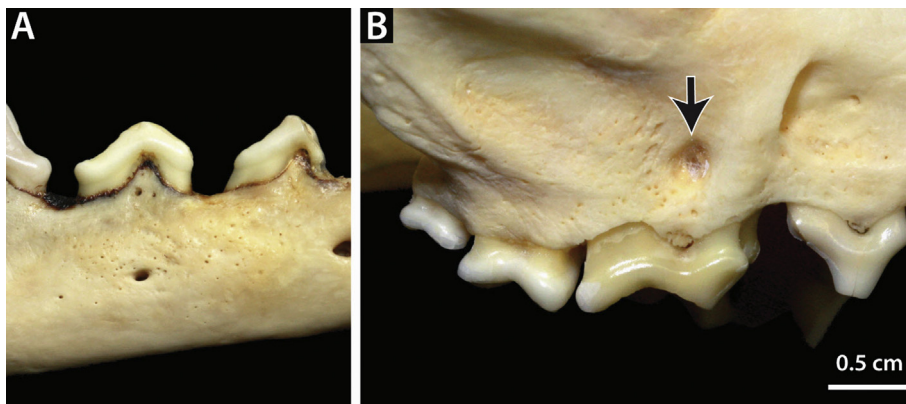


Fig. 8. (A) Mandibular periapical lesion associated with a crown–root fracture of the second premolar tooth (MVZ 195482). (B) Maxillary periapical lesion associated with a complicated crown fracture of the fourth premolar tooth (MVZ 195759).

this information, it is interesting that *V. macrotis*, which are almost strictly carnivorous, should have higher rates of attrition/abrasion.

Only two abnormalities had associations with sex; fenestrations were more prevalent in males and attrition/abrasion was more prevalent in females. Fenestrations may be a congenital/development defect or

the result of periodontitis. Because the prevalence of fenestrations was not associated with age, it can be concluded that in this species, fenestrations formed as a congenital/developmental defect in normal bone growth. Given this conclusion, the higher prevalence of fenestrations in males could indicate that there is a genetic or developmental difference between

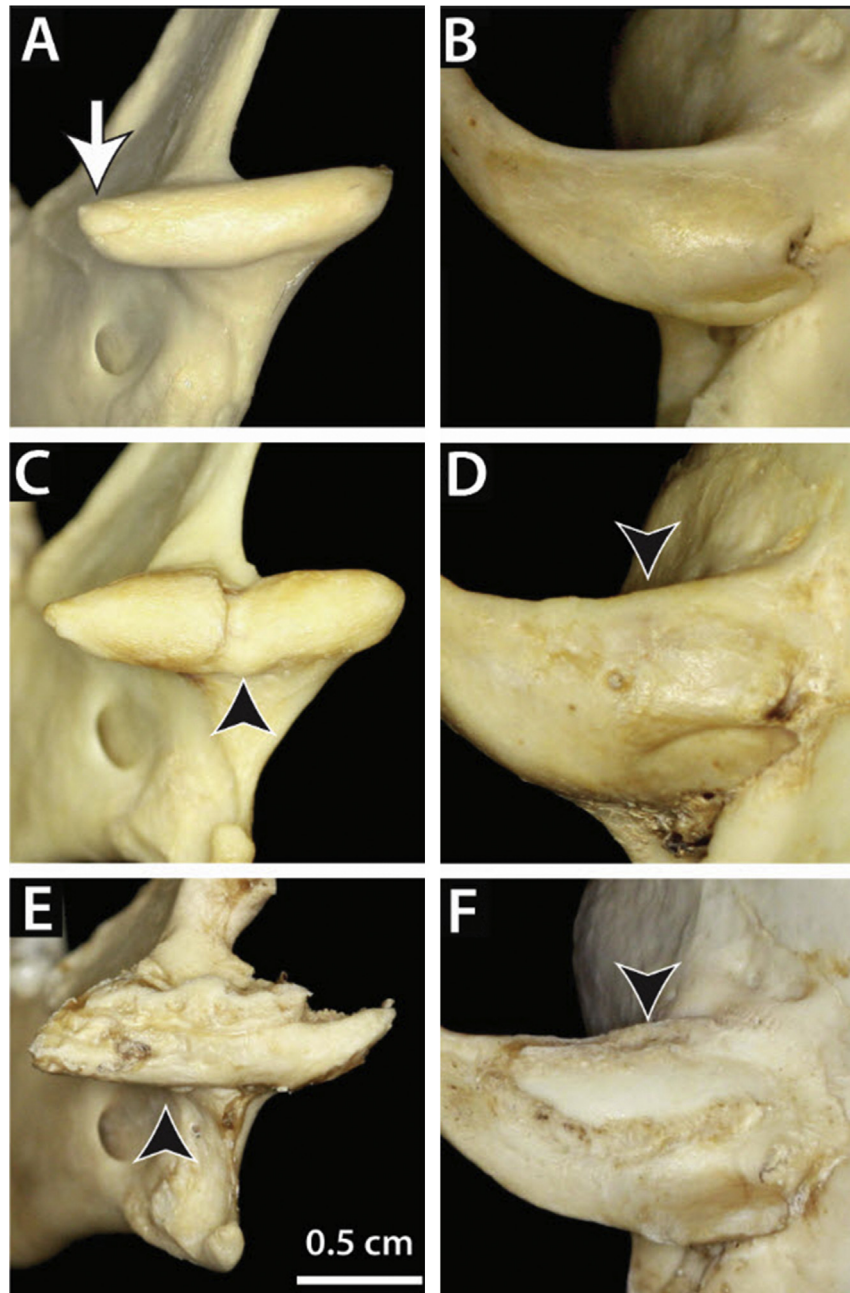


Fig. 9. Specimens with varying severities of TMJ-OA. Mild TMJ-OA with (A) a small osteophyte on the medial aspect of the right condylar process of the mandible and (B) a normal mandibular fossa (MVZ 224405). Moderate TMJ-OA with subchondral bone change on (C) the right condylar process and (D) right mandibular fossa (MVZ 195750). Severe TMJ-OA exhibiting marked remodelling of the subchondral bone at both the (E) mandibular head and (F) fossa; this adult fox of unknown sex also showed similar lesions throughout its skeleton consistent with septic polyarthritis (MVZ 227393).

male and female kit foxes with regards to alveolar bone growth. It is of interest that there was a sex difference in attrition/abrasion, especially in light of the fact that the same observation was made in *U. cinereoargenteus*. This could indicate a genetic, behavioural or physiological difference between the sexes of each species that would make the males more susceptible to having dental wear. A behavioural aetiology is un-

likely in the case of *V. macrotis* because the behaviours of males and females are relatively similar; they are nocturnal animals that hunt individually. Breeding pairs are usually monogamous and will cohabitate the same den to care for their litter together for the majority of the adolescence of the pups (Meaney *et al.*, 2006). One observed difference is that male kit foxes will participate in den-raiding and intrasexual

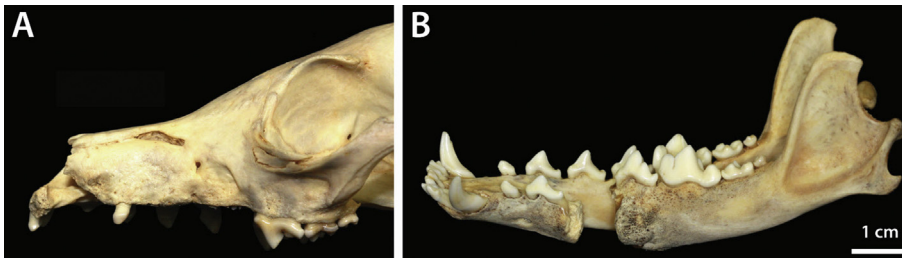


Fig. 10. Two different specimens with evidential healing of skull fractures to the (A) maxilla (MVZ 206969) and (B) mandible (MVZ 195390).

aggression more than females; however, this difference would more likely result in trauma than in the long-term process of dental wear.

Because distribution of specimens across the span of 1903–2014 was uneven, a significant increase in prevalence of one or even two diseases during a specific decade was likely to be incidental. Two decades, the 1930s and the 2000s, had increased prevalence of more than two abnormalities, indicating that there may have been environmental stressors that increased pathology in the foxes. The 1930s had significantly higher rates of periodontitis and acquired tooth losses, as well as double-rooted first premolar teeth, and the 2000s had increased rates of attrition/abrasion, fenestrations and congenital absences.

Periapical lesions were more prevalent in *V. macrotis* compared with *U. cinereoargenteus*, with 66 lesions found in this study, while only two lesions were found in the study of *U. cinereoargenteus* (Evenhuis *et al.*, 2018). Periapical lesions result as a consequence of pulp cavity exposure of the associated tooth. This study revealed a total of 968 (4.4%) teeth with pulp cavity exposure (complicated fractures and stage 4 attrition/abrasion); however, only 2.7% of teeth ($n = 634$) in the study of *U. cinereoargenteus* had pulp cavity exposure. The tendency to have more complicated fractures can explain the difference in the prevalence of periapical lesions in the two species.

Unlike *U. cinereoargenteus*, in which no TMJ-OA was detected, *V. macrotis* had a 5.9% rate of (mostly mild) TMJ-OA (Evenhuis *et al.*, 2018). As discussed above, *V. macrotis* also has a slightly higher prevalence of attrition/abrasion, which could be a potential correlation. However, the relationship between dental wear and TMJ degenerative disease has been questioned in human dentistry, with two recent systematic review studies concluding that the numerous correlative studies have proven to be inconclusive in this regard (van 't Spijker *et al.*, 2007; Yadav, 2011). Studies on marine mammals showed higher rates of TMJ-OA, especially in the California sea lion (*Zalophus californianus*) and walrus (*Odobenus rosmarus*) (63.5% and 60.5%, respectively) (Sinai *et al.*, 2014; Winer *et al.*,

2016). It was hypothesized that these species may have higher rates of TMJ-OA not because of increased mastication, but rather because of their use of tusks as weapons, particularly in light of the fact that males, who are the ones who express this behaviour, were more likely to have TMJ-OA (Winer *et al.*, 2016). Furthermore, there was no association between sex and TMJ-OA in *V. macrotis*. An alternative explanation for the difference in susceptibility of *V. macrotis* and *U. cinereoargenteus* to TMJ-OA is genetic predisposition. Understanding the prevalence of axial and appendicular osteoarthritis in the two species would help shed light on this possibility.

At 37.7% of specimens affected, *V. macrotis* suffered a higher prevalence of traumatic skull injuries than *U. cinereoargenteus* (9.8%); this perhaps reflects the smaller size of *V. macrotis* and thus higher predation rates by coyotes, red foxes and birds of prey. Twelve skulls in this study group showed evidence of healing head wounds; one individual with a complete fracture of the mandible showed evidence of callous formation; it can be presumed that the pain and soft tissue inflammation secondary to this healing process could have impaired eating to the point of starvation.

Limitations of this study were mostly inherent to the nature of the specimens. Care was taken to exclude post-mortem changes, as many of these have characteristic features, such as supraphysiological angles to fractures, sharp edges that lack any evidence of wear and empty alveoli that have no signs of osseous remodelling. Given the small size of *V. macrotis* skulls, true pathology may have been missed if lesions were small. This specimen collection also posed a limitation to the analysis of the canine teeth specifically; at least 169 canine teeth from *V. macrotis mutica* specimens had previously been removed *post mortem* for ageing studies. An additional 218 canine teeth were missing artifactually (possibly part of the ageing studies or from other causes), resulting in a total of 387 (17.3% of all potential canine teeth) unavailable for inspection. Nevertheless, the study design provided a sufficient number of specimens representing

a wild population, allowing analysis of the prevalence of dental pathology in the species across a variety of geographical locations and time periods.

Acknowledgments

The authors thank C. Conroy at the Museum of Vertebrate Zoology, University of California, Berkeley, for making the collection of *V. macrotis* specimens available for this study. This research was funded by an Academic Senate Research Grant to F. J. M. Verstraete and the Students Training in Advanced Research Programme of the School of Veterinary Medicine of the University of California, Davis, as well as the Boehringer-Ingelheim Animal Health Veterinary Scholar's Programme, which had no role in the study design, in the collection, analysis and interpretation of data, in the writing of the manuscript or in the decision to submit the manuscript for publication.

Supplementary data

Supplementary data to this article can be found online at <https://doi.org/10.1016/j.jcpa.2019.01.001>.

References

- Aalderink MT, Nguyen HP, Kass PH, Arzi B, Verstraete FJM (2015) Dental and temporomandibular joint pathology of the northern fur seal (*Callorhinus ursinus*). *Journal of Comparative Pathology*, **152**, 325–334.
- Aghashani A, Kim AS, Kass PH, Verstraete FJM (2016) Dental pathology of the California bobcat (*Lynx rufus californicus*). *Journal of Comparative Pathology*, **154**, 329–340.
- Clark EJ, Chesnutt S, Winer JN, Verstraete FJ (2017) Dental pathology of the American black bear (*Ursus americanus*). *Journal of Comparative Pathology*, **156**, 240–250.
- Clark JHO (2011) The history of arid-land fox discoveries in North America. *Archives of Natural History*, **38.2**, 300–312.
- Cypher B, List R (2014) *Vulpes macrotis*. The IUCN Red List of Threatened Species 2014: e.T41587A62259374. <https://doi.org/10.2305/IUCN.UK.2014-3.RLTS.T41587A62259374.en>.
- Doring S, Arzi B, Winer JN, Kass PH, Verstraete FJM (2018) Dental and temporomandibular joint pathology of the grey wolf (*Canis lupus*). *Journal of Comparative Pathology*, **160**, 56–70.
- Evenhuis JV, Zisman I, Kass PH, Verstraete FJM (2018) Dental pathology of the grey fox (*Urocyon cinereoargenteus*). *Journal of Comparative Pathology*, **158**, 29–50.
- Koopman ME, Cypher BL, Scrivner JH (1999) Dispersal patterns of San Joaquin kit foxes (*Vulpes macrotis mutica*). *Journal of Mammalogy*, **81**, 213–222.
- Meaney CA, Reed-Eckert M, Beauvais GP (2006) *Kit Fox (Vulpes macrotis): A Technical Conservation Assessment* [Online]. USDA Forest Service, Rocky Mountain Region. Available at: <http://www.fs.fed/us/r2/projects/scp/assessments/kitfox.pdf>.
- Sinai NL, Dadaian RH, Kass PH, Verstraete FJM (2014) Dental pathology of the California sea lion (*Zalophus californianus*). *Journal of Comparative Pathology*, **151**, 113–121.
- US Fish and Wildlife Service (1998) *Recovery Plan for Upland Species of the San Joaquin Valley, California*. Region 1 US Fish and Wildlife Service, Portland.
- van't Spijker A, Kreulen CM, Creugers NHJ (2007) Attrition, occlusion, (dys)function, and intervention: a systematic review. *Clinical Oral Implants Research*, **18**(Suppl. 3), 117–126.
- Verstraete FJM (2003) Advances in diagnosis and treatment of small exotic mammal dental disease. *Seminars in Avian and Exotic Pet Medicine*, **12**, 37–48.
- Verstraete FJM, van Aarde RJ, Nieuwoudt BA, Mauer E, Kass PH (1996) The dental pathology of feral cats on Marion Island, part I: congenital, developmental and traumatic abnormalities. *Journal of Comparative Pathology*, **115**, 265–282.
- Waithman J, Roest A (1977) A taxonomic study of the kit fox, *Vulpes macrotis*. *Journal of Mammalogy*, **58**, 157–164.
- Winer JN, Arzi B, Leale DM, Kass PH, Verstraete FJM (2016) Dental and temporomandibular joint pathology of the walrus (*Odobenus rosmarus*). *Journal of Comparative Pathology*, **155**, 242–253.
- Yadav S (2011) A study on prevalence of dental attrition and its relation to factors of age, gender and to the signs of TMJ dysfunction. *Journal of Indian Prosthodontic Society*, **11**, 98–105.

[Received, December 17th, 2018]
 [Accepted, January 24th, 2019]