

UC Davis

Dermatology Online Journal

Title

Verrucous tumor mimicking squamous cell carcinoma in immunocompetent patient

Permalink

<https://escholarship.org/uc/item/93z9c7pm>

Journal

Dermatology Online Journal, 22(2)

Authors

Ruiz-Villaverde, Ricardo
Sanchez-Cano, Daniel
Martinez-Peinado, Carmen M
[et al.](#)

Publication Date

2016

DOI

10.5070/D3222030098

Copyright Information

Copyright 2016 by the author(s). This work is made available under the terms of a Creative Commons Attribution-NonCommercial-NoDerivatives License, available at <https://creativecommons.org/licenses/by-nc-nd/4.0/>

Peer reviewed

Photo vignette

Verrucous tumor mimicking squamous cell carcinoma in immunocompetent patient

Ricardo Ruiz-Villaverde¹, Daniel Sánchez-Cano², Carmen M Martínez-Peinado³, Manuel Galan-Gutierrez³

Dermatology Online Journal 22 (2): 13

¹Complejo Hospitalario de Granada, Granada, Spain

²Hospital Santa Ana, Motril, Granada, Spain

³Complejo Hospitalario de Jaen, Jaen, Spain

Correspondence:

Ricardo Ruiz-Villaverde
Complejo Hospitalario de Granada
Granada, Spain
ismenios2005@gmail.com

Abstract

Mycobacteria cause a range of diseases in both immunocompetent and immunosuppressed individuals. An increase in non-tuberculous mycobacterial (NTM) infections targeting skin has been described. Many hypotheses have been developed in order to explain it: the increasing burden of immunocompromised individuals, immigration from endemic countries, improved laboratory identification techniques, and changes in human behavior that expose individuals to this NTM. *Mycobacterium mucogenicum* group comprises *M. mucogenicum*, *Mycobacterium aubagnense*, and *Mycobacterium phocaicum*. This group of organisms was first named Mycobacterium chelonae-like organism in 1982. Most clinically significant cases of those organisms involved catheter-related infections. Nevertheless, we report an interesting patient with a cutaneous infection produced by *M. mucogenicum* mimicking a squamous cell carcinoma; an excellent response to combined therapy with rifampicin and clarythromycin was observed.

Keywords: mycobacteria, Non-tuberculous, skin infection, rifampicin, clarythromycin

Introduction

Different mycobacterial species from *Mycobacterium tuberculosis* and *Mycobacterium leprae* have been called designated environmental, opportunistic, or atypical mycobacteria, although the term, non-tuberculous mycobacteria (NTM), is one of the most accepted. These pathogens can show resistance to antituberculosis drugs, although those with rapid growth are sensitive to conventional antibiotics. We report an interesting patient with a cutaneous infection produced by *M. mucogenicum* mimicking a squamous cell carcinoma. He obtained an excellent response to combined therapy with rifampicin and clarythromycin.

Case synopsis

A 59-year-old male with a past medical history of type 2 diabetes mellitus, attended our dermatology unit complaining about a cutaneous tumor of rapid growth, which had developed over the previous three months. He denied contact with animals, but he admitted an occasional prick with a rose thorn at work. He did not present with fever or systemic symptoms. On clinical examination, an infiltrated erythematous plaque with marked hyperkeratosis centrally could be appreciated on the dorsal aspect of his right hand (Figure 1A). No locoregional lymph nodes or hepatosplenomegaly were observed. Dermoscopy showed an erythematous periphery, hyperkeratosis, and central erosions without defined vascular pattern. Histological examination showed the existence of pseudoepitheliomatous hyperplasia with the presence of an acute inflammatory reaction

(Figure 2). Zielh Neelsen, Fite Faraco, and periodic acid-Schiff (PAS) staining and AFB smear were all negative. However, the culture showed the presence of non-pigmented mucoid colonies of alcohol resistant bacilli (ARB). Species identification based on 16S rRNA was consistent with *Mycobacterium mucogenicum*. After antimicrobial susceptibility testing, the patient was started on clarithromycin 500 mg, twice daily, in association with rifampicin 300 mg, twice daily, with resolution of symptoms in 3 months (Figure 1B). Voluntary and written consent was obtained for publication.

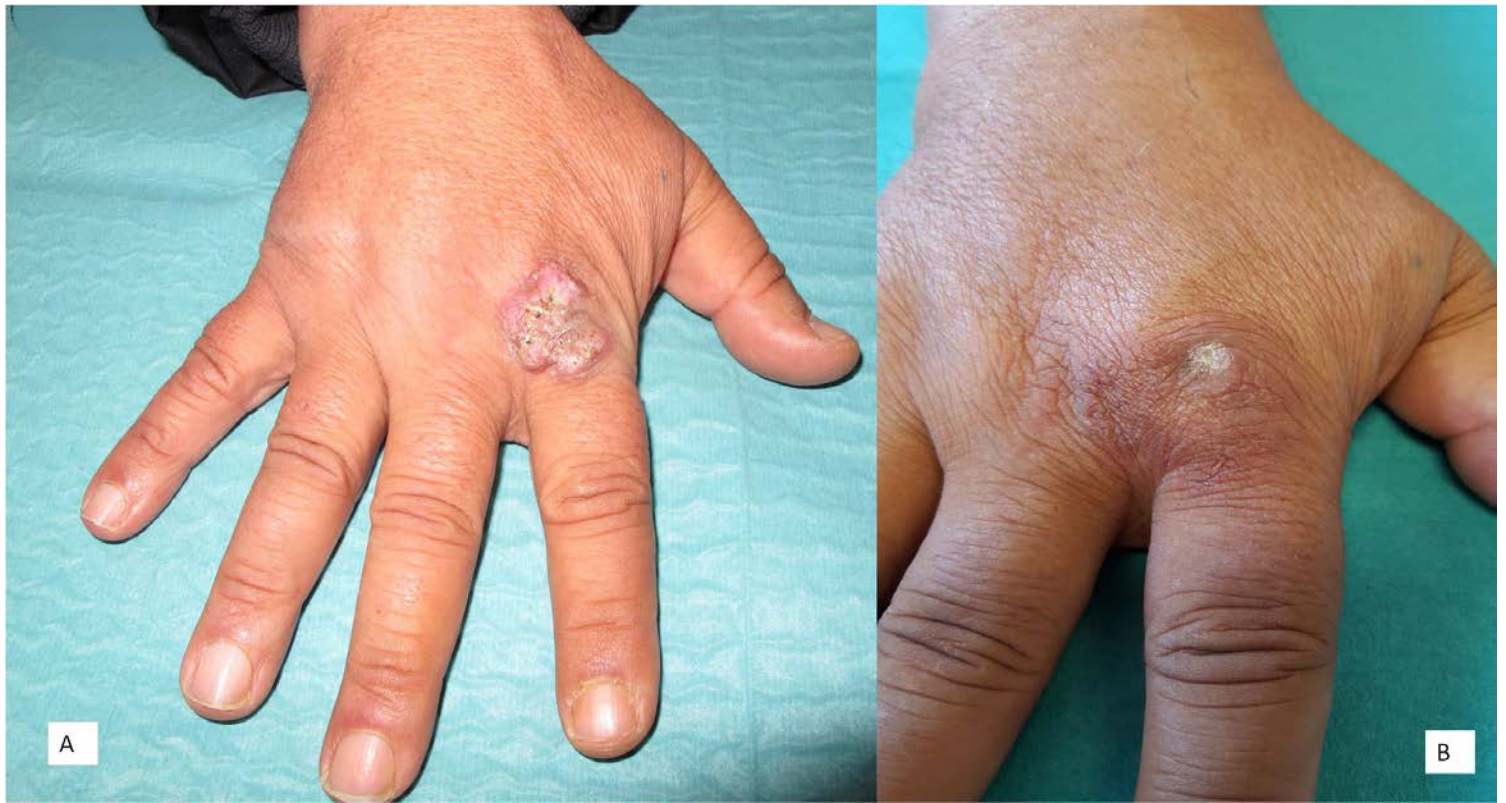

Figure 1. A. Hyperkeratotic tumor on dorsal aspect of the right hand B. Resolution after treatment

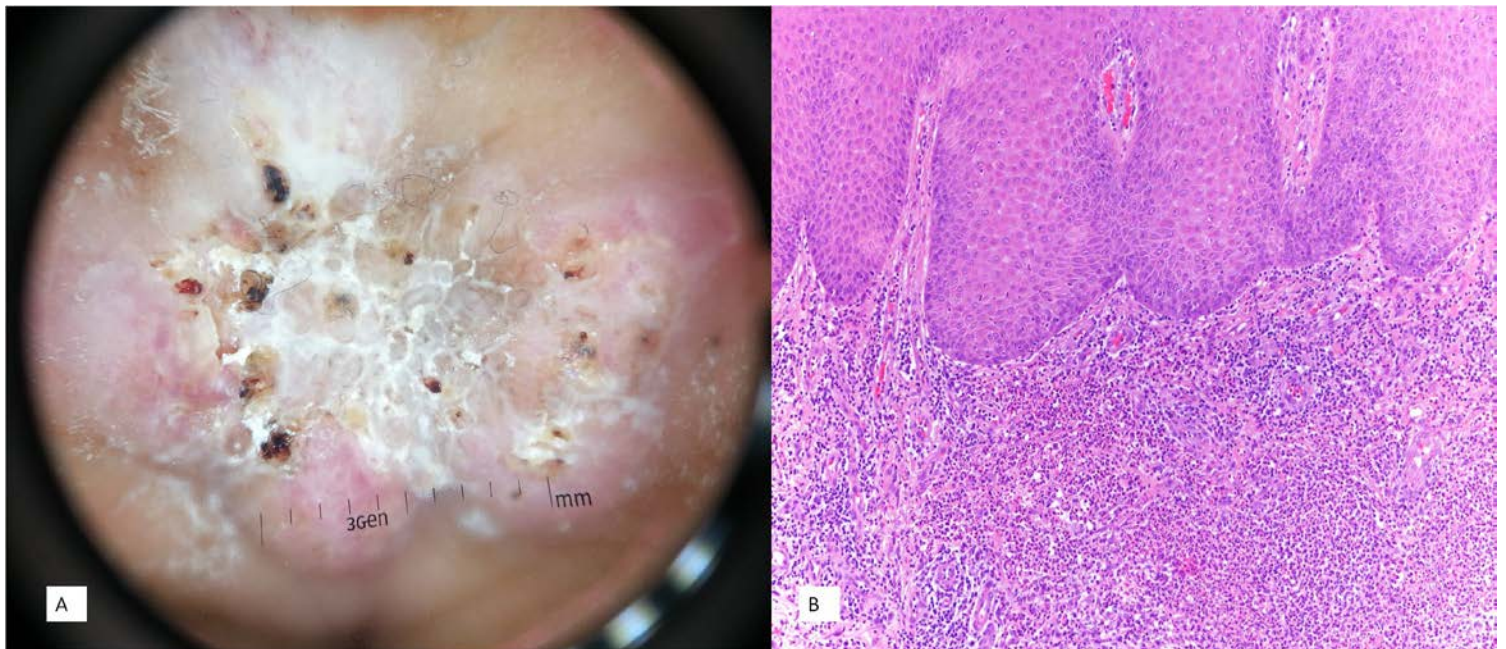


Figure 2. Histology (HEEx40): Pseudoepitheliomatous hyperplasia with presence of acute inflammatory reaction

Discussion

Mycobacterium mucogenicum is a fast-growing NTM, formerly known as *M. chelonae*-like, but its name may be attributed to Springer [1], who in 1995 bequeathed his description based on 16S rRNA sequencing. Infections owing to *M. mucogenicum* are extremely rare, but often involve skin and soft tissues. Hosts are usually undergoing peritoneal dialysis or experiencing catheter-related sepsis. Otherwise, infection is the result of a soft tissue trauma. Immunocompetent patients rarely develop severe infections [2]. The organism can also induce a granulomatous hepatitis, pneumonia in AIDS patients, and skin infections in patients treated with TNF blockers [3].

From a clinical point of view the presentation of cutaneous infections caused by NTM may be highly variable. The differential diagnosis includes common warts, verrucous tuberculosis, aquarium granuloma, sporotrichosis, and squamous cell carcinoma, as in the present case. The routine culture of exudates from lesions can be misleading and may give rise to the rapid overgrowth of skin contaminants. The identification of mycobacterium species on skin biopsy cultures is the reference standard. DNA sequencing may be used to identify the exact subtype isolated from culture.

There is no defined therapeutic regimen for treatment owing to the existence of multiple bacterial resistances. The choice of antimicrobial therapy may be guided by antimicrobial susceptibility testing. A combination of two or more agents should be considered [4], especially in cases of severe infections, or in immunocompromised patients. Amikacin, ciprofloxacin, clarithromycin, minocycline, and linezolid have shown in vitro activity against *M.mucogenicum*. The optimal duration of antimicrobial therapy is unknown, but in soft skin infections oral therapy for at least 4–6 weeks is recommended [5].

References

1. Springer B, Böttger EC, Kirschner P, Wallace RJ Jr. Phylogeny of the Mycobacterium chelonae-like organism based on partial sequencing of the 16S rRNA gene and proposal of Mycobacterium mucogenicum sp. nov. *Int J Syst Bacteriol* 1995;45(2):262-7.[PMID: 7537060]
2. Fonteyn N, Wauters G, Vandercam B, Degraux J, Avesani V, Vincent V, Delmée M. Mycobacterium mucogenicum sepsis in an immunocompetent patient. *J Infect*. 2006;53 (3):e143-6.[PMID: 16403579]
3. Shehan JM, Sarma DP. Mycobacterium mucogenicum: report of a skin infection associated with etanercept. *Dermatol Online J*. 2008;15;14(1):5.[PMID: 18319022]
4. Paterson DL, Singh N, Gayowski T, Marino IR. Mycobacterium mucogenicum bacteremia in a patient with cirrhosis. *J Clin Gastroenterol*. 1998;27(4):346-7.[PMID: 9855267]
5. Adékambi T. Mycobacterium mucogenicum group infections: a review. *Clin Microbiol Infect*. 2009;15(10):911-8. [PMID: 19845703]