

# UC San Diego

## UC San Diego Previously Published Works

### Title

Pediatric Nasal Chondromesenchymal Tumors: Case Report and Review of the Literature

### Permalink

<https://escholarship.org/uc/item/93r5w6vr>

### Journal

Pediatric Neurosurgery, 56(1)

### ISSN

1016-2291

### Authors

Schaerer, Daniel  
Nation, Javan  
Rennert, Robert C  
[et al.](#)

### Publication Date

2021

### DOI

10.1159/000512717

Peer reviewed



Published in final edited form as:

*Pediatr Neurosurg.* 2021 ; 56(1): 61–66. doi:10.1159/000512717.

## Pediatric Nasal Chondromesenchymal Tumors: Case Report and Review of the Literature

Daniel Schaerer, MD<sup>1</sup>, Javan Nation, MD<sup>1</sup>, Robert C. Rennert, MD<sup>2</sup>, Adam DeConde, MD<sup>1</sup>, Michael L. Levy, MD, PhD<sup>2,3,\*</sup>

<sup>1</sup>Department of Head and Neck Surgery, University California San Diego, San Diego, CA

<sup>2</sup>Department of Neurosurgery, University California San Diego, San Diego, CA

<sup>3</sup>Rady Children's Hospital of San Diego, San Diego, CA

### Abstract

**Introduction:** Nasal chondromesenchymal tumors (NCMT) are rare benign neoplasms that usually present in children < 1 year of age. They can display rapid growth and significant local bony remodeling that can mimic a malignant process. Of the ~50 published cases to date, few have documented the need for neurosurgical intervention. We herein report a NCMT in an infant treated with a staged cranial and transnasal approach, as well as summarize the available literature on this pathology.

**Case Report:** A newborn male with a compromised airway was noted to have a large sinonasal lesion. After stabilization, MRI demonstrated a 4 cm enhancing mass with diffuse sinus involvement and significant extension into the anterior cranial fossa, with displacement of the optic apparatus and hypothalamic pituitary axis. After an initial biopsy, the patient underwent a bifrontal craniofacial approach at 2 months of age, followed by a second stage transnasal endoscopic approach at 15 months which resulted in a complete resection. There were no neurosurgical complications. Pathology was consistent with a NCMT.

**Discussion:** Although rare, neurosurgical involvement is critical for the treatment of NCMTs with intracranial extension. Staged cranial and endonasal endoscopic approaches may be needed for complete resection of such lesions.

### Keywords

Chondromesenchymal; Hamartoma; Nasal Tumor; Pediatric Sinus Surgery; Pediatric Neurosurgery; Pediatric Skull Base Surgery

\* **Corresponding author:** Michael L. Levy, MD, PhD, UCSD Division of Pediatric Neurosurgery, 7910 Frost Street, Suite 120, San Diego, CA 92123. Phone: (858) 966-8644, Fax (858)-966-5674, mlevy@rchsd.org.

**Author Contributions:** D.S., J.N., A.C., and M.L.L developed and implemented the clinical plan, as well generated the idea and framework for the case writeup. D.S. and R.R. performed the literature review. All authors contributed to the drafting, revising, and final approval of the manuscript.

**Statement of Ethics:** Consent for procedures, as well as data collection, and review was obtained in accordance with institutional and review board guidelines and Health Insurance Portability and Accountability Act regulations.

Disclosure Statement:

The authors have no disclosures concerning the materials or methods used in this study or the findings specified in this paper. A previous version of this report was presented as a poster presentation at the American Rhinological Society Annual Meeting, September 25–26, 2015, Dallas, TX.

## Introduction:

Nasal chondromesenchymal tumors (NCMTs) are rare benign neoplasms that most often affect infants and young children, although can present over a wide range of ages.<sup>1-3</sup> First described in 1998,<sup>4</sup> and alternatively referred to as “chondroids”, “mesenchymomas” or “nasal hamartomas,” NCMTs can cause significant remodeling of local bony anatomy and invade the orbit and intracranial space. They have also recently been associated with DICER1 syndrome, a rare autosomal dominant tumor predisposition syndrome caused by loss-of-function alterations of the *DICER1* microRNA biogenesis machinery gene.<sup>5</sup>

Surgical resection is the treatment of choice for NCMTs, with trans-nasal approaches most often employed. Significant skull base and/or intracranial tumor extension can nonetheless make complete resection challenging. Of the approximately 51 prior reports on NCMTs, documentation of neurosurgical involvement was rare. We herein present the case of an infant requiring a staged transcranial and transnasal approach for a NCMT with significant intracranial extension, highlighting the importance of multidisciplinary surgical care of such patients.

## Case Report:

A newborn male with a compromised airway was noted to have a large sinonasal lesion. His neurologic exam was otherwise nonfocal. MRI of the brain and sinuses with and without contrast documented a 4 cm enhancing mass with sinus involvement and extension into the anterior cranial fossa with associated displacement of the optic apparatus and hypothalamic pituitary axis. There was associated bony remodeling (Figure 1). Differential diagnoses included benign and malignant nasopharyngeal neoplasms, nasal glioma, nasal pyogenic granuloma, and chondromesenchymal hamartoma.

He underwent a transnasal biopsy at two weeks diagnosing an NCMT, followed by an uncomplicated bifrontal craniofacial approach at 2 months of age at an outside facility, clearing the intracranial compartment and decompressing the frontal lobes. At 15 months of age following a transfer of care to our institution, he underwent a transnasal endoscopic approach which resulted in a complete resection and maintenance of the subfrontal dural plane (Figure 2-4). The patient tolerated both procedures without neurologic complications. Pathology confirmed a diagnosis of NCMT (Figure 5) with negative margins at the time of the second surgery. Surveillance MRI at 14 months post-operatively did not reveal any evidence of tumor recurrence.

## Discussion:

NCMTs are rare neoplasms involving the nasal cavity that can be difficult to diagnose prior to pathologic analysis.<sup>3, 6-8</sup> Review of the MEDLINE database for pertinent articles and manual review of their citations identified 51 prior reports of NCMTs published in English language peer reviewed journals from 1950 to August 2019.<sup>1-4, 6-37</sup> Nineteen of these patients were 1 year of age or less, with the oldest being 70 years. Average age was 130 ( $\pm$  189) months. 37 of these patients were male and 14 were female.

Based on this review, NCMTs commonly present as a visible mass, with other manifestations including nasal congestion, proptosis, extraocular movement disruptions, and/or respiratory difficulty. In rare cases of significant intracranial extension, neurologic symptoms from cerebral compression can also occur. On CT scan, tumor extension from the sinonasal region into the orbit, paranasal sinuses, and/or cribriform plate is common, as is local bony remodeling and internal calcifications.<sup>20</sup> On MRI NCMTs commonly have both solid and cystic components with low signal intensity on T1 and heterogenous high signal intensity on T2-weighted images. There is usually heterogeneous enhancement following the administration of contrast.<sup>21–23</sup>

On histology NCMTs demonstrate irregular islands of mature and immature hyaline cartilage, well demarcated from the surrounding stroma, with occasional binucleated chondrocytes. They exist in a myxoid background. Immunohistochemistry often documents a spindle cell stroma and immature cartilaginous tissue positive for vimentin and smooth muscle actin as well as mature cartilaginous tissue positive for S100.<sup>21</sup>

Malignant transformation of NCMTs has been reported in only one case,<sup>15</sup> making surgical resection the preferred treatment. Although operative details are sparse in many reports, endonasal endoscopic or open nasal approaches appear sufficient for the majority of NCMTs, with limited cases documenting the involvement of a neurosurgical team and an associated craniotomy.<sup>4, 14, 23, 37</sup> In the current case, a staged approach to first address the intracranial component and decompress the frontal lobes under direct visualization, followed by a definitive transnasal endoscopic approach for the residual sinonasal component was pursued to provide both timely neurologic decompression and long-term disease control. A single-stage transnasal approach was not chosen at the time of initial surgery as the significant intracranial extension combined with the small nasal passages of infancy would have made intracranial visualization and safe tumor-dura dissection challenging.

Regarding other treatment considerations, only one prior case utilized preoperative embolization, which can be challenging due to adjacent orbital collaterals and/or arterial supply to cranial nerves. The role for adjuvant therapies also appears limited, with chemotherapy and/or radiation described in only a small number of cases. Although the true recurrence rate of NCMTs is unclear (only 66% [34/51] of reported cases included follow-up), nearly one-quarter of patients (23.5%, 8/34) had trackable residual or recurrent tumors over a mean follow-up period of  $29.4 \pm 37.2$  months. The majority of these cases nonetheless appeared to result from incomplete initial resections as opposed to true tumor recurrences. This highlights the importance of surgical technique in long-term disease control, including the importance of neurosurgical involvement in patients with skull base/intracranial extension.

Although not assessed in this case, given the subsequent association of NCMTs with DICER1 syndrome, surgeons should also be aware of the common central nervous system (CNS) and non-CNS syndromic manifestations that can occur in these patients, including pineoblastomas, pituitary blastomas, CNS sarcomas, pleuropulmonary blastomas, and Ovarian Sertoli-Leydig cell tumors, among others.<sup>5</sup>

## Conclusions:

Of the approximately 51 reported cases of NCMTs in the literature, few describe neurosurgical involvement. Neurosurgeons should nonetheless be aware of the potential for significant intracranial extension, which can necessitate staged and/or combined operative approaches. Long-term follow-up is warranted as the risk of recurrence is further defined.

## Acknowledgements:

None.

**Funding Sources:** This work was supported by an NIH T32 Institutional Research Training Grant (DC000028–25) to Daniel Schaerer. No other funding sources were used to complete this work.

## References:

1. Mirchia K, Naous R. Nasal Chondromesenchymal Hamartoma: Rare Case Report in an Elderly Patient and Brief Review of Literature. *Case Rep Pathol* 2018;2018: 5971786.
2. Ozolek JA, Carrau R, Barnes EL, Hunt JL. Nasal chondromesenchymal hamartoma in older children and adults: series and immunohistochemical analysis. *Arch Pathol Lab Med* 2005;129(11): 1444–1450. [PubMed: 16253025]
3. Mason KA, Navaratnam A, Theodorakopoulou E, Chokkalingam PG. Nasal Chondromesenchymal Hamartoma (NCMH): a systematic review of the literature with a new case report. *J Otolaryngol Head Neck Surg* 2015;44: 28. [PubMed: 26138824]
4. McDermott MB, Ponder TB, Dehner LP. Nasal chondromesenchymal hamartoma: an upper respiratory tract analogue of the chest wall mesenchymal hamartoma. *Am J Surg Pathol* 1998;22(4): 425–433. [PubMed: 9537469]
5. de Kock L, Priest JR, Foulkes WD, Alexandrescu S. An update on the central nervous system manifestations of DICER1 syndrome. *Acta Neuropathol* 2019.
6. Sarin V, Singh B, Prasher P. A silent nasal mass with ophthalmic presentation. *Orbit* 2010;29(6): 367–369. [PubMed: 21158582]
7. Uzomefuna V, Glynn F, Russell J, McDermott M. Nasal chondromesenchymal hamartoma with no nasal symptoms. *BMJ Case Rep* 2012;2012.
8. Cho YC, Sung IY, Son JH, Ord R. Nasal chondromesenchymal hamartoma: report of a case presenting with intraoral signs. *J Oral Maxillofac Surg* 2013;71(1): 72–76. [PubMed: 22695010]
9. Shet T, Borges A, Nair C, Desai S, Mistry R. Two unusual lesions in the nasal cavity of infants--a nasal chondromesenchymal hamartoma and an aneurysmal bone cyst like lesion. More closely related than we think? *Int J Pediatr Otorhinolaryngol* 2004;68(3): 359–364. [PubMed: 15129948]
10. Silkiss RZ, Mudvari SS, Shetlar D. Ophthalmologic presentation of nasal chondromesenchymal hamartoma in an infant. *Ophthalmic Plast Reconstr Surg* 2007;23(3): 243–244. [PubMed: 17519672]
11. Moon SH, Kim MM. Nasal chondromesenchymal hamartoma with incomitant esotropia in an infant: a case report. *Can J Ophthalmol* 2014;49(1): e30–32. [PubMed: 24513379]
12. Finitis S, Giavroglou C, Potsi S, Constantinidis I, Mpaltatzidis A, Rachovitsas D, Tzioufa V. Nasal chondromesenchymal hamartoma in a child. *Cardiovasc Intervent Radiol* 2009;32(3): 593–597. [PubMed: 18972159]
13. Hsueh C, Hsueh S, Gonzalez-Crussi F, Lee T, Su J. Nasal chondromesenchymal hamartoma in children: report of 2 cases with review of the literature. *Arch Pathol Lab Med* 2001;125(3): 400–403. [PubMed: 11231491]
14. Kim B, Park SH, Min HS, Rhee JS, Wang KC. Nasal chondromesenchymal hamartoma of infancy clinically mimicking meningoencephalocele. *Pediatr Neurosurg* 2004;40(3): 136–140. [PubMed: 15367805]

15. Li Y, Yang QX, Tian XT, Li B, Li Z. Malignant transformation of nasal chondromesenchymal hamartoma in adult: a case report and review of the literature. *Histol Histopathol* 2013;28(3): 337–344. [PubMed: 23348387]
16. Low SE, Sethi RK, Davies E, Stafford JS. Nasal chondromesenchymal hamartoma in an adolescent. *Histopathology* 2006;49(3): 321–323. [PubMed: 16918986]
17. Alrawi M, McDermott M, Orr D, Russell J. Nasal chondromesenchymal hamartoma presenting in an adolescent. *Int J Pediatr Otorhinolaryngol* 2003;67(6): 669–672. [PubMed: 12745162]
18. Priest JR, Williams GM, Mize WA, Dehner LP, McDermott MB. Nasal chondromesenchymal hamartoma in children with pleuropulmonary blastoma--A report from the International Pleuropulmonary Blastoma Registry registry. *Int J Pediatr Otorhinolaryngol* 2010;74(11): 1240–1244. [PubMed: 20822816]
19. Obidan AA, Ashoor MM. Nasal chondromesenchymal hamartoma in an adolescent with pleuropulmonary blastoma. *Saudi Med J* 2014;35(8): 876–878. [PubMed: 25129191]
20. Kim JE, Kim HJ, Kim JH, Ko YH, Chung SK. Nasal chondromesenchymal hamartoma: CT and MR imaging findings. *Korean J Radiol* 2009;10(4): 416–419. [PubMed: 19568473]
21. Johnson C, Nagaraj U, Esguerra J, Wasdahl D, Wurzbach D. Nasal chondromesenchymal hamartoma: radiographic and histopathologic analysis of a rare pediatric tumor. *Pediatr Radiol* 2007;37(1): 101–104. [PubMed: 17091268]
22. Wang T, Li W, Wu X, Li Q, Cui Y, Chu C, Xiang M, Ren G. Nasal chondromesenchymal hamartoma in young children: CT and MRI findings and review of the literature. *World J Surg Oncol* 2014;12: 257. [PubMed: 25117604]
23. Kato K, Ijiri R, Tanaka Y, Hara M, Sekido K. Nasal chondromesenchymal hamartoma of infancy: the first Japanese case report. *Pathol Int* 1999;49(8): 731–736. [PubMed: 10504541]
24. Li GY, Fan B, Jiao YY. Endonasal endoscopy for removing nasal chondromesenchymal hamartoma extending from the lacrimal sac region. *Can J Ophthalmol* 2013;48(2): e22–23. [PubMed: 23561613]
25. Norman ES, Bergman S, Trupiano JK. Nasal chondromesenchymal hamartoma: report of a case and review of the literature. *Pediatr Dev Pathol* 2004;7(5): 517–520. [PubMed: 15547776]
26. Park SK, Jung H, Yang YI. Mesenchymal hamartoma in nasopharynx: a case report. *Auris Nasus Larynx* 2008;35(3): 437–439. [PubMed: 17980991]
27. Avcı H, Çomo lu , Öztürk E, Bilgiç B, Kıyak Ö. Nasal chondromesenchymal hamartoma: a rare nasal benign tumor. *Kulak Burun Bogaz İhtis Derg* 2016;26(5): 300–303. [PubMed: 27888828]
28. Golbin DA, Ektova AP, Demin MO, Lasunin N, Cherekaev VA. Nasal Chondromesenchymal Hamartoma with Skull Base and Orbital Involvement: Case Presentation. *Cureus* 2018;10(6): e2892. [PubMed: 30167348]
29. Nakaya M, Yoshihara S, Yoshitomi A, Baba S. Endoscopic endonasal excision of nasal chondromesenchymal hamartoma with intracranial extension. *Eur Ann Otorhinolaryngol Head Neck Dis* 2017;134(6): 423–425. [PubMed: 28385583]
30. Lee CH, Park YH, Kim JY, Bae JH. Nasal chondromesenchymal hamartoma causing sleep-disordered breathing in an infant. *Int J Clin Exp Pathol* 2015;8(8): 9643–9646. [PubMed: 26464731]
31. Ünal A, Kum RO, Avcı Y, Ünal DT. Nasal chondromesenchymal hamartoma, a rare pediatric tumor: Case report. *Turk J Pediatr* 2016;58(2): 208–211. [PubMed: 27976564]
32. Jeyakumar AMT, N F. Neonatal nasal mass: Chondromesenchymal hamartoma. *Int J Pediatr Otorhinolaryngol Extra* 2010: 223–225.
33. Nakagawa TST, Ito J. Nasal chondromesenchymal hamartoma in an adolescent. *Int J Pediatr Otorhinolaryngol Extra* 2009: 111–113.
34. Eloy PTH, Nassogne, M WB, Rombaux P. Nasal chondromesenchymal hamartoma: Case report. *Int J Pediatr Otorhinolaryngol Extra* 2011;6: 300–303.
35. Kang JHY, Ahn GH. Nasal Chondromesenchymal Hamartoma a case report. *Kor J Pathol* 2006;41: 258–262.
36. Chandra MSN, VP V. Nasal chondromesenchymal hamartoma: a case report and review of literature. *JK Practitioner* 2014;19: 53–59.

37. Tabatabaei ANM, AR G. Nasal chondromesenchymal hamartoma in an adolescent: a report of case and review of literature. *Ir J Otorhinolaryngol* 2006;17: 19–22.

Author Manuscript

Author Manuscript

Author Manuscript

Author Manuscript

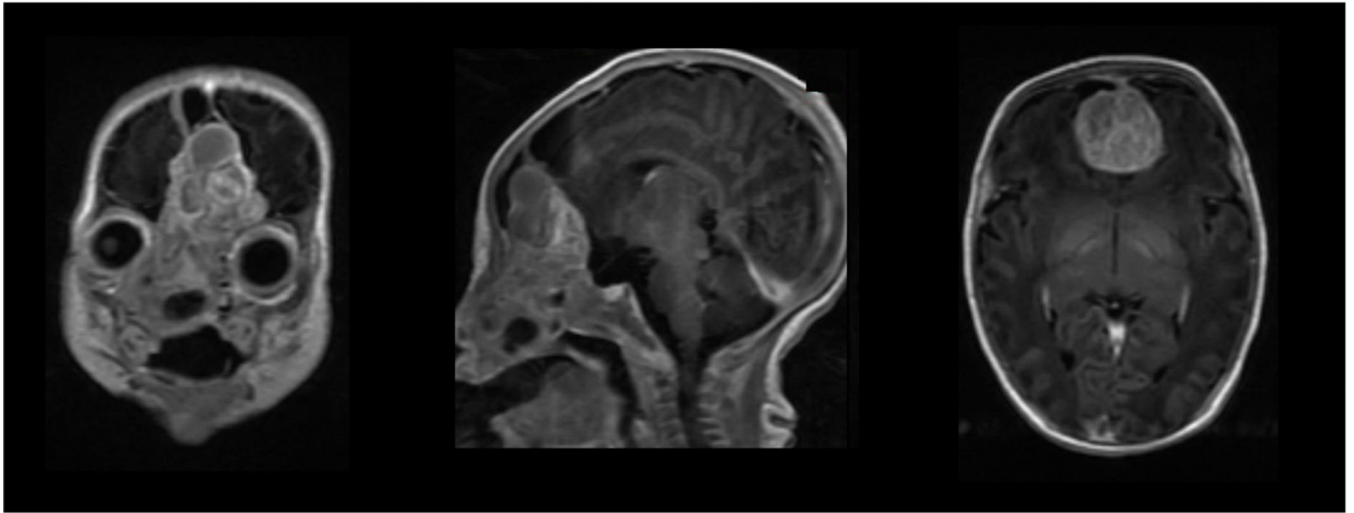
**Established Facts**

- Nasal chondromesenchymal tumors (NCMT) are rare benign neoplasms typically treated trans-nasally.
- Although invasion of the intracranial space can occur, neurosurgical involvement is documented in less than 10% of cases.



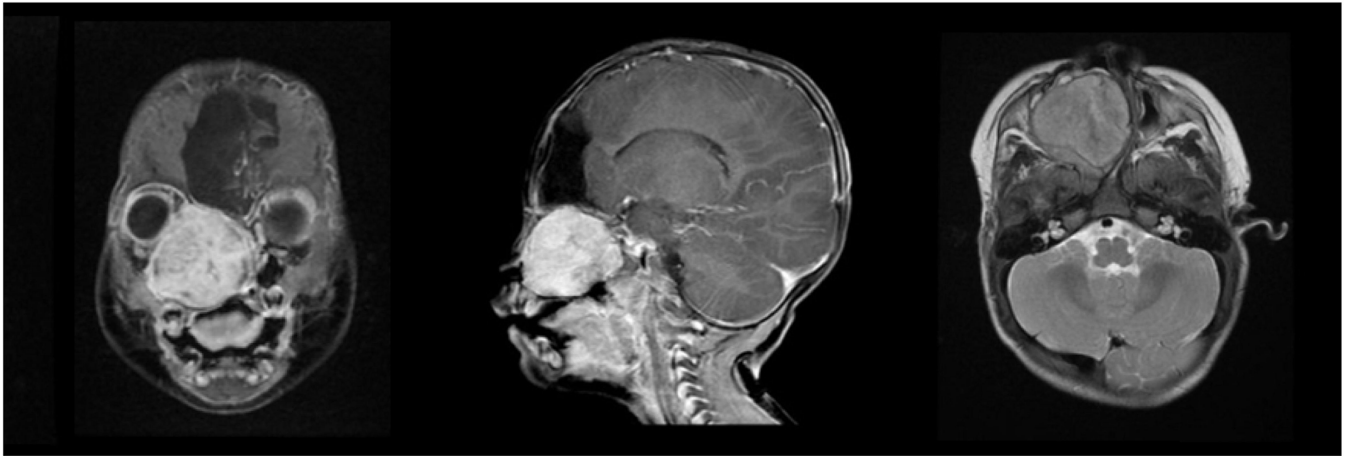
### Novel Insights

- Neurosurgical involvement is critical for the treatment of NCMTs with concern for intracranial extension.
- Staged cranial and endonasal endoscopic approaches may be needed for complete resection of such lesions.



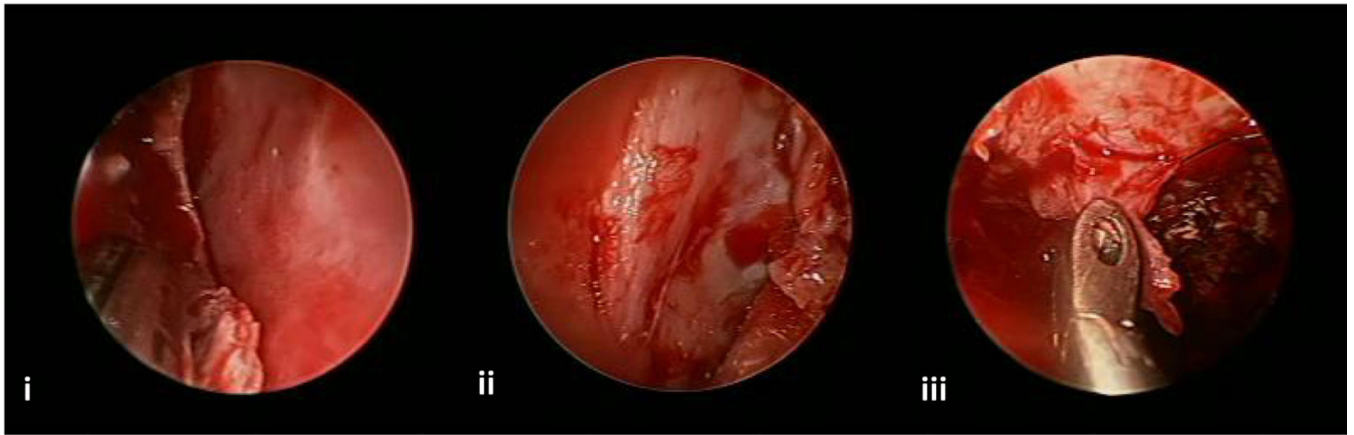
**Figure 1: Initial MRI.**

Preoperative T1 MRI with contrast of the brain and sinuses documents a 6 cm enhancing mass with diffuse sinus involvement and significant extension into the anterior cranial fossa. Displacement of the optic apparatus and hypothalamic pituitary axis was noted.



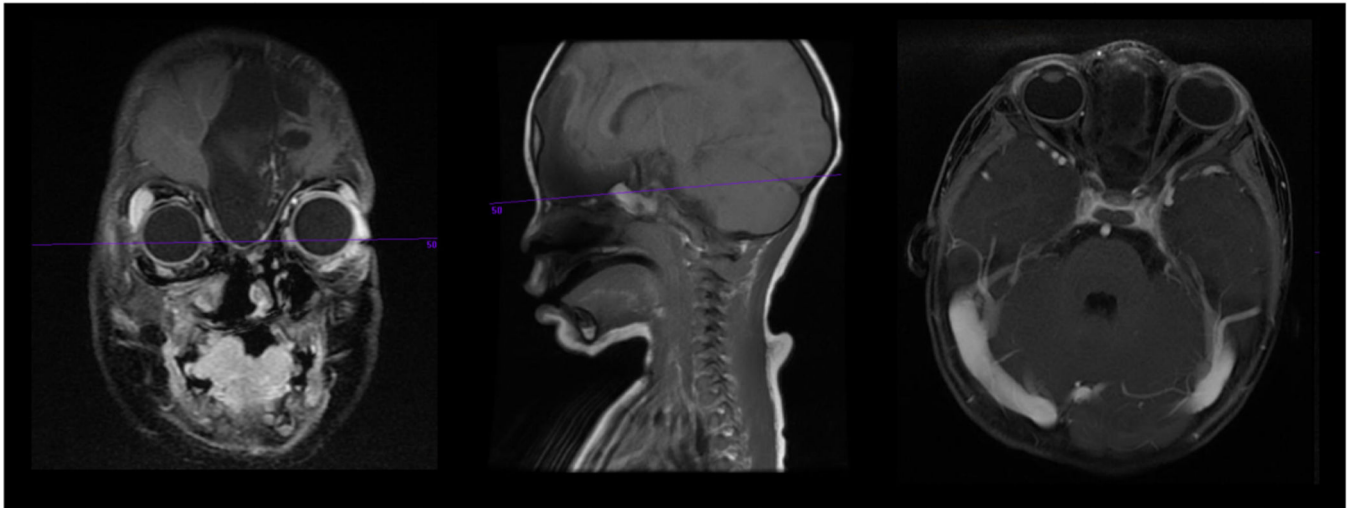
**Figure 2: MRI prior to trans-nasal resection.**

T2 MRI with contrast obtained after resection of the intracranial portion of the tumor and before trans-nasal resection of the residual sinus component. From left to right, coronal, sagittal, and axial views. A  $4.4 \times 4.4 \times 4.1$  cm heterogeneously enhancing hyperintense well-circumscribed mass filling the entire right sinonasal cavity was noted, with expansion and remodeling of the cribriform plate, planum sphenoidale, and inferomedial right orbital wall. This lesion displayed moderate growth on interval imaging obtained after stage one surgery.

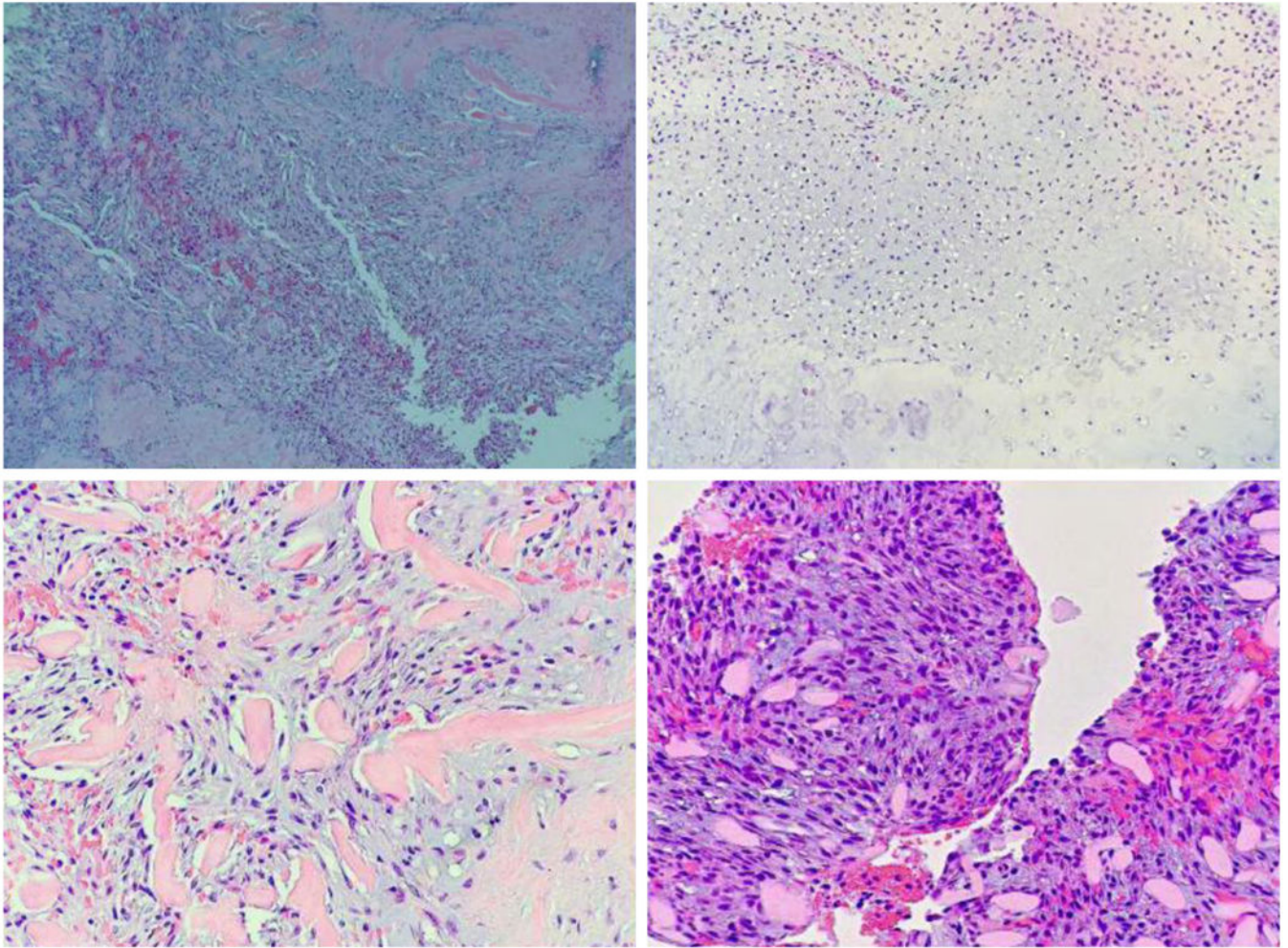


**Figure 3: Stage 2 intra-operative resection photos.**

Intraoperative view of endoscopic resection: i) tumor being peeled off of septum, ii) periorbital exposed after tumor resection, and iii) tumor being removed from dura.



**Figure 4: MRI after stage two resection.**  
Postoperative T1 MRI images demonstrating a gross total resection.



**Figure 5: Tumor histology.**

Histologic analysis demonstrated a mixture of immature cartilage, myxoid mesenchymal tissue, and fibroblastic-type spindle cells with variable cellularity, consistent with a NCMT.