

UC San Diego

UC San Diego Previously Published Works

Title

The Greater Omentum-A Vibrant and Enigmatic Immunologic Organ Involved in Injury and Infection Resolution.

Permalink

<https://escholarship.org/uc/item/92g2106n>

Journal

Shock, 53(4)

Authors

Wang, Andrew

Prieto, James

Cauvi, David

et al.

Publication Date

2020-04-01

DOI

10.1097/SHK.0000000000001428

Peer reviewed



Published in final edited form as:

Shock. 2020 April ; 53(4): 384–390. doi:10.1097/SHK.0000000000001428.

THE GREATER OMENTUM – A VIBRANT and ENIGMATIC IMMUNOLOGIC ORGAN INVOLVED in INJURY and INFECTION RESOLUTION

Andrew W. Wang^{*}, James M. Prieto^{*}, David M. Cauvi^{†,‡}, Stephen W. Bickler^{‡,§}, Antonio De Maio^{†,‡,||}

^{*} Department of Surgery, Naval Medical Center San Diego, San Diego, CA 92134, USA

[†] Division of Trauma, Critical Care, Burns and Acute Surgery, University of California, La Jolla, CA 92093, USA

[‡] Department of Surgery, School of Medicine, University of California, La Jolla, CA 92093, USA

[§] Division of Pediatric Surgery, Rady Children's Hospital, San Diego, CA 92123, USA

^{||} Department of Neurosciences, School of Medicine, University of California, La Jolla, CA 92093, USA

Abstract

Once thought of as an inert fatty tissue present only to provide insulation for the peritoneal cavity, the omentum is currently recognized as a vibrant immunologic organ with a complex structure uniquely suited for defense against pathogens and injury. The omentum is a source of resident inflammatory and stem cells available to participate in the local control of infection, wound healing, and tissue regeneration. It is intimately connected with the systemic vasculature and communicates with the central nervous system and the hypothalamic pituitary adrenal axis. Furthermore, the omentum has the ability to transit the peritoneal cavity and sequester areas of inflammation and injury. It contains functional, immunologic units commonly referred to as “milky spots” that contribute to the organ’s immune response. These milky spots are complex nodules consisting of macrophages and interspersed lymphocytes, which are gateways for the infiltration of inflammatory cells into the peritoneal cavity in response to infection and injury. The omentum contains far greater complexity than is currently conceptualized in clinical practice and investigations directed at unlocking its beneficial potential may reveal new mechanisms underlying its vital functions and the secondary impact of omentectomy for the staging and treatment of a variety of diseases.

Keywords

milky spots; inflammation; abdominal sepsis; macrophages; lymphocytes

INTRODUCTION

The omentum has long been recognized as an important ally in the fight against intraabdominal infections. Often referred to as the “guardian or policeman of the abdomen” (1), it is commonly observed plugging a hole in a perforated appendix or adhering to other bowel pathologies (Fig. 1). The seasoned surgeon often follows the omentum to identify the source of intraabdominal sepsis and returns the omentum to the surgical field following the definitive management of the pathology encountered. The omentum is also recognized for its remarkable healing ability. Omental tissue and its properties have long been exploited in the practice of surgery to buttress gastrointestinal anastomosis, fill empty space, aid in hemostasis, and provide soft tissue coverage for various vulnerable structures (2). Perhaps the best-known example of this utility is the Graham patch for treating a perforated duodenal ulcer. First described by Dr. Roscoe Reid Graham in 1937, the technique involves the deliberate placement of a tongue of omentum as a definitive treatment over the focal area of perforation (3). More recently, it has been suggested that the omentum has a role in the spontaneous sealing of spontaneous intestinal perforation and focal necrotizing enterocolitis in neonates, allowing a subset of patients to be managed with peritoneal drains without the need for subsequent laparotomy (4). Additionally, the technique of free omental sheet graft repair has been shown to be superior to other surgical interventions for typhoid enteric perforation as evidenced by lower rates of enterocutaneous fistula and mortality (5). Despite these remarkable features, the role of the omentum and the immunologic mechanisms underlying the organ’s function remains to be fully understood. During recent investigations, the omentum was discarded as an experimental variable during bariatric procedures as a means to optimize weight loss (6), illustrating the view of the omentum as an unnecessary pedicle of fat. Interestingly, this practice was aborted due to the lack of long-term clinical benefit from omentectomy rather than a new appreciation for the omentum (7). Contemporarily, another peritoneal structure, the mesentery, has gained significant attention for its reclassification as an organ based upon its structure, function, and role in localized and systemic disease (8). A recent review also highlighted some of the critical immunologic roles that the omentum plays on a cellular level with specific attention to its role in peritoneal tumor metastases. (9). In this context, we review the embryology, anatomy, and histologic structure of the omentum with a specific focus on the immunology of the organ and its role in the response to intraabdominal infection. We aim to enhance the reader’s appreciation for this vibrant immunologic organ and underscore the mechanisms responsible for its clinical utility.

EMBRYOLOGY

The embryology of the omentum is intimately connected to that of the stomach. The omentum is derived from the dorsal (greater omentum) and ventral (lesser omentum, falciform ligament) mesentery. Following a 90 degree, clockwise rotation of the gut tube and stomach at approximately five to six weeks gestation, differential growth is responsible for the size discrepancy between the greater and lesser curvatures of the stomach and their corresponding relationships with the greater and lesser omentum (10, 11). The omentum continues to organize and increase in length over the next seven to eight weeks and later fuses with the transverse colon (12). A well-developed structure, readily identifiable as the

greater omentum, is present at birth and can be seen in utero using prenatal ultrasound (13). However, it continues to develop during the postnatal period reaching full development by the age of eleven. Immunological units found within the omentum referred to as “Milky spots” are the microscopic functional units of the omentum. They are first observed as small clusters of macrophages at 20-weeks’ gestation in the developing fetus and there are progressively increasing numbers of macrophages and lymphocytes throughout gestation. The number of milky spots increases in number throughout the first year. Following this rise, they progressively decrease in number with age (12, 14, 15). The differentiation and development of macrophages within the milky spots is dependent on M-CSF production by omental stromal cells (16). Milky spots may play a role in the maturity of the adaptive immune system as well. For example, the fetal omentum has been speculated to be a source of B-cell development analogous to the thymus (2, 17).

GROSS ANATOMY

The greater omentum is a two-leaflet hammock of fibro-fatty tissue that extends from the greater curvature of the stomach to the transverse colon. It spans the width of the abdomen laterally and reaches the pelvis inferiorly. It varies in size depending on the age of the patient and the body habitus of the individual. It can be as large 36 cm in height, extending as far caudally as the pubic symphysis, and as wide as 46 cm, covering up to 500 cm, approximately the size of a textbook (2, 12). The greater omentum has remarkable mobility within the abdominal cavity. This mobility is possible as a result of its smooth mesothelial surface imparting a near friction-free interface with the peritoneum and visceral serosa (18). As a result of its limited fixation, the omentum is free to migrate within the abdominal cavity due to the effects of gravity, respiration, and peristalsis of visceral structures (2, 19). The omentum has a rich blood supply that is formed by an anastomotic arcade between the celiac trunk and the superior mesenteric artery. The right gastro-omental artery is a branch of the gastroduodenal artery as it descends from the common hepatic artery of the celiac trunk. It joins the left gastro-omental artery, a branch of the splenic artery, along the greater curvature of the stomach. This arcade receives input from the superior mesenteric artery via the inferior pancreaticoduodenal artery. A varying number of epiploic vessels branch perpendicularly from the gastro-omental vessels to perfuse the omentum (12). Angiogenic factors and growth factors are produced in the omentum during inflammation (20, 21), leading to a rise in blood vessel density, resulting in a dramatic increase in blood flow in response to peritonitis (21, 22). The network of vessels and this physiologic response to infection serves to support the immunologic and regenerative properties of the omentum and provides a bridge between the peritoneal cavity and the systemic circulation.

HISTOLOGICAL FEATURES

The histology of the omentum is heterogeneous in nature and is composed of distinct translucent and adipose-rich regions (18). These regions are similar in architecture with several important differences. They are composed of a sandwich of submesothelial connective tissue containing collagen and fibroblasts between two single-layer mesothelial sheets. There are multiple fenestrations throughout this bilayer measuring up to 225 μm . (18), allowing the transit of small particles and cells between the peritoneal cavity and the

anterior and posterior leaflets of the omentum. The mesenchymal cells are covered by microvilli and contain vesicles along their apical and basal surfaces. The surface architecture of the mesothelial cells increases in microvilli number and density in response to inflammatory stimuli (23). Transport through the mesenchymal cell layer into the submesenchymal connective tissue has been shown following the injection of radiopaque substances into the peritoneal cavity (24). Once present in this layer of connective tissue, substances may contact inflammatory cells and other immune mediators.

The adipose-rich region of the greater omentum is abundant with fat tissue in the submesothelial layer. This area is also rich in blood vessels and important aggregates of inflammatory cells commonly referred to as “milky spots” or “omentum-associated lymphoid tissue.” They are composed mainly of macrophages, T and B cells with different proportions and localized in an apparently orderly manner (Fig. 2). Similar spots have been identified in the pleural cavity and various other locations throughout the peritoneal cavity and pelvis (25, 26). They are arranged in variable configurations ranging from round to irregular and are usually, though not always, perivascular in nature (27). Milky spots measure approximately 0.3–3.5 mm² and have a density that decreases with age to 2 per cm². In the adipose-rich region, mesenchymal fenestrations overlie the milky spots allowing for the transport of inflammatory cells (23, 28). They are the portal of entry into the peritoneal cavity for immune cells in response to infection. Macrophages conglomerate around a specialized postcapillary venule referred to as a high endothelial venule (25, 29) with more immature cells located centrally with respect to mature macrophages (30). However, avascular or so-called secondary milky spots exist as well (16). Most commonly, B and T lymphocytes are also located periarteriolar, but they do not appear to organize into lymphoid follicles (23, 25, 30). However, macrophages and B cells have been also been observed to segregate to discrete regions within the milky spot with T cells interspersed throughout (21). Autonomic nerve fibers (parasympathetic and sympathetic) similar to those that innervate the visceral peritoneum, are also present in the omentum and traverse the milky spots (30) and adult stem cells within the adipose-rich region of the greater omentum (2, 25, 31). These undoubtedly contribute to the clinically relevant properties of this tissue during healing and control of infection.

IMMUNOLOGICAL FUNCTION

Milky spots are dense conglomerations of immune cells interspersed throughout the adipose-rich region of the greater omentum forming immunological units (Fig. 2). Milky spots are composed of approximately a half million immune cells (32) distributed between macrophages (approximately 1/3), and B and T lymphocytes, plus a few mast cells (2, 25, 30, 32). The proportion between immune cells within the omentum has been shown with some degree of discrepancy by various reports (see legend in Fig. 2). They display a phenotypic spectrum of omental and peritoneal macrophages that is dependent upon the genetics, nutritional status, and tissue microenvironment (33). Thus, there are variable ratios of macrophages and lymphocytes observed among individual milky spots (27). Additionally, myeloid progenitor cells within omental milky spots are thought to be the source of inflammatory cells in the peritoneal cavity (2, 34). Milky spots are hypothesized to be a sight for extramedullary megakaryopoiesis and neutrophil myelopoiesis due to the presence

of large megakaryocytes within these units in some species (35). Overlying milky spots, the mesothelial cell layer is fenestrated and the basement membrane is absent (2), allowing for the rapid egress of neutrophils from the circulation into the peritoneal cavity in response to infection. Interestingly, the transmigration of neutrophils across high endothelial venules within the omentum is more rapid than across conventional postcapillary venules. This transmigration requires a unique combination of selectins and cellular adhesion molecules to complete this process (36). Dysfunction of these molecules allows for the spread of infection (22, 36). When these adhesion molecules are blocked with monoclonal antibodies, neutrophil phagocytosis of bacteria is negatively affected, and bacterial counts within the peritoneum are increased (22). However, a recent study has shown that the infiltration of neutrophils into the peritoneum during inflammation is not impaired in absence of the omentum suggesting that the existence of alternative routes for the translocation of these cells into the cavity (37). Other inflammatory cells including B and T lymphocytes also use high endothelial venules to traverse the peritoneal cavity (19, 38). Berberich et. al. (39) demonstrated that this pathway was utilized by a subset of B2 lymphocytes in addition to an alternative route to egress from the peritoneum and return to the systemic circulation via parathymic lymph nodes. This observation suggests there is redundancy in the immune surveillance of the peritoneal cavity. The number of milky spots increases in response to infection similar to the vascular response to inflammation. Moreover, the reticular connective tissue network within individual milky spots expands as well (21). Enlargement of milky spots is accompanied by an increase in the cellularity of the peritoneal cavity especially with respect to macrophages. There is also a rapid influx of neutrophils with stimulation (21), which is followed shortly thereafter with a rise in the number of macrophages within hours of the insult leading to milky spot saturation within a day (23). Omental macrophages concentrate intraperitoneally injected foreign materials (16) and display a phagocytic phenotype upon infection (21). B1 lymphocytes compose the dominant fraction of B cells present in milky spots. They bind bacterial antigens and produce natural antibodies; a significant contribution to the adaptive immune response (40). These cells require specific intercellular signals for proper localization to the omentum and milky spot formation. These signals actually require the presence of bacteria to stimulate high endothelial venule endothelium and omental macrophages (41). Omental B-cells are similar to systemic B lymphocytes with regard to their ratios of IgG to IgA differentiation and level of somatic hypermutation (42).

ARE MILKY SPOTS SECONDARY LYMPHOID ORGANS?

While it is widely accepted that milky spots are an immune unit, there is debate regarding their role as a perivascular infiltrate versus a secondary lymphoid organ due to the variant structure from lymph nodes and spleen (43). The number and mass of milky spots increase in response to intra-abdominal stimulation and decreases with age (20, 21, 25, 44). This argues for their identity as a specialized lymphoid organ since inflammation typically increases with age (32). CD4⁺ and CD8⁺ T cell clones are specifically primed to antigens that have been retrieved from the omentum and peritoneal cavity. This observation indicates that peripherally activated populations of T-cells circulate through the omentum and peritoneal cavity to survey contributing to a secondary immune response (45). There is also

a perceived paucity of follicular dendritic cells, which are specialized antigen-presenting cells within the omentum. However, dendritic cells have been observed to be present in milky spots possibly in an immature form in transit between the omentum and the peritoneal cavity (19, 21, 45). Their presence makes an argument for the classification of milky spots as a secondary lymphoid organ. Further, the humoral immune response of omental B cells in splenectomized individuals to peritoneal infection is equivalent to that observed in those with a full complement of secondary lymphoid organs (46). A robust humoral immune response is generated following intraperitoneal antigen injection in mice completely devoid of the spleen, lymph nodes, and Peyer's patches (45), while milky spots are present in these individuals devoid of secondary lymphoid organs. These observations indicate that perhaps the omentum may serve as an alternative secondary lymphoid organ, suggesting that, while milky spots may be distinct from conventional secondary lymphoid structures, they do possess the ability to function as such.

Finally, while milky spots have a distinct histologic behavior in comparison to traditional secondary lymphoid structures (21), the B-cell functions of isotype switching, affinity maturation, somatic hypermutation, and immune response to systemic antigens occur within milky spots (42) highlighting some similarities to the lymph nodes and the spleen. Additionally, germinal follicle centers rapidly form in the omentum following intraperitoneal viral inoculation (47). Thus, while they are structurally and functionally distinct from the other secondary lymphoid structures, the argument has been made that they are unique secondary lymphoid structures that play an important and evolving role in the immune response to infection within the peritoneal cavity (45). Perhaps the omentum and milky spots are structurally and functionally designed to serve the dual function of mechanically isolating bacteria and limiting the spread of infection while simultaneously mounting a humoral and cytotoxic immune response. This dual mission is evidenced by the macrophage predominance in the structure of milky spots combined with the previously described sophistication in the B cell response. Milky spots are structurally and functionally distinct from other secondary lymphoid organs because they are involved in both the response to infection and the gross clearance of the infectious source. They perhaps represent a hybrid between innate and acquired immunity.

ROLE IN CONTROLLING INTRA-ABDOMINAL INFECTION

The best evidence that the omentum has a role in controlling intraabdominal infection is that omentectomy has a detrimental effect on both animal and human studies (2, 37, 48, 49). In a rat model of peritonitis using cecal ligation and puncture (CLP), the absolute number of macrophages isolated from the peritoneal cavity is increased following omentectomy (49). This is in distinction to the observation that the number of macrophages isolated from peritoneal lavage samples is significantly reduced in peritonitis due to alterations in the coagulation cascade and cellular adhesion resulting in macrophage adhesion to the peritoneum, which is referred to as "the macrophage disappearance reaction" (49). Agalar et al. (50) observed that shortly following omentectomy in rats the cell counts, chemotactic indices, and the ratio of macrophages to lymphocytes was negatively impacted. Similarly, Uzunkoy et al. (51) found that bacterial growth in cultures obtained from mesenteric lymphoid tissue and blood cultures in a model of peritonitis was elevated in rats that

underwent omentectomy as compared to those in which the omentum was left intact. Additionally, a recent study using a mouse model of intraabdominal sepsis (CLP) showed that the absence of the omentum has a detrimental impact on mortality. The increase in mortality was associated with a higher level of inflammatory cytokines including IL-6 and IL-10 (37). This study is perhaps the most convincing evidence that the omentum plays a significant role in the body's response to intrabdominal sepsis.

In humans, when the omentum is purposefully removed in an effort to decrease adhesion formation and limit subsequent bowel obstructions, a larger incidence of peritonitis has been observed, whereas the rate of small bowel obstruction was unchanged (48), which has resulted in a reduction in the practice of omentectomy. Evidence suggests that the omentum can contribute to the management of infection and given the detrimental effect omentectomy has upon outcomes related to intraabdominal infection, it raises the question of what is the involved mechanism? Based on our existing knowledge, it is likely that it is manifested through several mechanisms. First, the omentum has the ability to encapsulate areas of infection and necrosis allowing for the clearance of pathogens and dead tissue (36, 52). Its mobility allows the omentum to contact areas of localized injury. Due to its tremendous surface area in combination with its limited fixation and mobility, the omentum is afforded access to the vast majority of pathologies that can befall the abdomen. How exactly this occurs remains poorly understood, but it has been suggested that tissue damage during inflammation and peritoneal irritation alters the homeostasis of fibrin and thrombin deposition and lysis allowing the omentum to adhere to and segregate infection and injury (49). Second, the omentum is the major route of delivery for inflammatory mediators into the peritoneum (21), which is critical in the control of infection (53). Although macrophages can be delivered to the peritoneal cavity from a variety of other sources, the gross mobility of the omentum along with its ability to adhere to damaged tissues provides a rapid influx of concentrated inflammatory cells to rapidly deal with an infection, resulting from perforation, in isolation from the remainder of the coelomic cavity. Phagocytic cells derived from other sources do not possess gross mobility on this scale and are limited to migration on a microscopic level. This observation suggests a survival benefit for the redundancy built into the omental portal to the peritoneal cavity. Perhaps the leukocytes delivered to the abdomen via alternate pathways are qualitatively limited in their ability to combat the gross spread of infection despite being quantitatively similar due to the distinct source from which they are derived.

Finally, the omentum has tremendous signaling and regenerative properties that may play a fundamental role in improving the outcome from infection (2). The cellular components of the omentum have the ability to trigger the production of inflammatory cytokines and antimicrobial peptides (36). Paracrine signals conducted by nerve fibers traversing the milky spots (30) could stimulate the central nervous system (CNS) and potentially influence the hypothalamic pituitary adrenal axis (HPAA). Furthermore, the rich adipose tissue within the omentum is likely to contribute to additional endocrine signals (26). Indeed, there is a growing body of evidence demonstrating complex interactions between lymphoid structures and adipose tissue (54–56). These signaling pathways in conjunction with the stem cells present within the adipose-rich regions of the omentum (2, 25, 31) are likely vital in the response to intraabdominal infection and in the regenerative properties of the organ.

In summary, the omentum is the main avenue for the infiltration of inflammatory cells into the peritoneum (21) and the absence of this portal results in the spread of infection and peritonitis (36). The characteristics and organization of the immune response to infection are altered by the absence of the omentum and omentectomy negatively impacts peritoneal defense mechanisms (2). Consequently, the ability to limit the spread of infection and to recruit inflammatory reinforcements from the systemic circulation is limited. This allows for the spread of infection throughout the peritoneal cavity which can lead to generalized peritonitis, extreme inflammation, and even death. Thus, the tremendous importance of the omentum, a vibrant immunologic organ, cannot be overstated.

AREAS FOR FUTURE STUDY

Despite the important role the omentum plays in controlling intraabdominal infection, the mechanism of how this remarkable organ accomplishes its function is still unclear. The migratory nature of the omentum is well appreciated, yet the underlying processes are vaguely described. In clinical practice, some patients physiologically compensate quite well in the setting of peritonitis (ex. perforated appendicitis) in the short term whereas others decompensate quickly. The study of omental migration and adhesion could shed light on these observations. There is also considerable evidence suggesting that omentectomy results in a state of immune compromise. However, omentectomy is routinely performed for treatment of malignant processes involving the stomach, colon, and ovary both for therapeutic and staging purposes (29). It is also commonly removed during the placement of peritoneal dialysis catheters in the pediatric population to prevent catheter malfunction. Research into the long-term consequences of these practices both clinically and immunologically is warranted. Additionally, as previously highlighted, the number of milky spots does decrease with age and the impact of this phenomenon has not been studied.

The role of the omentum in peritonitis is inferred from the observation of significant populations of inflammatory cells found within milky spots, the ability for pathogens to move beyond the peritoneal cavity following omentectomy, and the histologic organization of the organ in relation to blood vessels, nerves, and adipose tissue. However, the details surrounding the complexity of intercellular signaling and the interface between the local and systemic responses are not described. Further investigations are necessary to illuminate signaling pathways at play within the omentum.

CONCLUDING REMARKS

In summary, the omentum is an enigmatic immunologic organ uniquely suited for defense against pathogens and injury within the peritoneal cavity. The microscopic functional unit of the organ, the milky spot, is rich in macrophages and lymphocytes organized around a specialized postcapillary venule allowing for the rapid influx of inflammatory mediators into the peritoneal cavity in response to injury and infection. These functional units are widely distributed throughout the adipose-rich regions of the organ and, along with a population of resident stem cells, are largely responsible for the remarkable properties of infection control, wound healing, and tissue regeneration that are widely appreciated and applied clinically. Thus, the omentum is much more than visceral fat and peritoneal insulation. It is a versatile

and mobile immunologic organ poised to guard against infection and inflammation within the abdomen.

Acknowledgments

Support: Support was provided by the National Institutes of Health (NIH) Grant R01 GM114473-01.

REFERENCES

- Collins D, Hogan AM, O'Shea, Winter DC. The omentum: anatomical, metabolic, and surgical aspects. *J Gastrointest Surg* 2009. 13 6:1138–1146, 2009.
- Platell C, Cooper D, Papadimitriou JM, Hall JC. The omentum. *World J Gastroenterol* 6 2:169–176, 2000. [PubMed: 11819552]
- Graham RR. The treatment of perforated duodenal ulcers. *Surg Gynecol Obstet* 64:235–238, 1937.
- Diesen DL, Skinner MA. Spontaneous sealing of a neonatal intestinal perforation by the omentum. *J Pediatr Surg* 43 12:2308–2310, 2008. [PubMed: 19040962]
- Singh A, Gora N, Soni ML, Khandelwal RG, Vidyarthi SH, Thounaojam CK. Comparative study of free omental sheet graft and other operative procedures of enteric perforation repair. *J Gastrointest Surg* 18 4:751–756, 2014. [PubMed: 24474632]
- Thörne A, Lönnqvist F, Aelman J, Hellers G, Arner P. A pilot study of long-term effects of a novel obesity treatment: omentectomy in connection with adjustable gastric banding. *Int J Obes* 26 2:193–199, 2002.
- Andersson DP, Eriksson-Hogling D, Bäckdahl J, Thorell A, Lofgren P, Ryden M.. Omentectomy in Addition to Bariatric Surgery-a 5-Year Follow-up. *Obes Surg* 27 4:1115–1118, 2017. [PubMed: 28155057]
- Coffey JC, O'Leary DP. Defining the mesentery as a new organ and what this means for understanding its roles in digestive disorders. *Expert Rev Gastroenterol Hepatol* 11 8:703–705, 2017. [PubMed: 28482706]
- Meza-Perez S, Randall TD. Immunological Functions of the Omentum. *Trends Immunol* 38 7:526–536, 2017. [PubMed: 28579319]
- Sadler TW. *Langman's Essential Medical Embryology*. Philadelphia, PA USA: Lippincott Williams & Wilkins 2005.
- Sompayrac SW, Mindelzun RE, Silverman PM, Sze R. The greater omentum. *Am J Roentgenol* 168 3:683–687, 1997. [PubMed: 9057515]
- Liebermann-Meffert D The greater omentum. Anatomy, embryology, and surgical applications. *Surg Clin North Am* 80 1:275–293, 2000. [PubMed: 10685153]
- Gross BH, Callen PW, Filly RA. Ultrasound appearance of fetal greater omentum. *J Ultrasound Med* 1 2:67–69, 1982. [PubMed: 6152928]
- Krist LF, Koenen H, Calame W, van der Harten JJ, van der Linden JC, Eestermans IL. Ontogeny of milky spots in the human greater omentum: an immunochemical study. *Anat Rec* 249 3:399–404, 1997. [PubMed: 9372174]
- Shimotsuma M, Simpson-Morgan MW, Takahashi T, Hagiwara A. Ontogeny of milky spots in the fetal lamb omentum. *Arch Histol Cytol* 57 3:291–299, 1994. [PubMed: 7818952]
- Zhu H, Naito M, Umezu H, Moriyama H, Takatsuka H, Takahashi K. Macrophage differentiation and expression of macrophage colony-stimulating factor in murine milky spots and omentum after macrophage elimination. *J Leukoc Biol* 61 4:436–444, 1997. [PubMed: 9103230]
- Solvason N, Kearney JF. The human fetal omentum: a site of B cell generation. *J Exp Med* 175 2:397–404, 1992. [PubMed: 1370683]
- Wilkosz S, Ireland G, Khwaja N, Walker M, Butt R, de Giorgio-Miller A. A comparative study of the structure of human and murine greater omentum. *Anat Embryol (Berl)* 209 3:251–261, 2005. [PubMed: 15662530]
- Carlow DA, Gold MR, Ziltener HJ. Lymphocytes in the peritoneum home to the omentum and are activated by resident dendritic cells. *J Immunol* 183 2:1155–1165, 2009. [PubMed: 19553538]

20. Litbarg NO, Gudehithlu KP, Sethupathi P, Arruda JAL, Dunea G, Singh AK. Activated omentum becomes rich in factors that promote healing and tissue regeneration. *Cell Tissue Res* 328 3:487–497, 2007. [PubMed: 17468892]
21. Van Vugt E, Van Rijthoven EAM, Kamperdijk EWA, Beelen RHJ. Omental milky spots in the local immune response in the peritoneal cavity of rats. *Anat Rec* 245 :235–245, 1996. [PubMed: 8769666]
22. Doherty NS, Griffiths RJ, Hakkinen JP, Scampoli DN, Milici AJ. Post-capillary venules in the “milky spots” of the greater omentum are the major site of plasma protein and leukocyte extravasation in rodent models of peritonitis. *Inflamm Res* 44 4:169–177, 1995. [PubMed: 7545527]
23. Shimotsuma M, Simpson-Morgan MW, Takahashi T, Hagiwara A. Activation of omental milky spots and milky spot macrophages by intraperitoneal administration of a streptococcal preparation, OK-432. *CANCER Res* 52:5400–5402, 1992. [PubMed: 1394145]
24. Fedorko ME, Hirsch JG, Fried B. Studies on transport of macromolecules and small particles across mesothelial cells of the mouse omentum. II. Kinetic features and metabolic requirements. *Exp Cell Res* 69 1:113–127, 1971. [PubMed: 4330918]
25. Liu J, Geng X, Li Y. Milky spots: omental functional units and hotbeds for peritoneal cancer metastasis. *Tumor Biol* 37 5:5715–5726, 2016.
26. Michailova KN, Usunoff KG. The milky spots of the peritoneum and pleura: Structure, development and pathology. *Biomed Rev* 15 1:47–66, 2004.
27. Liu J-Y, Yuan J-P, Geng X-F, Qu A-P, Li Y. Morphological study and comprehensive cellular constituents of milky spots in the human omentum. *Int J Clin Exp Pathol* 8 10:12877–12884, 2015. [PubMed: 26722479]
28. Mironov VA, Gusev SA, Baradi AF. Mesothelial stomata overlying omental milky spots: scanning electron microscopic study. *Cell Tissue Res* 201 2:327–330, 1979. [PubMed: 315819]
29. Sorensen EW, Gerber SA, Sedlacek AL, Rybalko VY, Chan WM, Lord EM. Omental immune aggregates and tumor metastasis within the peritoneal cavity. *Immunol Res* 45 2–3:185–194, 2009. [PubMed: 19253004]
30. Yildirim A, Akta A, Nergiz Y, Akku M. Analysis of human omentum-associated lymphoid tissue components with S-100: an immunohistochemical study. *Rom J Morphol Embryol* 51 4:759–764, 2010. [PubMed: 21103638]
31. Shah S, Lowery E, Braun RK, Martin A, Huang N, Medina M. Cellular basis of tissue regeneration by omentum. Kerkis I, ed. *PLoS One* 7 6:e38368, 2012. [PubMed: 22701632]
32. Shimotsuma M, Takahashi T, Kawata M, Dux K. Cellular subsets of the milky spots in the human greater omentum. *Cell Tissue Res* 264 3:599–601, 1991. [PubMed: 1868524]
33. Okabe Y, Medzhitov R. Tissue-specific signals control reversible program of localization and functional polarization of macrophages. *Cell* 157 4:832–844, 2014. [PubMed: 24792964]
34. Pinho Mse-F, Hurtado SP, El-Cheikh MC, Rossi MI, Dutra HS, Borojevic R. Myelopoiesis in the omentum of normal mice and during abdominal inflammatory processes. *Cell Tissue Res* 308 1:87–96, 2002. [PubMed: 12012208]
35. Takemori N, Hirai K, Onodera R, Saito N, Namiki M. Light and electron microscopic study of omental milky spots in New Zealand Black mice, with special reference to the extramedullary hematopoiesis. *Anat Embryol (Berl)* 189:215–226, 1994. [PubMed: 8042764]
36. Buscher K, Wang H, Zhang X, Striewski P, Wirth B, Saggi G. Protection from septic peritonitis by rapid neutrophil recruitment through omental high endothelial venules. *Nat Commun* 7:1–7, 2016.
37. Wang AW, Cauvi DM, Hawisher D, Reyes T, Coimbra R, Bickler S, De Maio A. The Contribution of The Omentum to the Outcome From Sepsis: An Experimental Animal Study. *Shock PMID* 30601409, 2018.
38. Cui L, Johkura K, Liang Y, Teng R, Ogiwara N, Okouchi Y, Asanuma K, Sasaki K. Biodefense function of omental milky spots through cell adhesion molecules and leukocyte proliferation. *Cell Tissue Res* 310 3:321–330, 2002. [PubMed: 12457231]
39. Berberich S, Dahne S, Schippers A, Peters T, Muller W, Kremmer E. Differential molecular and anatomical basis for B cell migration into the peritoneal cavity and omental milky spots. *J Immunol* 180 4:2196–2203, 2008. [PubMed: 18250426]

40. Mebius RE. Lymphoid organs for peritoneal cavity immune response: milky spots. *Immunity* 30 5:670–672, 2009. [PubMed: 19464991]
41. Ansel KM, Harris RBS, Cyster JG. CXCL13 Is required for B1 cell homing, natural antibody production, and body cavity immunity. *Immunity* 16:67–76, 2002. [PubMed: 11825566]
42. Boursier L, Montalto SA, Raju S, Culora G, Spencer J. Characterization of cells of the B lineage in the human adult greater omentum. *Immunology* 119 1:90–97, 2006. [PubMed: 16787506]
43. Rangel-Moreno J, Moyron-Quiroz JE, Carragher DM, Kusser K, Hartson L, Moquin A. Omental milky spots develop in the absence of lymphoid tissue-inducer cells and support B and T cell responses to peritoneal antigens. *Immunity* 30:731–743, 2009. [PubMed: 19427241]
44. Beelen RHJ, Oosterling SJ, van Egmond M, van den Born J, Zareie M. Omental milky spots in peritoneal pathophysiology (spots before your eyes). *Perit Dial Int* 25:30–32, 2005. [PubMed: 15770922]
45. Bedford PA, Todorovic V, Westcott EDA, Windsor AC, English NR, Al-Hassi HO. Adipose tissue of human omentum is a major source of dendritic cells, which lose MHC Class II and stimulatory function in Crohn's disease. *J Leukoc Biol* 80 3:546, 2006. [PubMed: 16822853]
46. Jones DD, Racine R, Wittmer ST, Harston L, Papillon AM, Dishaw LM. The omentum is a site of protective IgM production during intracellular bacterial infection. *Infect Immun* 83 5:2139–2147, 2015. [PubMed: 25776744]
47. Gray KS, Collins CM, Speck SH. Characterization of omental immune aggregates during establishment of a latent gammaherpesvirus infection. *PLoS One* 7 8:e43196, 2012. [PubMed: 22952645]
48. Ambroze WL Jr., Wolff BG, Kelly KA, Beart RW Jr., Dozois RR, Ilstrup DM. Let sleeping dogs lie: role of the omentum in the ileal pouch-anal anastomosis procedure. *Dis Colon Rectum* 34 7:563–565, 1991. [PubMed: 1905221]
49. Agca B, Paksoy M, Polat E, Aksin E, Dirican A, Durgun V. Influence of omentectomy on peritoneal defense mechanisms in an experimental model of intra-abdominal infection. *Eur Surg Res* 35 1:35–40, 2003. [PubMed: 12566785]
50. Agalar F, Sayek I, Cakmakci M, Hascelik G, Abbasoglu O. Effect of omentectomy on peritoneal defence mechanisms in rats. *Eur J Surg* 163 8:605–609, 1997. [PubMed: 9298913]
51. Uzunköy A, Ozbilge H, Horoz M. The influence of omentectomy on bacterial clearance: an experimental study Omentektominin bakteriyel çö alma üzerine etkisi: Deneysel çalı ma. *Ulus Travma Acil Cerrahi Derg* 15 6:541–545, 2009. [PubMed: 20037870]
52. Konturek SJ, Brzozowski T, Majka I, Pawlik W, Stachura J. Omentum and basic fibroblast growth factor in healing of chronic gastric ulcerations in rats. *Dig Dis Sci* 39 5:1064–1071, 1994. [PubMed: 7513630]
53. Li Y, Karlin A, Loike JD, Silverstein SC. A critical concentration of neutrophils is required for effective bacterial killing in suspension. *Proc Natl Acad Sci* 99 12:8289–8294, 2002. [PubMed: 12060772]
54. Pond CM. Adipose tissue and the immune system. *Prostaglandins Leukot Essent Fatty Acids*. 73:17–30, 2005. [PubMed: 15946832]
55. Harman-Boehm I, et al., Macrophage infiltration into omental versus subcutaneous fat across different populations: effect of regional adiposity and the comorbidities of obesity. *J Clin Endocrinol Metab*, 2007 92(6): p. 2240–7. [PubMed: 17374712]
56. Tsujimura Y, Matsutani T, Matsuda A, Kutsukake M, Uchida E, Sasajima KI. Effects of pioglitazone on survival and omental adipocyte function in mice with sepsis induced by cecal ligation and puncture. *J Surg Res* 171 2:e215–e221, 2011. [PubMed: 21962804]

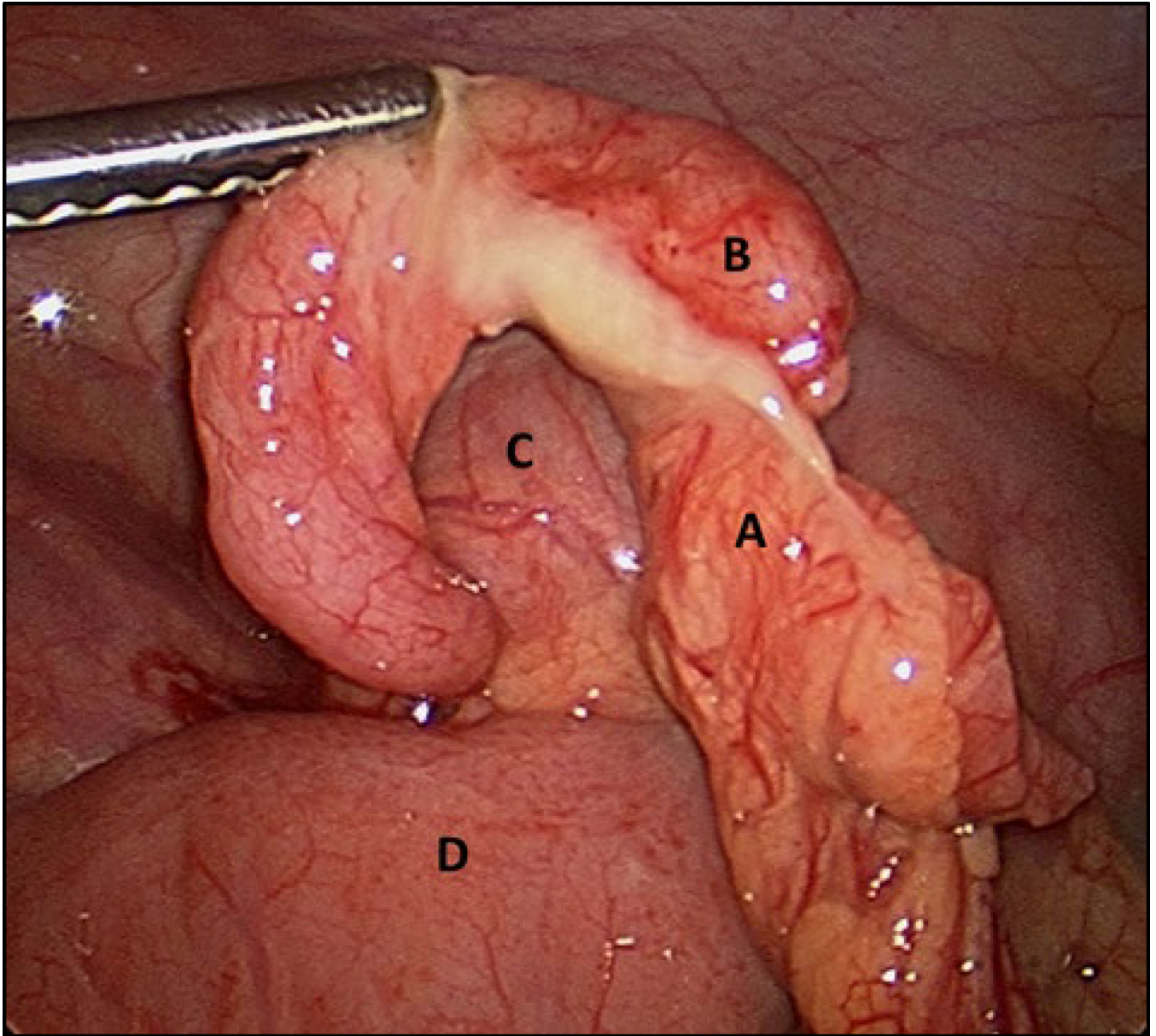


Fig. 1. Intraoperative photo of the human omentum (A) joining an inflamed appendix at the tip (B), demonstrating its great capacity for tissue adhesion. Other organs within the picture correspond to the cecum (C), and small bowel (D).

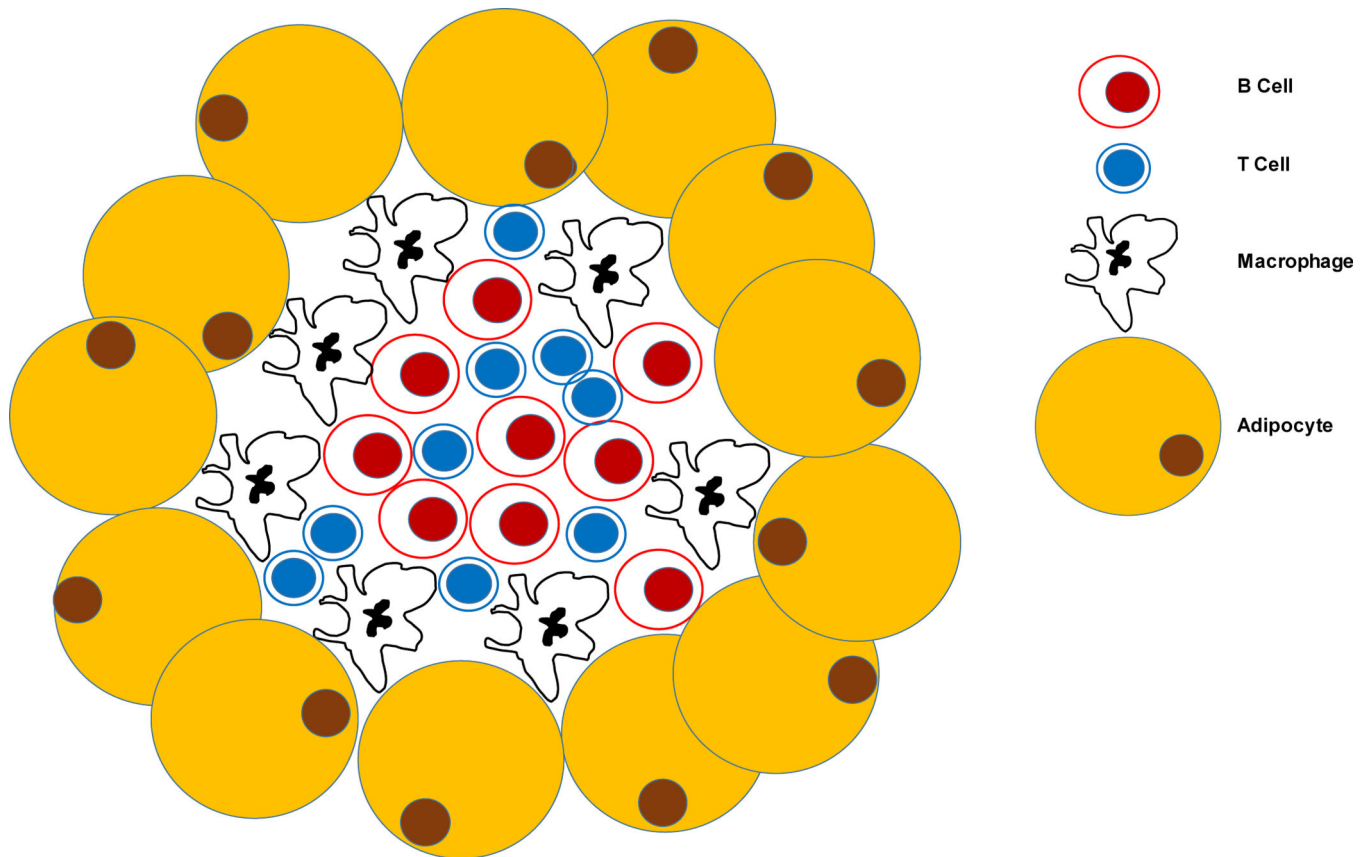


Fig. 2. Scheme displaying the different composition of immune cells within the Milky spots. Milky spots are made up of a variety of immune cells, mainly macrophages, B and T cells with different proportions and localized in an apparent orderly manner with B and T cells in the center surrounded by macrophages. The relative composition of immune cells within the Milky spots showed some degree of discrepancy between various reports. Thus, macrophages have been reported to vary between 68 to 12%, T cells between 46 to 12% and B cells between 29 to 10% (32, 14, 25).