

UC Davis

UC Davis Previously Published Works

Title

Radiographic outcome of root canal treatment of canine teeth in cats: 32 cases (1998-2016).

Permalink

<https://escholarship.org/uc/item/91k9q8ns>

Journal

Journal of the American Veterinary Medical Association, 252(5)

ISSN

0003-1488

Authors

Strøm, Peter C
Arzi, Boaz
Lommer, Milinda J
et al.

Publication Date

2018-03-01

DOI

10.2460/javma.252.5.572

Peer reviewed

Radiographic outcome of root canal treatment of canine teeth in cats: 32 cases (1998–2016)

Peter C. Strøm DVM, MSc

Boaz Arzi DVM

Milinda J. Lommer DVM

Helena Kuntsi DVM

Amy J. Fulton Scanlan DVM

Philip H. Kass DVM, PhD

Frank J. M. Verstraete DrMedVet, MMedVet

From the William R. Pritchard Veterinary Medical Teaching Hospital (Strøm) and Departments of Surgical and Radiological Sciences (Arzi, Lommer, Fulton Scanlan, Verstraete) and Population Health and Reproduction (Kass), School of Veterinary Medicine, University of California-Davis, Davis, CA 95616; Aggie Animal Dental Center, 487 Miller Ave, Mill Valley, CA 94941 (Lommer, Fulton Scanlan); and Anident Veterinary Clinic, Lamminpaantie 43, 02880 Veikkola, Finland (Kuntsi). Dr. Strøm's present address Accessia AB, Slottsmöllan (G), 302 31 Halmstad, Sweden.

Address correspondence to Dr. Verstraete (fjverstraete@ucdavis.edu).

OBJECTIVE

To describe the radiographic outcome of root canal treatment (RCT) of canine teeth of cats.

DESIGN

Retrospective case series.

ANIMALS

32 cats with 37 canine teeth with complicated crown fractures that underwent RCT.

PROCEDURES

Medical record databases of 5 referral veterinary hospitals were searched to identify cats that underwent RCT between 1998 and 2016. Only cats that had at least 1 follow-up examination during which radiographs were obtained of the treated canine tooth or teeth were included in the study. Dental radiographs obtained before and immediately after RCT and during all follow-up examinations were reviewed. Treatment was considered successful if the periodontal ligament space was within reference limits and preoperative external inflammatory root resorption (EIRR), if present, had stabilized. Treatment was considered to have no evidence of failure if preoperative EIRR had stabilized and preexisting periapical lucency was stable or decreased in size but had not resolved. Treatment was considered to have failed if periapical lucency or EIRR developed subsequent to RCT or preexisting periapical lucency increased in size or preoperative EIRR progressed following RCT.

RESULTS

Follow-up time after RCT ranged from 3 to 72 months. The RCT was successful for 18 (49%) of the 37 treated teeth, had no evidence of failure for 12 (32%), and failed for 7 (19%). Preexisting EIRR and patient age \geq 5 years significantly increased the rate of RCT failure.

CONCLUSIONS AND CLINICAL RELEVANCE

Results indicated that RCT was a viable treatment option to salvage endodontically diseased canine teeth in cats. (*J Am Vet Med Assoc* 2018;252:572–580)

Endodontics is a discipline within the field of dentistry aimed at prevention, diagnosis, and treatment of conditions and injuries of the dental pulp and periapical tissues.^{1–3} Endodontic treatment allows preservation of teeth with pulp disease as an alternative to dental extraction. Pulp disease is a source of pain in animals and may go unnoticed or, in some cases, may be ignored by owners and veterinarians. Root canal treatment is an option for teeth in which pulp inflammation (pulpitis) has or will become irreversible leading to pulp necrosis.⁴ There are several possible etiologies for pulpitis. In cats, dental fracture is the most common cause of pulp disease,^{5–7} perhaps

because the anatomic structure of the canine teeth, in which the pulp cavity is very close to the tip of the crown, is such that most crown fractures expose the pulp. If left untreated, pulpitis will develop as a consequence of pulp exposure and allow bacteria to travel through the pulp to the periapical tissue, resulting in infection and inflammation of the periapical tissue and development of apical periodontitis.⁸

Apical periodontitis is a pathological change of the periapical tissue that frequently develops as a consequence of irreversible pulpitis. In the presence of direct pulp exposure, nonspecific and specific inflammatory mediators, such as kinins, cytokines, complement fragments, and antigens, invade the pulp and eventually the periapical tissue. Apical periodontitis is classified into different stages. Initially, the first extension of pulp pathology into the periapical tissue is an egress of inflammatory mediators, such as bacterial toxins. This early process may not necessarily be associated with PL, which typically develops later in the process.⁸

The goal of RCT is to salvage the tooth and eliminate pulpal and periapical infection and inflamma-

ABBREVIATIONS

CI	Confidence interval
EIRR	External inflammatory root resorption
IRR	Incidence rate ratio
NEF	No evidence of failure
PDL	Periodontal ligament
PL	Periapical lucency
RCT	Root canal treatment

tion. Root canal treatment entails removal of the pulp tissue followed by cleaning, disinfection, shaping, preparing, and solid obturation of the pulp cavity with biologically inert materials.⁹⁻¹¹

Although the teeth of cats are substantially smaller than the teeth of dogs, they have similar morphology. In cats, RCT can be challenging owing to the small size of the teeth; therefore, the procedure is most commonly limited to the canine teeth because they are of adequate size and the most amenable to endodontic treatment. Root canal treatment has been described and is an accepted treatment modality in cats.^{1,5,7,9,12} However, the success rate of RCT in cats has not been reported to date, and our understanding of RCT success rates stem from human² and dog¹² studies. Thus, the purpose of the study reported here was to describe the outcome of RCT of canine teeth in cats.

Materials and Methods

Case selection criteria

The medical record databases of 2 veterinary teaching hospitals (University of California-Davis William R. Pritchard Veterinary Medical Teaching Hospital and Cornell University Hospital for Animals) and 3 private dental specialty practices (Aggie Animal Dental Center in Mill Valley, Calif; Animal Dental Clinic in San Carlos, Calif; and Anident Veterinary Clinic in Veikkola, Finland) were searched to identify cats that underwent RCT of at least 1 canine tooth between 1998 and 2016. Only cats that had at least 1 recheck appointment following RCT during which they were anesthetized and had radiographs obtained of the treated tooth or teeth were included in the study. Also, all teeth assessed in the study had to be free of severe periodontal disease or evidence of resorptive lesions.

Medical records review

For each cat included in the study, information extracted from the medical record included signalment, affected teeth, and reason for RCT. All dental radiographic images obtained before and immediately after RCT and during all follow-up examinations were reviewed.

RCT procedure

All RCTs were performed by diplomates of the American Veterinary Dental College or veterinary trainees under their supervision in accordance with the quality guidelines for endodontic treatment established by the European Society of Endodontology^{13,14} and modified to accommodate the anatomy of the canine teeth of cats.^{9,15} Radiographic images of the affected teeth were obtained by use of the bisecting angle technique¹⁶ prior to and immediately after RCT. Digital (indirect) and conventional analog dental plate and film sizes of 0, 2, and 4 were used. All treated teeth were ultrasonically or sonically scaled prior to RCT. A straight-line occlusal surface access preparation was performed in all cats, with the exception of 1, which required additional mesial access to the pulp

cavity. Prior to pulp cavity obturation, the root canal was cleaned, disinfected, and shaped with handheld endodontic files and rotary instruments. Sodium hypochlorite (2.5% to 8.25%) irrigation solution was used as a disinfectant and for chemomechanical preparation of the canal, and file lubrication was achieved by use of uniquely formulated glycol, peroxide, and EDTA chelating gels.¹⁷ For cats in which RCT was staged, a calcium hydroxide dressing and temporary filling were placed on the affected tooth until definitive obturation could be performed. Final obturation was completed with crystalline forms of gutta-percha^a and resin-based endodontic sealers.^b Methods of obturation used were single-cone thermoplastic gutta-percha,^c vertical compaction with thermoplastic gutta-percha,^{d-f} single-cone gutta-percha with flowable gutta-percha,^{g,h} and single-cone gutta-percha with a root canal sealer.ⁱ Pulp access sites were restored with a glass ionomer intermediate layer and composite resin final restorative or with a composite resin restorative.^j

Follow-up evaluations

During each follow-up examination, each cat was anesthetized and radiographic images of the treated tooth or teeth were obtained by use of the bisecting angle technique.¹⁶ Digital (indirect) and conventional analog dental plate and film sizes of 0, 2, and 4 were used. Standard protocol was to request follow-up examinations at 3 and 12 months after the RCT and annually thereafter. For statistical analyses, follow-up periods were grouped as follows: < 3 months, 4 to 12 months, 13 to 24 months, and ≥ 25 months.

Outcome evaluation

All dental analog and digital radiographic images were individually evaluated by 3 observers (PCS, BA, and FJMV). Digital images were viewed on a medical-grade computer screen,^k and conventional analog dental radiographs were evaluated on an x-ray viewing box with a calibrated magnifying loupe.^l

To assess the quality of obturation, each pulp cavity was divided into thirds (coronal, middle, and apical). Within each third, voids were considered small if they were narrower than half the width of the obturated pulp cavity and shorter than the width of the obturated pulp cavity; all other voids were considered large. Overfill was recorded if there was radiopaque material in the periapical region. The largest diameter of any periapical lesion was measured, and comparable radiographic images obtained at each follow-up visit were examined. Widening of the PDL space was recorded if the space was greater than twice the width of the PDL space in other areas surrounding the root.

Root canal treatment outcome was classified as successful, NEF, or failure in accordance with guidelines for radiographic assessment of RCT established by the European Society of Endodontology.¹³ Treatment was considered successful if the periapical PDL space was within reference limits and preoperative EIRR, if present, had stabilized. Treatment was

considered to have NEF if preoperative EIRR had stabilized and preexisting PL remained the same or decreased in size but had not completely resolved. Treatment was considered to have failed if PL or EIRR developed subsequent to endodontic treatment or preexisting PL had increased in size or preoperative EIRR appeared to have progressed after RCT.

Statistical analysis

The outcome at the most recent (ie, last) follow-up examination was recorded for each cat. Dependent variables assessed included age, sex, preoperative pulp vitality, evidence of preoperative EIRR, evidence of a preoperative PL, method of obturation, quality of obturation (ie, voids), and evidence of extrusion of the sealant material periapically (ie, overfill). Patient weight was not considered an applicable dependent variable for RCT outcome in cats.

The Shapiro-Wilk test was used to evaluate the data distributions of all dependent variables for normality. The distributions for age, follow-up time, and time from pulp exposure to RCT were not normally distributed; therefore, results for those variables were reported as the median (range). Each factor was initially analyzed with a univariate Cox proportional hazards regression model with robust variance estimation to account for clustering of teeth within individual cats. A multivariable model was then created, which included only factors that had values of $P < 0.05$ on univariate analysis. Incidence rate ratios and the accompanying 95% CIs were used to quantify the results. Time to evaluation after RCT and success probability were assessed and compared among levels of potential predictive factors by use of the Kaplan-Meier method of time-to-event function estimation. All statistical analyses were performed with commercially available software,^m and values of $P < 0.05$ were considered significant.

Results

Cats

Fifty-six cats had RCT performed at the 5 participating hospitals during the period of 1998 to 2016; however, only 32 cats had post-RCT radiographic images available for review and were included in the study. The study population consisted of 21 castrated males, 9 spayed females, and 2 sexually intact females and had a median age of 5 years (range, 1 to 13 years; age was not recorded for 2 of the cats).

RCT outcome

Among the 32 cats, RCT was performed on 37 canine teeth, of which 33 (89%) were maxillary canine teeth and 4 (11%) were mandibular canine teeth. A complicated crown fracture was the sole reason for RCT in all cats. The median follow-up period was 14 months (range, 3 to 72 months).

The RCT outcome was classified as successful for 18 (49%) teeth (**Figure 1**), NEF for 12 (32%) teeth (**Figure 2**), and failure for 7 (19%) teeth (**Figure 3**). The

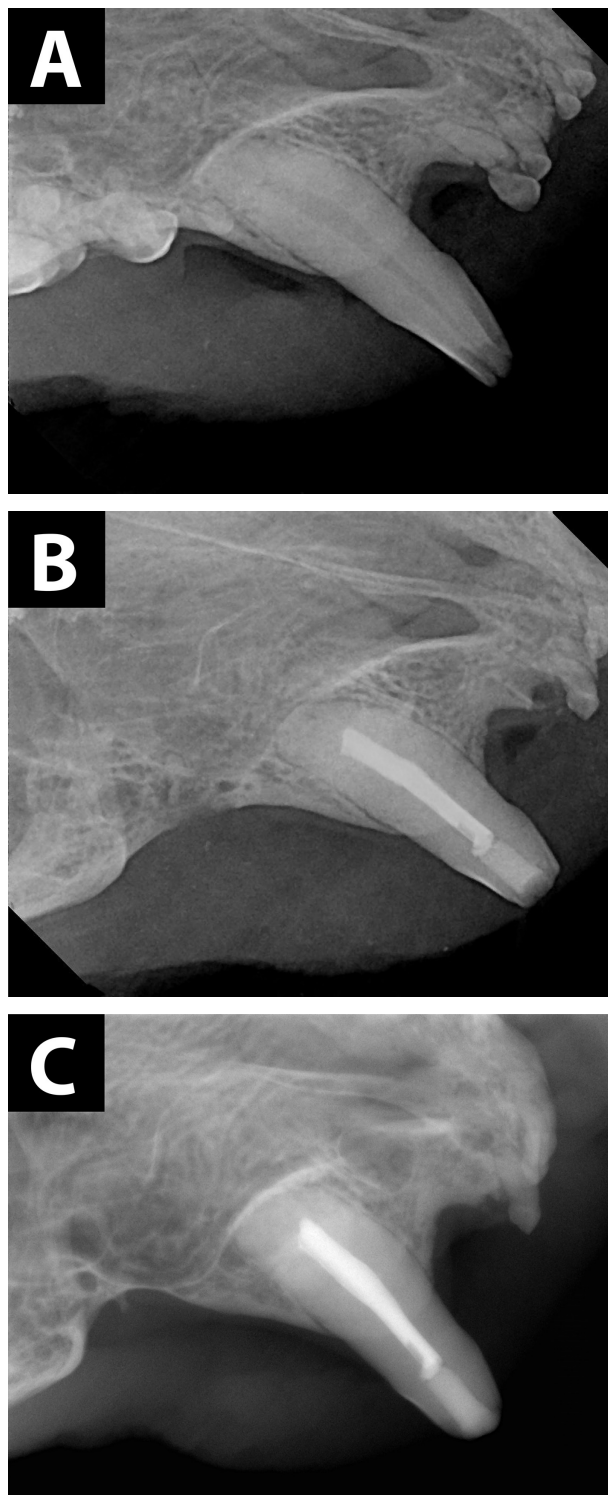


Figure 1—Intraoral lateral radiographic images of the right maxillary canine tooth of an 8-year-old castrated male Siamese-mix cat with a complicated crown fracture before (A), immediately after (B), and at the last follow-up examination 4 years after (C) RCT, which resulted in a successful outcome. All images were obtained with conventional analog radiography by use of a bisecting angle technique. In panel B, notice the vacated alveolus of the second premolar tooth and retention of a root fragment of the third premolar tooth following unsuccessful extraction. In panel C, a linear void in the apical obturation is visible.

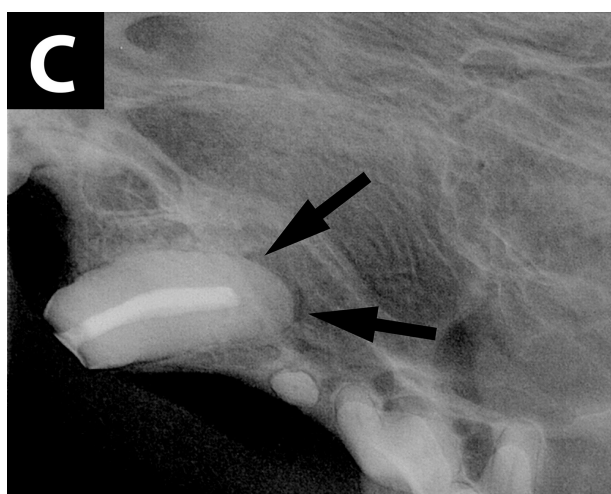
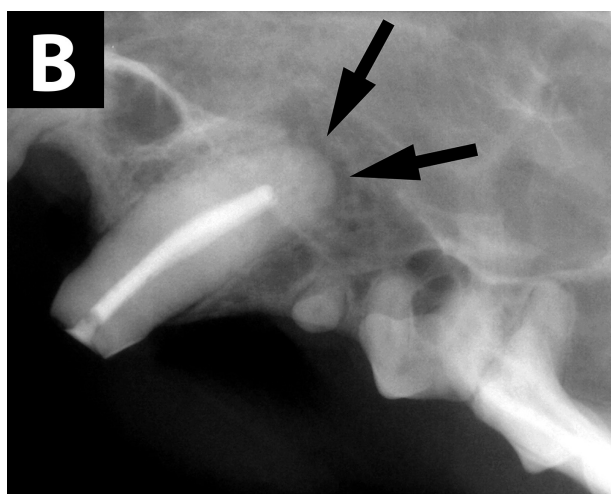
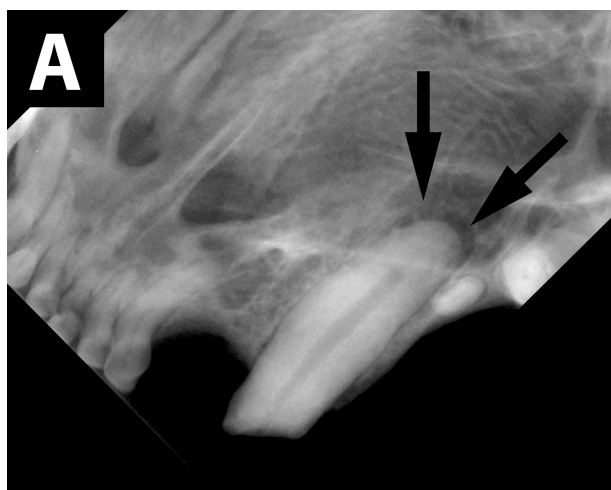


Figure 2—Intraoral lateral radiographic images of the left maxillary canine tooth of a 9-year-old castrated male domestic shorthair cat with a complicated crown fracture and PL (arrows) before (A), immediately after (B), and at the last follow-up examination 18 months after (C) RCT, which was classified as having NEF because the PL appeared to remain fairly stable in size following the procedure. **See Figure 1** for remainder of key.

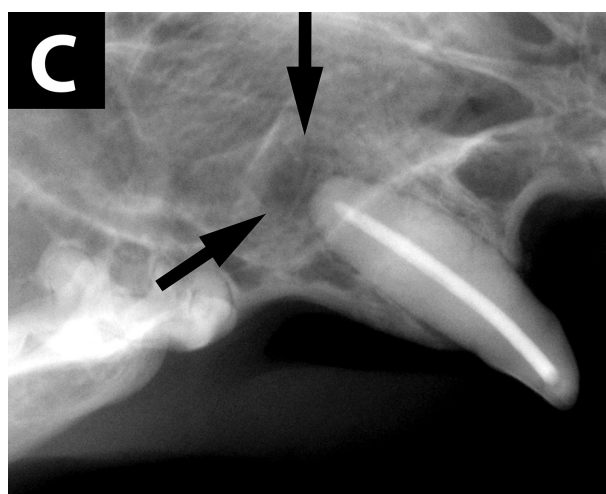
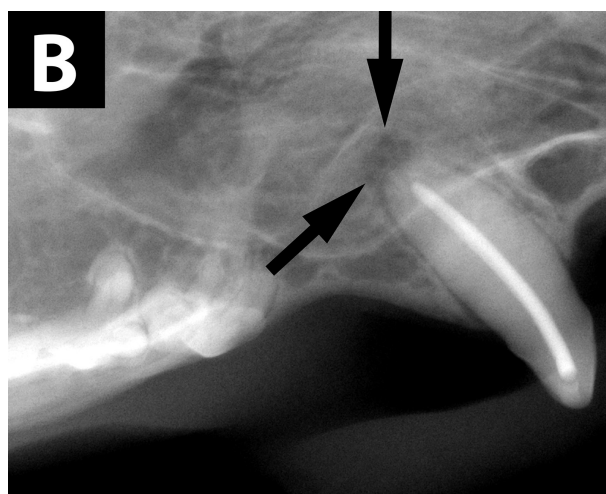
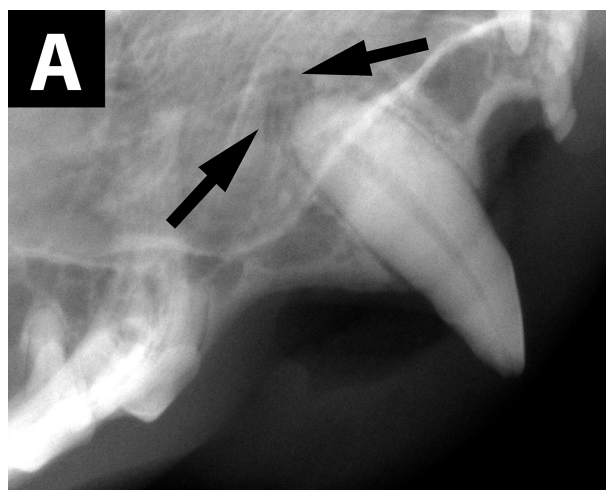


Figure 3—Intraoral lateral radiographic images of the right maxillary canine tooth of a 4-year-old castrated male domestic shorthair cat with a complicated crown fracture and PL (arrows) before (A), immediately after (B), and at the last follow-up examination 27 months after (C) RCT, which was classified as having failed because the PL appeared to increase in size following the procedure. **See Figure 1** for remainder of key.

RCT outcome was not significantly associated with the time to follow-up examination (**Figure 4**). Fifteen teeth had preexisting PL prior to RCT, of which RCT was classified successful for 5, NEF for 6, and failure for 4. Of the 6 teeth with preexisting PL and an NEF outcome, the PL was considered static for 2 and had decreased in size but not completely resolved for the remaining 4 at the time of the final follow-up examination (the time since RCT at the last follow-up examination was 6, 11, 11, and 18 months for those 4 teeth). Prior to RCT, 7 of the 37 (19%) teeth had evidence of EIRR associated with preoperative pulpal necrosis, and the treatment outcome was classified as successful, NEF, or failure for 1, 3, and 3 of those teeth, respectively. Five of those 7 teeth were vital at the time of the RCT; the status of the pulp was not recorded for the remaining 2 teeth. For each of 2 cats (2 teeth), the RCT was performed in 2 stages owing to uncontrolled intracanal hemorrhage; treatment outcome was classified as successful for both of those teeth. In 2 other cats (2 teeth), the treated tooth refractured, but the fracture did not require extraction of the affected tooth, and the RCT outcome was classified as NEF for both teeth.

The RCT was performed with single access to the pulp cavity for all but 1 tooth, which required both occlusal and mesial supragingival access sites to the pulp cavity. The obturation methods used included single-cone thermoplastic gutta-percha ($n = 4$), vertical compaction with thermoplastic gutta-percha (7), single-cone gutta-percha with flowable gutta-percha

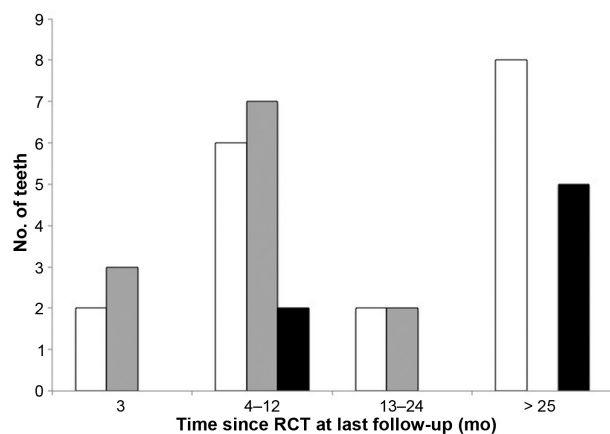


Figure 4—Number of canine teeth that had a successful outcome (white bars), NEF (gray bars), and a failed outcome (black bars) following RCT as determined by evaluation of dental radiographs obtained during the last follow-up examination. The study population consisted of 37 canine teeth from 32 cats. The time since RCT at the last follow-up examination was categorized into 4 categories (< 3, 4 to 12, 13 to 24, and > 25 months). Root canal treatment was considered successful if the PDL space was within reference limits and EIRR, if present prior to the procedure, had stabilized. Treatment was considered to have NEF if preoperative EIRR had stabilized and preexisting PL was stable or decreased in size but had not resolved. Treatment was considered to have failed if PL or EIRR developed subsequent to RCT or preexisting PL increased in size or preoperative EIRR progressed following RCT.

(21), and single-cone gutta-percha with a root canal sealer (5). Overfill was observed for 10 of the 37 teeth and occurred nearly twice as frequently when obturation was performed with vertical compaction with thermoplastic gutta-percha (3/7), compared with all other techniques (7/30). Overfill was not significantly ($P = 0.25$) associated with an increased rate of RCT failure (IRR, 2.59; 95% CI, 0.52 to 12.9).

Obturation voids were identified in the pulp cavity for 20 of the 37 treated teeth. Four teeth had both large and small voids, 7 teeth had a small void in 2 portions of the pulp cavity, and 1 tooth had a large void in 2 portions of the pulp cavity. The voids were observed in the apical third of the pulp cavity in 13 teeth (9 with small voids and 4 with large voids), middle third of the pulp cavity in 11 teeth (8 with small voids and 3 with large voids), and the coronal third of the pulp cavity in 8 teeth (5 with small voids and 3 with large voids). Obturation voids in the apical third of the pulp cavity were associated with a 5-fold increase (IRR, 5.01; 95% CI, 0.88 to 28.42) in the rate of RCT failure; however, that relative rate was not significant ($P = 0.069$).

Teeth with evidence of periapical EIRR prior to RCT had a 10-fold increase (IRR, 10.5; 95% CI, 1.66 to 66.29; $P = 0.012$) in the rate of additional postoperative periapical EIRR and therefore treatment failure (**Figure 5**). Age was also significantly ($P = 0.029$) associated with an increased rate of continued EIRR (IRR, 1.26; 95% CI, 1.02 to 1.55). Evidence of postoperative EIRR was identified in 6 cats, and the age of those cats was 5 ($n = 2$ cats), 10 (1), and 12 (1) years (the age was not reported for the remaining 2 cats). Sex was not significantly ($P = 0.41$) associated with rate of RCT failure (IRR, 1.95; 95% CI, 0.4 to 9.63).

Thirty teeth were lost to follow-up over a period of 72 months after RCT, and the treatment success rate steadily decreased beyond 2 years after the pro-

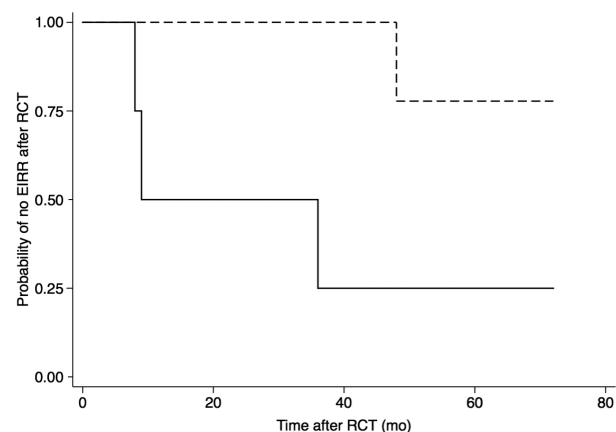


Figure 5—Kaplan-Meier product limit estimator plot for 37 canine teeth from 32 cats that did (solid line; $n = 7$) or did not (dashed line; 30) have EIRR present before RCT and did not develop EIRR after the procedure. Notice that teeth with EIRR prior to RCT were more likely to develop EIRR after the procedure than were teeth without EIRR prior to RCT.

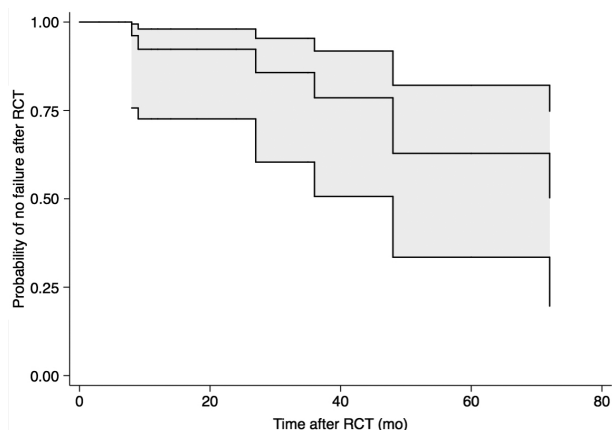


Figure 6—Kaplan-Meier product limit estimator plot for 37 canine teeth from 32 cats with complicated crown fractures that were successfully treated with RCT. The predicted probability of RCT success over time (center line) and associated 95% CI (shaded area) are presented.

cedure (**Figure 6**) as a result of continued root resorption ($n = 3$) and failure of apical periodontitis to resolve (2).

Discussion

In the present study, the medical records, radiographic images, treatment outcome, and factors associated with outcome were reviewed for 37 canine teeth of 32 cats that underwent RCT subsequent to a complicated crown fracture. Root canal treatment was successful ($n = 18$) or considered to have NEF (12) for the majority (30/37 [81%]) of teeth. Preexisting EIRR and age were associated with a significant increase in the rate of postoperative EIRR and RCT failure. Failure to properly clean or obturate the canal resulting in an obturation void in the apical third of the pulp cavity was also associated with an increase in the rate of RCT failure, although that association was not significant. Overfill was more frequently observed in teeth that were obturated with vertical compaction with thermoplastic gutta-percha, compared with all other obturation techniques, but neither obturation method nor overfill was associated with an increase in the rate of RCT failure. The RCT success rate steadily decreased beyond 2 years after the procedure owing primarily to continued root resorption ($n = 3$) and failure of apical periodontitis to resolve (2). Overall, results of the present study indicated that RCT is a suitable treatment for endodontically compromised canine teeth in cats.

In dogs and humans, the success and prognosis of RCT are dependent on several variables such as obturation method used, bacterial infiltrates associated with faulty coronal restoration,¹⁸ extrusion of the filling material,^{19–25} presence of preexisting apical periodontitis,^{19,26,27} presence of microorganisms in the pulp at the time of obturation,²⁸ and improper obturation of the pulp cavity.^{29,30} Similar to results of

studies involving dogs¹² and humans,²⁷ results of the present study indicated that preexisting EIRR was associated with a 10-fold increase in the rate of RCT failure for canine teeth of cats. However, unlike in dogs¹² and humans,¹⁹ preexisting apical periodontitis and extrusion of filling material were not associated with RCT outcome for the cats of the present study. Differences among species in regard to factors associated with RCT outcome are likely the result of the exactitude of the radiographic assessment or the technical accuracy or quality of the radiographic images. The small sample size of the present study also likely contributed to the differences observed.

The success rate of RCT ranges from 69% to 95% in dogs^{12,31} and humans.^{19,22,23,26,27,29,30,32–41} In a study³¹ involving dogs, RCT resulted in a favorable outcome (ie, lesions absent or reduced) for 57 of 72 (79%) teeth when it was determined by evaluation of periapical radiographic images, which was similar to the results for the cats of the present study (ie, RCT outcome was classified as successful or having NEF in 30 of 37 [81%] teeth). However, when RCT outcome for the dogs of that study³¹ was determined on the basis of evaluation of cone-beam CT images, the success rate dropped to 35% (25/72). Although further research is necessary, CT may be a valuable diagnostic imaging modality to assess endodontic disease in cats.

For the cats evaluated in the present study, age at the time of RCT was significantly associated with an increase in the rate of treatment failure. Age is not significantly associated with RCT outcome in dogs¹² but is associated with RCT outcome in humans.^{18,27,30,42} Although the sample size of the present study was too small to identify a specific age cutoff above which the rate of RCT failure increased, it is interesting to note that all 5 cats with RCT failure for which age was reported were ≥ 5 years old. The reason for the apparent negative association between age and RCT success in cats is unclear. Fractured teeth are often ignored in cats; therefore, the older cats of the present study may have had inflammation for a longer duration prior to RCT than younger cats, which led to chronic tissue changes and increased rate of EIRR. In human patients, the physiologic effects of aging slow and impair the effectiveness of the healing process,⁴³ and the same phenomenon may occur in cats. Moreover, tooth trauma in humans can lead to the deposition of calcified hard tissue within the pulp cavity and obliterate the pulp canal.⁴⁴ A similar effect is observed in cats with EIRR, which also practically obliterates the pulp canal. This may pose a challenge for optimal root canal preparation and have a negative effect on healing outcome.⁴⁴ The estimated duration between the crown fracture and RCT was unknown for most of the cats of the present study, so we cannot draw any definitive conclusions as to the effect of fracture chronicity on RCT success.

In the present study, obturation voids in the apical third of the pulp cavity were associated with a 5-fold increase in the rate of RCT failure; however,

that association was not significant, which we believe was a result of low power owing to the small sample size. Filling defects or an incomplete apical seal relative to the radiographic apical delta may represent poor instrumentation, incomplete debridement, or insufficient obturation. In a study⁴⁵ involving human patients, poor obturation and instrumentation were significantly associated with RCT failure.

Although multiple studies⁴⁶⁻⁴⁸ involving human subjects have compared various sealers and the sealing ability of various obturation methods, a consensus has yet to be reached on which material or method is superior. Similarly, results of the present study failed to identify a superior obturation method or sealer. The fact that overfill was observed in a greater proportion of teeth that underwent the vertical compaction with thermoplastic gutta-percha technique, compared with all other techniques combined, may have been caused by the small sample size and operator error or might be related to the technique itself, which requires that pressure be placed on the obturation material to compact it toward the apex of the canal.

The overall success rate (30/37 [81%], which included teeth classified as successful and NEF) of RCT for the cats of the present study was comparable to that reported in studies involving dogs¹² and humans.⁴⁵ Other studies^{32,33,49} involving humans had higher RCT success rates, but treatment success was fairly loosely defined in those studies, and comparisons with and among those studies is difficult. A stringent definition similar to that described in a study¹² of RCT in dogs was used to determine RCT success in the present study, which may have contributed to the lower success rate for this study, compared with that reported in those other studies.^{32,33,49} Had the monitoring period been longer for the teeth evaluated in the present study, the true RCT success rate might have been higher because 9 of the 12 teeth that were considered to have NEF had either no evidence of or diminished PL at the last follow-up examination.

Long-term radiographic follow-up after RCT is essential to evaluate the underlying disease process, and RCT outcome can only be determined on the basis of results of radiographic and clinical examination.¹³ Clinical and radiographic follow-up at regular intervals for a minimum observation period of 1 year, and possibly for as long as 4 years, are recommended before RCT can be judged a success,¹³ because the healing process is not always rapid and radiographic evidence of disease resolution is not always present at initial follow-up examinations. In the present study, the probability of RCT success dropped steadily for teeth evaluated > 2 years after treatment. The 21 teeth that were lost to follow-up during the 2 years after RCT were considered a key reason for that steady decrease in RCT success rate, as evidenced by the marked increase in the width of the 95% CI for RCT success 2 years after the procedure, but it also indicated the importance of long-term follow-up in cats.

Two of the 37 teeth evaluated in the present study were refractured following RCT, but neither tooth had evidence of RCT failure at the last follow-up examination. Unlike dogs, in which chewing behavior contributes to dental fractures, canine tooth fractures in cats are commonly associated with trauma⁵⁰ related to animal interaction and aggression or secondary to an accident or impact during landing after jumping from a height.⁵¹

Limitations of the present study were primarily associated with the use of dental radiographs to determine treatment success because they provide only a 2-D image of the 3-D structures of the jaw. Moreover, although 56 cats underwent RCT of a canine tooth at the 5 referral hospitals during the study period, only 32 cats (37 treated teeth) returned for a follow-up examination, which highlights an inherent limitation for any retrospective cohort study. A high loss-to-follow-up rate jeopardizes the precision of survival probability estimates⁵² and was presumably the reason that the factors associated with RCT success for the cats of the present study differed from those reported for the dogs and humans of other studies.¹⁸⁻³⁰ Also, the available information for the treated teeth of this study was insufficient to evaluate the effect that the duration between tooth fracture and RCT had on treatment outcome, and this effect requires further investigation.

Results of the present study were comparable to findings of similar studies involving dogs¹² and humans⁴⁵ and indicated that RCT is a viable option for salvaging endodontically diseased canine teeth in cats. The presence of EIRR and patient age ≥ 5 years old at the time of RCT were negative prognostic indicators for treatment outcome. Long-term (> 2 years) radiographic follow-up is important for cats following RCT because treatment failure > 2 years after the procedure was observed with some frequency for the teeth evaluated in this study.

Acknowledgments

The authors declare that there were no conflicts of interest. No extra-institutional funding was received.

The authors thank Dr. Nadine Fiani from the Department of Clinical Sciences, College of Veterinary Medicine, Cornell University, and Dr. Steven E. Holmstrom from the Animal Dental Clinic in San Carlos, Calif, for case material and John Doval from the William R. Pritchard Veterinary Medical Teaching Hospital, Department of Surgical and Radiological Sciences, School of Veterinary Medicine, University of California-Davis, for technical assistance.

Footnotes

- a. Gutta Percha, Dentsply Tulsa Dental Specialties, Tulsa, Okla.
- b. AH26, Dentsply Tulsa Dental Specialties, Tulsa, Okla.
- c. Thermafil, Dentsply Tulsa Dental Specialties, Tulsa, Okla.
- d. Successfil, Coltène/Whaledent, Mahwah, NJ.
- e. SimpliFill, LightSpeed Technology, San Antonio, Tex.
- f. Ultrafil, Coltène/Whaledent, Mahwah, NJ.
- g. GuttaFlow, Coltène/Whaledent, Mahwah, NJ.
- h. GuttaFlow 2, Coltène/Whaledent, Mahwah, NJ.

- i. AH26, Dentsply Tulsa Dental Specialties, Tulsa, Okla.
- j. Filtek Supreme Plus, 3M ESPE, Saint Paul, Minn.
- k. Asus PB278Q, AsusTeK Computer Inc, Fremont, Calif.
- l. Peak Scale Loupe 7x, Peak Optics, GWJ Co, Hacienda Heights, Calif.
- m. Stata/IC, version 13.1, Stata Corp LP, College Station, Tex.

References

1. Clarke DE. Endodontics of dogs and cats: an alternative to extraction. *Aust Vet J* 1995;72:383-389.
2. Friedman S, Abitbol S, Lawrence HP. Treatment outcome in endodontics: the Toronto study. Phase 1: initial treatment. *J Endod* 2003;29:787-793.
3. Jensen JR. *Fundamentals of clinical endodontics*. 8th ed. Dubuque, Iowa: Kendall Hunt Publishing, 1984;1.
4. Berman L, Hartwell GR. Diagnosis. In: Hargreaves KM, Cohen S, eds. *Cohen's pathway of the pulp*. 10th ed. St Louis: Mosby, 2011;36.
5. Holmstrom SE. Feline endodontics. *Vet Clin North Am Small Anim Pract* 1992;22:1433-1451.
6. Holmstrom SE, Frost P, Gammon RL. Endodontics. In: *Veterinary dental techniques for the small animal practitioner*. Philadelphia: WB Saunders, 1992;207-266.
7. Niemiec BA. Fundamentals of endodontics. *Vet Clin North Am Small Anim Pract* 2005;35:837-868.
8. Torabinejad M, Shabahang S. Pulp and periapical pathosis. In: Torabinejad M, Walton RE, eds. *Endodontics: principles and practice*. 4th ed. St Louis: Saunders Elsevier, 2009;49-66.
9. Gorrel C, Robinson J. Endodontics in small carnivores. In: Crossley DA, Penman S, eds. *Manual of small animal dentistry*. 2nd ed. Gloucestershire, England: British Small Animal Veterinary Association, 1995;168-181.
10. Gutmann JL, Witherspoon DE. Obturation of the cleaned and shaped root canal system. In: Burns RC, Cohen S, eds. *Cohen's pathways of the pulp*. 7th ed. St Louis: Mosby, 1998;258-361.
11. Peters OA, Peters CI. Cleaning and shaping of the root canal system. In: Hargreaves KM, Cohen S, eds. *Cohen's pathway of the pulp*. 10th ed. St Louis: Mosby, 2011;283-348.
12. Kuntisi-Vaattovaara H, Verstraete FJM, Kass PH. Results of root canal treatment in dogs: 127 cases (1995-2000). *J Am Vet Med Assoc* 2002;220:775-780.
13. European Society of Endodontology. Quality guidelines for endodontic treatment: consensus report of the European Society of Endodontology. *Int Endod J* 2006;39:921-930.
14. Consensus report of the European Society of Endodontology on quality guidelines for endodontic treatment. *Int Endod J* 1994;27:115-124.
15. Visser CJ. Coronal access of the canine dentition. *J Vet Dent* 1991;8:12-15.
16. Goaz PW, White SC. Infection and inflammation of the jaws and facial bones In: *Oral radiology: principles and interpretation*. St Louis: Mosby Elsevier, 1994;382-383.
17. Thé SD, Maltha JC, Plasschaert AJ. Reactions of guinea pig subcutaneous connective tissue following exposure to sodium hypochlorite. *Oral Surg Oral Med Oral Pathol* 1980;49:460-466.
18. Ray HA, Trope M. Periapical status of endodontically treated teeth in relation to the technical quality of the root filling and the coronal restoration. *Int Endod J* 1995;28:12-18.
19. Kerekes K, Tronstad L. Long-term results of endodontic treatment performed with a standardized technique. *J Endod* 1979;5:83-90.
20. Lazarski MP, Walker WA III, Flores CM, et al. Epidemiological evaluation of the outcomes of nonsurgical root canal treatment in a large cohort of insured dental patients. *J Endod* 2001;27:791-796.
21. Buckley M, Spangberg LS. The prevalence and technical quality of endodontic treatment in an American subpopulation. *Oral Surg Oral Med Oral Pathol Oral Radiol Endod* 1995;79:92-100.
22. Swartz DB, Skidmore AE, Griffin JA Jr. Twenty years of endodontic success and failure. *J Endod* 1983;9:198-202.
23. Pirani C, Chersoni S, Montebugnoli L, et al. Long-term outcome of non-surgical root canal treatment: a retrospective analysis. *Odontology* 2015;103:185-193.
24. Shipper G, Troppe M. In vitro microbial leakage of endodontically treated teeth using new and standard obturation techniques. *J Endod* 2004;30:154-162.
25. Sritharan A. Discuss that the coronal seal is more important than the apical seal for endodontic success. *Aust Endod J* 2002;28:112-115.
26. Jokinen MA, Kotilainen R, Poikkeus P, et al. Clinical and radiographic study of pulpectomy and root canal therapy. *Scand J Dent Res* 1978;86:366-373.
27. Sjogren U, Hagglund B, Sundqvist G, et al. Factors affecting the long-term results of endodontic treatment. *J Endod* 1990;16:498-504.
28. Fabricius L, Dahlén G, Sundqvist G, et al. Influence of residual bacteria on periapical tissue healing after chemomechanical treatment and root filling of experimentally infected monkey teeth. *Eur J Oral Sci* 2006;114:278-285.
29. Smith CS, Setchell DJ, Harty FJ. Factors influencing the success of conventional root canal therapy—a five-year retrospective study. *Int Endod J* 1993;26:321-333.
30. Lee AH, Cheung GS, Wong MC. Long-term outcome of primary non-surgical root canal treatment. *Clin Oral Investig* 2012;16:1607-1617.
31. Garcia de Paula-Silva FW, Hassan B, Bezerra da Silva LA, et al. Outcome of root canal treatment in dogs determined by periapical radiography and cone-beam computed tomography scans. *J Endod* 2009;35:723-726.
32. Barbakow FH, Cleaton-Jones PE, Friedman D. Endodontic treatment of teeth with periapical radiolucent areas in a general dental practice. *Oral Surg Oral Med Oral Pathol* 1981;51:552-559.
33. Barbakow FH, Cleaton-Jones P, Friedman D. An evaluation of 566 cases of root canal therapy in general dental practice. 2. Postoperative observations. *J Endod* 1980;6:485-489.
34. Heling B, Tamshe A. Evaluation of the success of endodontically treated teeth. *Oral Surg Oral Med Oral Pathol* 1970;30:533-536.
35. Ashkenaz PJ. One-visit endodontics. *Dent Clin North Am* 1984;28:853-863.
36. Kerekes K. Radiographic assessment of an endodontic treatment method. *J Endod* 1978;4:210-213.
37. Heling B. Statistical evaluation of the success of endodontically treated teeth. *N Y J Dent* 1971;41:69.
38. Peak JD. The success of endodontic treatment in general dental practice: a retrospective clinical and radiographic study. *Prim Dent Care* 1994;1:9-13.
39. Adenubi JO, Rule DC. Success rate for root fillings in young patients. A retrospective analysis of treated cases. *Br Dent J* 1976;141:237-241.
40. Raedel M, Hartmann A, Bohm S, et al. Three-year outcomes of root canal treatment: mining an insurance database. *J Dent* 2015;43:412-417.
41. Paredes-Vieyra J, Enriquez FJ. Success rate of single- versus two-visit root canal treatment of teeth with apical periodontitis: a randomized controlled trial. *J Endod* 2012;38:1164-1169.
42. Fransson H, Dawson VS, Frisk F, et al. Survival of root-filled teeth in the Swedish adult population. *J Endod* 2016;42:216-220.
43. Ørstavik D, Qvist V, Stoltze K. A multivariate analysis of the outcome of endodontic treatment. *Eur J Oral Sci* 2004;112:224-230.
44. McCabe PS, Dummer PM. Pulp canal obliteration: an endodontic diagnosis and treatment challenge. *Int Endod J* 2012;45:177-197.
45. Ng YL, Mann V, Rahbaran S, et al. Outcome of primary root canal treatment: systematic review of the literature—part 2. Influence of clinical factors. *Int Endod J* 2008;41:6-31.
46. Schäfer E, Olthoff G. Effect of three different sealers on the sealing ability of both thermafil obturators and cold laterally compacted gutta-percha. *J Endod* 2002;28:638-642.
47. Nagas E, Altundasar E, Serper A. The effect of master point taper on bond strength and apical sealing ability of different root canal sealers. *Oral Surg Oral Med Oral Pathol Oral Radiol Endod* 2009;107:e61-e64.

48. Chen G, Chang YC. Effect of immediate and delayed post space preparation on apical leakage using three root canal obturation techniques after rotary instrumentation. *J Formos Med Assoc* 2011;110:454–459.
49. Morse DR, Esposito JV, Pike C, et al. A radiographic evaluation of the periapical status of teeth treated by the gutta-percha-eucapercha endodontic method: a one-year follow-up study of 458 root canals. Part III. *Oral Surg Oral Med Oral Pathol* 1983;56:190–197.
50. Verstraete FJM, van Aarde RJ, Nieuwoudt BA, et al. The dental pathology of feral cats on Marion Island, part I: congenital, developmental and traumatic abnormalities. *J Comp Pathol* 1996;115:265–282.
51. Bonner SE, Reiter AM, Lewis JR. Orofacial manifestations of high-rise syndrome in cats: a retrospective study of 84 cases. *J Vet Dent* 2012;29:10–18.
52. Daya S. Life table (survival) analysis to generate cumulative pregnancy rates in assisted reproduction: are we overestimating our success rates? *Hum Reprod* 2005;20:1135–1143.



From this month's AJVR

Effects of dexmedetomidine combined with commonly administered opioids on clinical variables in dogs

Lilian T. Nishimura et al

OBJECTIVE

To evaluate cardiopulmonary, sedative, and antinociceptive effects of dexmedetomidine combined with commonly administered opioids in dogs.

ANIMALS

8 healthy Beagles.

PROCEDURES

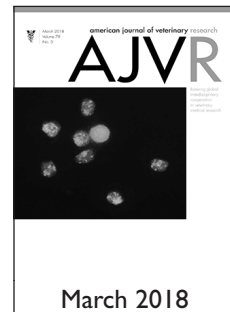Dogs were sedated by IM administration of each of 7 treatments. Treatments comprised dexmedetomidine (0.01 mg/kg; Dex) and that dose of dexmedetomidine plus butorphanol (0.15 mg/kg; Dex-But), meperidine (5 mg/kg; Dex-Mep), methadone (0.5 mg/kg; Dex-Meth), morphine (0.5 mg/kg; Dex-Mor), nalbuphine (0.5 mg/kg; Dex-Nal), or tramadol (5 mg/kg; Dex-Tram). Cardiorespiratory and arterial blood gas variables and sedative and antinociceptive scores were measured before drug injection (time 0; baseline) and at 15-minute intervals for 120 minutes.

RESULTS

Heart rate was reduced at all time points after injection of Dex-But, Dex-Mep, Dex-Meth, and Dex-Mor treatments. There was a significant reduction of mean arterial blood pressure for Dex-But, Dex-Mep, and Dex-Mor treatments at all time points, compared with baseline. There was a significant decrease in respiratory rate, compared with the baseline value, for Dex, Dex-But, Dex-Meth, and Dex-Tram treatments from 15 to 120 minutes. A significant decrease in arterial blood pH was detected from baseline to 120 minutes for all treatments, with differences among Dex, Dex-Mep, and Dex-Mor. Reduction in P_{aO_2} was greater for the Dex-Mep treatment than for the other treatments. The highest sedation scores were detected for Dex-Mep and Dex-Meth treatments. Antinociceptive effects were superior for Dex-But, Dex-Meth, Dex-Mor, and Dex-Nal treatments.

CONCLUSIONS AND CLINICAL RELEVANCE

Drug combinations caused similar cardiorespiratory changes, with greater sedative effects for Dex-Mep and Dex-Meth and superior antinociceptive effects for Dex-But, Dex-Meth, Dex-Mor, and Dex-Nal. (*Am J Vet Res* 2018;79:266–274)



March 2018

See the midmonth issues of JAVMA for the expanded table of contents for the AJVR or log on to avmajournals.avma.org for access to all the abstracts.