

**UC Davis**

**UC Davis Previously Published Works**

**Title**

Orbital meningioma with intraocular invasion in a dog: Histology and ultrastructure

**Permalink**

<https://escholarship.org/uc/item/91d234pz>

**Journal**

Veterinary Pathology, 14(5)

**ISSN**

1544-2217

**Author**

Buyukmihci, N

**Publication Date**

1977-09-01

Peer reviewed

## **Orbital Meningioma with Intraocular Invasion in a Dog**

### **Histology and Ultrastructure**

N. BUYUKMIHCI

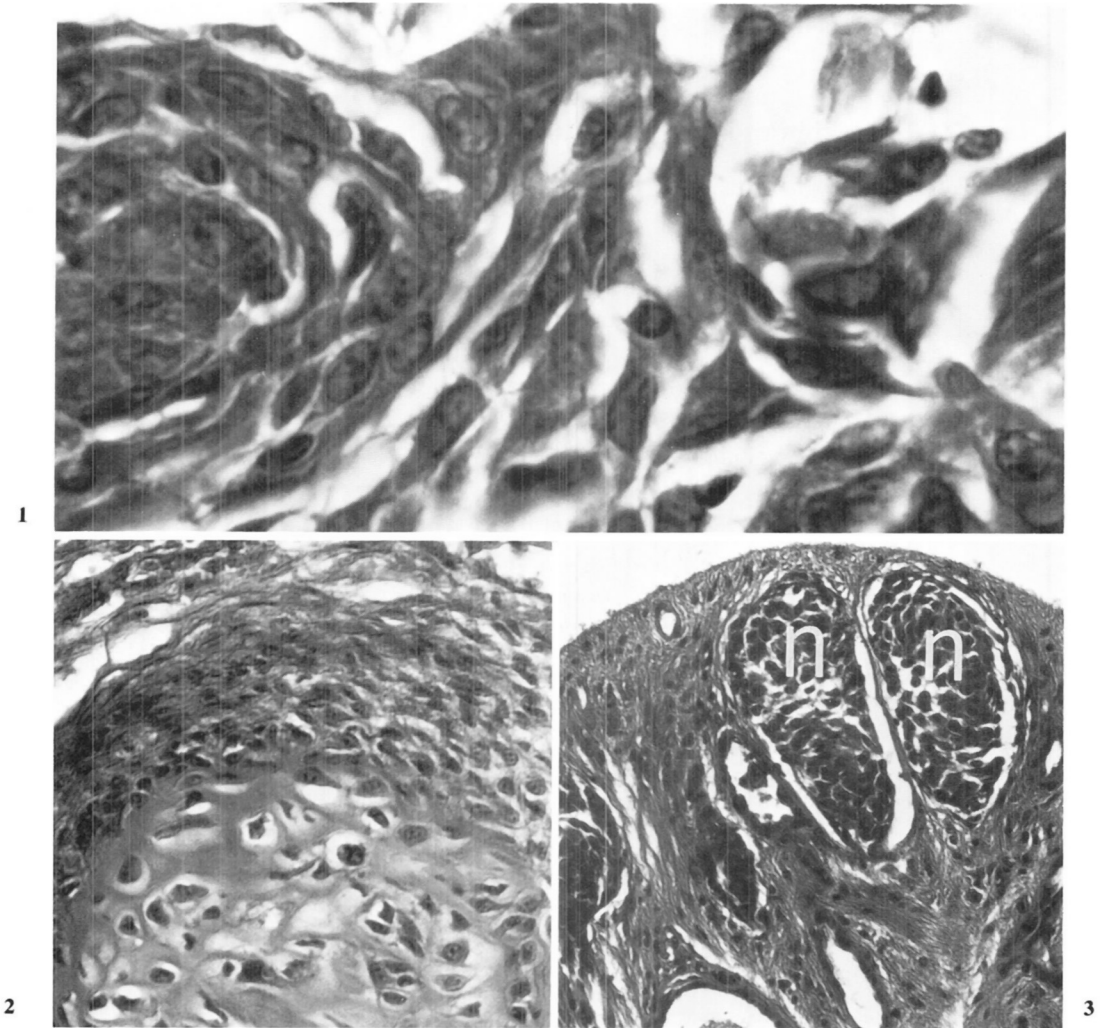
Meningiomas have been reported in a variety of domestic animals [9]. Although most meningiomas have been intracranial, there are several reports of meningiomas with orbital or ocular involvement or both [1-3, 5-8, 10].

A 7-year-old, ovariohysterectomized Scottish Terrier dog had had a "film" over the right eye with gradual increase in prominence of the globe and loss of a menace response for 2 weeks. The dog had had a nonresponsive conjunctivitis of the right eye for 2 months before the "film" developed.

The right eye was blind with no direct or consensual pupillary response. The globe was deviated laterally, exophthalmic and fixed in position. The nictitans protruded from the medial canthus. The retina was displaced anteriorly so that parts were in contact with the back of the lens. It could not be determined if the neuroretina was separated from its pigment epithelium or if an intraocular or extraocular mass was causing the anterior displacement. The optic disk was not visible. The diagnosis was a space-occupying lesion in the orbit. After thoracic radiographs showed no evidence of lung disease the right orbit was exenterated. The globe was compressed by firm, moderately vascular tissue that filled the orbit and extended posteriorly to the orbital fissure and optic foramen. The eye with firmly adherent orbital tissue was placed in Zenker's solution with acetic acid and processed for routine light microscopy. Pieces of the attached mass also were fixed in 10 percent neutral buffered formalin. Formalin-fixed neoplastic tissue was processed for electron microscopy by a rapid method [11]. Ultrathin sections were stained with uranyl acetate and lead citrate.

The dog was re-examined 73 days after surgery. During these 73 days the dog had seemed normal. The exenterated orbit was unremarkable and the left eye normal. Two months later the dog was killed because there was extensive regrowth of the neoplasm. There was destruction of orbital bone (especially zygomatic arch) and invasion of the roof of the pharynx. No invasion of the brain was seen grossly. The lungs contained miliary white nodules.

The tissue surrounding the globe looked neoplastic and in some areas had many islands of polygonal cells arranged in swirls; these islands ranged in size from four cells to more than 100 (fig. 1). In other areas, the cells were close together in an indiscriminate manner. The nuclei were generally large and pleomorphic and many contained linear basophilic densities. The abnormal cells gave rise to cartilage,



**Fig. 1:** Section through meningioma. Islands of neoplastic meningothelial cells. HE.

**Fig. 2:** Section through meningioma. Probable precartilagenous metaplasia of neoplastic cells. HE.

**Fig. 3:** Section through optic disk. Invasion by neoplastic cells (n). HE.

osteoid and bone (fig. 2); the cartilage especially was a prominent feature of the abnormal tissue. Some of the cells had undergone fibrous metaplasia. Mitotic figures were not conspicuous. Abundant adipose tissue and areas of hemorrhage were between areas of neoplastic tissue. The tumor had destroyed much extraocular tissue and invaded the sclera and choroid in several places. Near the optic nerve, the tumor seemingly arose from tissue indistinguishable from optic nerve meninges although normal nerve tissue was not seen. From this area, the neoplasm extended into the optic disk and peripapillary retina (fig. 3). Neoplastic cells were also between the peripapillary neuroretina and pigment epithelium.

The lung tissue contained several areas of neoplastic growth. The abnormal cells

looked similar to those in the orbital tumor in that they were arranged in whorls and appeared meningotheial.

The primary diagnosis was transitional meningioma with chondrification and ossification.

Ultrastructurally, cell preservation was not good and intracellular organelles were not recognizable except for dilated rough endoplasmic reticulum and swollen mitochondria. Cell borders and junctions were not distinct. Many of the cells were embedded in a matrix of both fibrillar and dense areas. The fibrils had dimensions similar to those of collagen. There was marginization of nuclear chromatin and several nuclei had deeply folded membranes, which accounted for the linear densities seen histologically.

The number of reported cases of meningioma in which ossification and chondrification have occurred is low in domestic animals [2, 3, 4, 6]. In human meningiomas cartilage is considered extremely rare [12]. The dog in this report had an unusual amount of cartilage. The cartilage, osteoid and bone are presumed to have been derived from the neoplastic meningotheial cells since there were many areas of smooth transition. As in another case [6], evidence of metastasis was not evident until sometime after surgery.

### References

- 1 Andrews, E.J.: **Clinicopathologic characteristics of meningiomas in dogs.** *J Am Vet Med Assoc* **163**:151-157, 1973
- 2 Barnett, K.C.; Kelly, D.F.; Singleton, W.B.: **Retrolbulbar and chiasmal meningioma in a dog.** *J Small Anim Pract* **8**:391-394, 1967
- 3 Barron, C.N.; Saunders, L.Z.; Jubb, K.V.: **Intraocular tumors in animals. III. Secondary intraocular tumors.** *Am J Vet Res* **24**:835-853, 1963
- 4 Davis, C.L.; Phillips, L.R.; Neuburger, K.T.: **Malignant meningioma in a dog.** *J Am Vet Med Assoc* **112**:367-370, 1948
- 5 Frith, C.H.: **Meningioma in a young dog resulting in blindness and retinal degeneration.** *Vet Med Small Anim Clin* **70**:307-312, 1975
- 6 Geib, L.W.: **Ossifying meningioma with extracranial metastasis in a dog.** *Pathol Vet* **3**:247-254, 1966
- 7 Hayes, K.C.; Schiefer, B.: **Primary tumors in the CNS of carnivores.** *Pathol Vet* **6**:94-116, 1969
- 8 Langham, R.F.; Bennett, R.R.; Zydeck, F.A.: **Primary retrolbulbar meningioma of the optic nerve of a dog.** *J Am Vet Med Assoc* **159**:175-176, 1971
- 9 Luginbühl, H.: **Comparative aspects of tumors of the nervous system.** *Ann NY Acad Sci* **108**:702-721, 1963
- 10 Magrane, W. G.: **Canine ophthalmology**, 2nd ed., p. 255; Lea and Febiger, Philadelphia, 1974
- 11 Ockleford, C. D.: **Redundancy of washing in the preparation of biological specimens for transmission electron microscopy.** *J Microsc (Oxf)* **105**:193-203, 1975
- 12 Russell, D.S.; Rubinstein, L.J.: **Pathology of tumours of the nervous system**, 3rd ed., pp. 48-73; Williams and Wilkins, Baltimore, 1971

Request reprints from Ned Buyukmihci, College of Veterinary Medicine, University of Tennessee, Knoxville, TN 37901 (USA).