

# UC Davis

## Dermatology Online Journal

### Title

Unilateral hyperhidrosis secondary to brainstem meningioma producing mass effect

### Permalink

<https://escholarship.org/uc/item/905497s9>

### Journal

Dermatology Online Journal, 25(11)

### Authors

Margheim, Ashlee  
Schadt, Courtney R

### Publication Date

2019

### DOI

10.5070/D32511046144

### Copyright Information

Copyright 2019 by the author(s). This work is made available under the terms of a Creative Commons Attribution-NonCommercial-NoDerivatives License, available at <https://creativecommons.org/licenses/by-nc-nd/4.0/>

Peer reviewed

# Unilateral hyperhidrosis secondary to brainstem meningioma producing mass effect

Ashlee Margheim<sup>1</sup> BSN, Courtney R Schadt<sup>2</sup> MD

Affiliations: <sup>1</sup>University of Louisville School of Medicine, Louisville, Kentucky, USA, <sup>2</sup>Division of Dermatology, University of Louisville, Louisville, Kentucky, USA

Corresponding Author: Ashlee Margheim, BSN, 3810 Springhurst Boulevard, Louisville, KY 40241, Tel: 502-572-4739, Email: [amargheim01@gmail.com](mailto:amargheim01@gmail.com)

## Abstract

Unilateral hyperhidrosis of neurological origin has been associated with head trauma, cerebral palsy, spinal cord injury, peripheral neuropathy, lesions of the hypothalamus, and cerebral or brainstem strokes. In this report, we describe a 61-year-old man with isolated sweating on the left side of his entire body. A right-sided brainstem meningioma producing mass effect is suspected as the underlying etiology.

*Keywords: unilateral hyperhidrosis, meningioma*

## Introduction

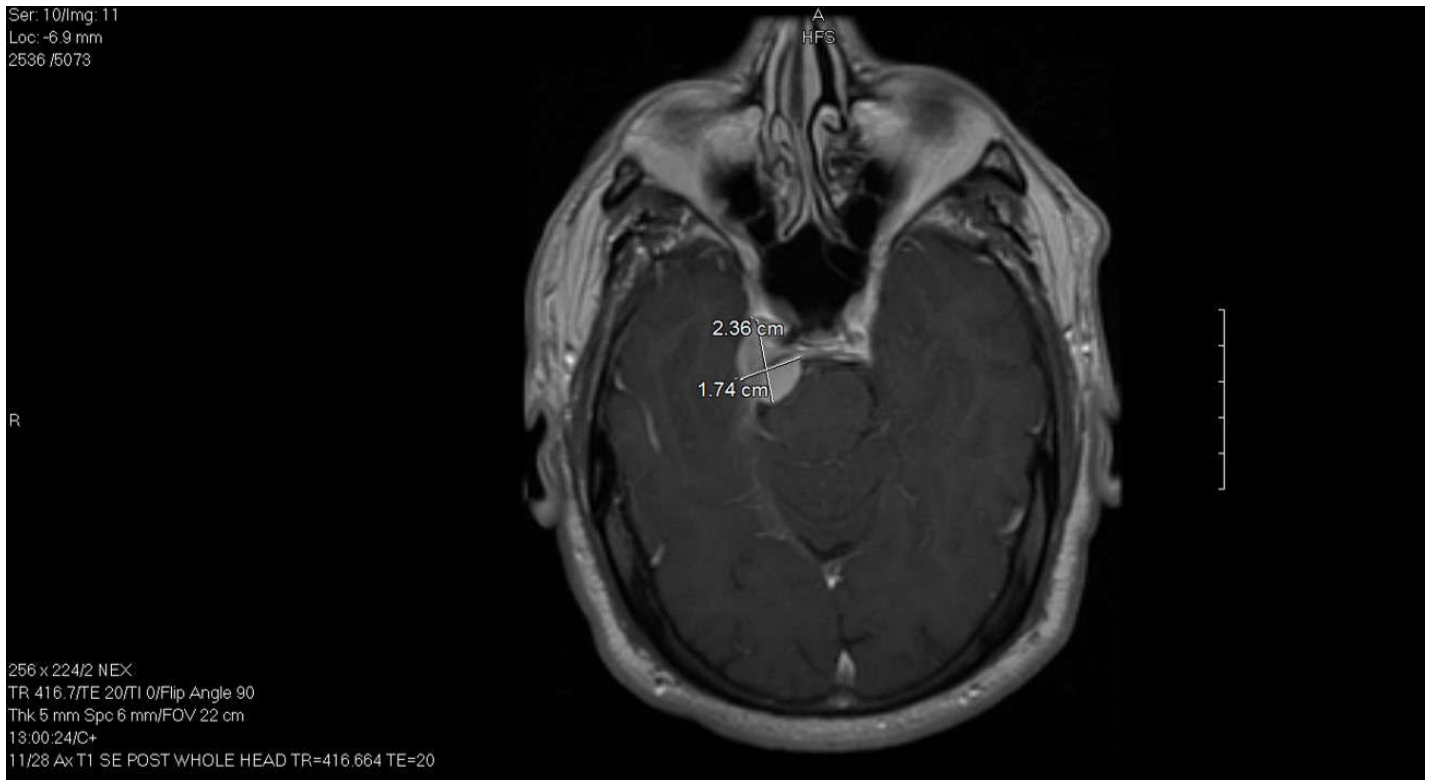
Hyperhidrosis is defined as a condition of excessive sweating that exceeds thermoregulatory requirements. Recent onset suggests that the etiology should be further investigated. Primary hyperhidrosis is a common condition which produces symmetric and localized sweating of the palms, soles, axilla, face, or scalp and is not associated with an underlying medical condition [1]. Excessive sweating localized to one side of the body is rare and more suggestive of a neurologic or intrathoracic lesion [2]. Unilateral hyperhidrosis of neurological origin has been associated with head trauma, cerebral palsy, spinal cord injury, peripheral neuropathy,

lesions of the hypothalamus, and cerebral or brainstem strokes [2, 3]. We report a case of a 61-year-old man with isolated sweating on the left side of his entire body; a right-sided brainstem meningioma producing mass effect is the suspected underlying cause.

## Case Synopsis

A 61-year-old right-handed male with no known medical history presented to the dermatologist with complaints of sweating on the left side of the body, including face, trunk, left arm, and left leg for a duration of one year. He reported sweating that drenched his clothes on occasion that was worse during the summer months. The patient emphasized a clear line of demarcation between the left and right sides of his body, with excessive sweating on the left side. In addition, he described a tingling sensation on the right side of his face whenever he ate spicy foods. The patient denied taking any current medications and had no history of head trauma or spinal cord injury. He denied any weakness or visual changes and had a negative review of systems. Physical examination of the body revealed no abnormalities of the skin.

Owing to concern for a focal brain lesion, the patient was scheduled for a magnetic resonance image of the brain with, and without contrast.



**Figure 1.** Magnetic resonance imaging of the brain demonstrates a 1.74×2.36-centimeter extra-axial mass originating from the right side of the tentorium just posterior to the cavernous sinus; this likely represents a meningioma.

Imaging showed a 2.5-centimeter extra-axial mass, which appeared to originate from the right side of the tentorium just posterior to the right cavernous sinus. The mass possessed smooth margins and showed brisk enhancement, which likely represented a meningioma causing mass effect on the right anterior aspect of the pons of the brainstem (**Figure 1**). The patient was subsequently referred to the neurosurgery department for evaluation.

The patient ultimately declined subtotal surgical resection of the mass and decompression of the trigeminal nerve. However, a couple of months later, he returned to neurosurgery clinic for persistent left-sided hyperhidrosis, increasing numbness on the right side of his face, and some mild disturbances in peripheral vision on the right side. Reimaging did not demonstrate a change in the size of the lesion. The patient's case was discussed at a multidisciplinary tumor board and the patient subsequently underwent five rounds

of stereotactic radiosurgery. On follow-up, he was much improved and noted sweating on both sides of his body. He experienced slightly increased sweating on the left side of his face as compared to the right. He described occasional watering of his eyes but denied any issues with his vision.

## Case Discussion

Our case highlights the unique finding of isolated unilateral hyperhidrosis and its association with brainstem pathology. Unilateral hyperhidrosis is a phenomenon that has been described in patients after infarction of the cerebral hemispheres, hypothalamus, pons, medulla and spinal cord. Sympathetic pathways that are postulated to arise in the cortex, possibly the frontal operculum, project to the hypothalamus, descend into the brainstem, cross in the medulla, and make connections with sympathetic sudomotor neurons in the contralateral thoracic spinal cord

are believed to be inhibitory to sweating. At the level of the pons and medulla, the fibers of this inhibitory pathway are believed to descend in very close proximity to the corticospinal tract [4]. In the absence of motor deficits, the isolated contralateral hyperhidrosis observed in this patient suggests a precise clinicoanatomic correlation independent of the pyramidal tracts.

## References

1. McConaghy JR, Fosselman D. Hyperhidrosis: Management Options. *Am Fam Physician*. 2018;97:729-734. [PMID: 30215934].
2. Kreyden OP, Schmid-Grendelmeier P, Burg G. Idiopathic Localized Unilateral Hyperhidrosis: Case Report of Successful Treatment with Botulinum Toxin Type A and Review of the Literature. *Arch Dermatol*. 2001;137:1622-1625. [PMID: 11735712].
3. Iseri PK, Bayramgurler D, Koc K. Unilateral localized hyperhidrosis associated with frontal lobe meningioma. *Neurology*. 2004;63:1753-1754. [PMID: 15534278].
4. Kim BS, Kim YI, Lee KS. Contralateral hyperhidrosis after cerebral infarction. Clinicoanatomic correlations in five cases. *Stroke*. 1995;26:896-899. [PMID: 7740586].

## Conclusion

We propose that the patient's pure contralateral hyperhidrosis may be attributed to the mass effect of the meningioma compromising a portion of this sympathetic inhibitory pathway.

## Potential conflicts of interest

The authors declare no conflicts of interests.