

UCSF

UC San Francisco Previously Published Works

Title

Clinical outcomes of percutaneous drainage of breast fluid collections after mastectomy with expander-based breast reconstruction.

Permalink

<https://escholarship.org/uc/item/8z28w7p1>

Journal

Journal of vascular and interventional radiology : JVIR, 24(9)

ISSN

1051-0443

Authors

Tong, Ricky T
Kohi, Maureen
Fidelman, Nicholas
[et al.](#)

Publication Date

2013-09-01

DOI

10.1016/j.jvir.2013.04.036

Peer reviewed



Published in final edited form as:

J Vasc Interv Radiol. 2013 September ; 24(9): 1369–1374. doi:10.1016/j.jvir.2013.04.036.

Clinical outcomes of percutaneous drainage of breast fluid collections following mastectomy with expander-based breast reconstruction

Abstract

PURPOSE—To determine clinical outcomes of patients who underwent imaging-guided percutaneous drainage of breast fluid collections following mastectomy and breast reconstruction.

MATERIAL AND METHODS—Retrospective review included all consecutive patients who underwent percutaneous drainage of fluid collections following mastectomy with tissue expander-based reconstruction between January 2007 and September 2012. A total of 879 mastectomies (563 patients) with expander-based breast reconstruction were performed during this period. 28 patients (5%) developed fluid collections, which led to 30 imaging-guided percutaneous drainage procedures. The median follow up time was 533 days. Patient characteristics, surgical technique, microbiology analysis, and clinical outcomes were reviewed.

RESULTS—The mean age was 51.5 years (range 30.9 to 69.4 years) and the median time between breast reconstruction and drainage was 35 days (range 4 to 235 days). Erythema and swelling were the most common presenting symptoms. The median volume of fluid evacuated at the time of drain placement was 70 mL. Drains were left in place for a median 14 days (range 6 to 34 days). Microorganisms were detected in the fluid in 12 of 30 drainage procedures, with *Staphylococcus aureus* being the most common microorganism. No further intervention was needed in 21 of 30 drainage procedures (70%). However, surgical intervention (removal of expanders) was needed following 6 (20%) drainages, and additional percutaneous drainage procedures were performed following 3 (10%) drainages.

CONCLUSION—Percutaneous drainage is an effective means of treating post operative fluid collections after expander-based breast reconstruction and can obviate the need for repeat surgery in most cases.

Introduction

Breast cancer is the second leading cause of cancer death among women, and mastectomy remains a common surgical treatment [1]. Many patients undergo breast reconstruction surgery immediately following mastectomy [2]. According to the American Society of Plastic Surgeons report, approximately 90,000 breast reconstruction procedures were performed in the US in 2010 [2], and the majority of them involved insertion of a tissue expander. Breast fluid collection is one of most common complications of breast reconstruction surgeries. Most fluid collections develop between the skin and the pectoralis muscle/expander pocket and can lead to uncontrolled distention adjacent to the expander [3]. Fluid collections can also cause pain and discomfort, delay initiation of adjuvant cancer therapies, and impede wound healing. Moreover, fluid collections may become infected or may lead to overlying skin necrosis [4–6].

Although the pathophysiology of breast fluid collection remains unclear, studies have identified several risk factors and predictors such as age and BMI > 30 [7–11]. Other researchers also examined various mechanical and chemical techniques to obliterate the dead space during surgery to reduce breast fluid formation after mastectomy [12–14]. Studies have also shown that early surgical drain removal did not increase the risk of breast fluid collection formation [15, 16].

Due to the risk of expander puncture during drainage, breast fluid collections are often drained under a combination of ultrasound and fluoroscopic guidance. While imaging guided drainage of breast fluid collection is a commonly used treatment, the clinical outcomes of imaging guided drainage are not known. In this study, we present our experience accumulated at a single institution with drainage of breast fluid collections over a 5-year period.

Materials and Methods

Patient selection

This study was approved by the Institutional Review Board at our institution. Informed consent requirement was waived. A retrospective record review of all consecutive patients who underwent imaging-guided percutaneous drainage of fluid collections following breast reconstruction at our institution from January 2007 to September 2012 was performed. All patients who underwent mastectomy for biopsy-proven breast cancer immediately followed by expander placement were included in this study. Patients who underwent lumpectomy, mastectomy without breast reconstruction, or exchange of expander with silicone implant/expander were excluded from this study. Patients who underwent percutaneous imaging-guided breast fluid collection drainage in the setting of mastitis without a prior history of breast reconstruction were also excluded.

Patient demographics, operative reports and clinical notes were obtained through electronic medical records. Ultrasound images and reports as well as fluoroscopic images and reports were obtained and reviewed through the picture archiving and communication system (PACS).

Study outcomes

The primary outcome of the study was the clinical success of percutaneous drainage. Successful drainage was defined as resolution of presenting signs and symptoms without a need for surgical procedure or additional percutaneous drainage following the initial drainage procedure prior to permanent implant placement. In addition, information pertaining to microbiologic fluid analysis and clinical signs and symptoms of infection were collected. The clinical and microbiology data were derived from chart review.

Patient demographics

Between January 2007 to September 2012, 879 mastectomy procedures (in 563 patients) with expander placement (bilateral mastectomies counted as 2 mastectomy procedures) were performed in our institution. Among them, 413 mastectomies (43%) have AlloDerm

regenerative tissue matrix (LifeCell Corporation, Branchburg, NJ) placed during the surgery. A total of 30 fluid collections developed in 28 patients, which required percutaneous drainage. Two of the patients had repeat drainage procedures due to recurrent fluid collections despite successful drainage initially from the first drainage. The patient demographics and types of mastectomy and breast reconstruction procedures performed are summarized in Table 1. All patients underwent skin-sparing mastectomies. The mean age of patients was 51.5 years (range 30.9 to 69.4 years). All 28 patients underwent mastectomies for removal of malignancy. 18 out of 28 patients (64%) underwent bilateral mastectomies, and the remaining 10 patients (36%) underwent unilateral mastectomies. 1 out of the 18 patients with bilateral mastectomies had breast cancers in both breasts, while the remaining 17 patients with bilateral mastectomies had breast cancer only in one of the breasts. In 8 out of those 17 patients, breast fluid collection developed on the same side as the breast cancer. All mastectomies were immediately followed by subpectoral tissue expander placement. Types of expander coverage include subpectoral alone in 7 out of 28 patients (25%), subpectoral coverage with serratus muscle flap in 5 patients (17.9%), subpectoral coverage with AlloDerm in 15 patients (53.6%) and subpectoral coverage with a combination of AlloDerm® and serratus muscle flap in 1 patient (3.6%).

In addition to mastectomy with tissue expander placement, 8 out of 28 patients (29%) had sentinel lymph node dissection, 5 patients (18%) had axillary lymph node dissection and 3 patients (11%) had both sentinel lymph node and axillary lymph node dissections.

Seven patients had radiation therapy prior to breast fluid collection drainage. One of them underwent post-mastectomy radiation therapy, while the rest of them received radiation therapy prior to mastectomy. Thirteen patients also had systemic chemotherapy prior to breast fluid collection drainage. Ten of them received neoadjuvant chemotherapy and the other three patients received chemotherapy after mastectomy but prior to or during the period of breast fluid collection drainage.

All of the patients were started on antibiotics at the time of mastectomy (typically oral trimethoprim/sulfamethoxazole unless patients were allergic to the medications) until the removal of surgical drains. When patients developed breast fluid collections, antibiotics were initiated again in anticipation of imaging-guided drainage procedure. The choice of antibiotics was at the discretion of plastic surgeon, but the patients either received oral antibiotics (clindamycin or cephalexin) if they had no or minimal signs of infection or admitted for IV antibiotics if they had significant signs of infection such as elevated white blood cell count, systemic symptoms or significant erythema. For IV antibiotics, vancomycin and piperacillin/tazobactam were used until the fluid culture results were available, then the antibiotics were adjusted appropriately.

The initial presenting signs and symptoms are summarized in Table 1. While most patients presented with multiple symptoms, erythema (70% of 30 drainage procedures) and swelling (53%) were the most common initial presenting symptoms associated with fluid collections.

Diagnostic Ultrasound

Some of the breast fluid collection drainage procedures were preceded by diagnostic ultrasound studies. The estimated volumes of fluid collections were based on the reported three orthogonal measurements and by assuming the fluid collection were ellipsoids.

Percutaneous drainage procedures

All percutaneous drainage procedures were performed by fellowship trained interventional radiologists. Local anesthesia using 1% lidocaine was administered to all patients. The needle size used to access fluid collections was mentioned in 26 procedure reports. Under direct real-time sonographic guidance, either a 21-gauge needle/micropuncture set (24 out of 26 procedures, 92%) or a 19-gauge needle (2 out of 26 procedures, 8%) was advanced into the collection. If a 21-gauge needle/micropuncture set was used, a 0.018" guidewire and a 4-French Micropuncture conversion system (Cook Medical Inc, Bloomington IN) were employed. Subsequently, a long-taper 0.035" guidewire (Cook Medical Inc) was inserted through the 4-French introducer. If a 19-gauge needle was used, a 0.035" guidewire was inserted directly through the needle. The wire was allowed to coil within the collection. Guidewire placement within the fluid collection was confirmed under ultrasound and fluoroscopy. The track was then serially dilated, and a drainage catheter was placed into the fluid collection. The size and type of the drainage catheter was at the discretion of the treating interventional radiologist. Multipurpose (Cook) or Dawson-Mueller drainage catheters (Cook) ranging from 8.5-French (Fr) to 12.0-Fr were used for the drainage. No immediate major or minor complications were reported in all cases. As much fluid as possible was drained when the catheters were initially placed. The volumes of fluid evacuated at the time of drain placement were recorded, and a fluid samples were sent for bacterial culture and Gram-stain evaluation.

At our institution, after drainage catheters were placed, patients returned to plastic surgery clinic weekly for re-assessment. At the time of clinic visit, the drainage catheter was removed if the clinical symptoms had resolved and the drainage output was less than 20 mL over a 24-hour period.

Statistical Analysis

The variables examined in this study included age of the patients, type of reconstruction surgery, type and size of the drainage tube used, time period spent with a drain in place, volume of fluid collection based on the ultrasound examination, volume of fluid removed upon drain placement, white blood cell (WBC) count within 7 days prior to drainage, clinical symptoms at presentation, results of microbiologic fluid analysis, and clinical success of the drainage. Fisher's Exact test and paired Student's t-test were used to analyze the data. All statistical analyses were performed using Microsoft Excel (Microsoft, Redmond, Washington). A p-value <0.05 was considered statistically significant.

Results

The median follow up time was 533 days (range 11 to 1946 days), from the day of imaging guided procedure to the most recent breast cancer clinic day. The median time between

breast reconstruction and drainage of fluid collections was 35 days (range 4 to 235 days). A diagnostic ultrasound study was obtained prior to percutaneous drainage in 22 out of 30 drainage (73%). Of note, after 2009, all patients had a diagnostic ultrasound study prior to fluid collection drainage. Only 10 of the 22 ultrasound studies included the size measurements of the fluid collections in all three orthogonal dimensions. Assuming that collections were ellipsoid in shape, the median volume based on the reported sonographic measurements was 6.6 mL (range, 1.6 to 45 mL). While most fluid collections were anechoic on ultrasound, some of them presented with septations (11 of 22 cases, 50%), and 7 of 22 cases (32%) had heterogeneous echogenic debris within the fluid collections (Figure 1a and 1b).

The drainage catheters employed for fluid evacuation ranged from 8.5-Fr to 12.0-Fr (Table 2). Twenty-nine cases reported the type of drainage catheter use. In 22 out of 29 cases (76%), Dawson-Mueller drainage catheters were used while the remaining drainages were performed using multipurpose catheters (7 of 29 cases, 24%). In 25 out of 30 drainages, the total volume of the drained fluid was recorded at the time of the procedure. The median volume of the drained fluid was 70 mL (range 5 to 900 mL). The estimated fluid collection volumes based on ultrasound measurements were significantly lower than the actual amounts of fluid evacuated immediately following drain placement ($p=0.0069$). Twenty-seven out of 30 dictation reports of imaging guided drainage procedure reported the appearance of drained fluid. In 12 cases, the fluid was described as “cloudy”, “thick” or “purulent” in the procedure report.

In all procedures, fluid samples were sent for laboratory analysis (Table 3). In 18 out of 30 drainages (60%), fluid culture results were negative for bacterial growth. Twelve cases (40%) were found to have positive fluid culture, with *Staphylococcus aureus* being the most common isolated pathogen ($n=7$). In 2 of these 7 drainages, Methicillin-resistant *Staphylococcus aureus* was isolated. The fluid culture obtained from the other 5 procedures grew *Serratia marcescens*, viridans streptococci, *Pseudomonas aeruginosa*, *Staphylococcus epidermidis* and *Mycobacterium*. A total of 21 patients had their WBC count results available within 7 days prior to the drainage, and 5 of them (24% of 21 patients) demonstrated leukocytosis. Neither the abnormal WBC count ($p=0.397$) nor the ultrasound appearance (septations ($p = 0.324$) or presence of echogenic debris (0.349)) correlated with positive fluid culture on univariate analysis. However, there was a statistically significant association between purulent fluid appearance and positive fluid culture (Table 4, $p=0.02$).

The median time spent with an indwelling catheter was 14 days (range 6 to 34 days). Clinical success (resolution of clinical symptoms without additional intervention needed) was achieved following 21 out of 30 drainages (70%). In 6 patients (20%), surgical removal of the expander was required despite drainage procedures. For these 6 patients, the symptoms persist despite placement of drainage catheter. 3 patients (10%) required additional imaging-guided procedures (10%). 2 patients required re-insertion of a drainage catheter due to re-accumulation of fluid collection after catheter removal and 1 patient needed a catheter exchange due to leakage at the catheter skin exit site. Positive fluid culture did not correlate with a requirement for additional imaging-guided or surgical procedures ($p = 0.296$).

Discussion

Breast reconstruction surgery commonly follows mastectomy. In recent years improved surgical techniques and better coordination between neoadjuvant therapy and surgery have improved the quality and outcome of breast reconstruction surgery [17]. However, breast reconstruction surgeries do result in complications. Accumulation of fluid adjacent to the expander is the most common early complication of breast reconstruction surgery, with incidence of 2.5% – 51% [3, 18, 19].

The pathophysiology of post-breast reconstruction fluid accumulation is poorly understood [20]. Fluid collections are likely composed of an inflammatory exudate in response to surgery. Gonzalez et al. showed that the incidence of fluid collection formation is influenced by the type of surgery, with radical mastectomy having a higher incidence than breast-conserving therapy [18]. Mastectomies likely lead to a more extensive damage to vascular and lymphatic structures than breast-conservation surgery, thus resulting in an increased incidence of fluid collection formation. Other reported risk factors for accumulation of fluid include age, BMI > 30, diabetes, radiation, hypertension and increased initial drainage via surgical drains [7–10].

The outcome of breast reconstruction surgery relies heavily on overlying soft tissue coverage and mechanical support [21]. Additional procedures such as acellular dermal matrix placement, serratus muscle flap, pectoralis minor muscle flaps, and rectus fascial extension have been performed to optimize the tissue coverage. Several types of acellular dermal matrix are currently available, including AlloDerm, DermaMatrix (Synthes, Inc., West Chester, PA) and FlexHD (Ethicon Inc., Bedminister, NJ). Brook et al [22] suggested that use of these three acellular dermal matrices is associated with similar complication and infection rates. Two other studies demonstrated that the rate of fluid accumulation is higher when AlloDerm is used [23, 24]. At our institution, AlloDerm is used to provide complete coverage of the expander when needed. Out of 879 mastectomies performed during the study period, 413 (43%) of them had AlloDerm placement. Among the 28 patients examined in our study, 16 mastectomies with AlloDerm placement (57%, out of 28 patients or affected mastectomies) developed breast fluid collections (including the one patient with both AlloDerm placement and serratus muscle flap). Further research is required to determine whether AlloDerm placement affects the clinical success of drainage procedures.

Formation of breast fluid collections is usually an early complication of breast reconstruction. In our series, the majority of the patients (>70%) underwent drainage within 50 days of the breast reconstruction surgery. However, there were 3 patients whose fluid collections developed at least 100 days after the surgery. Interestingly, two of these patients had neoadjuvant chemotherapy, and one patient received adjuvant chemotherapy. Furthermore, one of these patients also had concurrent radiation therapy. While this is a small subgroup, it raises the possibility that radiation and/or chemotherapy may be additional risk factors for delayed fluid accumulation. One study demonstrates that the failed rate of reconstruction is as high as 40% if radiation therapy was performed 3 weeks after tissue expanders were implanted, versus 2.3% in the control group with no radiation therapy [25]. Peled et al [26] showed that neither neoadjuvant or adjuvant chemotherapy affects the

expander loss rate, although there slight increase risk of infection with adjuvant chemotherapy.

Our study showed that 12 cases had positive fluid cultures (1.4% of 879 mastectomies with expander procedures or 40% of drainage procedures). Our findings are in contrast those of Chun et al. [5] who showed the infection rate of drained fluid was 8.9% and Spear et al. [17] who demonstrated the infection rate was 6.7%. Both of these studies show a higher infection rates than our study. On the other hand, Anthony et al. [4] reported none of the fluid collections were infected. One might expect a higher percentage of positive fluid culture given the patients' initial presenting symptoms. One potential explanation for lower rate of positive fluid culture than expected is that at our institution, patients were treated with antibiotics for suspected breast fluid collections prior to drainage. Thus, by the time of the drainage procedure, patients could have been treated with antibiotics for up to 2 days.

Similar to the findings of Chun et al. [5], fluid culture revealed a wide spectrum of pathogens, with *Staphylococcus aureus* being the most common pathogen isolated from the fluid. While presence of leukocytosis was not associated with positive fluid culture, statistically significant difference was seen between purulent, thick, and/or cloudy fluid appearance and positive fluid culture. This finding implies that it is important to take note of the appearance of drained fluid as it may predict whether the fluid collection is infected or not before the final culture results. This can potentially influence the decision regarding initiation of antibiotic therapy.

At our institution, since 2009, all patients underwent a diagnostic breast ultrasound study prior to fluid collection drainage. Assuming fluid collections are ellipsoid shape, the calculated fluid collection volume on ultrasound was statistically smaller than the initial drainage volume ($p=0.0069$). This finding suggests that it is difficult to estimate the true volume of a fluid collection by ultrasound. Since fluid within the collections tends to be freely mobile and collections take on irregular shapes, it is difficult for sonographers to determine if the fluid is "drainable" or not. A trial of imaging-guided drainage may be warranted for most symptomatic patients with a fluid collection detected after breast reconstruction.

One limitation of the study is its retrospective design. Since most of the clinical data are based on visit notes, some of the information is incomplete, leading to information bias. To minimize selection bias, we included only patients who underwent mastectomies with breast reconstruction surgery during the study period. Additionally, this was a single institutional review. Different institutions might have various approaches to management of post-operative breast fluid collections. The small sample size prevented us from performing meaningful subgroup analyses.

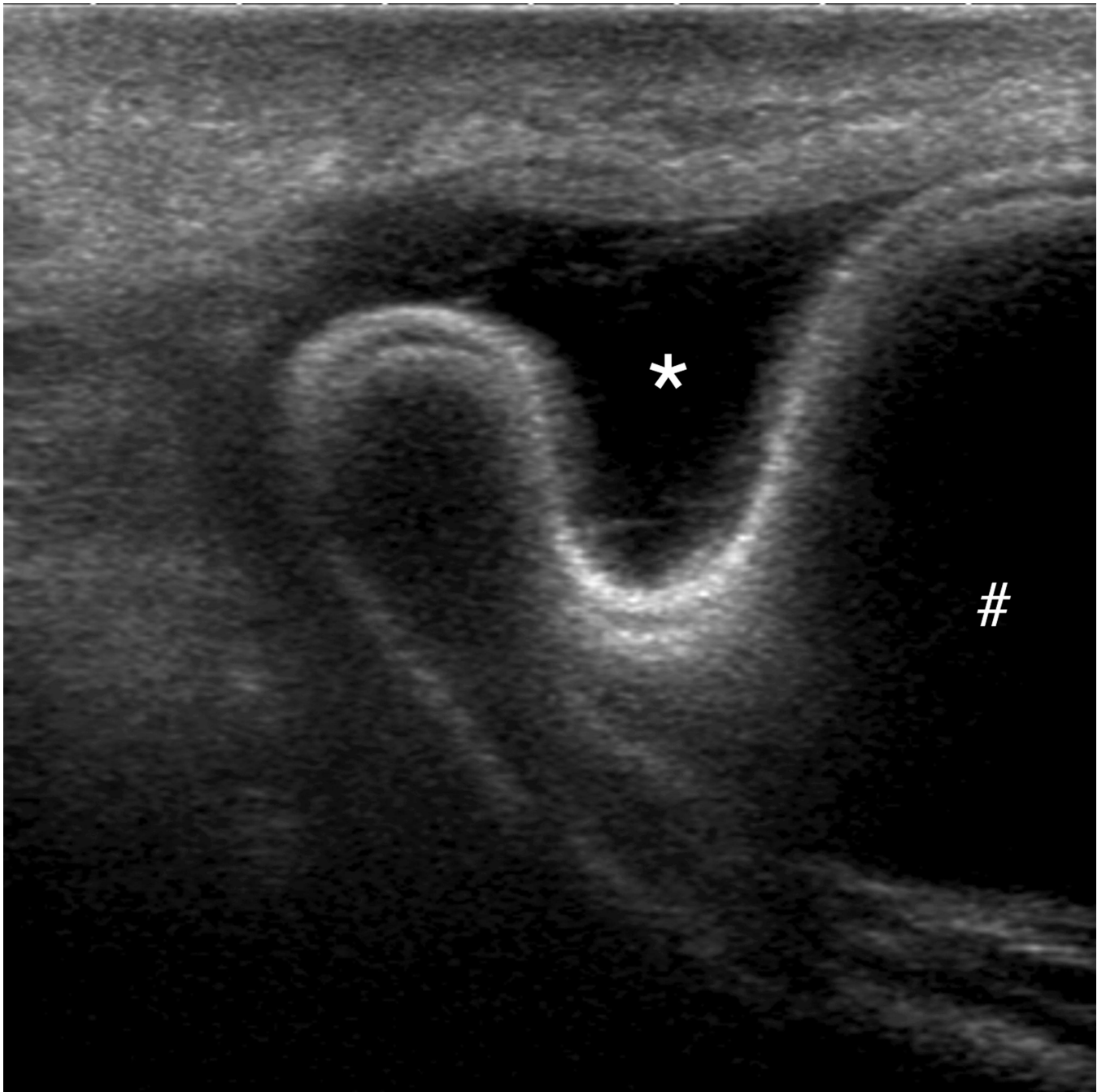
In conclusion, most fluid collections developed after expander-based breast reconstruction can be managed successfully by imaging-guided drainage. In our study, only 40% of the cases were found to have a positive microbial culture, which may be due to initiation of antibiotics therapy prior to drainage. Clinical success was achieved in 21 out of 30 drainage procedures (70%). Despite conservative management with antibiotic treatment and

percutaneous drainage catheter placement, six patients (20%) ultimately required expander removal. These findings support the importance of early percutaneous drainage of breast fluid collections in order to prevent more significant morbidity for patients, including unnecessary hospitalizations, unplanned operative procedures, and potential reconstructive loss.

References

1. Siegel R, Naishadham D, Jemal A. Cancer statistics, 2013. *CA: a cancer journal for clinicians*. 2013; 63:11–30. [PubMed: 23335087]
2. Gurunluoglu R, Gurunluoglu A, Williams SA, Tebockhorst S. Current Trends in Breast Reconstruction: Survey of American Society of Plastic Surgeons 2010. *Annals of plastic surgery*. 2011
3. Moyer KE, Potochny JD. Technique for seroma drainage in implant based breast reconstruction. *Journal of plastic, reconstructive & aesthetic surgery : JPRAS*. 2012
4. Antony AK, McCarthy CM, Cordeiro PG, et al. Acellular human dermis implantation in 153 immediate two-stage tissue expander breast reconstructions: determining the incidence and significant predictors of complications. *Plastic and reconstructive surgery*. 2010; 125:1606–1614. [PubMed: 20517083]
5. Chun YS, Verma K, Rosen H, et al. Implant-based breast reconstruction using a cellular dermal matrix and the risk of postoperative complications. *Plastic and reconstructive surgery*. 2010; 125:429–436. [PubMed: 20124828]
6. Newman MI, Swartz KA, Samson MC, Mahoney CB, Diab K. The true incidence of near-term postoperative complications in prosthetic breast reconstruction utilizing human a cellular dermal matrices: a meta-analysis. *Aesthetic plastic surgery*. 2011; 35:100–106. [PubMed: 21184070]
7. Akinci M, Cetin B, Aslan S, Kulacoglu H. Factors affecting seroma formation after mastectomy with full axillary dissection. *Acta Chir Belg*. 2009; 109:481–483. [PubMed: 19803259]
8. Berry T, Brooks S, Sydow N, et al. Complication rates of radiation on tissue expander and autologous tissue breast reconstruction. *Ann Surg Oncol*. 2010; 17(Suppl 3):202–210. [PubMed: 20853034]
9. Brooks S, Djohan R, Tendulkar R, Nutter B, Lyons J, Dietz J. Risk factors for complications of radiation therapy on tissue expander breast reconstructions. *Breast J*. 2012; 18:28–34. [PubMed: 22098451]
10. Loo WT, Chow LW. Factors predicting seroma formation after mastectomy for Chinese breast cancer patients. *Indian journal of cancer*. 2007; 44:99–103. [PubMed: 18250530]
11. Srivastava V, Basu S, Shukla VK. Seroma formation after breast cancer surgery: what we have learned in the last two decades. *Journal of breast cancer*. 2012; 15:373–380. [PubMed: 23346164]
12. Coveney EC, O'Dwyer PJ, Geraghty JG, O'Higgins NJ. Effect of closing dead space on seroma formation after mastectomy--a prospective randomized clinical trial. *Eur J Surg Oncol*. 1993; 19:143–146. [PubMed: 8491318]
13. Gong Y, Xu J, Shao J, et al. Prevention of seroma formation after mastectomy and axillary dissection by lymph vessel ligation and dead space closure: a randomized trial. *Am J Surg*. 2010; 200:352–356. [PubMed: 20409509]
14. Jain PK, Sowdi R, Anderson AD, MacFie J. Randomized clinical trial investigating the use of drains and fibrin sealant following surgery for breast cancer. *The British journal of surgery*. 2004; 91:54–60. [PubMed: 14716794]
15. Inwang R, Hamed H, Chaudary MA, Fentiman IS. A controlled trial of short-term versus standard axillary drainage after axillary clearance and iridium implant treatment of early breast cancer. *Annals of the Royal College of Surgeons of England*. 1991; 73:326–328. [PubMed: 1929138]
16. Parikh HK, Badwe RA, Ash CM, et al. Early drain removal following modified radical mastectomy: a randomized trial. *Journal of surgical oncology*. 1992; 51:266–269. [PubMed: 1434659]

17. Spear SL, Parikh PM, Reisin E, Menon NG. Acellular dermis-assisted breast reconstruction. *Aesthetic plastic surgery*. 2008; 32:418–425. [PubMed: 18338102]
18. Gonzalez EA, Saltzstein EC, Riedner CS, Nelson BK. Seroma formation following breast cancer surgery. *The breast journal*. 2003; 9:385–388. [PubMed: 12968958]
19. Hashemi E, Kaviani A, Najafi M, Ebrahimi M, Hooshmand H, Montazeri A. Seroma formation after surgery for breast cancer. *World journal of surgical oncology*. 2004; 2:44. [PubMed: 15588301]
20. Agrawal A, Ayantunde AA, Cheung KL. Concepts of seroma formation and prevention in breast cancer surgery. *ANZ journal of surgery*. 2006; 76:1088–1095. [PubMed: 17199696]
21. Gamboa-Bobadilla GM. Implant breast reconstruction using acellular dermal matrix. *Ann Plast Surg*. 2006; 56:22–25. [PubMed: 16374090]
22. Brooke S, Mesa J, Uluer M, et al. Complications in Tissue Expander Breast Reconstruction: A Comparison of AlloDerm, DermaMatrix, and FlexHD Acellular Inferior Pole Dermal Slings. *Annals of plastic surgery*. 2012; 69:347–349. [PubMed: 22868313]
23. Parks JR, Hammond SE, Walsh WW, Adams RL, Chandler RG, Luce EA. Human Acellular Dermis (ACD) vs. No-ACD in Tissue Expansion Breast Reconstruction. *Plastic and reconstructive surgery*. 2012
24. Glasberg SB, Light D. AlloDerm and Strattice in breast reconstruction: a comparison and techniques for optimizing outcomes. *Plast Reconstr Surg*. 2012; 129:1223–1233. [PubMed: 22327891]
25. Nava MB, Pennati AE, Lozza L, Spano A, Zambetti M, Catanuto G. Outcome of different timings of radiotherapy in implant-based breast reconstructions. *Plast Reconstr Surg*. 2011; 128:353–359. [PubMed: 21788827]
26. Warren Peled A, Itakura K, Foster RD, et al. Impact of chemotherapy on postoperative complications after mastectomy and immediate breast reconstruction. *Archives of surgery*. 2010; 145:880–885. [PubMed: 20855759]



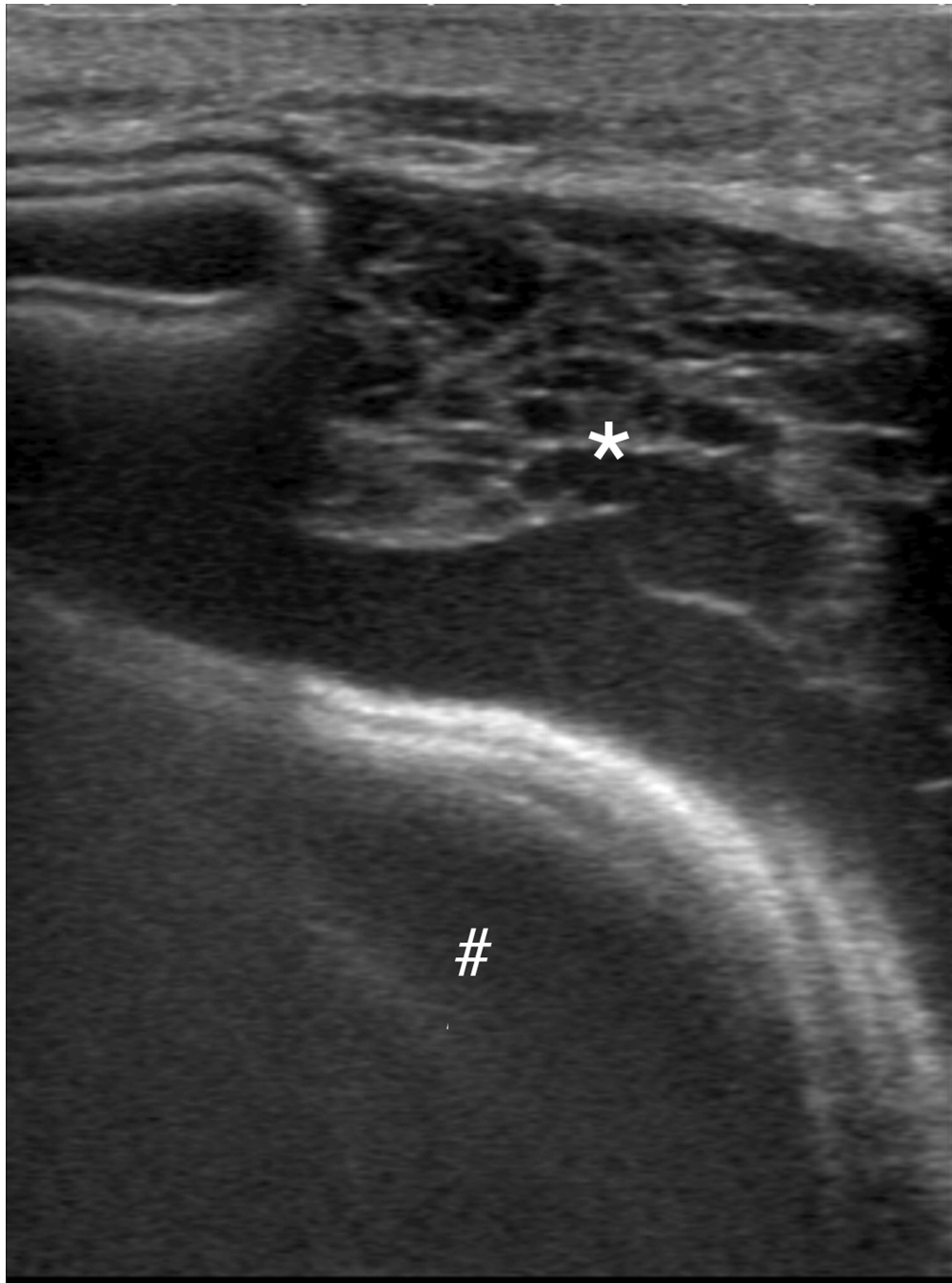


Figure 1. Ultrasound images of breast fluid collections. (a) Breast fluid collection (*) either abuts a fold in a non-fully inflated tissue expander versus partially deforms the expander (#). (b) Breast fluid collection (*) with septations.

Table 1

Characteristics of patients with imaging guided breast fluid collection drainage following mastectomy and expander-based breast reconstruction surgery

Categories/Variables	Mean (SD) or n (%)
<u>Demographic</u>	
Number of patients	28
Age in years	51.5 (9.0)
Female gender	28 (100%)
<u>Breast surgery (% of patients)</u>	
Bilateral mastectomies	18 (64%)
Unilateral mastectomy	10 (36%)
<u>Reconstructive surgery (% of patients)</u>	
Expander alone	7 (25%)
Expander with AlloDerm	15 (53.6%)
Expander with serratus muscle flap	5 (17.9%)
Expander with AlloDerm and serratus muscle flap	1 (3.6%)
<u>Pre-drainage therapy (% of patients)</u>	
Pre-drainage radiation therapy	7 (25%)
Pre-mastectomy radiation	6 (21%)
Post-mastectomy radiation	1 (4%)
Pre-drainage chemotherapy	13 (46%)
Pre-mastectomy chemotherapy (neoadjuvant)	10 (35%)
Post-mastectomy chemotherapy (adjuvant)	3 (11%)
<u>Initial presenting signs/symptoms (% of drainage procedures)</u>	
Erythema	16 (53%)
Swelling	10 (33%)
Fever	11 (37%)
Tenderness	4 (13%)
Other *	21 (70%)

* Other symptoms include chill, malaise, skin breakdown and skin dimpling

Table 2

Drainage catheter used in breast fluid collection drainage.

Catheter Size (Fr)		Number, (%)
Multipurpose catheter	8.5	1 (3%)
	10.2	4 (14%)
	12.0	2 (7%)
Dawson Mueller	8.5	10 (34%)
	10.2	10 (34%)
	12.0	2 (7%)

Author Manuscript

Author Manuscript

Author Manuscript

Author Manuscript

Table 3

Fluid culture analysis

Fluid culture result	Number
Negative	18
<i>Staphylococcus aureus</i> *	7
Other †	5

* 2 samples showed Methicillin-resistant *Staphylococcus aureus*

† 1 case of *Serratia marcescens*, 1 case of viridans streptococci, 1 case of *Pseudomonas aeruginosa*, 1 case of *Mycobacterium fortuitum*, 1 case of *Staphylococcus epidermidis*.

Table 4

Fluid culture results with respect to appearance of fluid collections

Fluid appearance	Fluid culture	
	Normal	abnormal
clear	12	4
Cloudy, thick fluid or pus	3	8

Fisher's Exact test (p=0.02)

Author Manuscript

Author Manuscript

Author Manuscript

Author Manuscript