

UC Davis

Dermatology Online Journal

Title

Linear, pruritic red to brown papules on the left chest

Permalink

<https://escholarship.org/uc/item/8ww2w4xw>

Journal

Dermatology Online Journal, 20(11)

Authors

Ren, Vicky
Champion, Rachel W
Boyd, Alan S
[et al.](#)

Publication Date

2014

DOI

10.5070/D32011024685

Copyright Information

Copyright 2014 by the author(s). This work is made available under the terms of a Creative Commons Attribution-NonCommercial-NoDerivatives License, available at <https://creativecommons.org/licenses/by-nc-nd/4.0/>

Peer reviewed

Photo Vignette

Linear, pruritic red to brown papules on the left chest

Vicky Ren BS¹, Rachel W. Champion MD², Alan S. Boyd MD², Jennifer G. Powers MD²

Dermatology Online Journal 20 (11): 15

¹Baylor College of Medicine, Houston, TX, USA

²Division of Dermatology, Vanderbilt University, Nashville, TN, USA

Correspondence:

Rachel W. Champion, MD
Vanderbilt University Division of Dermatology
719 Thompson Lane, Ste 26300
Nashville, TN 37204
Ph: (615) 322-6485
Fax: (615) 343-2591
rachel.w.champion@vanderbilt.edu

Abstract

A 28-year-old woman presented with a 12-year history of red to brown papules in a linear distribution on the left lateral chest associated with recent flares of pruritus. She had previously been clinically diagnosed with lichen planus. A punch biopsy was performed, and histopathologic exam revealed Darier-like acantholysis. The patient was diagnosed with type 1 segmental Darier disease and her symptoms improved with topical tretinoin.

Keywords: Darier disease, Darier-White, keratosis follicularis, dyskeratosis follicularis, type 1, segmental, localized, linear, zosteriform, unilateral

Introduction

Darier disease is an autosomal dominant genodermatosis characterized by pruritic red to brown keratotic papules in a seborrheic distribution. Segmental Darier disease is a subtype of Darier disease first described in 1906. Type 1 segmental Darier disease is characterized by linear seborrheic papules on a background of normal skin whereas type 2 segmental Darier disease is characterized by a linear region of accentuated Darier's disease on a background of generalized disease. Although rare, one should consider segmental Darier disease in a patient with localized Darier's skin findings; the disease is chronic and transmission of generalized Darier disease to offspring is theoretically possible.

Case synopsis

A 28-year-old woman presented with a 12-year history of a linear, pruritic eruption on her left lateral chest, previously diagnosed clinically as lichen planus. The patient reported increased flares of pruritus over the months prior to presentation, particularly when the area was occluded or she became overheated. Physical examination revealed multiple 2-5 mm well-defined, red to brown papules in a linear distribution on the left lateral chest (Figure 1). Examination was otherwise unremarkable. A punch

biopsy of a single papule revealed foci of suprabasilar, acantholytic clefting and overlying areas of parakeratotic keratinocytes within a hyperkeratotic stratum corneum (Figure 2). Corp ronds and corp grains were noted (Figure 3). The patient was diagnosed with type 1 segmental Darier disease and treated with tretinoin 0.025% cream nightly, which in combination with avoidance of triggers, resulted in decreased pruritus.

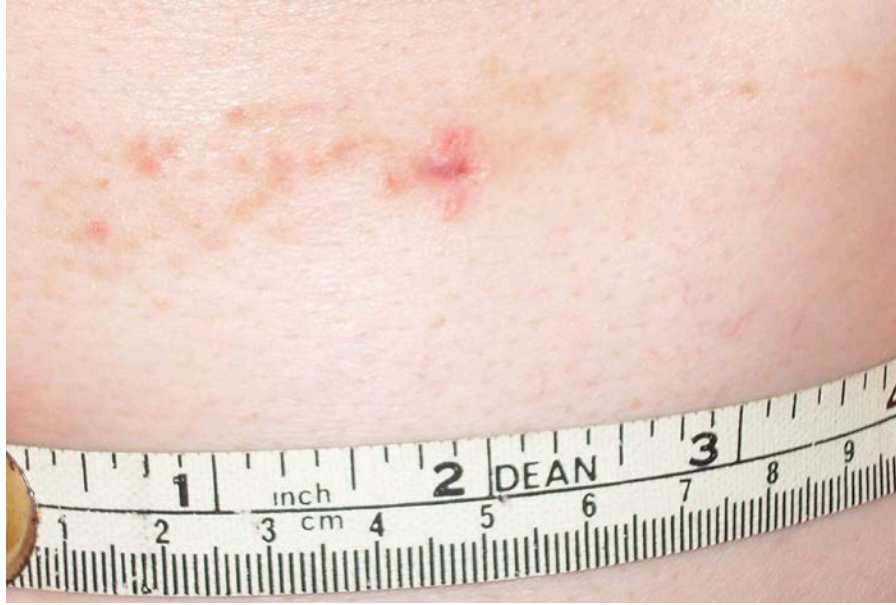

Figure 1. Red-to-brown papules in a linear distribution on the left lateral chest

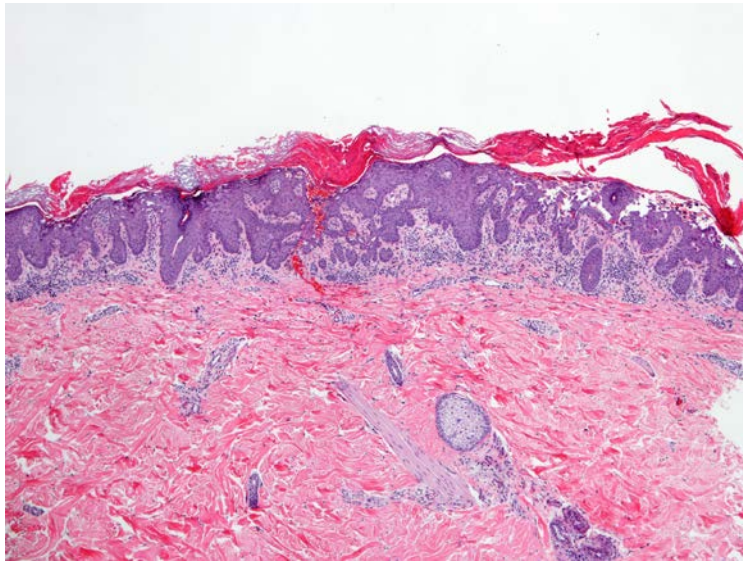


Figure 2. Foci of suprabasilar, acantholytic clefting and parakeratotic keratinocytes within a hyperkeratotic stratum corneum (H&E, original magnification x 40)

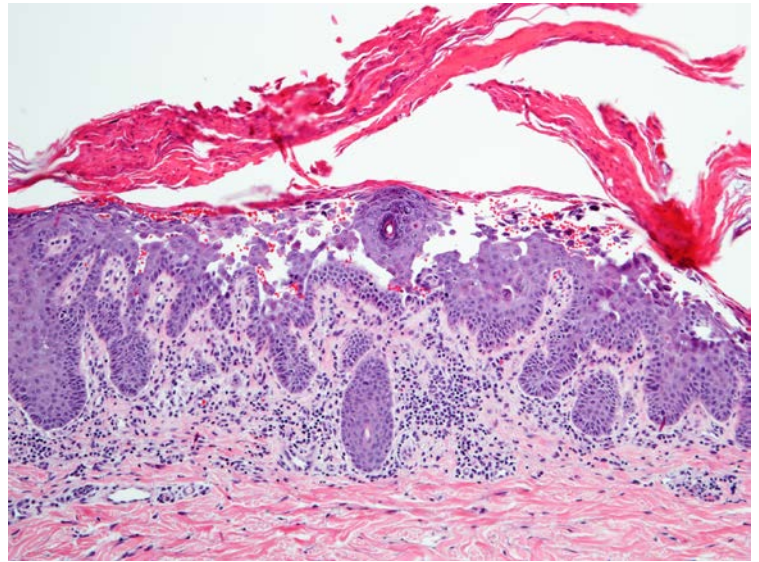


Figure 3. Corps ronds and corps grains within an acantholytic cleft (H&E, original magnification x 200)

Discussion

Darier disease (also known as Darier-White disease, keratosis follicularis, or dyskeratosis follicularis), is an autosomal dominant genodermatosis characterized by pruritic red to brown keratotic papules in a seborrheic distribution [1]. Palmoplantar papules, nail changes, and oral papules may also be observed [2, 3]. The disease is caused by mutations in the ATP2A2 gene, which leads to insufficient function of the sarco/endoplasmic reticulum Ca^{2+} ATPase (SERCA2) with consequent acantholysis and dyskeratosis [4]. In the vast majority of patients, disease onset occurs between ages 6 and 20. The disease is chronic with no spontaneous remission, but severity may fluctuate [5]. Exacerbating factors include UV light, sweating, heat, and occlusion [1].

Segmental Darier disease (also known as localized, linear, zosteriform, or unilateral Darier disease) is characterized by morphologically identical lesions in a limited distribution that follow the lines of Blaschko [6, 7, 8]. Lesions usually present in the third or fourth decade of life, most frequently on the trunk [7]. Nail abnormalities, including red and white longitudinal bands and V-shaped nicking are unusual in the segmental variant but have been reported [7, 8]. Histopathologic findings of segmental Darier disease are indistinguishable from that seen in the generalized form of the disease. Two types of segmental Darier disease with distinct genetic backgrounds have been described. Type 1 segmental Darier disease arises from a post-zygotic mutation in ATP2A2 and is characterized by lesional skin on a background of normal skin [1], as seen in our patient. Heterozygous ATP2A2 mutations in affected but not background skin have been detected in patients with type 1 segmental Darier disease [9]. Type 2 segmental Darier disease arises from loss of heterozygosity owing to a heterozygous germline mutation in ATP2A2 with subsequent post-zygotic mutation on the other allele; it is characterized by generalized disease with linear streaks of increased severity [1].

Patients with segmental Darier disease typically do not report a family history of disease and to date we have been unable to locate any case reports of transmission of generalized Darier disease to offspring [7]. However, if gonadal mosaicism is present, a patient with type 1 segmental manifestations may have offspring with generalized Darier disease [1]. Harboe et. al. reported an ATP2A2 mutation in the semen of a male patient with segmental Darier disease [10], further supporting the possibility that the generalized form of the disease may be transmitted to progeny. Patients with segmental Darier disease should be counseled regarding this possibility.

While rare, it is important to consider segmental Darier disease in a patient who presents with localized skin findings characteristic of generalized Darier disease. Biopsy should be performed to confirm diagnosis. A favorable response to various combinations of topical agents, including tretinoin cream, lactic acid, salicylic acid, and corticosteroids, as well as oral retinoids, has been observed [6, 7]. Successful treatment with a pulsed dye laser has been reported as well [11]. Although there are no reports of using carbon dioxide laser for treatment of segmental disease, this has been effective for treatment of generalized Darier disease [12].

References

1. Itin PH, Buchner SA, Happle R. Segmental manifestation of Darier disease. What is the genetic background in type 1 and type 2 mosaic phenotypes? *Dermatology*. 2000;200(3):254-7. [PMID: 10828637]
2. Burge S. Darier's disease—the clinical features and pathogenesis. *Clin Exp Dermatol*. 1994;19(3):193-205. [PMID: 8033376]
3. Macleod RI, Munro CS. The incidence and distribution of oral lesions in patients with Darier's disease. *Br Dent J*. 1991;171(5):133-6. [PMID: 1931295]
4. Sakuntabhai A, Ruiz-Perez V, Carter S, et al. Mutations in ATP2A2, encoding a Ca²⁺ pump, cause Darier disease. *Nat Genet*. 1999;21(3):271-77. [PMID: 10080178]
5. Burge SM, Wilkinson JD. Darier-White disease: a review of the clinical features in 163 patients. *J Am Acad Dermatol*. 1992;27(1):40-50. [PMID: 1619075]
6. Gilaberte M, Puig L, Vidal D, Alomar A. Acantholytic dyskeratotic naevi following Blaschko's lines: a mosaic form of Darier's disease. *J Eur Acad Dermatol Venereol*. 2003;17(2):196-9. [PMID: 12705751]
7. O'Malley MP, Haake A, Goldsmith L, Berg D. Localized Darier disease. Implications for genetic studies. *Arch Dermatol*. 1997;133(9):1134-8. [PMID: 9301591]
8. Munro CS, Cox NH. An acantholytic dyskeratotic epidermal naevus with other features of Darier's disease on the same side of the body. *Br J Dermatol*. 1992;127(2):168-71. [PMID: 1390147]
9. Sakuntabhai A, Dhitavat J, Burge S, Hovnanian A. Mosaicism for ATP2A2 mutations causes segmental Darier's disease. *J Invest Dermatol*. 2000;115(6):1144-7. [PMID: 11121153]
10. Harboe TL, Willems P, Jespersgaard C, Mølgaard Poulsen ML, Sørensen FB, Bisgaard ML. Mosaicism in segmental Darier disease: an in-depth molecular analysis quantifying proportions of mutated alleles in various tissues. *Dermatology*. 2011;222(4):292-6. [PMID: 21720150]
11. Schmitt L, Roos S, Raulin C, Karsai S. Segmental Darier disease : treatment with pulsed dye laser. *Hautarzt*. 2009;60(12):995-8. [PMID: 19367372]
12. Brown VL, Kelly SE, Burge SM, Walker NP. Extensive recalcitrant Darier disease successfully treated with laser ablation. *Br J Dermatol*. 2010;162(1):227-9. [PMID: 19912213]