

# UC Davis

## Dermatology Online Journal

### Title

Molluscum contagiosum of the eyelid: case report in a man receiving methotrexate and literature review of molluscum contagiosum in patients who are immunosuppressed secondary to methotrexate or HIV infection

### Permalink

<https://escholarship.org/uc/item/8vz669cj>

### Journal

Dermatology Online Journal, 22(3)

### Authors

Beutler, Bryce David  
Cohen, Philip R

### Publication Date

2016

### DOI

10.5070/D3223030363

### Copyright Information

Copyright 2016 by the author(s). This work is made available under the terms of a Creative Commons Attribution-NonCommercial-NoDerivatives License, available at <https://creativecommons.org/licenses/by-nc-nd/4.0/>

Peer reviewed

**Case report**

**Molluscum contagiosum of the eyelid: case report in a man receiving methotrexate and literature review of molluscum contagiosum in patients who are immunosuppressed secondary to methotrexate or HIV infection**

**Bryce David Beutler<sup>1</sup> and Philip R Cohen<sup>2</sup>**

**Dermatology Online Journal 22 (3): 5**

<sup>1</sup>University of Nevada School of Medicine

<sup>2</sup>University of California, San Diego, School of Medicine

**Correspondence:**

Bryce D. Beutler, BS  
1060 Wiegand Road  
Encinitas, CA 92024  
brycebeutler@hotmail.com

Philip R Cohen, MD  
10991Twinleaf Court  
San Diego, CA 92131  
Email: mitehead@gmail.com

---

**Abstract**

**Background:** Molluscum contagiosum is a benign viral infection of the skin. Lesions typically present as dome-shaped, flesh-colored, umbilicated papules that range in size from 1 to 5 millimeters in diameter. They are usually asymptomatic, but can become tender or pruritic. Children and immunocompromised adults, including individuals being treated with immunosuppressive drugs, are most susceptible to infection. Single or multiple lesions most commonly appear on the extremities, face, genitals, and trunk. However, albeit rarely, molluscum contagiosum may also develop at other sites, including the eyelids.

**Purpose:** We describe the clinical and pathologic findings of a man who developed molluscum contagiosum of the eyelid while receiving methotrexate. We also review the characteristics of other patients with molluscum contagiosum acquired either during treatment with methotrexate or associated with human immunodeficiency virus (HIV) infection and summarize the unusual sites of presentation for the viral lesions in these individuals.

**Materials and methods:** The features of a man receiving methotrexate who developed molluscum contagiosum of the eyelid are presented. Using PubMed, the following terms were searched and relevant citations assessed: adalimumab, contagiosum, Enbrel, etanercept, Humira, infliximab, methotrexate, molluscum, Remicade, TNF alpha, and tumor necrosis factor alpha. In addition, the literature on methotrexate treatment and molluscum contagiosum is reviewed.

**Results:** Several small papules were observed on the eyelid of a 24-year-old man who had been receiving methotrexate and adalimumab (Humira) for the treatment of Crohn disease. The lesions were removed by shave biopsy. Microscopic examination revealed epidermal hyperplasia composed of keratinocytes filled with large eosinophilic intracytoplasmic inclusions. Based on correlation of the clinical presentation and histopathologic findings, a diagnosis of molluscum contagiosum was established. The patient applied mupirocin 2% ointment to the biopsy sites, which subsequently healed without complication or recurrence.

**Conclusion:** Molluscum contagiosum is a benign viral papular eruption that frequently affects children and immunocompromised adults. Patients treated with immunosuppressive agents, such as methotrexate, have a heightened risk of developing molluscum contagiosum lesions. It remains to be determined whether adjunct therapy with a tumor necrosis factor alpha inhibitor increases the risk of this viral infection. Diagnosis can usually be established by clinical presentation, although a biopsy is sometimes

required to exclude other conditions. Molluscum contagiosum is generally self-limiting and often resolves spontaneously within 18 months. However, topical (cantharidin) or locally destructive (curettage, cryotherapy, and/or laser) therapy may be indicated for patients who are concerned about persistent lesions and for children who are particularly susceptible to autoinoculation.

**Keywords:** adalimumab, AIDS, contagiosum, Enbrel, etanercept, HIV, Humira, infliximab, methotrexate, molluscum, Remicade, TNF alpha, tumor necrosis factor alpha

## Introduction

Molluscum contagiosum is a benign cutaneous viral infection. Lesions typically present as asymptomatic, flesh-colored, umbilicated papules ranging in size from 1 to 5 millimeters in diameter. Children and immunocompromised adults, including individuals receiving immunosuppressive therapies, may be at a heightened risk for developing molluscum contagiosum lesions.

We describe a man with Crohn disease who developed molluscum contagiosum of the eyelid while receiving methotrexate. We also review the differential diagnosis of molluscum contagiosum, the characteristics of other patients with molluscum contagiosum acquired during treatment with methotrexate or associated with human immunodeficiency virus (HIV) infection, and the unusual sites of presentation for the viral lesions in these individuals.

## Case synopsis

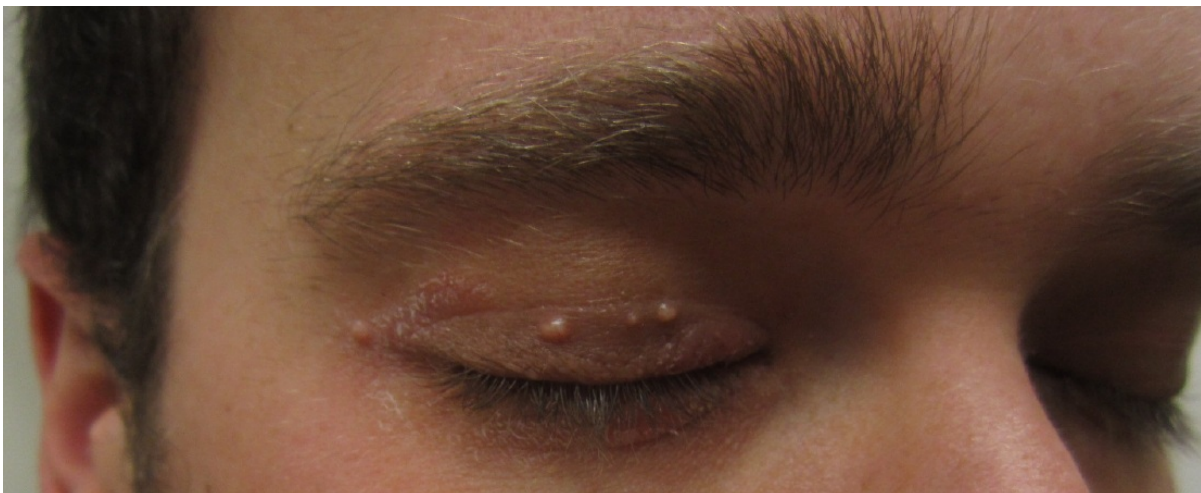A 24-year-old man with a 13-year history of Crohn disease presented in January 2015 for evaluation of several small lesions on his eyelid of 3 months duration. Crohn disease was diagnosed at 11 years of age. Infliximab (Remicade) was started at age 13 (10 mg/kg every 4 weeks) with weekly oral methotrexate. Within a year, he achieved a sustained remission of his Crohn disease.

In June 2012, his fecal calprotectin was 29 mg/kg (negative: < 0-50 mg/kg, borderline: 50-100 mg/kg, positive: > 100 mg/kg). Infliximab was stopped and he continued methotrexate (7.5 milligrams each week). However, by October 2013, his fecal calprotectin had increased to 195 mg/kg.

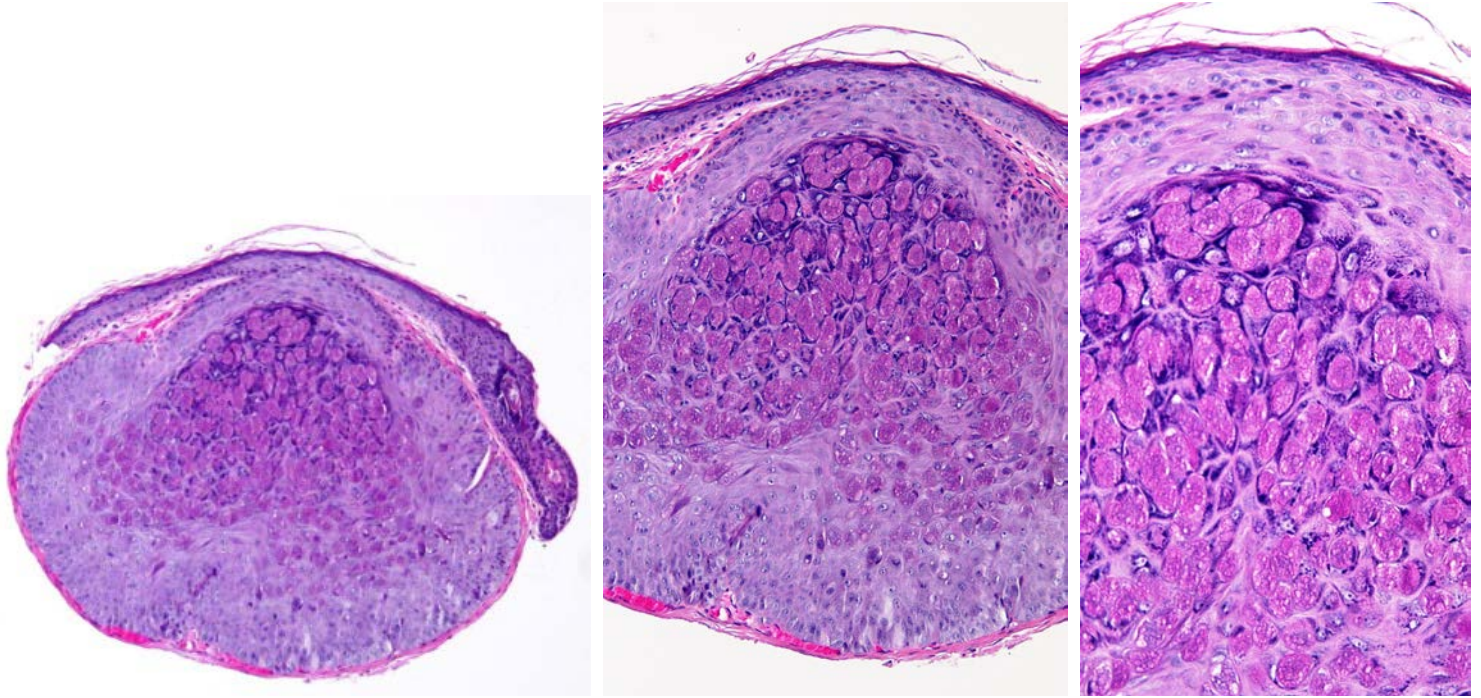
In January 2014, he began to develop recurrent oral ulcers and biopsy confirmed terminal ileitis and distal proctitis. Adjunct therapy with adalimumab (Humira) (40 milligrams once every 2 weeks) was subsequently initiated in March 2014 and his gastrointestinal symptoms resolved.

He developed dermatitis and lesions on his right upper eyelid in September 2014. Neither family members, sexual partners, nor other close personal contacts had any skin conditions. His dermatitis resolved within 2 days of beginning twice daily application of desonide 0.05% ointment.

In January 2015, cutaneous examination revealed recurrent dermatitis and persistence of 4 dome-shaped, flesh-colored papules involving his right upper eyelid and right lateral canthus (Figure 1). No lesions were present elsewhere on his body. The papules ranged in size from 1 to 3 millimeters in diameter and appeared similar to milia. However, attempted extraction of the lesions with a #11 scalpel blade was unsuccessful. A shave removal was subsequently performed. Histopathologic examination of all lesions showed similar changes: epidermal hyperplasia composed of keratinocytes filled with large eosinophilic intracytoplasmic inclusions (Figure 2).



**Figure 1.** Molluscum contagiosum papules involving the right upper eyelid and lateral canthus of a 24-year-old man with Crohn disease who was being treated with methotrexate and adalimumab



**Figure 2 (a, b, and c).** Low (a), intermediate (b), and high (c) magnification views of a molluscum contagiosum papule. Low magnification view (a) shows pronounced epidermal hyperplasia. The hallmark "molluscum body" -- a large, oval-shaped, eosinophilic, intracytoplasmic inclusion -- can be observed in both the intermediate magnification view (b) and the high magnification view (c). [Hematoxylin and eosin; a = x4, b = x10, c = x20].

Based on correlation of the clinical presentation and pathology findings, a diagnosis of molluscum contagiosum was established. The lesions had been completely removed by the shave biopsies. The patient applied mupirocin 2% ointment to the biopsy sites, which subsequently healed without complication or recurrence.

## Discussion

Molluscum contagiosum is a benign viral infection characterized by the development of flesh-colored, dome-shaped papules on the skin or mucous membranes. It was first described by Bateman in 1817 [1]. Henderson and Paterson later identified the distinctive intracytoplasmic inclusion bodies -- now referred to as "molluscum bodies" or "Henderson-Paterson bodies" -- that represent the histologic hallmark of the lesions [2]. In 1905, Juliusberg demonstrated the infectious nature of the condition by inoculating himself and two colleagues with the ground-up contents of multiple molluscum contagiosum lesions [3].

Molluscum contagiosum is a common infection. Although the worldwide incidence was once estimated to be between 2% and 8% [4], recent seroprevalence studies suggest that the true incidence is much higher [5]. Indeed, the condition is likely underreported owing to its benign and often self-limiting nature. Lesions are most frequently observed in young children and immunocompromised adults, particularly those with human immunodeficiency virus (HIV) [6,7].

Skin lesions typically present as asymptomatic, dome-shaped, flesh-colored papules. They generally range in size from 1 to 5 millimeters in diameter, although lesions as large as 1.5 centimeters in diameter have been described [8]. A central area of umbilication is a distinguishing feature of molluscum contagiosum papules; however, in some patients, including our own, the umbilication is not clearly visible. Multiple lesions are usually present, but solitary papules are not uncommon. Rarely, patients have described their lesions to be pruritic or tender. The lesions may resolve spontaneously within 18 months, although it is not uncommon for them to persist for many months, or even years, particularly in immunocompromised individuals.

Molluscum contagiosum papules most commonly develop on the extremities, face, genitals, and trunk [9]. Lesions that appear in immunocompetent adults are usually acquired through sexual contact and rarely spread beyond the genital region [10]. Less

common sites of infection include the areola [11], eyelids [12], fingers [13], lateral canthus [14], nipple [11,15], and sole of the foot [16].

Molluscum contagiosum can often be identified based on its clinical features; the unique central umbilication distinguishes molluscum contagiosum papules from similar-appearing lesions. However, pathologic examination is sometimes indicated, especially in immunocompromised patients who may present with other opportunistic infections or malignancies that mimic molluscum contagiosum (Table 1) [11,15,17,18].

**Table 1.** Clinical differential diagnosis of molluscum contagiosum

Benign adnexal tumors
Eccrine poroma
Leiomyoma
Sebaceous hyperplasia
Syringoma
Fungal infections
Aspergillosis
Coccidiomycosis
Cryptococcus
Histoplasmosis
Malignant tumors
Basal cell carcinoma
Keratoacanthoma
Paget's disease
Other
Granuloma annulare (papular)
Lichen planus
Papilloma
Viral infections
Condyloma acuminatum
Verruca vulgaris

Histologically, molluscum contagiosum is characterized by markedly swollen keratinocytes containing large molluscum bodies -- dense, oval-shaped, eosinophilic, intracytoplasmic inclusions. Prominent acanthosis is also common. Notably, the molluscum body is among the largest known viral structures in human histopathology. Indeed, it is often so large that it compresses the keratinocyte nucleus or displaces it to the periphery of the cell [11,15].

Individuals receiving immunosuppressive therapies may have an increased risk of developing molluscum contagiosum. Molluscum contagiosum in individuals receiving methotrexate was first identified in 1968 and has since been described in 9 other patients (Table 2) [19-26]. Tumor necrosis factor alpha inhibitors, such as infliximab (Remicade) and etanercept (Enbrel), have also been linked to molluscum contagiosum [27,28]. Our patient was receiving both methotrexate and a tumor necrosis factor alpha inhibitor (adalimumab) for the treatment of Crohn disease. He did not develop molluscum contagiosum during 10 years of methotrexate and infliximab or the following years when he received methotrexate monotherapy. However, within 6 months after starting adalimumab therapy (along with maintaining methotrexate), molluscum contagiosum lesions appeared. We therefore suspect that his eruption may be attributed to the synergistic activity of methotrexate plus adalimumab.

**Table 2.** Characteristics of patients with methotrexate-associated molluscum contagiosum

Case	Age	Site	TNF $\alpha$ Inhibitor	Underlying Disease	Treatment	Reference
1	24 years	Eyelid	Adalimumab	Crohn disease	Shave biopsy	Current report
2	39 years	Not reported	None	Mycosis fungoides	None	19
3	49 years	Eyelids	None	Mixed connective tissue disease	Surgical excision	20

4	67 years	Trunk and extremities	None	Rheumatoid arthritis	Curettage	21
5	67 years	Eyelids	Infliximab	Rheumatoid arthritis	Surgical excision	22
6	69 years	Eyelids, cheeks, and neck	None	Rheumatoid arthritis	Topical hydrogen peroxide 1% cream	23
7	69 years	Trunk, extremities, and buttocks	None	Plaque psoriasis	Methotrexate withdrawn	24
8	70 years	Trunk, extremities, and buttocks	None	Plaque psoriasis	Curettage	25
9	70 years	Trunk, extremities, and buttocks	None	Plaque psoriasis	Methotrexate withdrawn	26
10	72 years	Not reported	None	Exfoliative dermatitis	None	19

Similar to our patient, Cursiefen et al. described a 67-year-old woman with rheumatoid arthritis who developed molluscum contagiosum of the eyelid after a tumor necrosis factor alpha inhibitor (infliximab) was added to her methotrexate and prednisone treatment regimen. The onset of the lesions occurred only a short period of time after adjuvant therapy with infliximab had been initiated. The authors postulated that drug-induced inhibition of tumor necrosis factor-mediated antiviral defenses allowed the molluscum contagiosum to evade host immune responses and replicate. Their hypothesis is supported by Hu et al., who demonstrated that various molluscum contagiosum proteins interfere with tumor necrosis factor-receptor 1 in order to prevent apoptosis of infected cells [22,29]. The dual actions of the tumor necrosis factor alpha inhibitor and the viral proteins could conceivably cultivate an environment favorable to molluscum contagiosum survival.

Molluscum contagiosum is frequently associated with HIV infection and acquired immunodeficiency syndrome (AIDS) (Table 3) [30-37]. The onset of HIV-associated molluscum contagiosum range from infancy and early childhood [30,31] to middle-aged adults [36,37]. Indeed, in some individuals, molluscum contagiosum may serve as the first clinical indicator of HIV infection [30,35,37].

**Table 3.** Characteristics of representative patients with HIV-associated molluscum contagiosum.

Case	Age	Site	Size	HIV Treatment	MC Treatment	Reference
1	2 y	Peri-anal region	0.5 x 0.5 cm to 1.8 x 2 cm (multiple)	None	NR	30
2	5 y	Face and eyelids	0.1 to 1.5 cm (multiple)	None	Zidovudine, nevirapine, lamivudine	31
3	10 y	Left cheek	5 x 6 x 7 cm	Zidovudine, lamivudine, nevirapine	Excision and trichloroacetic acid	32
4	25 y	Face and groin	0.4 to 2 cm (multiple)	Atazanavir, emtricitabine, tenofovir	Paclitaxel (intravenous)	33
5	29 y	Face	NR (multiple giant molluscum contagiosum)	NR	Cidofovir cream and cryotherapy	34
6	34 y	Left and right eyelids	NR (multiple)	None	None	35
7	46 y	Left eyelid	0.2 cm	Combivir, norvir, fortovase	Excision	36
8	48 y	Face,	0.3 to 0.5 cm (multiple)	None	Zidovudine, nevirapine,	37

		neck, and scalp			lamivudine	
--	--	-----------------------	--	--	------------	--

\*Abbreviations: HIV = human immunodeficiency virus; MC = molluscum contagiosum; NR = not reported; y = years

Molluscum contagiosum papules that develop among individuals with HIV or AIDS are often enlarged: giant molluscum contagiosum [30-32,34,38]. They can be solitary [32,36] or multiple [30,31,33-35,37]. In addition, they may appear in uncommon sites, including the eyelids [31,35,36].

In most HIV-positive patients, molluscum contagiosum resolves after highly-active antiretroviral therapy (HAART) is initiated [31,37]. However, albeit rarely, molluscum contagiosum may occur as a manifestation of immune reconstitution inflammatory syndrome (IRIS) following the administration of antiretroviral treatment [38]. Alternatively, other antiviral agents (such as topical cidofovir [34]) have been used. Similar to HIV seronegative patients, destructive interventions (such as trichloroacetic acid [32]) or surgical removal [32,36] may be necessary.

The differential diagnosis for HIV or AIDS-related molluscum contagiosum, similar to HIV seronegative immunosuppressed patients and immunocompetent individuals, includes relatively common dermatoses (Table 1) [11,15,17,18]. Also, in HIV-infected patients, molluscum contagiosum may morphologically mimic the cutaneous manifestations of *Blastomyces dermatitidis*, *Cryptococcus neoformans*, *Histoplasma capsulatum*, *Leishmaniasis*, and *Pneumocystis jirovecii* [39]. In addition, in HIV-seropositive patients, molluscum contagiosum may occur in association with other HIV-related cutaneous conditions, such as Kaposi sarcoma [40].

Molluscum contagiosum is transmitted through direct skin-to-skin contact or, rarely, through fomite-to-skin contact [16]. The double-stranded DNA molluscum contagiosum virus -- a member of the family Poxviridae -- proliferates in the follicular epithelium and replicates within the cytoplasm of keratinocytes, causing the infected cells to swell and ultimately rupture. Various mechanisms are employed in order to evade host defenses; the virus expresses homologues of chemokine-binding proteins and major histocompatibility complex 1 as well as a viral tumor necrosis factor receptor superfamily member 6 (Fas)-Associated with Death Domain (FADD)-like Interleukin 1-Converting Enzyme (FLICE)-like inhibitory protein [41].

Molluscum contagiosum may resolve spontaneously; therefore, treatment is not always necessary. However, prompt removal of the lesions may be indicated in children in order to minimize the risk of inadvertent autoinoculation. In addition, patients who are concerned about the cosmetic appearance of the condition may desire treatment.

Surgical excision, curettage, cryotherapy, and various chemical removal methods have been described in the medical literature [16]. In a 2006 study comparing 4 recognized treatments of molluscum contagiosum -- curettage, cantharidin, imiquimod, and salicylic acid plus lactic acid -- researchers concluded that curettage was the most efficacious treatment and had the lowest rate of adverse effects [42]. Unfortunately, immunocompromised patients often present with lesions that are resistant to standard therapies [20]. These individuals may benefit from combined treatment involving several different modalities, including imiquimod, CO2 laser, trichloroacetic acid, and/or antiviral medication [43,44]. Withdrawal of immunosuppressive therapies may ultimately be necessary in patients with severe infections [24,26].

## Conclusion

Molluscum contagiosum is a benign viral infection of the skin that frequently occurs in young children and immunocompromised adults. Lesions typically present as flesh-colored, dome-shaped papules ranging in size from 1 to 5 millimeters in diameter. They are usually asymptomatic, but can become tender or pruritic. Common sites of presentation include the extremities, face, genitals, and trunk. However, albeit rarely, lesions may appear in unusual locations, such as the areola, eyelids, fingers, or sole of the foot.

Molluscum contagiosum can usually be identified by a single distinguishing clinical feature -- a central area of umbilication at the apex of the papule. However, in some patients, microscopic examination may be required in order to exclude other infections or malignancies. Histologically, molluscum contagiosum is characterized by swollen keratinocytes containing large, eosinophilic, intracytoplasmic structures known as "molluscum bodies."

Patients receiving immunosuppressive therapies or who have an acquired immunodeficiency (such as HIV infection) may have an increased risk of developing molluscum contagiosum. Methotrexate and several tumor necrosis factor alpha inhibitors -- not only etanercept and infliximab, but also adalimumab -- have been linked to molluscum contagiosum. Therefore, combination therapy

with multiple immunosuppressive drugs may contribute to the likelihood of individuals developing this infection after exposure to the virus, molluscum contagiosum.

Lesions may resolve spontaneously. Curettage has been found to be a safe and highly-effective option for most patients. However, immunocompromised individuals presenting with recalcitrant lesions may require combination therapy involving several different modalities.

## References

1. Bateman F: Molluscum contagiosum. In: Shelley WB, Cressey JT, editors. *Classics in Dermatology*. Springfield, Charles C. Thomas: 1953;20.
2. Brown ST, Nalley JF, Kraus SJ: Molluscum contagiosum. *Sex Transm Dis*. 1981;8(3):227-234. PMID: 7027479.
3. Juliusberg M: Zur Kenntnis des virus des Molluscum contagiosum. *Dtsch Med Wochenschr*. 1905;31:1598-1599.
4. Billstein SA, Mattaliano VJ Jr.: The "nuisance" of sexually transmitted diseases: molluscum contagiosum, scabies, and crab lice. *Med Clin North Am*. 1990;74(6):1487-1505. PMID: 2246949.
5. Sherwani S, Farleigh L, Agarwal N, Loveless S, Robertson N, Hadaschik E, Schnitzler P, Burgert JJ: Seroprevalence of Molluscum contagiosum virus in German and UK populations. *PLoS One*. 2014;9(2):e88734. PMID: 24558417.
6. Olsen JR, Gallacher J, Piquet V, Francis NA: Epidemiology of molluscum contagiosum in children: a systematic review. *Fam Pract*. 2014;31(2):130-136. PMID: 24297468.
7. Chaudhary M, Kulkarni M: Molluscum contagiosum in human immunodeficiency virus infected patients. *Indian J Dent Res*. 2008;19(2):155-159. PMID: 18445935.
8. Vardhan P, Goel S, Goyal G, Kumar N: Solitary giant molluscum contagiosum presenting as lid tumor in an immunocompetent child. *Indian J Ophthalmol*. 2010;58(3):236-238. PMID: 20413930.
9. Laxmisha C, Thappa DM, Jaisankar TJ: Clinical profile of molluscum contagiosum in children versus adults. *Dermatol Online J*. 2003;9(5):1. PMID: 14996374.
10. Stock I: Molluscum contagiosum -- a common but poorly understood "childhood disease" and sexually transmitted illness. *Med Monatsschr Pharm*. 2013;36(8):282-290. PMID: 23977728.
11. Hoyt BS, Tschen JA, Cohen PR: Molluscum contagiosum of the areola and nipple: case report and literature review. *Dermatol Online J*. 2013;19(7):18965. PMID: 24010511.
12. Massa AF, Borges-Costa J, Soares-Almeida L, Sacramento-Marques M: Molluscum contagiosum eyelid lesions in an HIV-patient. *Dermatol Online J*. 2013;19(1):10. PMID: 23374952.
13. Al-Mutairi N: Unusual presentations of molluscum contagiosum. *J Cutan Med Surg*. 2008;12(6):295-298. PMID: 19317952.
14. Rao VA, Baskaran RK, Krishnan MM: Unusual cases of molluscum contagiosum of eye. *Indian J Ophthalmol*. 1985;33(4):263-265. PMID: 3842837.
15. Kumar N, Okiro P, Wasike R: Cytological diagnosis of molluscum contagiosum with an unusual clinical presentation at an unusual site. *J Dermatol Case Rep*. 2010;4(4):63-65. PMID: 21886755.
16. Cohen PR, Tschen JA: Plantar molluscum contagiosum: a case report of molluscum contagiosum occurring on the sole of the foot and a review of the world literature. *Cutis*. 2012;90(1):35-41. PMID: 22908731.
17. Brown J, Janniger CK, Schwartz RA, Silverberg NB: Childhood molluscum contagiosum. *Int J Dermatol*. 2006;45(2):93-99. PMID: 16445494.
18. Hanson D, Diven DG: Molluscum contagiosum. *Dermatol Online J*. 2003;9(2):2. PMID: 12639455.
19. Rosenberg EW, Yusk JW: Molluscum contagiosum. Eruption following treatment with prednisone and methotrexate. *Arch Dermatol*. 1970;101(4):439-441. PMID: 5440817.
20. Cursiefen C, Holbach LM: Molluscum contagiosum in immunosuppression with methotrexate: multiple warts with central depressions of the eyelids. *Klin Monbl Augenheilkd*. 1998;212(2):123-124. PMID: 9577814.
21. Nakamura-Wakatsuki T, Kato Y, Miura T, Yamamoto T: Eruptive molluscum contagiosums in a patient with rheumatoid arthritis and lung cancer. *Rheumatol Int*. 2011;31(8):1117-1118. PMID: 21125279.
22. Cursiefen C, Grunke M, Dechant C, Antoni C, Junemann A, Holbach LM: Multiple bilateral eyelid molluscum contagiosum lesions associated with TNFalpha-antibody and methotrexate therapy. *Am J Ophthalmol*. 2002;134(2):270-271. PMID: 12140038.
23. Madan V, August PJ: Facial molluscum contagiosum in a patient with rheumatoid arthritis taking methotrexate. *Clin Exp Dermatol*. 2008;33(3):347. PMID: 18312454.
24. Lim KS, Foo CC: Disseminated molluscum contagiosum in a patient with chronic plaque psoriasis taking methotrexate. *Clin Exp Dermatol*. 2007;32(5):591-593. PMID: 17692062.
25. Fotiadou C, Lazaridou E, Lekkas D, Kourouklidou A, Demetrios I: Disseminated, eruptive molluscum contagiosum lesions in a psoriasis patient under treatment with methotrexate and cyclosporine. *Eur J Dermatol*. 2012;22(1):147-148. PMID: 22067728.



26. Bansal S, Relhan V, Roy E, Garg VK, Khurana N: Disseminated molluscum contagiosum in a patient on methotrexate therapy for psoriasis. *Indian J Dermatol Venereol Leprol.* 2014;80(2):179-180. PMID: 24685870.
27. Antoniou C, Kosmadaki MG, Stratigos AJ, Katsambas AD: Genital HPV lesions and molluscum contagiosum occurring in patients receiving anti-TNF-alpha therapy. *Dermatology.* 2008;216(4):364-365. PMID: 18285688.
28. Kluger N, Gil-Bistes D, Guillot B, Bessis D: Multiple molluscum contagiosum under etanercept. *Ann Dermatol Venereol.* 2011;138(6-7):518-519. PMID: 21700076.
29. Hu S, Vincenz C, Buller M, Dixit VM: A novel family of viral death effector domain-containing molecules that inhibit both CD-95- and tumor necrosis factor-1-induced apoptosis. *J Biol Chem.* 1997;272(15):9621-9624. PMID: 9092488.
30. Basu S, Kumar A: Giant molluscum contagiosum - a clue to the diagnosis of human immunodeficiency virus infection. *J Epidemiol Glob Health.* 2013;3(4):289-291. PMID: 24206800.
31. Averbuch D, Jaouni T, Pe'er J, Engelhard D: Confluent molluscum contagiosum covering the eyelids of an HIV-positive child. *Clin Experiment Ophthalmol.* 2009;37(5):525-527. PMID: 19624352.
32. Poojary SA, Kokane PT: Giant molluscum contagiosum with granulomatous inflammation and panniculitis: An unusual clinical and histopathological pattern in an HIV seropositive child. *Indian J Sex Transm Dis.* 2015;36(1):95-98. PMID: 26392667.
33. Sisneros SC: Recalcitrant giant molluscum contagiosum in a patient with advanced HIV disease - eradication of disease with paclitaxel. *Top HIV Med.* 2010;18(5):169-172. PMID: 21245518.
34. Baxter KF, Hight AS: Topical cidofovir and cryotherapy -- combination treatment for recalcitrant molluscum contagiosum in a patient with HIV infection. *J Eur Acad Dermatol Venereol.* 2004;18(2):230-231. PMID: 15009318.
35. Leahey AB, Shane JJ, Listhaus A, Trachtman M: Molluscum contagiosum eyelid lesions as the initial manifestation of acquired immunodeficiency syndrome. *Am J Ophthalmol.* 1997;124(2):240-241. PMID: 9262550.
36. Albin T, Rao N: Molluscum contagiosum in an immune reconstituted AIDS patient. *Br J Ophthalmol.* 2003;87(11):1427-1428. PMID: 14609853.
37. Sen S, Goswami BK, Karji N, Bhaumik P: Disfiguring molluscum contagiosum in a HIV-positive patient responding to antiretroviral therapy. *Indian J Dermatol.* 2009;54(2):180-182. PMID: 20101316.
38. Drain PK, Mosam A, Gounder L, Gosnell B, Manzini T, Moosa MY: Recurrent giant molluscum contagiosum immune constitution inflammatory syndrome (IRIS) after initiation of antiretroviral therapy in an HIV-infected man. *Int J STD AIDS.* 2014;25(3):235-238. PMID: 23970647.
39. Hicks MJ, Flaitz CM, Cohen PR: Perioral and cutaneous umbilicated papular lesions in acquired immunodeficiency syndrome. *Oral Surg Oral Med Oral Pathol Oral Radiol Endod.* 1997;83(2):189-191. PMID: 9117749.
40. Prasad Busarla SV, Sayed S, Nazarian RM, Gimbel DC, Moloo Z, Sohani AR: Kaposi sarcoma in association with molluscum contagiosum: an uncommon diagnosis in a single biopsy and potential diagnostic pitfall. *Am J Dermatopathol.* 2012;34(1):e7-e9. PMID: 22262366.
41. Smith KJ, Skelton H: Molluscum contagiosum: recent advances in pathogenic mechanisms, and new therapies. *Am J Clin Dermatol.* 2002;3(8):535-545. PMID: 12358555.
42. Hanna D, Hatami A, Powell J, Marcoux D, Maari C, Savard P, Thibeault H, McCuaig C: A prospective randomized trial comparing the efficacy and adverse effects of four recognized treatments of molluscum contagiosum in children. *Pediatr Dermatol.* 2006;23(6):574-579. PMID: 17156002.
43. Nguyen HP, Franz E, Stiegel KR, Hsu S, Tyring SK: Treatment of molluscum contagiosum in adult, pediatric, and immunodeficient populations. *J Cutan Med Surg.* 2014;18(5):299-306. PMID: 25186990.
44. Yoshinaga IG, Conrado LA, Schainberg SC, Grinblat M: Recalcitrant molluscum contagiosum in a patient with AIDS: combined treatment with CO(2) laser, trichloroacetic acid, and pulsed dye laser. *Lasers Surg Med.* 2000;27(4):291-294. PMID: 11074505.