

UC Davis

UC Davis Previously Published Works

Title

Clinical, Electrophysiological, and Intraoperative Analysis and Postoperative Success of Revision Surgery for Persistent and Recurrent Carpal Tunnel Syndrome.

Permalink

<https://escholarship.org/uc/item/8vm8j33c>

Authors

Jones, Quincy

Hill, Elise E

Li, Andrew

et al.

Publication Date

2024

Peer reviewed

Clinical, Electrophysiological, and Intraoperative Analysis and Postoperative Success of Revision Surgery for Persistent and Recurrent Carpal Tunnel Syndrome

Keywords

[Recurrent Carpal Tunnel Syndrome](#)
[hand](#)

October 2024

ISSN 1937-5719

Index ePlasty 2024;24:e56

Quincy Jones, BS; Elise E. Hill, MD; Andrew Li, MD; Clifford Pereira, MD; Dattesh Dave, MD; Jerrick Robker, DO; Neil F. Jones, MD

© 2024 HMP Global. All Rights Reserved.

Any views and opinions expressed are those of the author(s) and/or participants and do not necessarily reflect the views, policy, or position of ePlasty or HMP Global, their employees, and affiliates.

Abstract

Background. This paper reviews the signs and symptoms of recurrent or persistent carpal tunnel syndrome and examines some of the causes of failed primary carpal tunnel release.

Methods. A retrospective review of the surgical findings and outcomes of 29 consecutive patients who underwent 30 revision carpal tunnel operations was performed. Patient outcomes were recorded at a minimum of 1 year postoperatively.

Results. Thirty hands in 29 consecutive patients underwent a second operation by a single surgeon. The average time interval from the first carpal tunnel release to the revision surgery was 5.7 years. Twenty-three patients experienced recurrent symptoms, and 7 had persistent symptoms. On preoperative examination, 77% demonstrated abductor pollicis brevis muscle weakness, 67% demonstrated a positive Phalen sign, and 63% demonstrated ring finger "sensory splitting." Incomplete release of the transverse carpal ligament and circumferential fibrosis were the most common intraoperative findings, totaling 20 cases each; intact antebrachial fascia (8 cases), volar subluxation of the median nerve (5 cases), compression of the median nerve by palmaris longus (4 cases), flexor tenosynovitis (4 cases), and aberrant anatomy (1 case) were also observed. Nine patients (34%) had complete resolution of symptoms after the revision carpal tunnel release. Fifteen patients (58%) had improvement in symptoms, and 2 patients did not report improvement.

Conclusions. We have found the Phalen sign, comparison of the strength of the abductor pollicis brevis muscle, and subjective "splitting" of the ring finger sensation to be the most helpful findings in establishing the diagnosis. Persistent carpal tunnel syndrome is almost always secondary to incomplete division of the transverse carpal ligament.

Introduction

Carpal tunnel syndrome is the most common nerve compression syndrome in the US and is estimated to affect nearly 8% of the general US working population.¹ The etiology of carpal tunnel syndrome is unclear but is associated with certain risk factors, including repetitive wrist motions, trauma to the wrist, pregnancy, amyloidosis, hypothyroidism, diabetes, rheumatoid arthritis, and cancer.²

Surgical decompression of the median nerve at the wrist through complete division of the transverse carpal ligament (TCL) and antebrachial fascia is an effective procedure with reported success rates ranging from 75% to upwards of 90%.³ However, complications have been reported in up to 19% of these procedures with up to 12% requiring revision surgery.⁴ In 2012, Jones et al described their series of 50 patients who suffered recurrent or persistent carpal tunnel syndrome following index release.⁵ We contribute to this series with an additional 29 consecutive cases (involving 30 hands) of revision carpal tunnel release in this retrospective review. All revision carpal tunnel releases were performed by the senior author (N.F.J.), and associated patient factors, intraoperative findings, and surgical outcomes are analyzed and described.

Methods and Materials

After approval from our institutional review board, we reviewed medical records of patients who underwent a revision carpal tunnel surgery performed by a single surgeon, Neil F. Jones, MD, at the University of California, Irvine Medical Center over a 9-year period from April 2009 through June 2018. All patients with persistent or recurrent carpal tunnel symptoms following index carpal tunnel release who required a repeat carpal tunnel release were included in the study. The associated systemic conditions, comorbidities, preoperative clinical findings, and the technique used for the primary carpal tunnel release were recorded.

The intraoperative findings for each revision were collected from the operative reports, including status of the TCL and antebrachial fascia, any space-occupying lesions, tenosynovitis, fibrosis, aberrant anatomy, and the condition of the median nerve. Patient outcomes were recorded at a minimum of 1 year postoperatively. The outcome measures included complete, improved, or unchanged symptomatic relief categorization; abductor pollicis brevis strength improvement using the Medical Research Council Manual Muscle Testing scale, scored out of a possible 5 points; and the necessity of a third operation. We defined strength improvement as a postoperative Medical Research Council Manual Muscle Testing score greater than the preoperative score.

Results

Thirty hands in 29 consecutive patients underwent a second operation after an index carpal tunnel release over a 9-year period performed by a single surgeon (N.F.J.). Of the initial carpal tunnel releases, 22 were open carpal tunnel releases, 8 were endoscopic releases, and 3 were mini open carpal tunnel releases. Twenty-three patients experienced recurrent symptoms, and 7 had persistent symptoms. The average age of patients with recurrent symptoms and persistent symptoms was 55 and 59 years, respectively. Total and stratified numbers are summarized in **Table 1**.

Variable	Affected hands (N = 30)
Total procedures	
Index open carpal tunnel release, n	19
Index endoscopic carpal tunnel release, n	8
Index mini open carpal tunnel release, n	3
Total symptoms	
Recurrent symptoms, n	23
Persistent symptoms, n	7
Symptoms stratified by index procedure	
Index open carpal tunnel release, n	19
Recurrent symptoms, n	15
Persistent symptoms, n	4
Index endoscopic carpal tunnel release, n	8
Recurrent symptoms, n	6
Persistent symptoms, n	2
Index mini carpal tunnel release, n	3
Recurrent symptoms, n	2
Persistent symptoms, n	1

Table 1. Surgical Approach of Initial Carpal Tunnel Release

The preoperative comorbidities are summarized in **Table 2**. The most commonly found comorbidities were hypertension, hypercholesterolemia, diabetes, trigger finger, and lumbar stenosis, among others. On preoperative examination, 23 hands (77%) demonstrated abductor pollicis brevis muscle (APB) weakness (Medical Research Council Manual Muscle Testing score of less than 5, as examined by N.F.J.), 20 hands (67%) demonstrated a positive Phalen sign, and 19 hands (63%) demonstrated ring finger "sensory splitting." Electrodiagnostic evaluation was performed on 22 hands (73%), and of these, 13 (59%) demonstrated delayed motor latency while only 11 (50%) demonstrated delayed sensory latency.

Condition	N
Hypertension	10
Hypercholesterolemia	8
Diabetes	7
Trigger finger	7
Lumbar spinal stenosis	7
Cervical radiculopathy	6
Lumbar spine fusion	6
de Quervain's tenosynovitis	5
Cervical spine fusion	5
Cubital tunnel syndrome	4
Ulnar tunnel syndrome	4
History of recurrent carpal tunnel syndrome on contralateral side	4
Depression/anxiety	3
Hypothyroidism	3
Migraine	3
Associated ipsilateral distal radius fracture	3
Associated ipsilateral wrist trauma	3
Ipsilateral fall on outstretched hand	3
Inflammatory bowel disease	2
Radial tunnel syndrome	2
Pronator syndrome	2
Rheumatoid arthritis	1
Raynaud phenomenon	1
Lateral epicondylitis	1
Thoracic outlet syndrome	1
Keinbock disease	1
Ganglion	1
Hepatitis C	1
von Willebrand disease	1
Fibromyalgia	1
Other extensor tenosynovitis	1

Table 2. Preexisting Conditions of Study Population Before Revision Surgery

The average time interval from the first carpal tunnel release to the revision surgery was 5.7 years. Intraoperative findings are summarized in **Figure 1** and are grouped by all operated hands and by hands with persistent symptoms. Incomplete release of the TCL was the most common intraoperative finding, totaling 20 cases (66%): 14 cases (43%) incompletely released proximally, 4 cases (13%) incompletely released distally, and 2 cases (7%) were completely intact and unreleased.

Percentage of Hands with Noted Intraoperative Findings

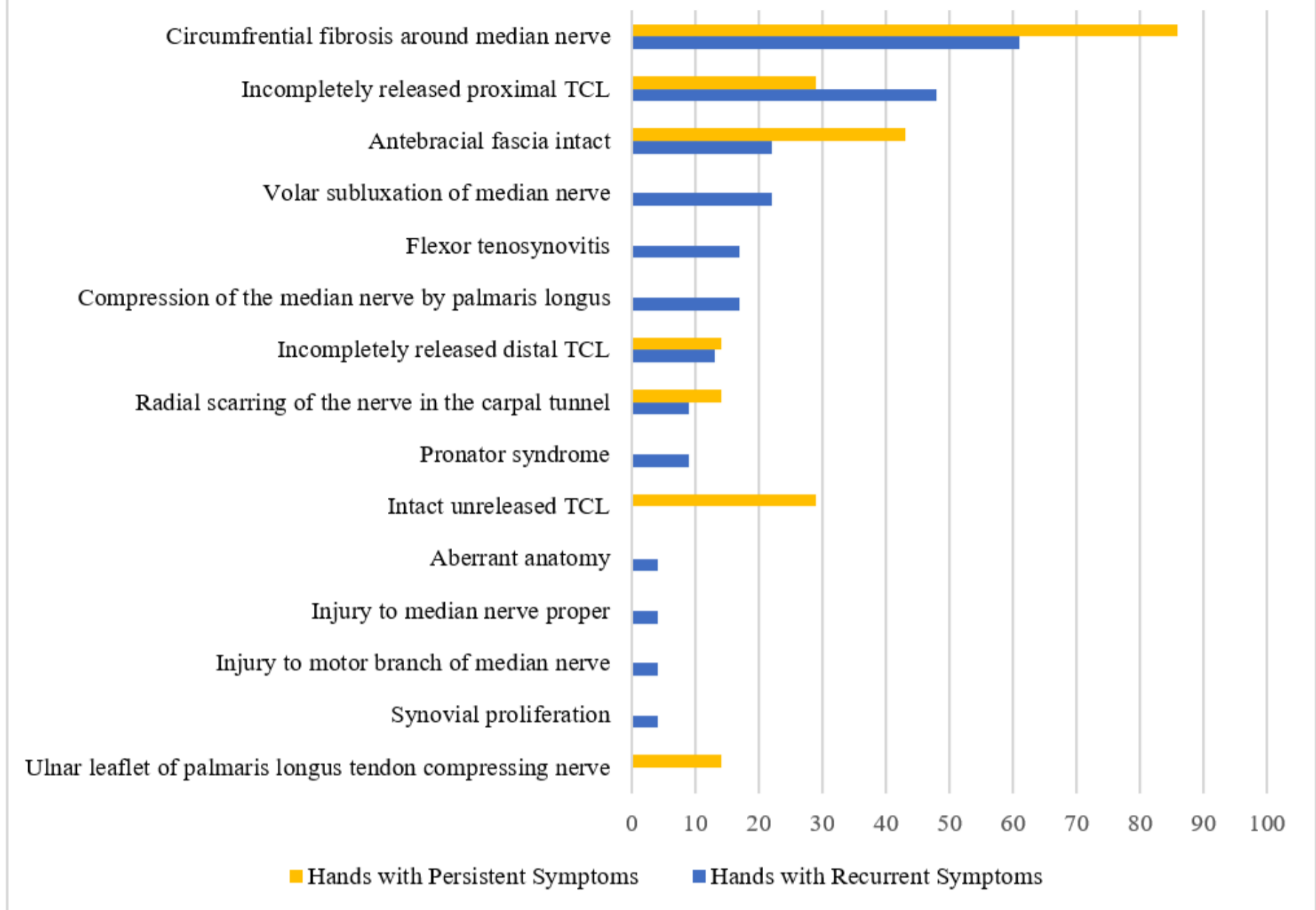


Figure 1: Intraoperative findings during revision carpal tunnel release: yellow bars represent the percentage of hands with persistent carpal tunnel symptoms with the corresponding findings; blue bars represent the percentage of hands with recurrent carpal tunnel symptoms in this study with the corresponding findings. TCL, transverse carpal ligament.

Other intraoperative findings included circumferential fibrosis of the median nerve within the carpal tunnel in 20 cases (67%), intact antebrachial fascia in 8 cases (27%), volar subluxation of the median nerve in 5 cases (17%), compression of the median nerve by palmaris longus in 4 cases (13%), flexor tenosynovitis in 4 cases, and 1 case of aberrant anatomy involving an aberrant branch of the palmar cutaneous branch of the median nerve, which was found to be compressed and released during the revision.

Hands that experienced persistent carpal tunnel syndrome following index release had a distribution of intraoperative findings that was similar to that of the recurrent group. However, a greater percentage of these hands were found to have a completely intact and unreleased TCL compared with the recurrent group (29% vs 0%, respectively). Conversely, all of the hands that were found to have a completely intact and unreleased TCL had persistent symptoms.

Nine patients (34%) had complete resolution of symptoms after the revision carpal tunnel release. Fifteen patients (58%) had improvement in symptoms, and 2 patients did not report improvement (**Figure 2**). Twenty-four (92.3%) had either complete resolution or improvement in symptoms. Overall, APB strength was improved in all but 1 patient who had pre-revision APB weakness. No patients required a third operation. There was no significant age difference between those who experienced improvement and those who did not improve following revision (average age, 55 vs 56 years).

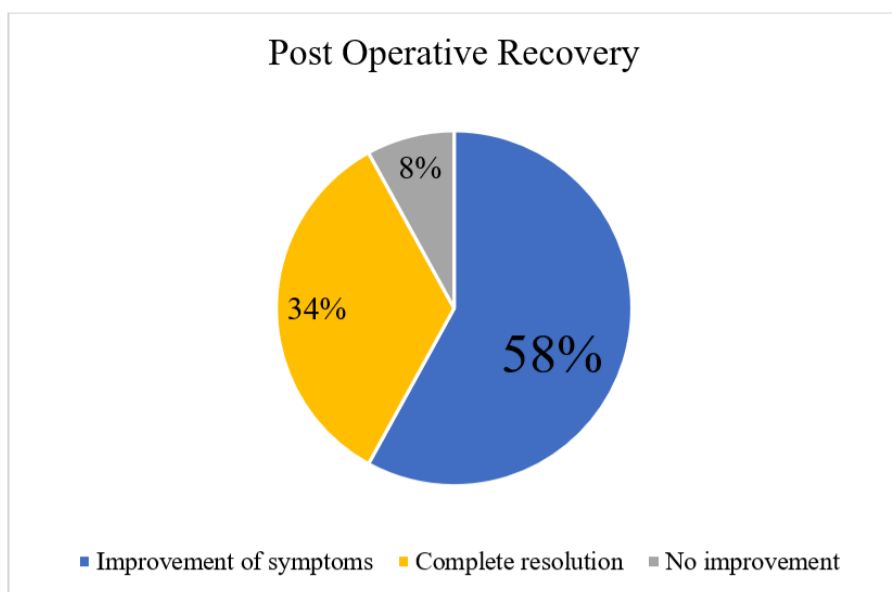


Figure 2: Postoperative recovery 1 year following revision carpal tunnel release, based upon subjective patient report.

Discussion

Recurrent carpal tunnel syndrome has been reported in 7% to 20% of cases following primary carpal tunnel release.^{6,7} Diagnosis of such patients remains clinically founded. As noted previously and presently in the current study, we have found that Phalen sign, comparison of the strength of the APB muscle, and subjective "splitting" of the ring finger sensation to be the most helpful findings in establishing the diagnosis. Additionally, importance must be placed upon a missed diagnosis from the previous clinical encounter, such as a double crush syndrome involving a more proximal site of compression. We identified 2 cases (6.6%) of pronator syndrome in 2 of the patients with recurrent carpal tunnel symptoms in our series. Indeed, Hsiao et al had identified 6% (21 out of 343) of their total identified cases of primary carpal tunnel syndrome as having pronator syndrome.⁸ This confirms that double-crush syndrome is a significant contributing factor in median nerve compression symptoms and should be considered in the differential when evaluating a patient with recurrent or persistent carpal tunnel syndrome.

Although emphasis must be placed on the clinical presentation and examination of the patient, diagnosis of recurrent or persistent carpal tunnel syndrome can be confirmed with adjunctive studies. The utility of electrodiagnostic confirmation has been studied in cases of primary carpal tunnel syndrome, and this test is associated with a sensitivity ranging from 56% to 85% and a specificity of at least 94%.⁹ However, there is currently a deficiency of literature regarding its use in recurrent and persistent cases. In the current study, we found that electrodiagnostic tests had a positive predictive value, at best, of only 59% (using distal motor latency delay). High-resolution ultrasound and its visualization of the cross-sectional area of the median nerve has also been studied in cases of recurrent carpal tunnel syndrome; Duetzmann et al reported that a cutoff cross-sectional area of 14.5 mm² produced a sensitivity and specificity of 78% and 97%, respectively, in diagnosing recurrent or persistent symptoms in cases with clinically apparent symptoms.¹⁰

When an agreement is made between the patient and surgeon to proceed with revision surgery, careful consideration of frequently encountered surgical findings is helpful for the surgeon prior to the revision release. Several studies have noted the most common intraoperative finding in such cases is incomplete release of the transverse carpal ligament followed by perineurial scarring.⁵⁻⁷ This is again confirmed with our current study population. Our less frequent findings included compression of the median nerve by the palmaris longus, compression of an aberrant branch of the palmar cutaneous nerve, compression of the median nerve by the ulnar leaflet of the palmaris longus tendon, and direct injury to the median nerve itself or the recurrent motor branch. Other less frequent findings in the literature have included aberrant flexor digitorum muscle belly extensions into the carpal tunnel, which often benefit from careful debulking of the muscle bellies.¹¹

In our study population, there was a greater percentage of hands that had an incompletely released proximal TCL compared with distal TCL, which is consistent with the current literature. Pacek et al¹² studied the flexor retinaculum of human cadaver forearms. It is difficult to establish standard lengths on any anatomic entity along the flexor retinaculum; however, they found the lengths along the radial, midline, and ulnar portions of the TCL to be 16.5 ± 2.0 mm, 14.4 ± 1.9 mm, and 15.1 ± 2.6 mm, respectively,¹² which seems shorter in comparison to the total length of fascia and ligament that is released in a standard carpal tunnel release that we perform. Indeed, it is important to remember that the TCL is part of the expanse of the flexor retinaculum, a continuous layer of fascia that begins with the flexor forearm fascia, continues to the thinner antebrachial fascia and transitions to the TCL, finally ending at the distal aponeurosis. A complete decompression of the median nerve at the wrist should not only involve division of the transverse carpal ligament but also a complete release proximally (of the antebrachial fascia) and distally, until the fat pad of the superficial palmar arch is visualized.

In our series of patients, we noted that all patients who presented with persistent symptoms following index carpal tunnel release had some aspect of an incomplete release of the flexor retinaculum, whether it was the TCL or the antebrachial fascia. A higher percentage of these cases had a completely intact TCL compared with those who suffered recurrent

symptoms, 29% versus 0%, respectively. Additionally, all patients who had an intact TCL had persistent symptoms. This supports the finding that all patients with persistent carpal tunnel syndrome had improvement or complete resolution of symptoms; the revision surgery functioned to complete what was incomplete at the index surgery, essentially a delayed primary carpal tunnel release that would have been successful from the beginning had the full release been performed.

Many studies have described methods of revision neuroplasty using local muscle flaps, such as the pronator quadratus flap, fascial flaps, synovial flaps, fat grafts, or pedicled flaps to improve nerve gliding and prevent excessive scar tissue formation. Hutting et al described a fasciocutaneous dorsal ulnar artery flap, which when transposed over the tertiary revision carpal tunnel release, resulted in symptomatic relief for their patient.¹³ In our study, we used 7 ulnar-based synovial flaps, 2 adipofascial flaps based on the ulnar artery, and 1 technique of volar bolstering of the TCL using the palmaris longus tendon to prevent volar subluxation of the median nerve.

While the majority (92%) of our patients experienced improvement or complete resolution of symptoms, 2 (8%) of our patients had unresolved symptoms following revision release. Both cases suffered initially from recurrent symptoms, and both received index open carpal tunnel releases. Interestingly, while these 2 cases had complete release of the TCL and antebrachial fascia, both were found to have circumferential fibrosis of the median nerve at the time of revision release. This suggests that perineurial scarring and fibrosis, in the presence of a completely and correctly released TCL and antebrachial fascia, may be a predictor of failure of a revision release to improve symptoms.

Although our improvement rate following revision surgery is slightly higher than stated in the literature (between 41% and 90%¹⁴), it is important to reiterate that revision surgery is often difficult and complex with potentially disappointing results. Djerbi et al found that only 16 of 38 patients (68%) experienced excellent or good results at the latest follow-up, and only 11 of 38 (28%) reported their symptoms as "cured"; the remaining 27 patients experiencing residual pain, numbness, or disabilities of the hand.^{15,16} Strasberg et al¹⁴ found after a mean follow-up from the second carpal tunnel surgery of 31 months (range, 9-92 months), only 24 patients (53%) reported significant improvement in their symptoms; residual numbness, weakness, pain, and cold intolerance were reported in 74%, 72%, 62%, and 50% of patients, respectively. Unglaub et al¹⁷ experienced more favorable results, with 36 patients (94%) reporting nocturnal paresthesias as mild or completely resolved, and 35 patients (92%) reported that they never or only infrequently awoke during the night due to pain or numbness. Regarding the paresthesia, 76% of patients indicated that they were completely or sufficiently satisfied. Weakness, understandably, proved to be more difficult to correct, with 28% indicating strong or even very strong persistent symptoms of weakness, 23% with moderate weakness, and 44% with little or no reported weakness.

Conclusions

Recurrent carpal tunnel syndrome has been reported in up to 20% of cases. Although diagnosis is based clinically, adjunctive studies, such as electrodiagnostic testing and high-resolution ultrasound, have been used for confirmation. The most common intraoperative findings in such cases is incomplete release of the TCL, perineurial scarring, and incomplete release of the antebrachial fascia. Persistent carpal tunnel syndrome is almost always secondary to incomplete division of the TCL or the antebrachial fascia, and these cases almost always improve when the release is completed during the revision. However, in cases of recurrent carpal tunnel syndrome with an already released TCL and antebrachial fascia, the most likely culprit is perineurial fibrosis, which may portend nonresolution of symptoms following the revision release.

Acknowledgments

Authors: Quincy Jones, BS¹; Elise E. Hill, MD²; Andrew Li, MD³; Clifford Pereira, MD³; Dattesh Dave, MD³; Jerrick Robker, DO⁴; Neil F. Jones, MD⁵

Affiliations: ¹University of California Davis School of Medicine, Sacramento, California; ²University of California Davis Health System, Department of Surgery, Sacramento, California; ³University of California Davis Health System, Hand, Upper Extremity, and Microsurgery, Division of Plastic Surgery, Sacramento, California; ⁴Synergy Orthopedic Specialists, San Diego, California; ⁵Ronald Reagan UCLA Medical Center, Santa Monica, California.

Correspondence: Andrew Li, MD; adrli@ucdavis.edu

Ethics: This study was classified as exempt research posing minimal risk to subjects as determined by the University of California Irvine institutional review board.

Disclosures: The authors disclose no relevant financial or nonfinancial interests.

References

1. Dale A, Harrison-Adamson C, Rempel D, et al. Prevalence and incidence of carpal tunnel syndrome in US working populations: pooled analysis of six prospective studies. *Scand J Work Environ Health*. 2013 Sep 1;39(5):495-505. doi:10.5271/sjweh.3351
2. Papanicolaou G, MacCabe SJ, Firrell J. The prevalence and characteristics of nerve compression syndromes in the general population. *J Hand Surg Am*. 2001 May;26:460-466. doi:10.1053/jhsu.2001.24972
3. Louie D, Earp B, Blazar P. Long-term outcomes of carpal tunnel release: a critical review of the literature. *Hand (N Y)*. 2012;7(3):242-246. doi:10.1007/s11552-012-9429-x
4. Stutz N, Gohritz A, van Schoonhoven J, Lanz U. Revision surgery after carpal tunnel release – analysis of the pathology in 200 cases during a 2 year period. *J Hand Surg Br*. 2006 Feb;31(1):68-71. doi:10.1016/j.jhsb.2005.09.022
5. Jones NF, Hee A, Eo S. Revision surgery for persistent and recurrent carpal tunnel syndrome and for failed carpal tunnel release. *Plast Reconstr Surg*. 2012 Mar;129(3):683-692. doi:10.1097/PRS.0b013e3182402c37
6. Kulick MI, Gordillo G, Javidi T, Kilgore ES Jr, Newmayer WL III. Long-term analysis of patients having surgical treatment for carpal tunnel syndrome. *J Hand Surg Am*. 1986 Jan;11(1):59-66. doi:10.1016/s0363-5023(86)80104-6
7. Gelberman RH, Pfeffer GB, Galbraith RT, Szabo RM, Rydevik B, Dimick M. Results of treatment of severe carpal tunnel syndrome without internal neurolysis of the median nerve. *J Bone Joint Surg Am*. 1987 Jul;69(6):896-903.
8. Hsiao C, Shih J, Hung S. Concurrent carpal tunnel syndrome and pronator syndrome: a retrospective study of 21 cases. *Orthop Traumatol Surg Res*. 2017 Feb;103(1):101-103. doi:10.1016/j.otsr.2016.10.009.
9. Keith MW, Masear V, Chung K, et al. Diagnosis of carpal tunnel syndrome. *J Am Acad Orthop Surg*. 2009 Jun;17(6):389-396. doi:10.5435/00124635-200906000-00007
10. Duetzmann S, Suleyman T, Seifert V, et al. Cross-sectional area of the median nerve before revision carpal tunnel release—a cross-sectional study. *Oper Neurosurg (Hagerstown)*. 2018 Jan;14(1):20-25. doi:10.1093/ons/oxp079
11. Takata SC, Roll SC. Identification of aberrant muscle bellies in the carpal tunnel using sonography. *J Diagn Med Sonogr*. 2019 Jan;35(1):62-68. doi: 10.1177/8756479318807469
12. Pacek CA, Chakan M, Goitz R, Kaufmann RA, Li Z-M. Morphological analysis of the transverse carpal ligament. *Hand (N Y)*. 2010 Jun;5(2):135-140. doi:10.1007/s11552-009-9219-2
13. Hutting KH, van Uchelen JH. Treatment of recurrent and persistent carpal tunnel syndrome: the fasciocutaneous dorsal ulnar artery flap. *J Hand Surg Am*. 2018 Jul;43(7):686.e1-686.e5. doi:10.1016/j.jhsa.2018.03.006
14. Strasberg S, Novak C, Mackinnon S, et al. Subjective and employment outcome following secondary carpal tunnel surgery. *Ann Plast Surg*. 1994 May;32(5):485-489. doi:10.1097/00000637-199405000-00008
15. Soltani AM, Allan BJ, Best MJ, Mir HS, Panthaki ZJ. A systematic review of the literature on the outcomes of treatment for recurrent and persistent carpal tunnel syndrome. *Plast Reconstr Surg*. 2013 Jul;132(1):114-121. doi:10.1097/PRS.0b013e318290faba
16. Evans GR, Dellon AL. Implantation of the palmar cutaneous branch of the median nerve into the pronator quadratus for treatment of painful neuroma. *J Hand Surg Am*. 1994 Mar;19(2):203-206. doi:10.1016/0363-5023(94)90006-x
17. Unglaub F, Wolf E, Goldbach C, Hahn P, et al. Subjective and functional outcome after revision surgery in carpal tunnel syndrome. *Arch Orthop Trauma Surg*. 2008 Sep;128(9):931-936. doi:10.1007/s00402-007-0451-3

