

UC Davis

Dermatology Online Journal

Title

Repair of adjacent defects on the nasal dorsum and nasal sidewall

Permalink

<https://escholarship.org/uc/item/8t195690>

Journal

Dermatology Online Journal, 31(1)

Authors

Levin, Adam

Zahir, Amir

Fakhoury, Tamara

et al.

Publication Date

2025

DOI

10.5070/D331164975

Copyright Information

Copyright 2025 by the author(s). This work is made available under the terms of a Creative Commons Attribution-NonCommercial-NoDerivatives License, available at

<https://creativecommons.org/licenses/by-nc-nd/4.0/>

Peer reviewed

Repair of adjacent defects on the nasal dorsum and nasal sidewall

Adam Levin¹⁻³ DO, Amir Zahir¹⁻³ MD, Tamara Fakhoury DO, David Kouba¹⁻³ MD PhD

Affiliations: ¹The Toledo Clinic, Lambertville, Michigan, USA, ²Toledo Clinic Facial Plastics and Dermatology, Toledo, Ohio, USA, ³Wayne State University, Detroit, Michigan, USA

Corresponding Author: Tamara Fakhoury, 2001 Kingsley Ave, Orange Park, FL 32073, Tel: 561-843-8578, Email: fakhourytamara@gmail.com

Keywords: aesthetic, Burrow's, flaps, Mohs, nasal, reconstruction, surgery

To the Editor:

A 63-year-old man underwent Mohs micrographic surgery for basal cell carcinoma on his left nasal sidewall and squamous cell carcinoma on his nasal dorsum, resulting in significant defects. Our case introduces a novel approach using Burrow triangles to incorporate two advancement flaps into one repair, addressing both defects simultaneously.

Mohs micrographic surgery is renowned for its efficacy in eradicating cancer cells while preserving healthy tissue, particularly critical in cosmetically sensitive areas like the nose [1]. The anatomical subunits of the nose present unique challenges in reconstruction. Keeping incision lines at the borders of these subunits enhances aesthetic outcomes [2]. The Burrow triangle technique described distributes tension in a horizontal direction without altering nasal shape while also hiding incision lines along nasal creases. Two separate repairs could be performed, but doing so would increase overall scar length and increase the likelihood of crossing cosmetic subunits. The nasal sidewall, dorsum, columella, and soft triangles typically have thin and loose skin. The tip, supratip, and ala usually have thicker, more rigid and sebaceous features [3]. Therefore, caution must be taken when designing flaps to ensure that the repair utilizes similar skin to that which was present at the site before the defect

occurred.

In our case, the defects on the nasal dorsum and sidewall posed challenges related to their proximity and limited tissue reservoir. Three Mohs stages were performed to clear the tumor from each site. This resulted in a 2.0cm x 1.7cm defect and a 1.0cm x 1.0cm defect on the left nasal sidewall and nasal dorsum, respectively (**Figure 1A**). An incision was made connecting the base of nasal dorsum defect to the apex of the defect on the left nasal sidewall. Another Burrow triangle located on the medial cheek along the alar groove and proximal nasolabial fold was removed (**Figure 1B**). Skin from the medial cheek was advanced to close the wound on the nasal sidewall (**Figure 1C**). Lastly, 6-0 plain gut was used to evert the wound edges. As a result of attempting to camouflage incision lines in the nasofacial sulcus and alar groove, the wound healed successfully (**Figure 1D, E**). Potential complications include postoperative bleeding, infection, or necrosis. Larger defects such as in the presented case, require lower lid elasticity testing to determine the risk of ectropion. However, given the horizontal motion of the flap the risk for ectropion remains low.

In conclusion, our case underscores the efficacy of utilizing the Burrow triangle technique in Mohs micrographic surgery. For nasal reconstruction, this technique is ideal for defects that measure up to 2cm

and are both located above the alar crease. Yet, it remains applicable for alternative surgical areas when traditional repair options, such as primary closure, flaps, or grafts, are insufficient because of factors such as limited tissue availability, defect size, or location. This approach offers a valuable tool for addressing complex nasal defects, emphasizing the importance of precision and creativity in achieving optimal outcomes for patients.

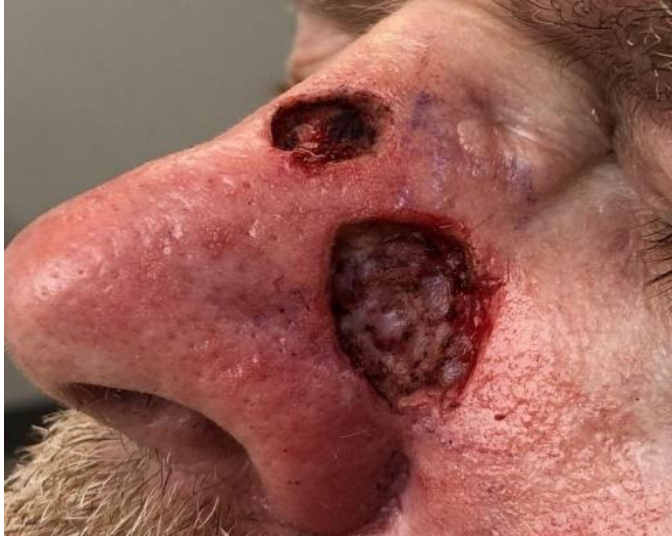

Figure 1. A) Evolution of nasal repair utilizing the Burrow triangle technique. Initial defect following resection with Mohs surgery, highlighting the extent of tissue removal.

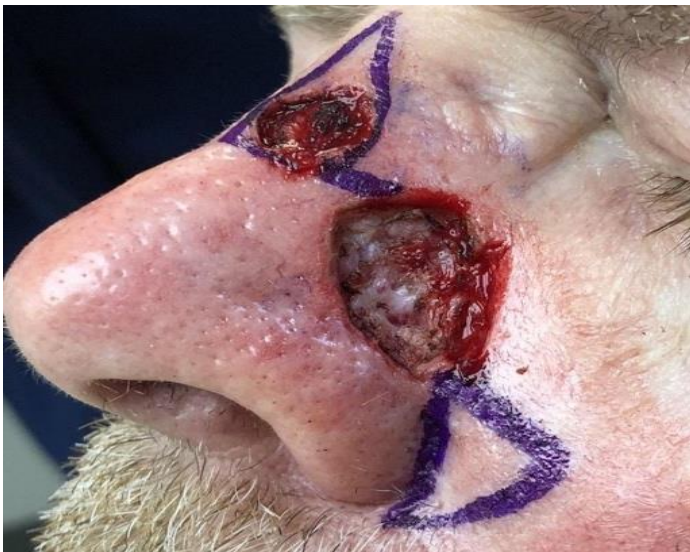

Figure 1. B) Application of the Burrow triangle technique to bridge and connect the two nasal defects, facilitating reconstruction.

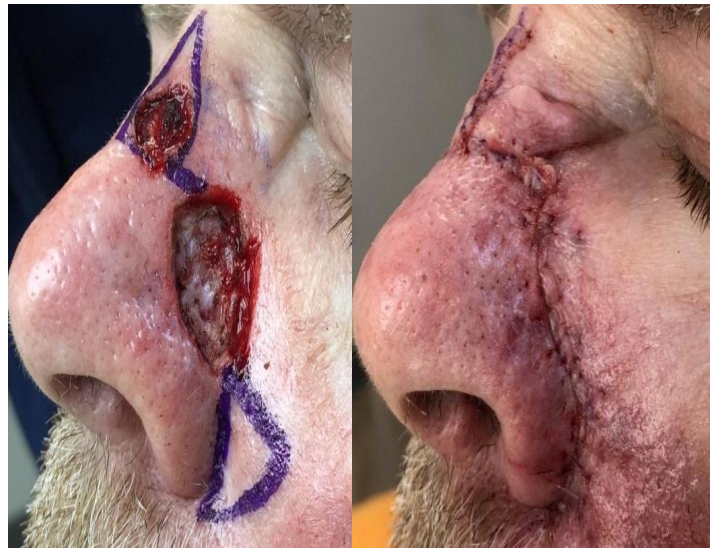

Figure 1. C) Closure of the nasal defects ensuring proper alignment and symmetry.

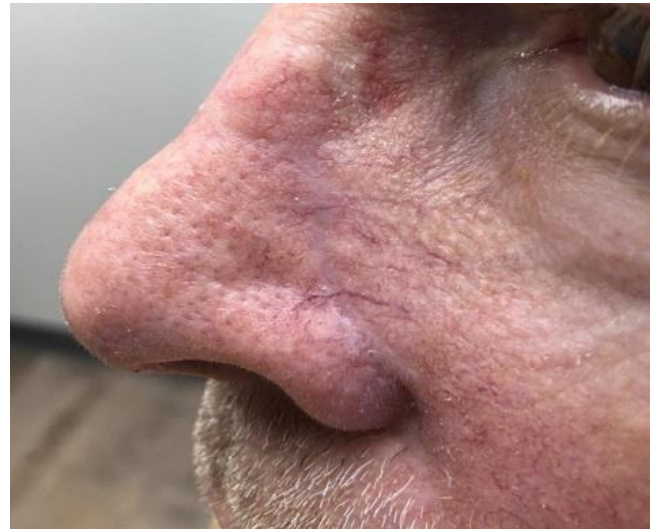

Figure 1. D) Final outcome of nasal repair, demonstrating no lower eyelid ectropion, satisfactory cosmetic appearance, and functional restoration.

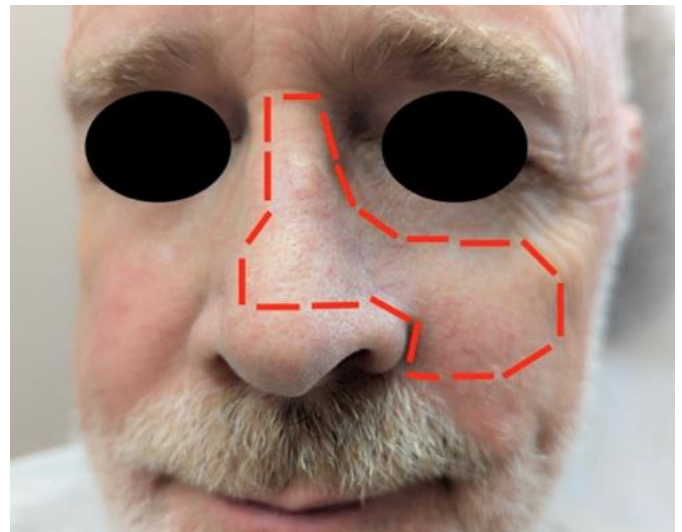


Figure 1. E) Final outcome of nasal repair, demonstrating no lower eyelid ectropion, satisfactory cosmetic appearance, and functional restoration.

lower eyelid ectropion, satisfactory cosmetic appearance, and functional restoration.

Potential conflicts of interest

The authors declare no conflicts of interest.

References

1. Bittner GC, Cerci FB, Kubo EM, Tolkachjov SN. Mohs micrographic surgery: A review of indications, technique, outcomes, and considerations. *An Bras Dermatol.* 2021;96:263-277. [PMID: 33849752].
2. Cerci FB. Usefulness of the subunit principle in nasal reconstruction. *An Bras Dermatol.* 2017;92:159-162. [PMID: 29267479].
3. Baker, SR. Local Flaps in Facial Reconstruction 4th Edition. Elsevier; 4th edition. 2022. p. 399-401.