

## **UC Irvine**

### **Western Journal of Emergency Medicine: Integrating Emergency Care with Population Health**

#### **Title**

Tracheal-Mediastinal Fistula Post-chemoradiation Therapy

#### **Permalink**

<https://escholarship.org/uc/item/8sq099nn>

#### **Journal**

Western Journal of Emergency Medicine: Integrating Emergency Care with Population Health, 15(7)

#### **ISSN**

1936-900X

#### **Authors**

McCarthy, Joseph  
Hamel, Jason

#### **Publication Date**

2014

#### **DOI**

10.5811/westjem.2014.8.23438

#### **Copyright Information**

Copyright 2014 by the author(s). This work is made available under the terms of a Creative Commons Attribution-NonCommercial License, available at <https://creativecommons.org/licenses/by-nc/4.0/>

Peer reviewed

# Tracheal-Mediastinal Fistula Post-chemoradiation Therapy

Joseph McCarthy, DO  
Jason Hamel, MD

Lakeland Regional Medical Center, Department of Emergency Medicine, St. Joseph, Michigan

Supervising Section Editor: Sean O. Henderson, MD

Submission history: Submitted August 6, 2014; Accepted August 28, 2014

Electronically published October 14, 2014

Full text available through open access at [http://escholarship.org/uc/uciem\\_westjem](http://escholarship.org/uc/uciem_westjem)

DOI: 10.5811/westjem.2014.8.23438

[West J Emerg Med. 2014;15(7):876–877.]

## INTRODUCTION

A 52-year-old male presented to the emergency department with chest pain, shortness of breath and hemoptysis that had been worsening over the past two days. Past medical history included a history of non-small cell lung carcinoma, which he had completed radiation therapy approximately four months prior and was currently undergoing chemotherapy. Significant vitals upon presentation included a respiration rate of thirty-six breaths/min and peripheral oxygen saturation measuring 80%. Physical examination revealed a cachectic male appearing older than his actual age, alert and oriented to person, place and time with rhonchi throughout his lung fields and decreased breath sounds on the right. He was started on non-invasive biphasic positive airway pressure with mild improvement of clinical status. An anteriorposterior chest radiograph was performed and prior computed tomography of the chest was reviewed (Figures 1, 2). Computed tomography of the chest was also repeated on the day of presentation (Figure 3).

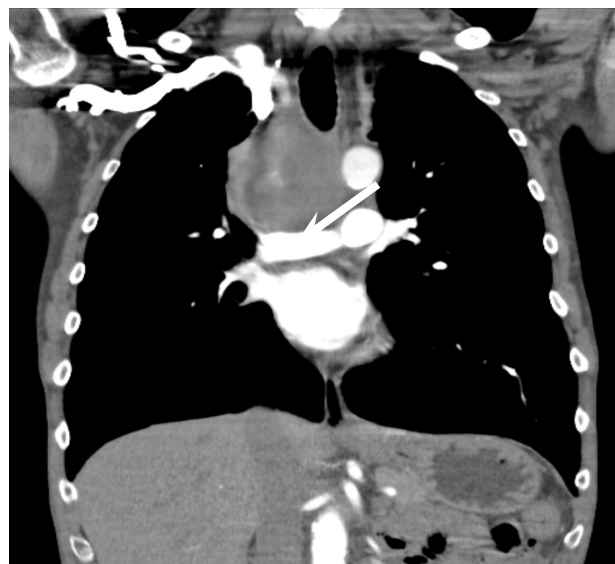

Figure 2. Coronal computed tomography of paratracheal mass with right anterolateral tracheal involvement.

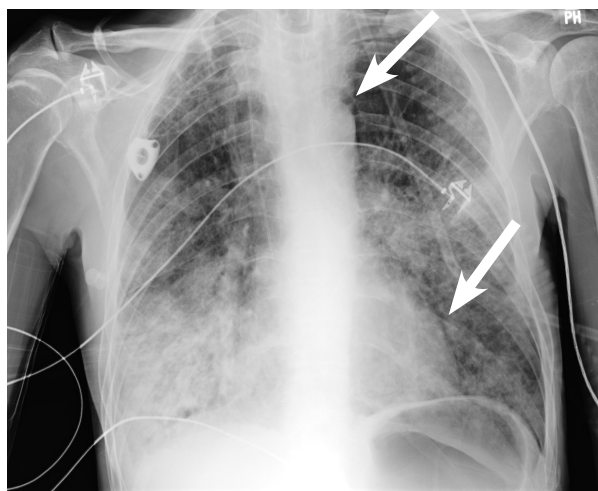


Figure 1. Anteriorposterior chest radiograph displaying lucency adjacent to the aortic knob (arrow) and left cardiac border (arrowhead) consistent with pneumomediastinum.

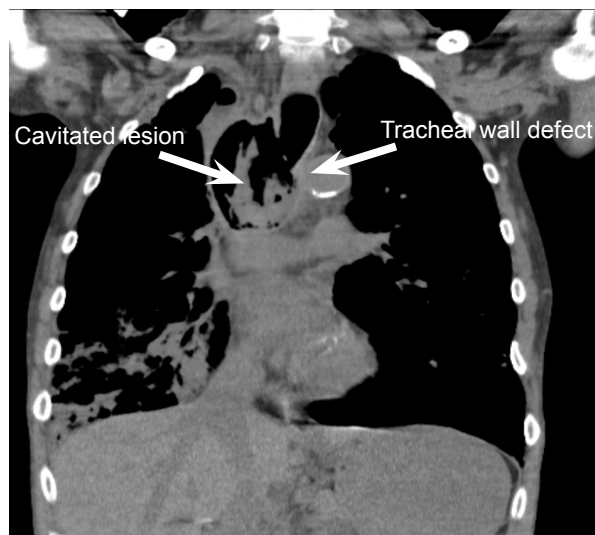


Figure 3. Coronal computed tomography exhibiting a deficit in the right tracheal wall with a cavitary space previously occupied by the large soft tissue mass seen in Figure 2.

## DISCUSSION

There are reports of high incidences of tracheoesophageal fistula formation in patients being treated for lung cancers with the combination of radiation therapy and chemotherapies, notably bevacizumab,<sup>1</sup> but tracheal-mediastinal fistulas are rare.<sup>2</sup> Patient's presentation can vary from acute tension pneumothorax and asphyxiation from pulmonary flooding secondary to hemorrhage, to insidious wasting, malaise, fever, or chronic cough.<sup>3</sup> Acquired fistulas of the tracheobronchial airways are associated with high rates of morbidity and mortality, with many patients dying from hemorrhage resulting from progression of the fistula into the blood vessels.<sup>2</sup> Emergent intubation is often required with the understanding that this may cause or worsen hemoptysis leading to possible cardiovascular and respiratory failure. There is lack of consensus for optimal definitive therapy, but options include open surgery, bronchoscopically placed expandable stents, fibrin glue, and even autologous adipose-derived stem cells.<sup>2,3</sup>

After discussion with the patient and family regarding the diagnosis, he preferred not to be intubated and requested only supportive care. He was admitted to the hospital on biphasic non-invasive positive airway pressure and expired from respiratory failure shortly thereafter.

---

*Address for Correspondence:* Joseph McCarthy, DO. Lakeland Regional Medical Center Emergency Medicine Residency Program, 1234 Napier Avenue, St. Joseph, MI 49085. Email: jmccarthy@lakelandregional.org.

---

*Conflicts of Interest:* By the WestJEM article submission agreement, all authors are required to disclose all affiliations, funding sources and financial or management relationships that could be perceived as potential sources of bias. The authors disclosed none.

## REFERENCES

1. Spigel, DR, Hainsworth, JD, Yardley, DA, et al. Tracheoesophageal fistula formation in patients with lung cancer treated with chemoradiation and bevacizumab. *J of Clinical Oncology*. 2010;28(1):43-48.
2. Diaz-Agero Alvarez P, Garcia-Arranz M, Georgiev-Hristov T, et al. A new bronchoscopic treatment of tracheomediastinal fistula using autologous adipose-derived stem cells. *Thorax*. 2008;63:374-376.
3. Lois M, Noppen M. Bronchopleural Fistulas: An overview of the problem with special focus on endoscopic management. *Chest*. 2005;128(6):3955-3965.