

# UC Irvine

## Clinical Practice and Cases in Emergency Medicine

### Title

Gastric Outlet Obstruction as a Result of an Inguinal Hernia

### Permalink

<https://escholarship.org/uc/item/8sc6j07f>

### Journal

Clinical Practice and Cases in Emergency Medicine, 0(0)

### Authors

Wohlford, Luke

Bounds, Rich

### Publication Date

2025-01-19

### DOI

10.5811/cpcem.35395

### Copyright Information

This work is made available under the terms of a Creative Commons Attribution License, available at <https://creativecommons.org/licenses/by/4.0/>

Peer reviewed

## Gastric Outlet Obstruction as a Result of an Inguinal Hernia

Luke Wohlford, MD  
Richard Bounds, MD

The University of Vermont Medical Center, Department of Emergency Medicine,  
Burlington, Vermont

Section Editor: Steven Walsh, MD

Submission history: Submitted October 15, 2024; Revision received December 14, 2024; Accepted December 16, 2024

Electronically published January 19, 2025

Full text available through open access at [http://escholarship.org/uc/uciem\\_cpccem](http://escholarship.org/uc/uciem_cpccem)

DOI: 10.5811/cpccem.35395

**Case Presentation:** We present a case of a 79-year-old male with gastric outlet obstruction resulting from a stomach herniation through a large left inguinal hernia.

**Discussion:** Stomach-containing inguinal hernias are a rare cause of gastric outlet obstruction. Treatment options range from conservative to surgical management. Once identified with imaging, prompt treatment should be initiated to prevent incarceration, strangulation, and gastric necrosis. [Clin Pract Cases Emerg Med. 2025;X(X):X–X.]

**Keywords:** *gastric outlet obstruction; inguinal hernia.*

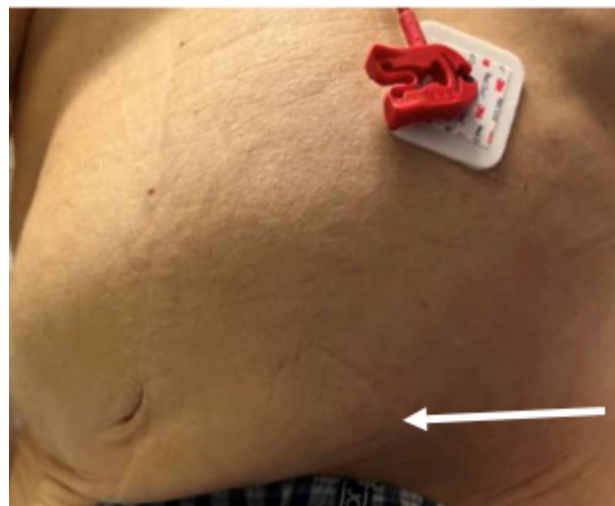### CASE PRESENTATION

A 79-year-old male with a left inguinoscrotal hernia and aortic stenosis presented to the emergency department with an acute syncopal episode. The patient attributed his own weakness and passing out to poor oral intake and abdominal pain for three days. He noted a left inguinal bulge that had never bothered him previously. The gastrointestinal symptoms had improved the day prior to the patient's syncopal episode, but he started to feel palpitations and generally weaker on the day of presentation. He had no prior surgeries for the inguinal hernia, which had no previous complications.

On examination, vital signs included blood pressure of 123/82 millimeters of mercury, pulse rate 141 and irregularly irregular, respiratory rate 16 breaths per minute, and temperature 36.8° Celsius. The abdominal exam demonstrated a distended but non-tender abdomen, with a palpable left inguinal mass (Image 1). Further workup with computed tomography demonstrated a large and distended stomach with extension of the distal portion including the pylorus into the inguinal hernia (Images 2 and 3).

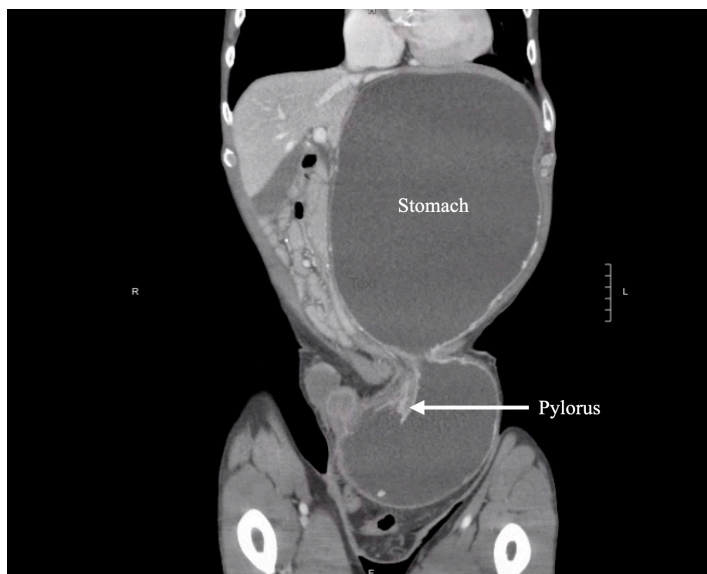
### DISCUSSION

Incarceration of a portion of the stomach is a rare cause of gastric outlet obstruction, with fewer than 20 cases documented in the literature.<sup>1</sup> The rarity of stomach-containing groin hernias is remarkable, considering that the lifetime incidence of groin hernias is estimated to be between 27-43% for men and 3-6% for women.<sup>2</sup> The inferior portion of the stomach attaches to

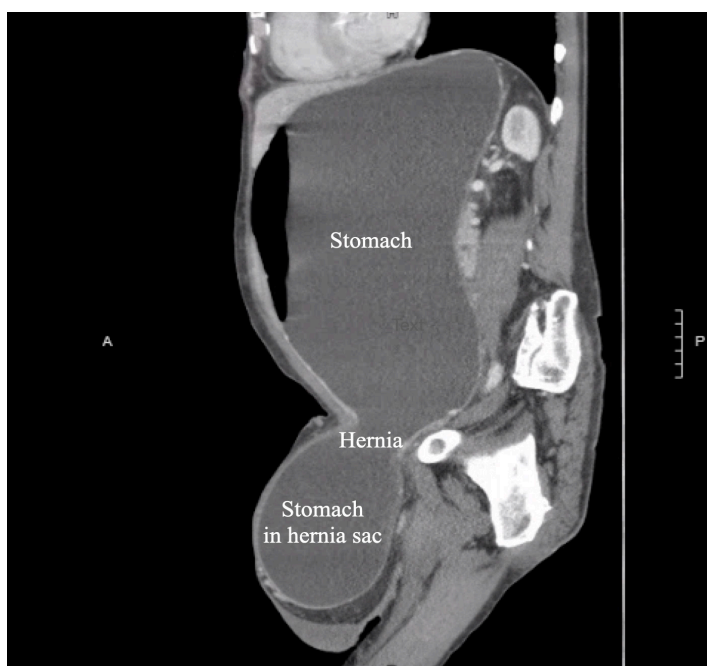


**Image 1.** Physical examination demonstrating a grossly distended and palpable left inguinal mass (white arrow)

the omentum by the gastrocolic ligament, making it vulnerable to herniation through particularly large and chronic inguinal hernias.<sup>3</sup> Acquired inguinal hernias are typically direct, resulting from the chronic pressure of a hernia sac just medial to the inferior epigastric vessels.<sup>4</sup> Less common than direct hernias, but seen in our patient, is the acquired, indirect hernia protruding lateral to the inferior epigastric vessels, which travels through the inguinal canal and often extends into the scrotum. Nasogastric



**Image 2.** Computed tomography with coronal images demonstrating a stomach-containing inguinal hernia including the pylorus.



**Image 3.** Computed tomography with sagittal images demonstrating a large and distended stomach partially in an inguinal hernia.

tube placement may adequately relieve the most severe symptoms, which can be followed by operative hernia repair, or even percutaneous endoscopic gastrostomy tube placement.<sup>5</sup> Physicians should be aware of the ability of the stomach to herniate into large inguinal hernia defects and act promptly to avoid incarceration, strangulation, and stomach necrosis.

Patient consent has been obtained and filed for the publication of this case report.

### *CPC-EM Capsule*

What do we already know about this clinical entity?

*Stomach-containing inguinal hernias are rare and can potentially lead to gastric outlet obstruction if left untreated.*

What is the major impact of the image(s)?

*The computed tomography images depict herniation of the stomach through the inguinal canal, including the gastric antrum, demonstrating a unique cause of gastric outlet obstruction.*

How might this improve emergency medicine practice?

*This case highlights the importance of thorough physical examination and consideration of imaging to prevent serious, hernia-related complications.*

**Address for Correspondence:** Luke Wohlford, MD, The University of Vermont Medical Center, Department of Emergency Medicine, 111 Colchester Ave, Burlington, VT, 05401. Email: luke.wohlford@uvmhealth.org.

**Conflicts of Interest:** By the CPC-EM article submission agreement, all authors are required to disclose all affiliations, funding sources and financial or management relationships that could be perceived as potential sources of bias. The authors disclosed none.

**Copyright:** © 2025 Wohlford et al. This is an open access article distributed in accordance with the terms of the Creative Commons Attribution (CC BY 4.0) License. See: <http://creativecommons.org/licenses/by/4.0/>

### REFERENCES

1. Favela JG, Argo MB, McAllister J, et al. Gastric outlet obstruction from stomach-containing groin hernias: case report and a systematic review. *J Clin Med.* 2023;13(1):155.
2. HerniaSurge Group. International guidelines for groin hernia management. *Hernia.* 2018;22(1):1-165.
3. Grantham TA, Ramachandran R, Parvataneni S, et al. Stomach within a large inguinal hernia. *Cureus.* 2022;14(5):e24783.
4. Morrison Z, Kashyap S, Nirujogi VL. Adult inguinal hernia. In: StatPearls. Treasure Island, FL: StatPearls Publishing. 2023. Available at: <https://www.ncbi.nlm.nih.gov/books/NBK537241/>. Accessed October 15, 2024.
5. Blair SM, Cournoyer RM, Newcomb MR, et al. Novel treatment of gastric outlet obstruction secondary to incarcerated inguinal hernia: percutaneous endoscopic gastrostomy tube. *J Surg Case Rep.* 2023;2023(6):rjad294.