

UC Irvine

UC Irvine Previously Published Works

Title

Thick Heart, Wide QRS, Broad Differential.

Permalink

<https://escholarship.org/uc/item/8r5110f7>

Journal

JACC: Case Reports, 3(11)

Authors

Howell, Stacey

Nazer, Babak

Publication Date

2021-09-01

DOI

10.1016/j.jaccas.2021.06.021

Peer reviewed

ECG TEACHING COMPETITION

INTERMEDIATE

IMAGING VIGNETTE: ECG CHALLENGE

Thick Heart, Wide QRS, Broad Differential



Stacey J. Howell, MD,^a Babak Nazer, MD^b

ABSTRACT

Routine electrocardiogram in a middle-aged man with left ventricular hypertrophy showed sinus rhythm, a short PR interval, and delta wave, confirming ventricular pre-excitation. Pre-excitation was fixed after a premature atrial complex and in atrial fibrillation, features diagnostic of a fasciculo-ventricular pathway. Genetic testing confirmed a diagnosis of hypertrophic cardiomyopathy. (**Level of Difficulty: Intermediate.**) (J Am Coll Cardiol Case Rep 2021;3:1363-1366)

© 2021 The Authors. Published by Elsevier on behalf of the American College of Cardiology Foundation. This is an open access article under the CC BY-NC-ND license (<http://creativecommons.org/licenses/by-nc-nd/4.0/>).

CASE

A 51-year-old man with severe left ventricular hypertrophy (LVH) was referred to cardiology clinic. Aside from palpitations, he was asymptomatic. He had no known family history of cardiomyopathy, arrhythmia, or sudden cardiac death. **Figure 1** demonstrates his baseline electrocardiogram (ECG) (**Figure 1A**) and ECG in tachycardia (**Figure 1B**).

WHAT IS THE DIAGNOSIS?

- A. Hypertrophic cardiomyopathy (HCM) with left bundle branch block
- B. Danon disease with right anterolateral atrio-ventricular accessory pathway (AP)
- C. Fabry disease with ventricular tachycardia
- D. HCM with a fasciculo-ventricular AP
- E. PRKAG2 mutation with a right anterolateral atrio-ventricular AP

The correct answer is D.

EXPLANATION

Baseline ECG shows sinus rhythm and a wide QRS complex with left bundle branch block-type morphology. A short PR interval and delta wave are present, confirming ventricular pre-excitation and excluding aberrant conduction (excludes answer A). The QRS precordial transition at V₄ and positive delta wave frontal axis localize the accessory pathway (AP) to the anterolateral right ventricle (1). However, 2 additional electrocardiographic clues are important to note. In **Figure 1A**, pre-excitation is fixed after a premature atrial complex (PAC). In **Figure 1B**, the patient is in atrial fibrillation (AF) (excludes answer C). Despite varying RR intervals, pre-excitation is fixed with the same pre-excited QRS morphology as in the sinus ECG.

From the ^aUniversity of California-San Francisco, San Francisco, California, USA; and the ^bKnight Cardiovascular Institute, Oregon Health and Science University, Portland, Oregon, USA.

The authors attest they are in compliance with human studies committees and animal welfare regulations of the authors' institutions and Food and Drug Administration guidelines, including patient consent where appropriate. For more information, visit the [Author Center](#).

Manuscript received April 16, 2021; revised manuscript received May 25, 2021, accepted June 1, 2021.

ABBREVIATIONS AND ACRONYMS

AF = atrial fibrillation

AP = accessory pathway

AVN = AV node

FVP = fasciculo-ventricular
pathway

HCM = hypertrophic
cardiomyopathy

LVH = left ventricular
hypertrophy

PAC = premature atrial
contraction

Fixed pre-excitation in the setting of a PAC and AF with varying RR intervals is a diagnostic feature of a fasciculo-ventricular pathway (FVP). FVPs are infranodal connections between a bundle branch and the ventricular myocardium. **Figure 1C** shows the effect of a PAC on pre-excitation in the setting of a typical atrioventricular AP and an FVP. Typical atrioventricular APs have different refractory periods than those of the AV node (AVN). Thus, a PAC will encounter either a more refractory AVN, resulting in greater pre-excitation, or a more refractory AP, resulting in less or no pre-excitation. On the other hand, an FVP is infranodal. Hence, a PAC will conduct through the AVN unchanged and will not affect the degree of pre-excitation as seen in the current patient. Similarly, AF would have conducted variably down the AV node and typical atrioventricular AP, resulting in beat-to-beat variations in QRS morphology and degree of pre-excitation (excludes answers B and E) but fixed pre-excitation in AF with an FVP (correct answer is D).

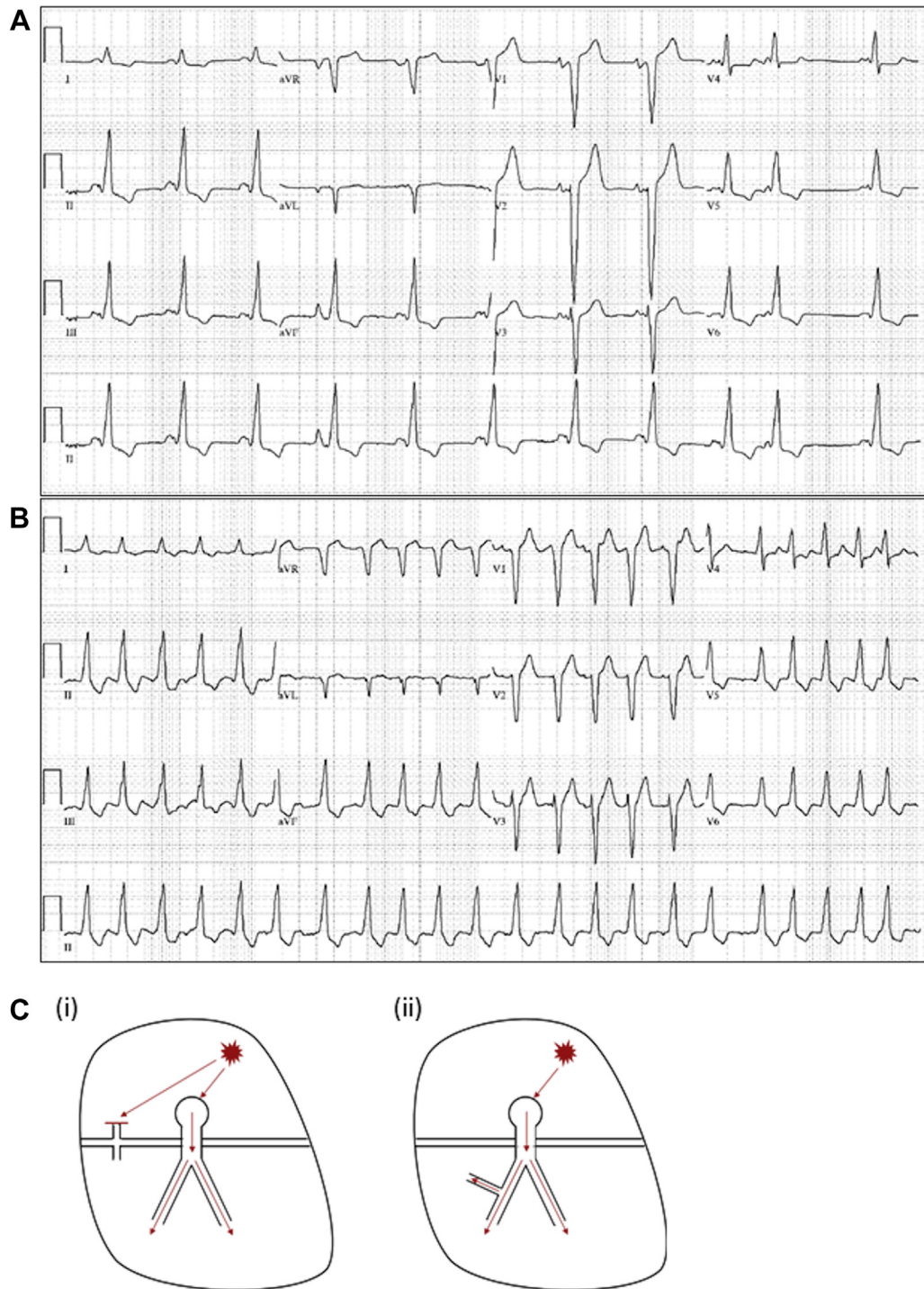
The clinical picture of LVH and pre-excitation raises suspicion for familial forms of pre-excitation associated with LVH which include mutation in the *PRKAG2* gene, Danon disease, and Fabry disease, among others (2). Initially there was high suspicion for the *PRKAG2* mutation because APs are prevalent in this disease and because the referring institution had diagnosed this patient as carrying the *PRKAG2* mutation prior to referral. However, repeated genetic testing at the authors' institution identified a pathogenic variant in myosin essential light chain 3 (MYL3), confirming a diagnosis of HCM.

The *PRKAG2* mutation disease is rare, resulting from mutations in adenosine monophosphate-activated protein kinase, which regulates glucose and fatty acid metabolism (3). Manifestations include LVH, ventricular pre-excitation, atrial tachyarrhythmias, bradycardia, and conduction disease (3). Danon and Fabry diseases have similar clinical pictures, however, both commonly have extracardiac features not present in the current patient (2).

FUNDING SUPPORT AND AUTHOR DISCLOSURES

The authors have reported that they have no relationships relevant to the contents of this paper to disclose.

FIGURE 1 Electrocardiography



(A) Baseline electrocardiography. (B) electrocardiography in tachycardia. (C) The effect of a premature atrial contraction on pre-excitation in the setting of a (i) typical atrioventricular bypass tract and (ii) fasciculo-ventricular bypass tract.

ADDRESS FOR CORRESPONDENCE: Dr. Stacey J. Howell, University of California-San Francisco, 500 Parnassus Avenue, San Francisco, California 94143, USA. E-mail: stacey.howell@ucsf.edu. Twitter: [@StaceyHowellMD](https://twitter.com/StaceyHowellMD), [@B_Naz_MD](https://twitter.com/B_Naz_MD).

REFERENCES

1. Fitzpatrick AP, Gonzales RP, Lesh MD, Modin GW, Lee RJ, Scheinman MM. New algorithm for the localization of accessory atrioventricular connections using a baseline electrocardiogram. *J Am Coll Cardiol*. 1994;23:107–116.
2. Koneru JN, Wood MA, Ellenbogen KA. Rare forms of pre-excitation: a case study and brief overview of familial forms of pre-excitation. *Circ Arrhythm Electrophysiol*. 2012;5:e82–e87.
3. Porto AG, Brun F, Severini GM, Losurdo P, Fabris E, Taylor MRG, et al. Clinical spectrum of *PRKAG2* syndrome. *Circ Arrhythm Electrophysiol*. 2016;9:e003121.

KEY WORDS atrial fibrillation, cardiomyopathy, electrophysiology, genetic disorders, inherited metabolic disorders