

UCLA

Proceedings of the UCLA Department of Medicine

Title

A Case of Diffuse Pulmonary Coccidioidomycosis as the Initial Presenting Symptom of Acute HIV Infection

Permalink

<https://escholarship.org/uc/item/8pn1k8x1>

Journal

Proceedings of the UCLA Department of Medicine, 19(1)

Authors

Pena, Jonathan Dell

Jun, Dale

Lewis, Michael S.

et al.

Publication Date

2015-03-12

CLINICAL VIGNETTE

A Case of Diffuse Pulmonary Coccidioidomycosis as the Initial Presenting Symptom of Acute HIV Infection

Jonathan Dell Pena,^a Dale Jun, M.D.,^b Michael S. Lewis, M.D.,^c Jaime Betancourt, M.D.^d

^aDavid Geffen School of Medicine at UCLA; ^bCedars-Sinai Medical Center Department of Medicine; ^cAssistant Professor of Pathology and Surgery, West Los Angeles VA Healthcare Center and the David Geffen School of Medicine at UCLA; and ^dDepartment of Medicine, Division of Pulmonary & Critical Care Medicine, West Los Angeles VA Healthcare Center and the David Geffen School of Medicine at UCLA

Introduction

Pulmonary coccidioidomycosis is a fungal infection endemic to the Southwestern United States. Typical presenting symptoms include fever and non-specific respiratory complaints, such as cough. Compared to immune competent patients, those with co-morbid disease(s) that compromise one's innate and humoral immune responses such as infection with human immunodeficiency virus (HIV) or acquired immune deficiency syndrome (AIDS) have a higher probability of developing disseminated disease, which may affect the musculoskeletal, integumentary, and central nervous systems. We report a case in which a patient presented with diffuse pulmonary coccidioidomycosis with lymphadenitis, which led to the diagnosis of acute HIV infection.

Clinical Case

A 54-year-old Caucasian male with no significant past medical history presented with a one-month history of cough, hemoptysis, exertional dyspnea, fatigue, weight loss, and night sweats. He was previously evaluated at an outside emergency department and prescribed antibiotics for community acquired pneumonia but did not notice any improvement. Pertinent physical exam findings were notable for a thin Caucasian male with a temperature of 101.2°F, who was oxygenating 99% on ambient air. His lung fields were clear to auscultation throughout, and he had no palpable lymphadenopathy.

Chest radiograph (Figure 1a) demonstrated diffuse interstitial lung markings with innumerable micronodules and right hilar lymphadenopathy suggestive of Pulmonary Sarcoidosis or lymphoma. Computed tomography (CT) of the chest (Figure 1b) revealed diffuse, mediastinal, and hilar lymphadenopathy with scattered micronodules throughout the lung fields. F-18 Fluorodeoxyglucose (FDG) positron emission tomography (PET) imaging further demonstrated intense FDG uptake in the mediastinal and bilateral hilar lymph nodes (Figure 2).

Coccidioidomycosis IgG antibodies were positive, but IgM antibodies and coccidioidomycosis complement fixation titers were negative. Serial acid-fast bacteria sputum cultures and QuantiFERON-TB Gold assay were negative. Flexible fiberoptic bronchoscopy with transbronchial biopsies and subcarinal lymph node fine-needle aspiration demonstrated spherules consistent with pulmonary coccidioidomycosis with lymphadenitis (Figure 3). The patient was eventually found to be HIV positive with an HIV PCR of 71,200 copies/mL and a CD4 count of 91 cells/mm³. The patient was initiated on fluconazole, in addition to the appropriate HIV-opportunistic infection prophylaxis (trimethoprim-sulfamethoxazole and azithromycin). Evaluation for disseminated disease was negative. The patient's symptoms improved on fluconazole, and he was discharged home with close outpatient follow-up. Repeat chest CT several months later demonstrated marked improvement in his radiographic abnormalities.

Discussion

Coccidioidomycosis, more commonly known as Valley Fever, is a fungal infection endemic to the Southwestern United States where the reported case incidence in 2002 was 28.65 per 1 million persons.¹ Presenting symptoms are generally non-specific (e.g., fever and cough). The disease is often self-limited in healthy individuals. Immunocompromised hosts (e.g., HIV) have a higher likelihood of developing disseminated and extra-pulmonary disease affecting the bones, skin, and central nervous system.² It has been established that this risk correlates with a patient's CD4 count, a measure of one's cellular immune function. Prior studies suggests a CD4 count of less than 250 cells/mm³ or the diagnosis of AIDS prognosticates a higher likelihood of developing acute coccidioidomycosis among HIV-infected patients living in endemic regions.^{3,4} Aside from acute exposures, reactivation of disease has also been described in HIV patients presenting with coccidioidomycosis.⁵

Diagnosis is often made in the setting of symptoms and suggestive radiographic findings with serologic testing (Table 1).^{5,6,7,8,9} Radiographic findings are non-specific but include nodular consolidations, interlobular septal thickening, and pleura effusions, which can be found bilaterally but have a tendency to be left-side predominant.^{10,11} Lymphadenitis affecting the hilar and mediastinal lymph nodes has been previously described, which can develop into mediastinal abscesses.¹² In an acute infection, a person will usually develop detectable anti-coccidioides IgM antibodies within one to two weeks of exposure. Anti-coccidioides IgG antibodies are detectable after the acute infection. However in immunocompromised patients, studies suggest this response can be less robust or blunted as humoral responses may be compromised. Thus, it may take months for a compromised individual to exhibit seropositivity against coccidioides.¹³ Whenever possible, direct cultures of primary infection sites via bronchoalveolar lavage, transbronchial biopsies, as well as analysis of blood, tissue, and cerebral spinal fluid with varying specific media should be used to visualize the spherules.¹⁴

In healthy populations, pulmonary coccidioidomycosis is usually self-limited and does not require treatment. In immunocompromised individuals at risk for developing life-threatening, disseminating disease a tailored treatment approach is necessary. When there is no CNS involvement, fluconazole monotherapy is usually first-line. In severe, disseminated disease, a polyene lipid-based anti-fungal, such as amphotericin B, may be used in addition to fluconazole. Duration of treatment is one-year at minimum, so long as CD4 counts are greater than 250 cells/mm³, and there is an absence of diffuse and/or extrapulmonary disease (e.g., meningitis). If the CD4 count is less than 250 cells/mm³ and/or if the patient is found to have diffuse or extrapulmonary disease, lifelong therapy is recommended.¹⁵

Despite the prevalence of the organism in the aforementioned endemic regions, current standard of care does not advocate for the use of prophylactic antifungals as the benefit in most cases is minimal when compared to the cost and side effects associated with anti-fungal medications.¹⁶ Instituting anti-retroviral combination therapy is the most effective way, from both a cost and quality-of-life perspective, to prevent disease as evidenced by a decrease in the incidence of coccidioides infection in populations with wider access to HIV anti-retrovirals.¹⁷

Conclusion

Compared to other opportunistic infections, acute pulmonary coccidioidomycosis with lymphadenitis is a less common manifestation of acute HIV infection. However, it is an important consideration especially in endemic regions. Diagnosis is challenging in immunocompromised individuals due to decreased reliability of serological tests that are commonly used to aid in the diagnosis, thus it should be

carefully considered in conjunction with radiographs and direct tissue examination when possible. Immunosuppressed individuals are more likely to develop more severe disseminated extrapulmonary infection. As a corollary, patients presenting with disseminated coccidioidomycosis should be further evaluated for underlying innate or acquired immunodeficient states such as HIV infection, as illustrated by this case.

Figures

Table 1. Symptoms and suggestive radiographic findings with serologic testing.

Serology Tests	Qualitative/Quantitative	Significance
Enzyme-linked immunoassay (EIA)	Qualitative	Both IgM and IgG with high sensitivity and specificity ⁶ ; used often as screening tool but often requires immunodiffusion study as confirmation when direct visualization is not available due to possible false positivity ⁷
Immunodiffusion Table Precipitins (IDTP)	Qualitative	“IgM test” (tube precipitins), important in diagnosis of Acute Coccidioidomycosis, detectable in most patients in 1 to 2 weeks after onset of symptoms ⁸
Immunodiffusion Complement Fixation (IDCF)	Qualitative	“IgG test” (CF), detected in serum months to years after initial infection
Complement Fixation (CF)	Quantitative	Useful after a diagnosis has been established (chronic infection) and monitoring disease activity (titer level)
Latex Agglutination	Qualitative	Rapid results. Intended to detect IgM but has significant false positive reactions ⁹

Figure 1a and 1b.

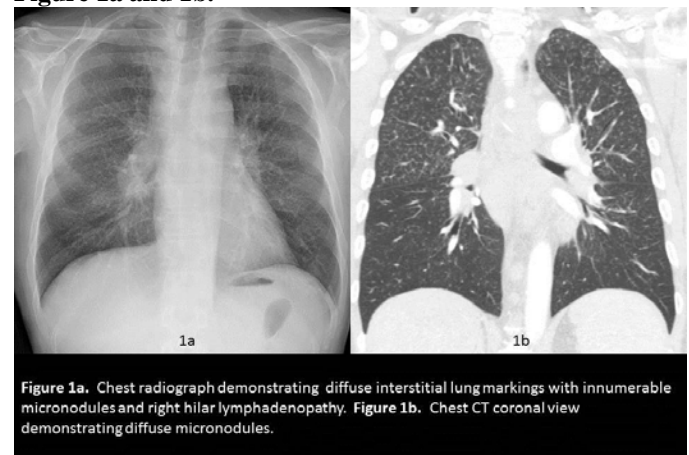


Figure 2.

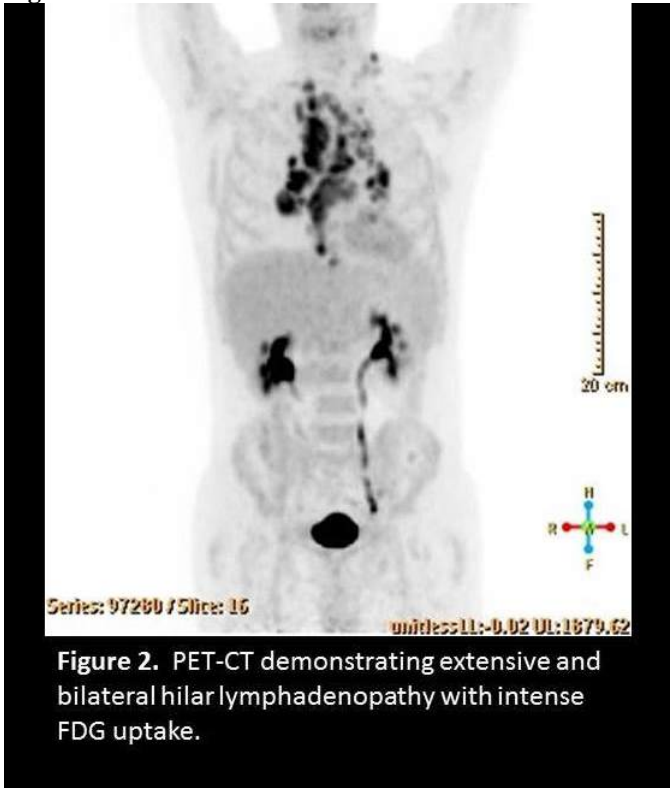


Figure 2. PET-CT demonstrating extensive and bilateral hilar lymphadenopathy with intense FDG uptake.

Figure 3.

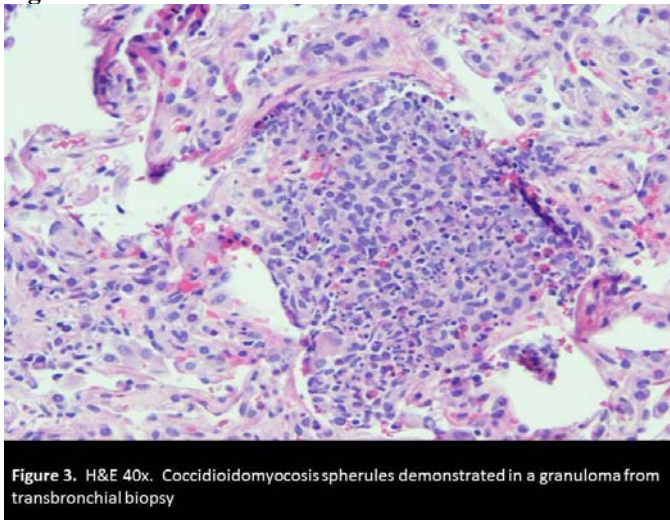


Figure 3. H&E 40x. Coccidioidomycosis spherules demonstrated in a granuloma from transbronchial biopsy

REFERENCES

1. **Chu JH, Feudtner C, Heydon K, Walsh TJ, Zaoutis TE.** Hospitalizations for endemic mycoses: a population-based national study. *Clin Infect Dis.* 2006 Mar 15;42(6):822-5. Epub 2006 Feb 1. PubMed PMID: 16477560.

2. **Elgafy H, Miller J, Meyers S, Assaly R.** Disseminated coccidioidomycosis of the spine. *Spine J.* 2013 Oct 24. pii: S1529-9430(13)01597-0. doi: 10.1016/j.spinee.2013.10.003. [Epub ahead of print] PubMed PMID: 24361127.
3. **Ampel NM.** Delayed-type hypersensitivity, in vitro T-cell responsiveness and risk of active coccidioidomycosis among HIV-infected patients living in the coccidioidal endemic area. *Med Mycol.* 1999 Aug;37(4):245-50. PubMed PMID:10421859.
4. **Singh VR, Smith DK, Lawrence J, Kelly PC, Thomas AR, Spitz B, Sarosi GA.** Coccidioidomycosis in patients infected with human immunodeficiency virus: review of 91 cases at a single institution. *Clin Infect Dis.* 1996 Sep;23(3):563-8. PubMed PMID: 8879781.
5. **Hernández JL, Echevarría S, García-Valtuille A, Mazorra F, Salesa R.** Atypical coccidioidomycosis in an AIDS patient successfully treated with fluconazole. *Eur J Clin Microbiol Infect Dis.* 1997 Aug;16(8):592-4. PubMed PMID: 9323471.
6. **Wieden MA, Lundergan LL, Blum J, Delgado KL, Coolbaugh R, Howard R, Peng T, Pugh E, Reis N, Theis J, Galgiani JN.** Detection of coccidioidal antibodies by 33-kDa spherule antigen, Coccidioides EIA, and standard serologic tests in sera from patients evaluated for coccidioidomycosis. *J Infect Dis.* 1996 May;173(5):1273-7. PubMed PMID: 8627085.
7. **Kaufman L, Sekhon AS, Moledina N, Jalbert M, Pappagianis D.** Comparative evaluation of commercial Premier EIA and microimmunodiffusion and complement fixation tests for Coccidioides immitis antibodies. *J Clin Microbiol.* 1995 Mar;33(3):618-9. PubMed PMID: 7751365; PubMed Central PMCID: PMC228000.
8. **Pappagianis D, Zimmer BL.** Serology of coccidioidomycosis. *Clin Microbiol Rev.* 1990 Jul;3(3):247-68. Review. PubMed PMID: 2200605; PubMed Central PMCID:PMC358158.
9. **Huppert M, Peterson ET, Sun SH, Chitjian PA, Derrevere WJ.** Evaluation of a latex particle agglutination test for coccidioidomycosis. *Am J Clin Pathol.* 1968 Jan;49(1):96-102. PubMed PMID: 5635281.
10. **Merchant M, Romero AO, Libke RD, Joseph J.** Pleural effusion in hospitalized patients with Coccidioidomycosis. *Respir Med.* 2008 Apr;102(4):537-40. doi:10.1016/j.rmed.2007.11.014. Epub 2007 Dec 31. PubMed PMID: 18164951.
11. **Capone D, Marchiori E, Wanke B, Dantas KE, Cavalcanti MA, Deus Filho A, Escuissato DL, Warszawiak D.** Acute pulmonary coccidioidomycosis: CT findings from 15 patients. *Br J Radiol.* 2008 Sep;81(969):721-4. doi: 10.1259/bjr/12054884. Epub 2008 May 28. PubMed PMID: 18508875.
12. **Rady MY, Lopez A, Patel BM, Larson JS.** Pyomyo-mediastinitis: A complication of pulmonary

- coccidioidomycosis. *Can J Infect Dis.* 2003 May;14(3):170-2. PubMed PMID: 18159453; PubMed Central PMCID: PMC2094931.
13. **Blair JE, Coakley B, Santelli AC, Hentz JG, Wengenack NL.** Serologic testing for symptomatic coccidioidomycosis in immunocompetent and immunosuppressed hosts. *Mycopathologia.* 2006 Nov;162(5):317-24. PubMed PMID: 17123029; PubMed Central PMCID: PMC2780641.
 14. **DiTomasso JP, Ampel NM, Sobonya RE, Bloom JW.** Bronchoscopic diagnosis of pulmonary coccidioidomycosis. Comparison of cytology, culture, and transbronchial biopsy. *Diagn Microbiol Infect Dis.* 1994 Feb;18(2):83-7. PubMed PMID: 8062536.
 15. **Ampel NM.** Coccidioidomycosis in persons infected with HIV type 1. *Clin Infect Dis.* 2005 Oct 15;41(8):1174-8. Epub 2005 Sep 12. Review. Erratum in: *Clin Infect Dis.* 2005 Dec 15;41(12):1830. PubMed PMID: 16163637.
 16. **Woods CW, McRill C, Plikaytis BD, Rosenstein NE, Mosley D, Boyd D, England B, Perkins BA, Ampel NM, Hajjeh RA.** Coccidioidomycosis in human immunodeficiency virus-infected persons in Arizona, 1994-1997: incidence, risk factors, and prevention. *J Infect Dis.* 2000 Apr;181(4):1428-34. Epub 2000 Apr 7. PubMed PMID: 10753734.
 17. **Masannat FY, Ampel NM.** Coccidioidomycosis in patients with HIV-1 infection in the era of potent antiretroviral therapy. *Clin Infect Dis.* 2010 Jan 1;50(1):1-7. doi: 10.1086/648719. PubMed PMID: 19995218.

Submitted March 12, 2015