

UCLA

Proceedings of UCLA Health

Title

Acute Herpes Simplex Hepatitis in a Patient with Systemic Lupus Erythematosus

Permalink

<https://escholarship.org/uc/item/8nk53203>

Journal

Proceedings of UCLA Health, 21(1)

Authors

Myung, Gihyun

Kurtz, Justin

Miller, Gopika

et al.

Publication Date

2017-06-04

CLINICAL VIGNETTE

Acute Herpes Simplex Hepatitis in a Patient with Systemic Lupus Erythematosus

¹Gihyun Myung, ²Justin Kurtz, ³Gopika Miller, ⁴Richard A. Murphy

¹Division of Rheumatology, Department of Medicine, UCLA Medical Center, Los Angeles, CA

²Department of Pathology, Harbor-UCLA Medical Center, Los Angeles, CA

³Division of Rheumatology, Harbor-UCLA Medical Center, Los Angeles, CA

⁴Division of Infectious Diseases, Harbor-UCLA Medical Center, Los Angeles, CA

Abstract

Herpes simplex virus (HSV) – depending on the host immunity, age, and the antigenic type of the virus – can manifest in varied ways. We describe a case of herpes simplex virus hepatitis in a patient with a history of systemic lupus erythematosus (SLE) accompanied by marked transaminitis, thrombocytopenia, coagulopathy whose presentation included ulcers on the penis. Initially, patient was thought to have systemic lupus erythematosus flare. Eventually, diagnosis was made through liver biopsy showing multilobular acute necrosis and immunohistochemical stain positive for herpes simplex type 2 in areas of necrosis. Patient improved clinically after acyclovir was started.

Case Presentation

A 26-year-old male with a history of lupus nephritis (LN) presented to the emergency room with 5 days of fever, right upper quadrant pain, vomiting, and diarrhea. The patient reported one week history of new ulcers on his penis after sexual intercourse with his partner. His past history was remarkable for Class IV LN diagnosed 6 years ago. He was treated with pulse methylprednisolone and IV cyclophosphamide before being lost to follow up.

On examination, the patient appeared ill. Temperature was 39.6°C, blood pressure 131/70 mm Hg, pulse 106 bpm, and respiratory rate 20 bpm with normal saturation. Two non-tender, shallow, erythematous-based ulcers were noted on the penile shaft proximal to the glans. Lab revealed a WBC 9 K, hemoglobin 13.5 g/dL, and platelet 86 K/cumm. AST and ALT were elevated at 603 and 479. Total bilirubin was elevated to 3.0 mg/dL (direct bilirubin was 0.8 mg/dL). Ultrasound of the liver showed hepatic enlargement with a smooth surface, normal

hepatic vein waveforms, and no focal lesion. On the hospital day 5, the AST peaked at 4,367, ALT 2,267, and the total bilirubin was 18.4 mg/dL.

The patient also developed a systolic murmur. Echocardiogram showed mild to moderate global hypokinesis with an ejection fraction of 35-40% and moderate mitral regurgitation. The serum troponin peaked at 0.27 ng/mL. Peripheral smear showed few schistocytes with low normal haptoglobin of 48 mg/dL and negative Coombs test. Infectious work up including *C. difficile* toxin PCR, FTA, gonorrhea and chlamydia, and hepatitis A, B, and C screening tests were negative. The serum EBV PCR was positive at 1182 copies/mL but had negative VCA-IgM. On hospital day 5, the HSV 2 PCR from the penile lesion and serum HSV 2 PCR returned qualitatively positive. Parenteral acyclovir was initiated with improvement in transaminases the following day. However, his bilirubin continued to rise, and a transjugular liver biopsy was performed on hospital day 6.

On hospital day 8, ANA (1:80) and dsDNA ab (58 IU/mL) returned mildly elevated. Methylprednisolone was started as an empiric treatment for possible autoimmune hepatitis. Anti-actin and anti-smooth muscle antibodies were within normal limits. Renal biopsy on hospital day 10 due to a slight rise in creatinine with significant proteinuria (24 hour urine protein 2952 mg) revealed normal glomeruli and patent capillaries without signs of active nephritis or microangiopathy. He had significant clinical recovery as well as improvement of LFTs and was discharged home on hospital day 14. Liver biopsy revealed submassive and multilobular acute necrosis with immunohistochemical stain positive for herpes simplex type 2 in areas of necrosis. (Figures 1-3).

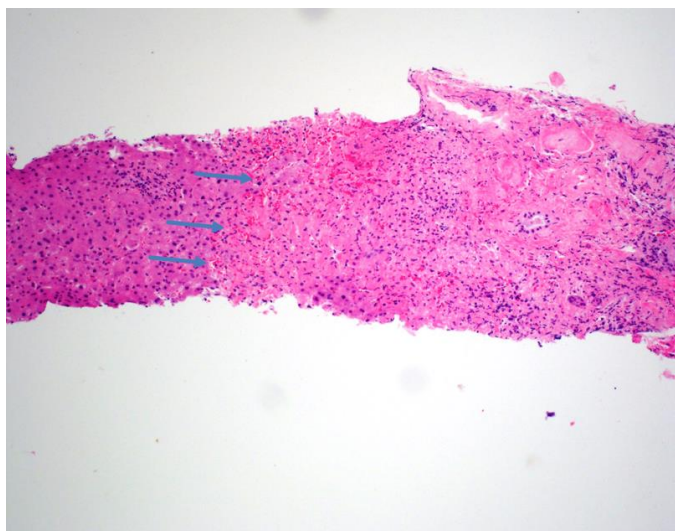


Figure 1. Liver biopsy showing submassive necrosis (large areas of necrosis involving entire lobules). Arrows demarcate the transition between viable liver parenchyma (left) and necrotic liver tissue (right). There is a neutrophilic infiltrate present in both viable and necrotic tissue. (Hematoxylin and Eosin, 4x)

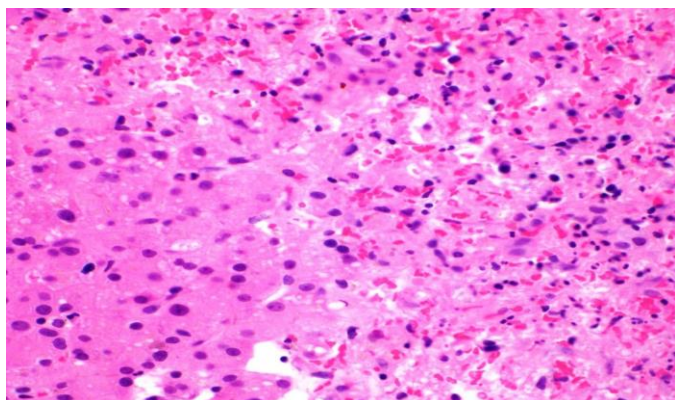


Figure 2. High power view of the transition between viable liver parenchyma (left) and necrotic liver tissue (right). A neutrophilic infiltrate can be seen in both viable and necrotic tissue. The necrotic area is hemorrhagic. Microvesicular steatosis can be appreciated in the viable liver tissue. In contrast, hepatitis E would have lymphocytic inflammation. (Hematoxylin and Eosin, 20x)

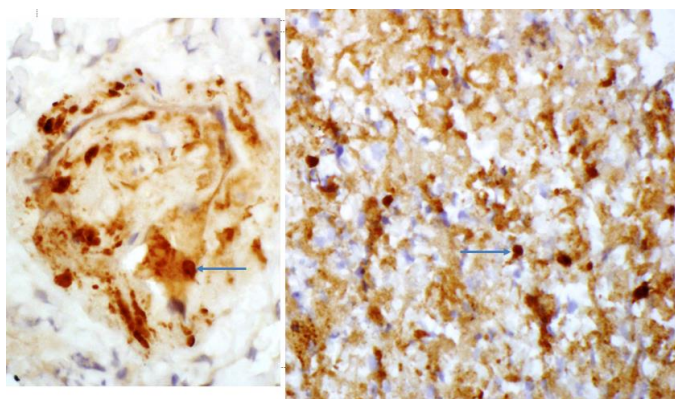


Figure 3. Immunohistochemistry stain for HSV-2 (left 40x, right 20x). Positive nuclear staining is seen in cells infected by HSV-2. (Arrows show examples of positive nuclei to differentiate from the weaker non-specific background stain that is common in necrotic tissue).

Discussion

Herpes simplex virus (HSV)-related hepatitis is a rare but life-threatening cause of acute hepatitis. HSV is responsible for 2-4% of cases of acute viral hepatitis and 0.8% of cases with fulminant liver failure.¹ Patients with HSV hepatitis typically present with non-specific clinical symptoms such as flu-like fever and abdominal pain, without signs of jaundice (“anicteric hepatitis” in 90% of cases).² Mucocutaneous lesions are present in approximately a quarter of patients with HSV hepatitis.³ HSV hepatitis is more commonly seen in the patients with impaired immunity such as in transplant patients, pregnancy, corticosteroid use, HIV infection and autoimmune disease,^{1,4,5} but can present in patients without impaired immunity.⁶ Although our patient was not receiving immunosuppressive agents on presentation, he was likely immunocompromised from underlying SLE.

With a history of SLE, the potential causes of acute hepatitis were broad and included rheumatologic and infectious etiologies. An SLE flare was considered, however, the patient lacked other flare symptoms and the liver biopsy was not consistent with autoimmune hepatitis. Other diagnostic considerations were antiphospholipid syndrome with hepatic artery thrombus leading to ischemia, catastrophic antiphospholipid syndrome (CAPS) causing transaminitis from ischemic liver, mitral valve regurgitation, thrombocytopenia, and TTP-like syndrome.^{7,8} However, our patient had negative anti-phospholipid (aPL) antibodies and both liver and kidney biopsies did not reveal significant microthrombi.

Patients with SLE are at increased risk of disseminated viral infections from Parvovirus B19, CMV, and HSV. Impaired T-cell and macrophage immunity may explain the dissemination of the HSV in both primary HSV and reactivation of HSV.⁹ HSV hepatitis should be considered in patients with hepatitis and typical mucocutaneous evidence of HSV disease was confirmed with liver biopsy. Histology typically shows extensive hepatocyte necrosis with minimal inflammatory infiltrates and positive immunohistochemical staining for HSV.¹⁰ Cowdry type A inclusions are pathognomonic for HSV hepatitis. These are nuclei with large eosinophilic ground glass-like inclusions surrounded by a clear halo.^{11,12} Mortality of untreated HSV hepatitis can exceed 80-90%,¹³ and early treatment with acyclovir can inhibit viral replication and enhance the probability of survival.¹⁴ Therapy should be initiated based on clinical suspicion, our patient was treated with acyclovir on hospital day 5 and his transaminitis improved early after initiation of therapy. The dosage of acyclovir for HSV hepatitis has

not been extensively studied, because of the rarity of this disease. High-dose acyclovir, at 10mg/kg every 8 hours with adjustment for renal function has been used historically.¹⁵ Treatment is typically given for 10-14 days.²

In conclusion, this case of acute HSV hepatitis in a patient with history of lupus nephritis was successfully treated with parenteral acyclovir. This highlights the importance of acute infection in patients with SLE presenting with systemic illness with particular attention to viral infections including HSV. Lastly, there should be a low threshold to initiate acyclovir empirically if there is a high clinical suspicion for HSV hepatitis because of high untreated mortality.

Disclosures

All authors have no potential disclosures or conflict of interests.

Funding

No outside funding was used in the production of this manuscript

Consent

Patient consented to the publication of this case.

References

1. **Wertheim RA, Brooks BJ Jr, Rodriguez FH Jr, Lesesne HR, Jennette JC.** Fatal herpetic hepatitis in pregnancy. *Obstet Gynecol.* 1983 Sep;62(3 Suppl):38s-42s. PubMed PMID: 6877709.
2. **Peters DJ, Greene WH, Ruggiero F, McGarrity TJ.** Herpes simplex-induced fulminant hepatitis in adults: a call for empiric therapy. *Dig Dis Sci.* 2000 Dec;45(12):2399-404. PubMed PMID: 11258565.
3. **Norvell JP, Blei AT, Jovanovic BD, Levitsky J.** Herpes simplex virus hepatitis: an analysis of the published literature and institutional cases. *Liver Transpl.* 2007 Oct;13(10):1428-34. PubMed PMID: 17902129.
4. **Hirschi S, Biondini D, Ohana M, Solis M, D'Urso A, Rosner V, Kessler R.** Herpes simplex virus 2 hepatitis in a lung transplant recipient: a diagnostic challenge. *Transpl Infect Dis.* 2015 Dec;17(6):904-8. doi: 10.1111/tid.12459. Epub 2015 Nov 5. PubMed PMID: 26370068.
5. **Montalbano M, Slapak-Green GI, Neff GW.** Fulminant hepatic failure from herpes simplex virus: post liver transplantation acyclovir therapy and literature review. *Transplant Proc.* 2005 Dec;37(10):4393-6. Review. PubMed PMID: 16387129.
6. **Farr RW, Short S, Weissman D.** Fulminant hepatitis during herpes simplex virus infection in apparently immunocompetent adults: report of two cases and review of the literature. *Clin Infect Dis.* 1997 Jun;24(6):1191-4. PubMed PMID: 9195081.
7. **Turiel M, Sarzi-Puttini P, Peretti R, Bonizzato S, Muzzupappa S, Atzeni F, Rossi E, Doria A.** Five-year follow-up by transesophageal echocardiographic studies in primary antiphospholipid syndrome. *Am J Cardiol.* 2005 Aug 15;96(4):574-9. PubMed PMID: 16098314.
8. **Uthman I, Godeau B, Taher A, Khamashta M.** The hematologic manifestations of the antiphospholipid syndrome. *Blood Rev.* 2008 Jul;22(4):187-94. doi: 10.1016/j.blre.2008.03.005. Epub 2008 Apr 15. Review. PubMed PMID: 18417261.
9. **Arkin LM, Castelo-Soccio L, Kovarik C.** Disseminated herpes simplex virus (HSV) hepatitis diagnosed by dermatology evaluation. *Int J Dermatol.* 2009 Sep;48(9):1020-1. doi: 10.1111/j.1365-4632.2009.04084.x. PubMed PMID: 19702997; PubMed Central PMCID: PMC2874893.
10. **Ichai P, Roque Afonso AM, Sebah M, Gonzalez ME, Codés L, Azoulay D, Saliba F, Karam V, Dussaix E, Guettier C, Castaing D, Samuel D.** Herpes simplex virus-associated acute liver failure: a difficult diagnosis with a poor prognosis. *Liver Transpl.* 2005 Dec;11(12):1550-5. PubMed PMID: 16315311.
11. **Sharma S, Mosunjac M.** Herpes simplex hepatitis in adults: a search for muco-cutaneous clues. *J Clin Gastroenterol.* 2004 Sep;38(8):697-704. Review. PubMed PMID: 15319655.
12. **Pinna AD, Rakela J, Demetris AJ, Fung JJ.** Five cases of fulminant hepatitis due to herpes simplex virus in adults. *Dig Dis Sci.* 2002 Apr;47(4):750-4. PubMed PMID: 11991604.
13. **Navaneethan U, Lancaster E, Venkatesh PG, Wang J, Neff GW.** Herpes simplex virus hepatitis - it's high time we consider empiric treatment. *J Gastrointest Liver Dis.* 2011 Mar;20(1):93-6. PubMed PMID: 21451806.
14. **Whitley R, Arvin A, Prober C, Burchett S, Corey L, Powell D, Plotkin S, Starr S, Alford C, Connor J, et al.** A controlled trial comparing vidarabine with acyclovir in neonatal herpes simplex virus infection. Infectious Diseases Collaborative Antiviral Study Group. *N Engl J Med.* 1991 Feb 14;324(7):444-9. PubMed PMID: 1988829.