

# UC Davis

## Dermatology Online Journal

### Title

Essential telangiectasia in an infant: a diagnosis to be considered

### Permalink

<https://escholarship.org/uc/item/8m27b1x4>

### Journal

Dermatology Online Journal, 23(8)

### Authors

Fernández-Crehuet, Pablo  
Ruiz-Villaverde, Ricardo

### Publication Date

2017

### DOI

10.5070/D3238036021

### Copyright Information

Copyright 2017 by the author(s). This work is made available under the terms of a Creative Commons Attribution-NonCommercial-NoDerivatives License, available at <https://creativecommons.org/licenses/by-nc-nd/4.0/>

# Essential telangiectasia in an infant: a diagnosis to be considered

Pablo Fernández-Crehuet<sup>1</sup> MD PhD, Ricardo Ruiz-Villaverde<sup>2</sup> MD PhD

Affiliations: <sup>1</sup>Department of Dermatology, Dermatologist MD PhD, Hospital Universitario Reina Sofía, Córdoba, Spain, <sup>2</sup>Department of Dermatology, Dermatologist MD PhD, Complejo Hospitalario de Granada, Granada, Spain

Corresponding Author: Ricardo Ruiz-Villaverde, Complejo Hospitalario de Granada, Avda. Conocimiento 33 18016 Granada Spain, Email: ismenios@hotmail.com

## Abstract

Essential generalized telangiectasia as the result of postcapillary venule dilatation, is characterized by the sudden development of generalized telangiectasias, sometimes involving the conjunctiva. A few pediatric cases have been reported. The main condition in the differential diagnosis includes syndromes with telangiectasia such as hereditary hemorrhagic telangiectasia of Rendu-Osler, unilateral nevoid telangiectasia, and neonatal lupus erythematosus. We present an 11-month-old boy that presented because of telangiectasia located on the face and neck. The telangiectasias appeared at two months of age and followed a progressive course. Nd-YAG laser therapy could be an interesting therapeutic approach in cosmetically compromised cases.

*Keywords: essential telangiectasia, diagnosis, treatment*

## Introduction

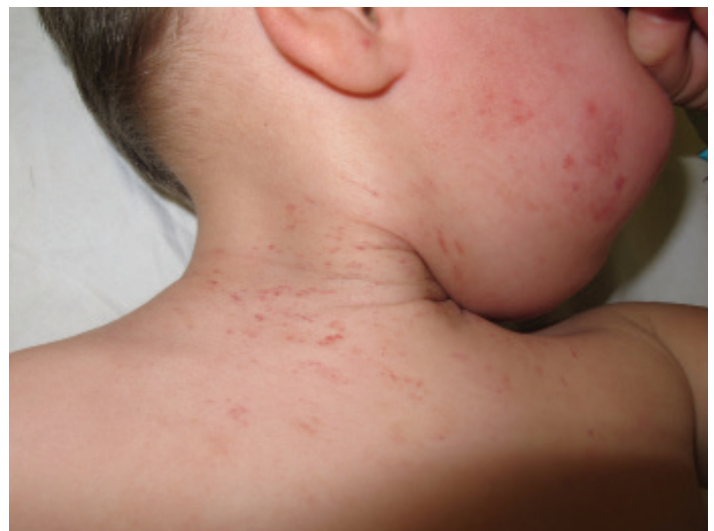Essential telangiectasia (ET) is the result of postcapillary venule dilatation. This entity is characterized by the sudden development of generalized or widespread telangiectasias, sometimes involving the conjunctiva. These are extremely rare in the pediatric population and may be considered a clinical diagnosis of exclusion.

## Case Synopsis

An 11-month-old boy without any remarkable antecedent was brought to our dermatological outpatient clinic complaining of telangiectasia

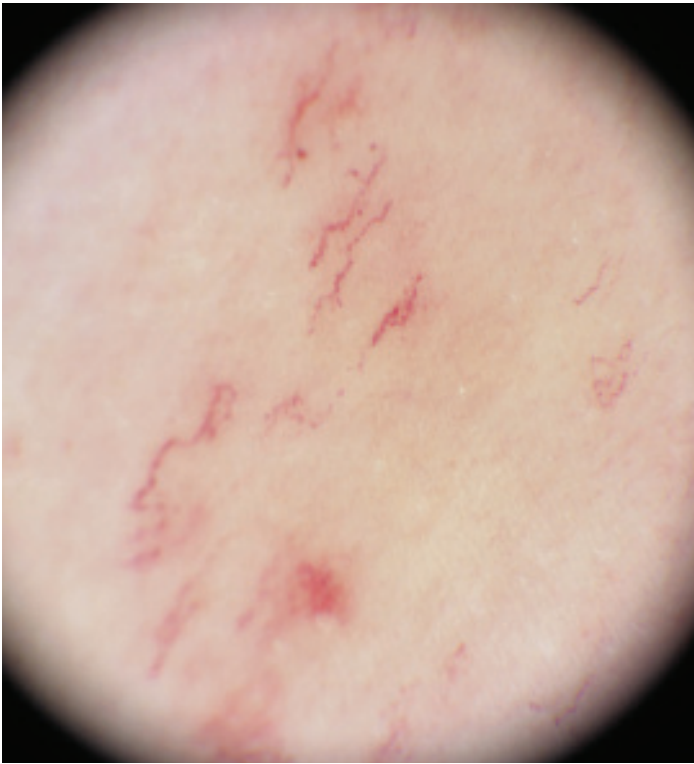
located on the face and neck. They had appeared at two months of age and had progressed in number thereafter. There was no history of drug intake, trauma, or situations leading to increased venous pressure. The patient was otherwise healthy and the skin lesions caused no pain or itch.

On examination, we observed hundreds of small arborescent and linear telangiectasia on the cheeks, neck, and the upper part of the anterior chest (**Figure 1**). On dermoscopy, fine, linear, irregular telangiectasia were seen (**Figure 2**). There were no mucosal telangiectasia.



**Figure 1.** Linear telangiectasias on the cheeks, neck and upper part of the anterior chest.

Analyses including blood cell count, ESR, serum chemistry, thyroid hormones, ANA, reactive C protein,  $\beta$ 2-microglobulin, serum tryptase, vitamin C, albumin, and serologies for syphilis and lupus erythematosus



**Figure 2.** Dermoscopy (DermLite DL3, California, 3Gen, CA, USA): Thin irregular telangiectasia.

(anti Ro, La, RNP) were all within normal values. An abdominal ultrasound was unremarkable.

A skin biopsy showed only capillary dilatation in the upper dermis. Mast cells were not increased in number. Estrogen receptors measured by immunohistochemistry were not increased in number. Echocardiography was also normal. The lesions persisted unchanged for 6 months. Nd-YAG laser therapy was offered, but refused by the parents.

## Case Discussion

Our patient had early-onset telangiectasia on the face and neck without any other systemic involvement or associated features. Essential telangiectasia is a rare condition characterized by the development of widespread telangiectasia that often progresses to additional areas of the whole body in the following years after diagnosis. Most cases described have been reported in adult patients.

Several conditions are associated with primary telangiectasia. The most important ones include generalized essential telangiectasia (GET), hereditary hemorrhagic telangiectasia (HHT), hereditary benign telangiectasia (HBT), ataxia-telangiectasia,

and unilateral nevoid telangiectasia. Primary telangiectasia in the context of Rothmund Thomson syndrome should also be ruled out. We believe it is important to investigate for conditions that can be associated with telangiectasia.

In hereditary hemorrhagic telangiectasia of Rendu-Osler [1], telangiectasia appear progressively from childhood anywhere on the skin and mucosae; they can bleed spontaneously or after trauma. Pulmonary, gastrointestinal, urinary tract, and central nervous system hemorrhage can be fatal.

The clinical diagnosis of benign hereditary telangiectasia (BHT) was initially considered, but the absence of affected family members, the absence of mucosal involvement, and the lack of episodes of bleeding with trauma caused us to temporarily rule out the diagnosis. In BHT the presence of telangiectasias with different morphological features (lineal, punctiform, arborescent, reticulated, or in plaques) may be observed. In ET most of the telangiectasias are lineal or arborescent [2].

Ataxia-telangiectasia [3] is an autosomal recessive immunodeficiency disorder with neurodegeneration leading to ataxia, dysarthria, and mental delay. In this condition, telangiectasia usually appear in the conjunctiva and less frequently on both sides of the face.

In unilateral nevoid telangiectasia (UNT), [4] linear and arborizing telangiectasia usually appear on the head, trunk, or limbs and may appear with a lateralization pattern. It can be congenital or acquired and in this latter case, usually appears associated with hyperestrogenic states [5]; UNT is commonly observed in women in the fertile years of life.

Telangiectasia may also be the only clinical manifestation of neonatal lupus erythematosus and lesions may persist, but this was ruled out with normal anti-Ro, La, and RNP.

On the other hand, generalized essential generalized telangiectasia, GET, has been proven to be the result of postcapillary venule dilatation and is characterized by the sudden development of generalized telangiectasia, sometimes involving the conjunctiva

[6]. This condition affects mainly Caucasian women, aged late thirties to late forties and first appears on the lower limbs with slow progression proximally to involve the trunk. Systemic symptoms, especially gastrointestinal, should be ruled-out. Vasculopathic changes have been observed on pathological examinations so it is feasible to think that GET could extend beyond purely cutaneous involvement. Nd Yag laser offers good cosmetic results when telangiectasias are treated. Treatment with tetracyclines, acyclovir, or ketoconazole have shown isolated successful responses [7].

We have been unable to find in the literature any similar case to the one presented. We believe our patient may be included within the spectrum of UNT, but the bilateral distribution challenges this diagnosis.

## Conclusion

Essential telangiectasia (ET) without systemic association is extremely rare in the pediatric population. The pathogenesis remains unknown. Further studies are needed to characterize this entity and provide an optimal therapeutical approach in the pediatric population.

## References

1. Maaloul I, Aloulou H, Fourati H, Sfaihi L, Chabchoub I, Kamoun T, et al. Hereditary hemorrhagic telangiectasia: Report of a pediatric case. *Arch Pediatr*. 2014;21:768-71. [PMID: 24935454].
2. Arévalo NY, Martínez del Sel J, Donatti L, Dahbar M, Cabrera H, Allevato M. Hereditary benign telangiectasia: punctate telangiectasia surrounded by anemic halo. *JAMA Dermatol*. 2013;149:633-4. [PMID: 23677110].
3. Jayadev S, Bird TD. Hereditary ataxias: overview. *Genet Med*. 2013;15:673-83. [PMID: 23538602].
4. Tanglertsampan C, Chanthothai J, Phichawong T. Unilateral nevoid telangiectasia: case report and proposal for new classification system. *Int J Dermatol*. 2013;52:608-10. [PMID: 23590376].
5. Kim EJ, Park HS, Yoon HS, Kim KH, Cho S. Demographic and clinical differences between unilateral and bilateral forms of nevoid telangiectasia: a retrospective study with review of literature. *Br J Dermatol*. 2015;172:1651-3. [PMID: 25495722].
6. Gordon Spratt EA, DeFelice T, O'Reilly K, Robinson M, PaTel:RR, Sanchez M. Generalized essential telangiectasia. *Dermatol Online J*. 2012 Dec 15;18:13. [PMID: 23286803].
7. Long D, Marshman G. Generalized essential telangiectasia. *Australas J Dermatol*. 2004 Feb;45(1):67-9. [PMID: 14961914].