

UC Irvine

Mediterranean Journal of Emergency Medicine & Acute Care

Title

Psoriasis and Heart Failure: Literature Review and a Case Challenge

Permalink

<https://escholarship.org/uc/item/8kg6x75k>

Journal

Mediterranean Journal of Emergency Medicine & Acute Care, 1(1)

ISSN

2642-7168

Authors

Sianipar, Maruli Tua
Siswanto, Bambang Budi

Publication Date

2019

DOI

10.52544/2642-7184(1)1002

Copyright Information

Copyright 2019 by the author(s). All rights reserved unless otherwise indicated. Contact the author(s) for any necessary permissions. Learn more at <https://escholarship.org/terms>

Peer reviewed

Psoriasis and Heart Failure: Literature Review and a Case Challenge

Maruli Tua Sianipar¹, Bambang Budi Siswanto^{1,2*}

¹Department of Cardiology & Vascular Medicine, University of Indonesia, Jakarta, Indonesia

²National Cardiovascular Centre, University of Indonesia, Jakarta, Indonesia

Abstract

Psoriasis is a disease characterized by chronic inflammation with a global prevalence of 1-2%. It has a strong genetic component with a systemic immunological response mainly driven by T helper (Th) 1 and 17 lymphocytes. The relationship between HF and psoriasis is not well-described. In this paper we describe 2 cases of concomitant psoriasis and heart failure. Furthermore, we revisit the pathogenesis of those entities and discuss the available evidence on their association, and the proper evaluation of psoriasis in the management of heart failure in patients present with both diseases.

Keywords: cardiovascular disease, heart failure, immunology, inflammation, pathogenesis, psoriasis

INTRODUCTION

Around 26 million adults worldwide are living with heart failure (HF) that is thus described as a “global pandemic”.¹ In Indonesia, the prevalence of HF is 0.13%.² Psoriasis is a disease characterized by chronic inflammation with a global prevalence of 1-2%. It has strong genetic component with a systemic immunological response mainly driven by T helper (Th) 1 and 17 lymphocytes.^{2,3} The relationship between HF and psoriasis is not well-described.

By presenting two cases of psoriatic HF patients with re-hospitalizations, this manuscript aims at highlighting the potential role of psoriatic inflammation in worsening HF.

CASE PRESENTATION

First Case

This is a case of a 61-year-old man, who regularly visits the outpatient clinic in the National Cardiac Center Harapan Kita (NCCHK) every two

months. During his last visit, he only admitted having slight limitation of physical activity without any paroxysmal nocturnal dyspnea (PND) or orthopnea. He had a history of valvular disease but did not complain of any HF symptoms until the age of 51. He then had mitral valve replacement due to mitral regurgitation in Penang. The patient also had a history of psoriasis diagnosed at the age of 49 but was not on any psoriasis treatment. There was no history of psoriasis exacerbation. The patient also denies any history of hypertension, diabetes mellitus, smoking, obesity, alcohol abuse, and drug use. Family history was negative for cardiovascular disease or cardiomyopathy. He reported four prior hospitalization in NCCHK due to decompensated HF. The first one was two months after surgery. The second one was in 2012, the third in 2014, and the last in 2016. On physical examination, the patient had normal vitals. There was no signs of left or right HF. Skin lesions consisting of scales and plaques over the extremities were noted. His joints were normal. Routine laboratory tests revealed normal renal function and normal electrolytes. Chest radiography (2016) showed an enlarged heart and bilateral pulmonary congestion. Electrocardiogram showed sinus rhythm, right bundle branch block (RBBB), and multiple PVCs. Echocardiography showed general severe hypokinesis, dilatation of

Correspondence to:

Bambang Budi Siswanto
Department of Cardiology & Vascular Medicine,
University of Indonesia, Jakarta, Indonesia
Email: bambang.siswanto@ui.ac.id

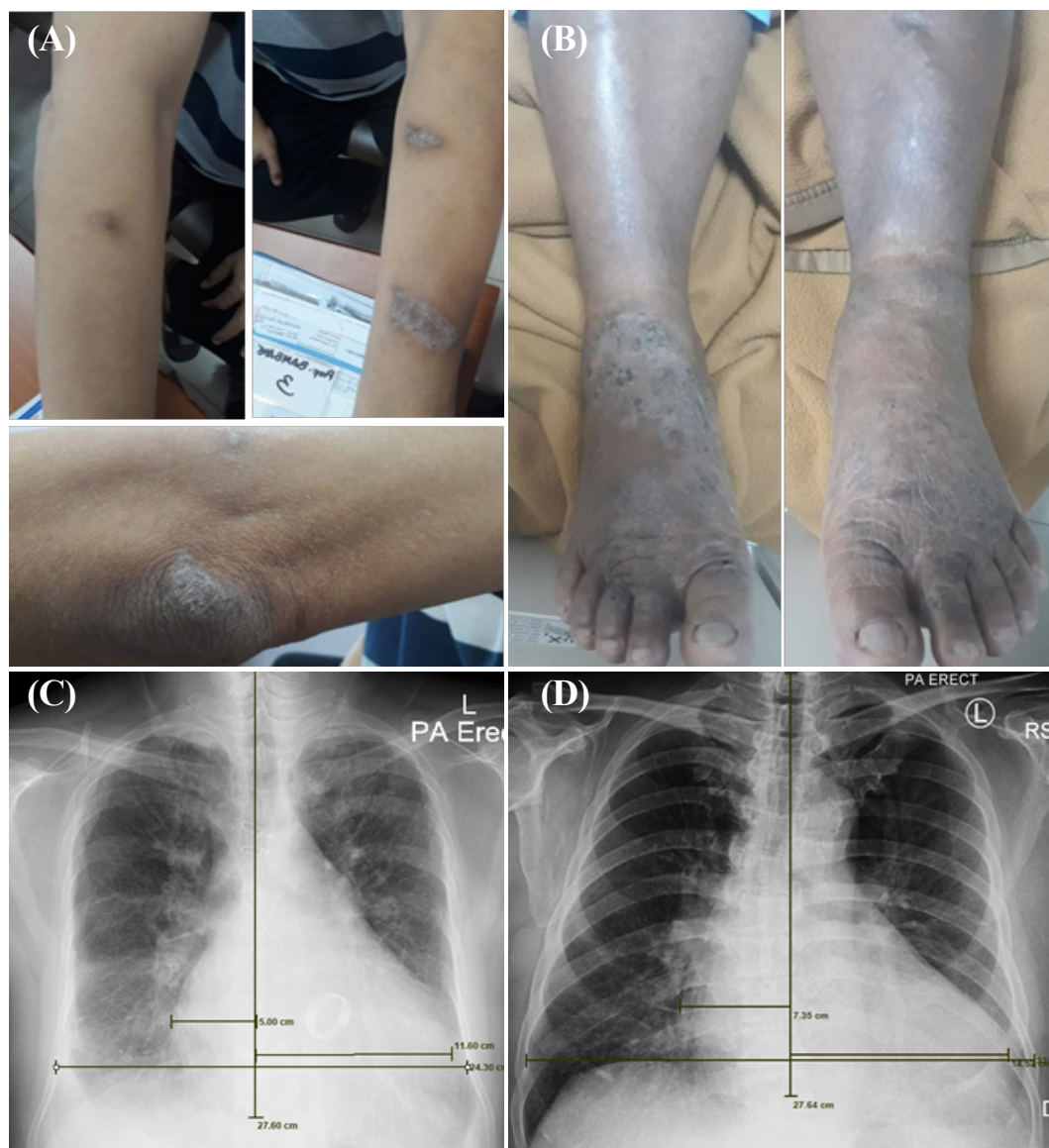


Figure 1 (A) skin lesions in the first patient: scales and plaques over the extremities; (B) skin lesions in the second patient: plaques over the feet; (C) chest radiograph of the first patient: enlarged heart and bilateral pulmonary congestion; (D) chest radiograph of the second patient: enlarged heart and mild congestion.

left atrium (LA) and left ventricle (LV), severely reduced global systolic function and regional wall abnormality, mild pulmonary regurgitation (PR), mild tricuspid regurgitation (TR), and a well functioning mechanical valve with trivial central leakage. Coronangiography in 2011 demonstrated normal coronary arteries.

Second Case

This is a case of a 58-year-old man who was admitted with a 1-month history of dyspnea. One

month prior to admission, he began suffering from shortness of breath on effort, orthopnea, and paroxysmal nocturnal dyspnea. His legs and abdomen started to swell 3 days before admission. The patient had a history of HF diagnosed in 2012. He was hospitalized in NCCHK back then. After discharge, he did not seek any medical therapy. His risk factors included hypertension, smoking, and obesity. He denied any family history of cardiovascular disease or cardiomyopathy, drug use or alcohol consumption. He has had psoriatic

skin lesions for 3 months prior to admission, for which no medical treatment was sought. On physical examination, the patient had normal vitals. However, he did have signs of congestive HF. He also has scaly skin lesions and plaques on both of his feet. Routine laboratory tests revealed normal white blood count and normal renal function. Chest radiography showed an enlarged heart and bilateral congestion. Electrocardiogram showed atrial fibrillation. Echocardiography showed generalized severe hypokinesis, dilatation of LA and LV, severely reduced global systolic function, severe mitral regurgitation, and severe TR. Coroangiography in 2012 demonstrated a normal left main artery, an irregular left axis deviation, an irregular left circumflex artery, and a normal right coronary artery (i.e., an insignificant stenosis).

DISCUSSION

Across the globe, 17-45% of patients admitted to hospital with heart failure (HF) die within 1 year of admission and the majority die within 5 years. This “global pandemic” affects 26 million adults. In many countries, population-based studies have found that 1-2% of people have HF, and similar or higher proportions have been reported in single-center studies.¹ Prevalence is variable across nations, ranging between 1.5-1.9% in North America, 1-2% in Europe, 1-3% in Australia, and as low as 0.13% in Indonesia. Interestingly, reported prevalence of HF in Malaysia and Singapore exceeds global prevalence.^{1,4}

Psoriasis is a disease of chronic inflammation, with a global prevalence of 1-2%, affecting not only the skin but also many other systems.³ The prevalence of psoriasis in Indonesia has not been calculated yet.⁵ The levels of interleukin 17A (IL-17A) and TNF- α , both responsible for inflammation in psoriasis, are also increased in HF. This mechanism is assumed to link both diseases.

Psoriasis

Psoriasis is a common chronic inflammatory disease with a strong genetic component characterized by a systemic immunological response, which is mainly driven by T helper (Th) 1 and 17 lymphocytes.^{6,7} Like other chronic

inflammatory disorders, including rheumatoid arthritis, inflammatory bowel disease, and systemic lupus erythematosus, psoriasis shares inflammatory mechanisms with atherosclerosis and confers an independent risk for various cardiovascular diseases as myocardial infarction.⁸ According to current guidelines, patients with rheumatoid arthritis and other forms of inflammatory arthritis, including psoriatic arthritis, should undergo annual evaluation of cardiovascular risk factors. There is also evidence suggesting that such a recommendation should be extended to patients with psoriasis.⁹

Pathogenesis of Psoriasis and Systemic Inflammation¹⁰

Chronic inflammation of the skin and joints have many common immunopathological features, including genetic predisposition, composition of inflammatory infiltrates, vascular changes, early immune events and proangiogenic similarities. The cellular infiltrate is predominantly perivascular. B lymphocytes are abundant but the contribution of B cells to the pathogenesis is unlikely. T lymphocytes are the most abundant in both skin and joints, with the dominant types being cytotoxic T lymphocyte CTL, T helper 1 (Th1) and T helper 17 (Th17). Neuropeptides (NP) are also involved in proinflammatory pathways. Antigen is presented to naive CD4 in lymph nodes. Emerging lymphocytes migrate preferentially to skin and joints, where the above-mentioned infiltrating T lymphocytes (CD4, CD8) interact with local Antigen Presenting Cell (APC), such as Langerhans cells, myeloid-DC and plasmacytoid-DC, to produce chronic inflammatory conditions. Local re-activated T cells secrete chemokines and cytokines that amplify the inflammatory environment, resulting in the formation of psoriatic plaque, induction of degradation of cartilage and perhaps atherosclerotic plaque. Since the suppressive activity of regulatory cells is decreased in both tissue and blood, lymphocytes show high replicative power. The chronic production of proinflammatory cytokines [interferon gamma (IFN- γ) and tumor necrosis factor (TNF- α)] crucially contributes to the perpetuation of the disease. TNF- α is critically involved in induction of inflammatory degradation

of cartilage and bone. The osteolytic activity is the result of the activation of osteoclasts by the action of IFN- γ .

Diagnosis of Psoriasis¹¹

The diagnosis of psoriasis is primarily clinical. There are different clinical types of psoriasis, the most common being chronic plaque psoriasis, affecting 80% to 90% of patients with psoriasis. The hallmark of classic plaque psoriasis is well-demarcated, symmetric, and erythematous plaques with overlying silvery scales. Plaques are typically located on the scalp, trunk, buttocks, and extremities but can occur anywhere on the body. Patients might demonstrate nail involvement, which can present without concomitant plaques. Active lesions might be itchy or painful. Psoriasis can also present as an isomorphic response, where new lesions develop

on previously normal skin that has sustained trauma or injury. The severity of disease can be helpful in guiding management and is classified as mild, moderate, and severe. Less common variants of psoriasis include inverse psoriasis, pustular psoriasis, guttate psoriasis, erythrodermic psoriasis, and annular psoriasis. These variants can be differentiated from the common plaque type by morphology. Differential diagnoses include atopic dermatitis, contact dermatitis, lichen planus, secondary syphilis, mycosis fungoides, tinea corporis, and pityriasis rosea. Careful observation often yields the diagnosis. For more atypical presentations, a skin biopsy might be helpful.

Heart Failure¹²

Activation of the adrenergic nervous system is an important regulator of cardiac performance during

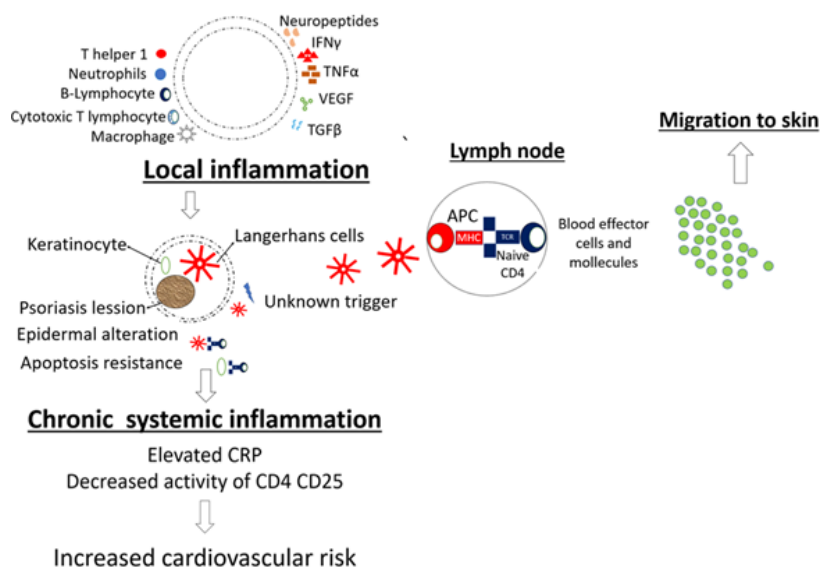


Figure 2 Immunopathogenesis of psoriasis and psoriatic arthritis associated events that worsen the cardiovascular risk profile.

exertion; it increases myocardial contractility and redistributes cardiac output. In acute HF, enhanced contractility resulting from adrenergic activation stimulates the depressed contractility of the failing heart and, by causing vasoconstriction, raises the blood pressure and aids in the perfusion of vital organs. However, prolonged activation of the adrenergic nervous system and of the

reninangiotensin-aldosterone system causes maladaptive remodeling of the ventricles and further myocardial injury, thereby initiating a vicious cycle in what has become known as the neurohumoral model of HF. In HF, there is elevation of C-reactive protein (CRP). The concentration of a number of pro-inflammatory cytokines, such as TNF- α and IL-6, have also been shown to increase in HF. In

elderly subjects without HF, abnormal elevation in three inflammatory markers (CRP, tumor necrosis factor alpha, and IL-6) was reported to be associated with a 4-fold increase in the risk of HF. The level of these biomarkers was correlated with the severity of HF; they appeared to be important predictors of the outcome.

Inflammation in HF and Psoriasis

The association of cardiomyopathy and psoriasis requires an insight into the possible pathogenetic links of these two diseases. The pathogenesis of psoriasis is characterized by an increased antigen presentation process, increased T lymphocyte activity, and upregulation of type 1 helper T cytokines.^{12,13} The etiology of psoriasis is unknown and is thought to be a combination of genetic, immune and environmental factors. One third of psoriatic patients has a first-degree relative with psoriasis, and the incidence in monozygotic twins is estimated to be 70% compared to dizygotic twins, where it is 25%. A number of genes related to psoriasis have been identified, but their role and function is not clear.^{13,14}

HF is a systemic disease that has many etiologies including genetic factors and immune factors. Immune activation leads to production and release of pro-inflammatory cytokines, activation of the complement system, and production of autoantibodies. Gene expression of chemokines is upregulated in T cells of patients with HF. This activates the immune system through binding to the tumor necrosis factor superfamily and their receptors. The inflammatory cytokines IFN- γ and IL-18 have a similar pattern in ischemic and idiopathic cardiomyopathy.¹³ T helper 1 and T helper 2 cytokine imbalance has also been identified to play a role in HF pathogenesis.¹²

IL-17A is a pro-inflammatory cytokine produced mainly by Th17 lymphocytes, but also by natural killer T cells, gd T cells, cytotoxic CD8⁺ T cells, and neutrophils.¹³ Multiple lines of evidence from animal and human studies suggest crucial roles of IL-17A and its receptor interleukin-17 receptor A (IL-17RA) in ischemic heart disease.¹³ Similarly, animal studies have provided evidence that IL-17A

plays an important role in dilated cardiomyopathy (DCM). Previous studies have identified Th17/Treg imbalance with upregulation of IL-17A that plays an important role in HF pathogenesis.¹⁵ Recent studies have identified single nucleotide polymorphisms (SNPs) in IL-17A/IL-17RA axis that contribute to both psoriasis and HF. A recent study demonstrated associations of rs8193037 in the promoter of IL17A with the risk of congestive HF, and of rs4819554 in the promoter of IL17RA with the risk of cardiovascular mortality in patients with congestive HF.¹⁵

Circulating levels of proinflammatory cytokines such as TNF- α , soluble TNF receptors (sTNF-R1 and sTNF-R2), IL-6 and sCD14 have been shown to be independent predictors of mortality in patients with advanced HF.¹³ Several published studies have investigated the association between the -308G/A (rs1800629) polymorphism in the tumor necrosis factor- α (TNF- α) gene and the risk of dilated cardiomyopathy (DCM). However, the TNF- α gene polymorphism has a controversial role in the pathogenesis of DCM among different populations. There may be a moderate association between TNF- α rs1800629 polymorphism and DCM susceptibility in populations studied; however, TNF- α rs1800629 polymorphism was significantly associated with the susceptibility of DCM for Asians, which indicates that such associations may be different between ethnicities.¹⁵

Association Between Clinical Manifestation of HF and Severity of Psoriasis⁹

A few observational studies have previously demonstrated an increased risk of HF in patients with psoriasis while others have found no such association.¹⁰ These conflicting results may be explained, in part, by methodological issues (e.g. differences in population size and adjustments for important covariates). Moreover, previous studies are mainly based on selected populations and so the impact of the severity of psoriasis on the risk of HF has not been fully investigated. However, one study, which is by far the largest to date, add to the evidence provided in the earlier studies demonstrating an association between psoriasis and HF with an increased risk of new-

Table 1 Case reports of psoriasis patients with heart failure.

<i>Anupam Prakash</i> ¹⁴	25-year-old man with generalized erythematous lesions for 4 months	Psoriasis, DCM, Anasarca
<i>Matt Chua</i> ¹⁶	38-year-old male with psoriasis and alcohol abuse	Psoriasis, septic shock/cardiogenic shock, high output HF
<i>Pietrzak A</i> ¹⁷	80-year-old male with DM, HTN, and ischemic heart disease	Psoriasis, ADHF, inflammation-related cardiomyopathy, conduction abnormality, hypertension, ischaemic heart disease

onset HF with increased severity of psoriasis. The association remains strong even after adjustments for comorbidities, cardiovascular medications and socioeconomic status. These results support the proposition of independent effects of psoriasis on the risk of HF mediated through inflammatory mechanisms. It is thus possible that even asymptomatic patients with psoriasis are at high risk of HF with/without structural heart disease. In the study, the overall incidence rates of new-onset HF were 2.82, 4.22 and 4.70 per 1000 person-years for the reference population, mild psoriasis, and severe psoriasis, respectively. This concludes that severity of psoriasis led to increased risk of new-onset HF. Several case reports about HF in psoriasis patients have been published. They are listed in Table 1.

Despite being diagnosed with heart disease earlier, the first patient only complained of dyspnea at the age of 51 and had mitral valve replacement shortly. Two years before symptom exacerbation, he had psoriasis on his legs, arms, and elbow. He was also hospitalized in 2012, 2014 and 2016 due to HF exacerbation. By that time, the psoriasis was still uncontrolled.

The second patient was hospitalized due to HF 6 years ago in NCCHK. He did not seek medical treatment afterwards. He was also obese and had hypertension and dyslipidemia. One month prior to admission, he experienced dyspnea and is now treated for full-blown HF. Also, three months before admission, he experienced psoriasis for the first time and was not treated.

In both patients, untreated psoriasis led to HF exacerbation. Chronic systemic inflammation in psoriasis, if left untreated, will amplify the

inflammatory state in HF patients thus leading to the exacerbation of the HF symptoms.

Patients with psoriasis carry an excessive risk of atrial fibrillation (AF). The differences between the maximum (Pmax) and the minimum (Pmin) P-wave duration on ECG are defined as P-wave dispersion (PWD). Prolongation of PWD is an independent risk factor for the development of AF. Atrial conduction of sinus impulses was shown to be impaired in patients with psoriasis vulgaris. It was more prominent in patients with severe disease, high disease activity score and hsCRP. Physicians caring for patients with psoriasis vulgaris should screen them for AF development.^{11,18} In the first patient, there is not any abnormality of PWD on ECG. However, the second patient had atrial fibrillation but due to unavailability of precious electrocardiography, his PWD during sinus rhythm could not be evaluated.

CONCLUSION

Psoriasis is a risk factor for the deterioration of HF due to uncontrolled inflammation factors. It is important to evaluate the disease activity of psoriasis to control the HF.

Conflicts of Interest: The authors declare no conflicts of interest or sources of funding.

REFERENCES

1. Ponikowski P, Anker SD, AlHabib KF, Cowie MR, Force TL, Hu S, et al. Heart failure: preventing disease and death worldwide. *ESC Hear Fail.* 2014 Sep;1(1):4–25.
2. Maharani A, Sujarwoto, Praveen D, Oceandy D, Tampubolon G, Patel A. Cardiovascular disease risk factor prevalence and

- estimated 10-year cardiovascular risk scores in Indonesia: The SMARThealth Extend study. Musinguzi G, editor. PLoS One. 2019 Apr 30;14(4):e0215219.
3. Gudjonsson JE, Elder JT. Psoriasis: epidemiology. Clin Dermatol. 2007 Nov;25(6):535–46.
4. Siswanto BB. Heart Failure in Indonesia. J Card Fail. 2013 Oct;19(10):S108.
5. Nofal A, Al-Makhzangy I, Attwa E, Nassar A, Abdalmoati A. Vascular endothelial growth factor in psoriasis: an indicator of disease severity and control. J Eur Acad Dermatology Venereol. 2009 Jul;23(7): 803–6.
6. Davidovici BB, Sattar N, Jörg PC, Puig L, Emery P, Barker JN, et al. Psoriasis and systemic inflammatory diseases: Potential mechanistic links between skin disease and co-morbid conditions. Journal of Investigative Dermatology. 2010.
7. Lowes MA, Kikuchi T, Fuentes-Duculan J, Cardinale I, Zaba LC, Haider AS, et al. Psoriasis vulgaris lesions contain discrete populations of Th1 and Th17 T cells. J Invest Dermatol. 2008;
8. Samarasekera EJ, Neilson JM, Warren RB, Parnham J, Smith CH. Incidence of cardiovascular disease in individuals with psoriasis: A systematic review and meta-analysis. J Invest Dermatol. 2013;
9. Khalid U, Ahlehoff O, Gislason GH, Kristensen SL, Skov L, Torp-Pedersen C, et al. Psoriasis and risk of heart failure: A nationwide cohort study. Eur J Heart Fail. 2014;
10. Kölliker Frers RA, Bisioendial RJ, Montoya SF, Kerzberg E, Castilla R, Tak PP, et al. Psoriasis and cardiovascular risk: Immune-mediated crosstalk between metabolic, vascular and autoimmune inflammation. IJC Metab Endocr. 2015 Mar;6:43–54.
11. Kim WB, Jerome D, Yeung J. Diagnosis and management of psoriasis. Can Fam Physician. 2017 Apr;63(4):278–85.
12. Braunwald E. Heart Failure. JACC Hear Fail. 2013 Feb;1(1):1–20.
13. Sandip C, Tan L, Huang J, Li Q, Ni L, Cianflone K, et al. Common variants in IL-17A/IL-17RA axis contribute to predisposition to and progression of congestive heart failure. Medicine (Baltimore). 2016 Jul;95(27):e4105.
14. Prakash A, Deepshikha. Psoriasis and cardiomyopathy: An intriguing association. Indian J Dermatol. 2010;
15. Zhang Y, Cao Y, Xin L, Gao N, Liu B. Association between rs1800629 polymorphism in tumor necrosis factor- α gene and dilated cardiomyopathy susceptibility. Medicine (Baltimore). 2018 Dec;97(50):e13386.
16. Chua MJ. High output heart failure secondary to psoriasis. J Am Coll Cardiol. 2015 Mar;65(10):A574.
17. Pietrzak A, Brzozowska A, Lotti T, Mosiewicz J, Wysokiński A, Mieczkowska J, et al. Future diagnosis, today's treatment - cardiomyopathy in the course of psoriasis: a case report. Dermatol Ther. 26(6):489–92.
18. Bacaksiz A, Erdogan E, Tasal A, Vatankulu MA, Kul S, Sevgili E, et al. Electrocardiographic P-wave characteristics in patients with psoriasis vulgaris. Ups J Med Sci. 2013 Mar 15;118(1):35–41.