

UC Davis

Dermatology Online Journal

Title

Disseminated punctate keratoderma: a rare case report and review of the literature

Permalink

<https://escholarship.org/uc/item/8jf1g7ff>

Journal

Dermatology Online Journal, 23(3)

Authors

Asemota, Eseosa
Markova, Alina
Ho, Jonathan
et al.

Publication Date

2017

DOI

10.5070/D3233034284

Copyright Information

Copyright 2017 by the author(s). This work is made available under the terms of a Creative Commons Attribution-NonCommercial-NoDerivatives License, available at <https://creativecommons.org/licenses/by-nc-nd/4.0/>

Peer reviewed

Disseminated punctate keratoderma: a rare case report and review of the literature

Eseosa Asemota MD, MPH¹, Alina Markova MD², Jonathan Ho MD², Michael K. Lichtman MD¹

Affiliations: ¹Boston University School of Medicine, Boston, Massachusetts, ²Department of Dermatology, Boston University, Boston, Massachusetts

Corresponding Author: Michael K. Lichtman, Boston University School of Medicine, 609 Albany Street, #207, Boston, MA 02118, Email: mkl20@bu.edu

Abstract

We report a rare case of a 53-year-old woman presenting with diffuse, late-onset disseminated hyperkeratotic papules. Biopsy showed massive hyperkeratosis overlying a crateriform epidermal depression and hypergranulosis with mild epidermal hyperplasia. There was no parakeratosis, cornoid lamella, or dyskeratosis. Based on the clinical findings and histopathological features, a diagnosis of disseminated punctate keratoderma was made. This is a rare subtype of palmoplantar keratoderma, which has a putative increased risk of malignancy. This case report emphasizes the importance of identifying the clinical and histological presentation of this rare condition; referral of the patient for age-appropriate malignancy screening is appropriate. We also present a concise review of treatment options.

Keywords: palmoplantar keratodermas (PPK), punctate palmoplantar keratoderma (PPPK)

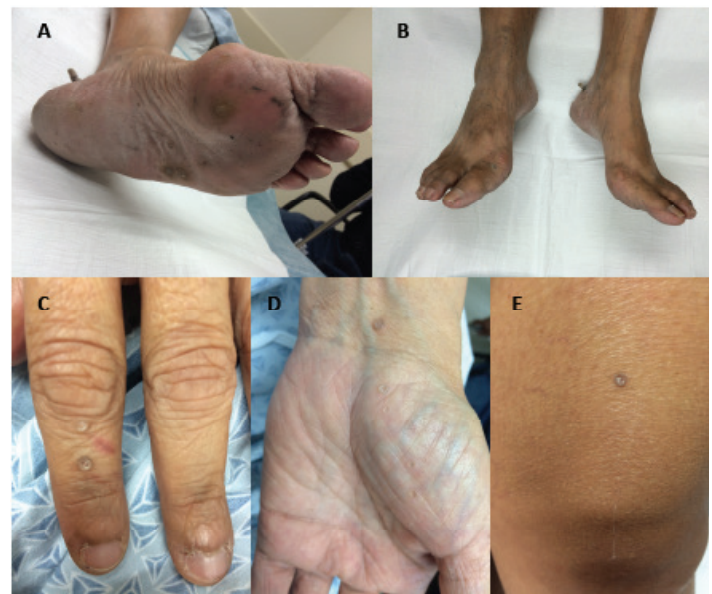Introduction

Palmoplantar keratodermas (PPK) are a heterogeneous group of disorders characterized by abnormal palmoplantar keratinization, which rarely extends onto the dorsal hands and feet [1]. Based on the clinical pattern of involvement, PPKs are classified into diffuse PPK (affecting most of the palms and soles), focal PPK (mainly involving pressure areas), and punctate palmoplantar keratoderma (resulting in tiny papules and plaques on the palms and soles) (**Table 1**). Several clinical variants of punctate palmoplantar keratoderma (PPPK) have been recognized: Brauer-

Buschke-Fischer keratoderma (an autosomal dominant with variable penetrance, characterized clinically by multiple, punctate keratoses over the palmoplantar surfaces), punctate prokeratotic keratoderma, focal acral hyperkeratosis (also known as acrokeratoelastoidosis lichenoides), and unilateral linear punctate keratoderma [1-3]. To our knowledge, we report the second case of disseminated punctate palmoplantar keratoderma and review the literature of this rare entity [4] (**Table 2**).

Case Synopsis

A 53-year-old woman presented with a 13-year history of asymptomatic papules on hands, feet,



keratoderma on the following locations. 1A: Left Plantar Foot, 1B: Bilateral Dorsal Feet and Pretibial Areas, 1C: Left Dorsal Hand, 1D: Left Palm, 1E: Right Anterior Thigh.

Table 1: Classification of Palmoplantar keratoderma [11-24]

	Definition	Known subtypes and genetic abnormality
Diffuse hereditary palmoplantar keratodermas	Diffuse hereditary PPK affect most of the palms and soles and are caused by a genetic abnormality.	Unna-Thost type (autosomal dominant) Verner's type (autosomal dominant) Mal de Meleda type (autosomal dominant or recessive) Huriez syndrome (autosomal dominant) Olmsted syndrome (unknown inheritance pattern) Vohwinkel syndrome (autosomal dominant) PPK with sensorineural deafness (mitochondrial inheritance) Bart-Pumphrey syndrome (autosomal dominant) Hidrotic <u>ectodermal dysplasia</u> (autosomal dominant) Papillon-Lefevre syndrome (autosomal recessive) Diffuse PPK with woolly hair and arrhythmogenic cardiomyopathy (autosomal recessive)
Focal hereditary palmoplantar keratodermas	Focal keratodermas are <u>palmoplantar keratodermas</u> that involve only some areas of the palms or soles, usually over pressure points. Some types are associated with abnormalities in organs other than the skin.	PPK striata/areata type (autosomal dominant) Hereditary painful callosities (autosomal dominant) Howell-Evans syndrome or tylosis (autosomal dominant) Richner-Hanhart syndrome (autosomal recessive) <u>Pachyonychia congenita</u> (autosomal dominant) Striate PPK with woolly hair and dilated cardiomyopathy (autosomal recessive)
Punctate-type palmoplantar keratoderma	Punctuate keratodermas result in tiny bumps of thickened skin on the palms and soles and usually appears in late childhood or early adulthood.	Punctate keratoderma (autosomal dominant) Filiform keratoderma (autosomal dominant, autosomal recessive) Marginal keratoderma (autosomal dominant)
Acquired keratoderma	Acquired keratoderma are keratodermas that are NOT inherited as a primary genetic condition. They may arise in association with a variety of different skin and internal conditions.	Keratoderma climactericum (women of menopausal age) Paraneoplastic Keratoderma Keratoderma due to inflammatory and reactive dermatoses Aquagenic keratoderma PPK caused by infections Drug-related PPK Systemic disease-associated PPK Idiopathic PPK

Based on the extent of the skin involvement, palmoplantar keratoderma can be described as transgradient or non-transgradient.

Non-transgradient keratodermas do not extend beyond the palms on the hands and the sole on the feet.

Transgradient keratodermas extend beyond the palms and soles onto the back of the hands and feet and in some cases up the wrists and ankles

forearms, thighs, and buttocks. She began to observe the lesions 13 years prior to presentation, but was not sure if they had been present prior to that. The lesions had gradually increased in number and enlarged over the years. She had no history of arsenic exposure and no family members with a similar eruption. Laboratory evaluation including a comprehensive metabolic panel was within normal limits; HIV Ag/Ab combined assay was negative and a serum arsenic level was normal at <3mcg/L [normal

<23 mcg/L; >100mcg/L suggestive of acute/chronic arsenic exposure].

On physical examination, there were numerous 0.2 – 0.4 cm hyperkeratotic discoid depressed papules on the dorsal and plantar aspects of her hands and feet. Similar papules were seen on the forearms, thighs, buttocks, and lower legs. There were no associated nail findings (**Figure 1**).

Table 2: Comparison between the two reported cases of disseminated PPPK.

Previous published case [4]	Current case report
Presented in the second decade of life	Presented in the fourth decade of life
Multiple asymptomatic lesions on both upper limbs, lower limbs, and trunk	Multiple asymptomatic lesions on both upper limbs, lower limbs, and trunk
Had no family history of similar condition	Had no family history of similar condition
Occurred in a Lebanese woman (probably with Fitzpatrick type 3 or 4)	Occurred in an African American woman (probably with Fitzpatrick type 5 or 6)

Hematoxylin and eosin (H&E) staining of the skin punch biopsy specimen of a punctate papule from the right palm showed massive orthokeratosis overlying a crateriform epidermal depression and hypergranulosis with mild epidermal hyperplasia. No parakeratosis, cornoid lamella, or dyskeratotic keratinocytes were noted (**Figure 2**).

Based on the clinical findings and histopathological features, a diagnosis of punctate palmoplantar keratoderma was made. The patient was up to date on her age-appropriate malignancy screening.

Case Discussion

Punctate palmoplantar keratodermas are a rare subtype of PPK, with an estimated prevalence rate of about 1.17 per 100,000 [1, 2]. PPPK lesions typically appear within the first two decades of life, but can occur in the fourth or fifth decade [5]. Males are affected more often than females [3]. Although disseminated variants of the punctate porokeratotic keratoderma have been reported, non-porokeratotic punctate PPPK with dissemination has only been previously described once in the literature [4].

The etiology of PPPK is postulated to be a dual influence of genetic and environmental factors. Although there is a strong genetic and familial association, some patients with PPPK have no apparent family history of the condition. Sporadic cases may be idiopathic or related to systemic disease, malignancy, malnutrition, medications, infections, UV irradiation, or immunosuppression [2, 5-7].

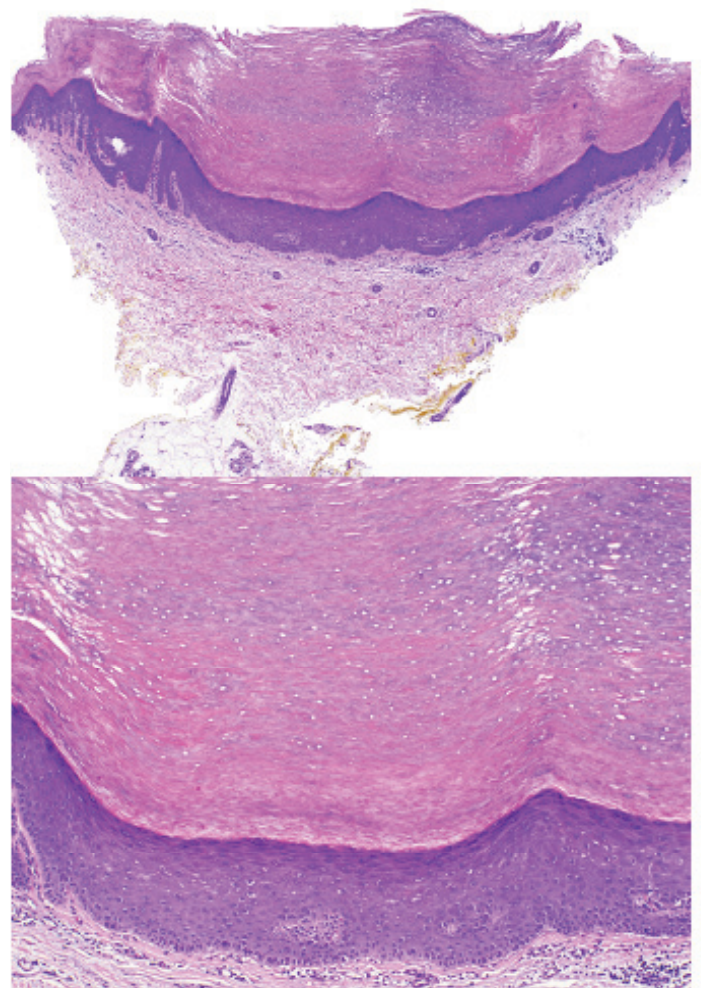


Figure 2. Histology. 2A: Punctate palmoplantar keratoderma. A) Note marked hyperorthokeratosis overlying an epidermal depression, H&E, 20x. B) Hypergranulosis and mild epidermal hyperplasia, H&E, 100x. (C) The conspicuous lack of parakeratosis necrotic keratinocytes or an interruption of the granular layer (features of a cornoid lamella) argues against a diagnosis of punctate porokeratosis, H&E, 200x and, (D) is characteristic of punctate palmoplantar keratoderma, H&E, 200x.

The Brauer-Buschke-Fischer keratoderma subtype has an autosomal dominant pattern of inheritance. Loss-of-function mutations in Alpha- And Gamma-Adaptin Binding (AAGAB) protein, with variable penetrance have been reported as the genetic basis for the Brauer-Buschke-Fischer type PPPK [8]. Trauma is hypothesized to trigger the abnormal proliferation of the epidermis in genetically predisposed subjects [9]. The punctate porokeratotic subtype has an unclear etiology, but it involves disordered keratinization. Keratins 6 and 16, typically present only in proliferating keratinocytes in stratum spinosum, are present in these lesions, indicating a hyperproliferative process. It is considered by some to be a subtype of porokeratosis, because the parakeratotic columns with subjacent interruption of the granular layer and individually necrotic keratinocytes seen on biopsy resemble the cornoid lamellae of porokeratosis. Although punctate porokeratotic keratoderma is typically limited to the palms and soles, a disseminated form is recognized [3, 6]. Unilateral linear punctate palmoplantar keratoderma is extremely rare [1]. Acrokeratoelastoidosis lichenoides typically presents with polygonal or crateriform discrete papules on the lateral aspect of palms and soles [7].

Clinically, PPPKs present as tiny, hyperkeratotic papules and plaques, with central depressions containing keratotic plugs, located on the palmoplantar surface [5]. The papules have a tendency to coalesce. PPPK also has a common clinical pattern of localizing to the palmar creases, which is seen especially in black persons. Nail abnormalities in the form of longitudinal ridging, onychorrhexis, trachyonychia, subungual hyperkeratosis, onycholysis, pitting, and notching may be seen [3]. Although most patients with PPPK do not have an underlying genetic disorder, they may have an increased risk of malignancy, especially gastrointestinal and pulmonary tumors [1]. Owing to the association of PPPK with malignancies, routine cancer screening and regular follow-up should be performed. Spastic paralysis and ankylosing spondylitis have also been documented in patients with PPPK [1].

Histopathologic examination with H&E staining typically demonstrates focal hyperorthokeratosis overlying an epidermal invagination, hypergranulosis, mild epidermal hyperplasia, and minimal dermal

perivascular lymphocytic inflammation. Parakeratosis and other features suggestive of a cornoid lamella must be absent in order to diagnose PPPK.

Important conditions in the differential diagnosis include arsenical keratosis, porokeratosis, and verruca vulgaris [5]. In this case, arsenical keratosis was ruled out by negative history of exposure to arsenic, undetectable arsenic serum level, and clinicopathologic correlation. Porokeratoses can be distinguished clinically by the presence of a thin, raised, scaly border, corresponding to the histologic cornoid lamella as discussed above [6]. Verrucae vulgaris can be differentiated from PPPK by the lack of characteristic histology (e.g., presence of koilocytes in verrucae). In addition, verrucae bleed or exhibit punctate vessels with paring whereas PPPK do not.

Symptomatic management of PPPK includes use of saltwater soaks, paring, and emollients to soften the lesions. Medical therapies include topical vitamin D, topical keratolytics (such as urea and salicylic acid, which regulate keratinocyte differentiation), topical corticosteroids, topical retinoids, and systemic retinoids [10]. Other less utilized therapies include psoralens and ultraviolet A (PUVA), retinoid-PUVA, and intravenous 5-FU. If medical therapy fails, reconstructive surgery can be considered, with total excision of the hyperkeratotic skin, followed by grafting [1, 3].

In summary, we present a rare case of PPPK manifesting as diffuse, late-onset hyperkeratotic papules that extended not only onto the dorsal hands and feet, but also onto the upper and lower extremities. Given the putative increased risk of malignancy in this subtype of PPPK, it is important to identify this clinical presentation and refer the patient for age-appropriate malignancy screening.

References

1. Sharma S, Barman KD, Garg VK, Jain S. Unilateral linear punctate palmoplantar keratoderma. *Indian J Dermatol Venereol Leprol*. 2012 Feb;78(1):85–8. [PMID: 22199066]
2. Oztas P, Alli N, Polat M, Dagdelen S, Ustün H, Artüz F, et al. Punctate palmoplantar keratoderma (Brauer-Buschke-Fischer syndrome). *Am J Clin Dermatol*. 2007;8(2):113–6. [PMID:17428117]
3. Alikhan A, Burns T, Zargari O. Punctate porokeratotic keratoderma. *Dermatol Online J*. 2010;16(1):13. [PMID: 20137755]
4. Mutasim D, Kurban AK. Disseminate palmoplantar keratoderma with truncal lesions. *Dermatologica*. 1984;168(6):296–9.

- [PMID:6235138]
5. Zur R, Shapero H, Shapero J. Dermacase. Can you identify this condition? Punctate palmoplantar keratoderma. *Can Fam Physician*. 2013 Jul;59(7):748, 752. [PMID: 23851542]
 6. Irisawa R, Yamazaki M, Yamamoto T, Tsuboi R. A case of prokeratosis plantaris palmaris et disseminata and literature review. *Dermatol Online J*. 2012 Aug;18(8):5. [PMID: 22948055]
 7. Meziane M, Senouci K, Ouidane Y, Chraïbi R, Marcil T, Mansouri F, et al. Acrokeratoelastoidosis. *Dermatol Online J*. 2008;14(9):11. [PMID: 19061593]
 8. Pohler E, Mamai O, Hirst J, Zamiri M, Horn H, Nomura T, et al. Haploinsufficiency for AAGAB causes clinically heterogeneous forms of punctate palmoplantar keratoderma. *Nat Genet*. 2012 Nov;44(11):1272–6. [PMID: 23064416]
 9. Raone B, Raboni R, Patrizi A. Alitretinoin: a new treatment option for hereditary punctate palmoplantar keratoderma (Brauer-Buschke-Fischer syndrome). *J Am Acad Dermatol*. 2014 Aug;71(2):e48–9. [PMID: 25037811]
 10. Gupta R, Mehta S, Pandhi D, Singal A. Hereditary Punctate Palmoplantar Keratoderma (PPK) (Brauer-Buschke-Fischer Syndrome). *J Dermatol*. 2004 May;31(5):398–402. [PMID: 15187307]
 11. Yang JM, Lee S, Kang HJ, Lee JH, Yeo UC, Son IY, et al. Mutations in the 1A rod domain segment of the keratin 9 gene in epidermolytic palmoplantar keratoderma. *Acta Derm Venereol*. 1998 Nov. 78(6):412–6. [PMID: 9833037]
 12. Has C, Technau-Hafsi K. Palmoplantar keratodermas: clinical and genetic aspects. *J Dtsch Dermatol Ges*. 2016 Feb. 14 (2):123–39. [PMID: 26819106]
 13. Rajashekhar N, Moideen R. Palmoplantar keratoderma--Mal de Meleda syndrome. *Int J Dermatol*. 1997 Nov. 36(11):854–6. [PMID: 9427080]
 14. Kabashima K, Sakabe J, Yamada Y, Tokura Y. "Nagashima-type" keratosis as a novel entity in the palmoplantar keratoderma category. *Arch Dermatol*. 2008 Mar. 144(3):375–9. [PMID: 18347294]
 15. Chen L, Lin H, Sheu H, Chao S. G59A mutation in the GJB2 gene in a Taiwanese family with knuckle pads, palmoplantar keratoderma and sensorineural hearing loss. *Clin Exp Dermatol*. 2011 Apr. 37(3):300–1. [PMID: 22007731]
 16. Duchatelet S, Hovnanian A. Olmsted syndrome: clinical, molecular and therapeutic aspects. *Orphanet J Rare Dis*. 2015 Mar 17. 10:33. [PMID: 25886873]
 17. Nakajima K, Nakano H, Takiyoshi N, Rokunohe A, Ikenaga S, Aizu T, et al. Papillon-Lefèvre syndrome and malignant melanoma. A high incidence of melanoma development in Japanese palmoplantar keratoderma patients. *Dermatology*. 2008. 217(1):58–62. [PMID: 18401176]
 18. Erken H, Yariz KO, Duman D, Kaya CT, Sayin T, Heper AO, et al. Cardiomyopathy with alopecia and palmoplantar keratoderma (CAPK) is caused by a JUP mutation. *Br J Dermatol*. 2011 Oct. 165 (4):917–21. [PMID: 21668431]
 19. Kubo A, Oura Y, Hirano T, Aoyama Y, Sato S, Nakamura K, et al. Collapse of the keratin filament network through the expression of mutant keratin 6c observed in a case of focal plantar keratoderma. *J Dermatol*. 2013 Jul. 40(7):553–7. [PMID: 23662636]
 20. Sakiyama T, Kubo A. Hereditary palmoplantar keratoderma "clinical and genetic differential diagnosis". *J Dermatol*. 2016 Mar. 43 (3):264–74. [PMID: 26945534]
 21. Blaydon DC, Etheridge SL, Risk JM, Hennies HC, Gay LJ, Carroll R, et al. RHBDF2 mutations are associated with tylosis, a familial esophageal cancer syndrome. *Am J Hum Genet*. 2012 Feb 10. 90 (2):340–6. [PMID: 22265016]
 22. Lucker GP, Steijlen PM. Pachyonychia congenita tarda. *Clin Exp Dermatol*. 1995 May. 20(3):226–9. [PMID: 7671418]
 23. Oztas P, Alli N, Polat M, Dagdelen S, Ustün H, Artüz F, et al. Punctate palmoplantar keratoderma (Brauer-Buschke-Fischer syndrome). *Am J Clin Dermatol*. 2007. 8(2):113–6. [PMID: 17428117]
 24. Bardazzi F, Savoia F, Dika E, Tabanelli M, Giacomini F. Acquired aquagenic keratoderma. *Pediatr Dermatol*. 2007 Mar-Apr. 24(2):197–8. [PMID: 17461826]
 25. Lim D, Rademaker M, Gardner D, Oakley A. Palmoplantar keratoderma: An adverse reaction to influenza vaccination. *Australas J Dermatol*. 2011 Nov. 52(4):298–300. [PMID: 22070708]