

# UC San Diego

## UC San Diego Previously Published Works

**Title**

Neural representations of skilled movement

**Permalink**

<https://escholarship.org/uc/item/8j896317>

**Journal**

Brain, 123(11)

**ISSN**

0006-8950

**Authors**

Haaland, Kathleen Y  
Harrington, Deborah L  
Knight, Robert T

**Publication Date**

2000-11-01

**DOI**

10.1093/brain/123.11.2306

Peer reviewed

# Neural representations of skilled movement

Kathleen Y. Haaland,<sup>1,2</sup> Deborah L. Harrington<sup>1</sup> and Robert T. Knight<sup>3</sup>

<sup>1</sup>Psychology and Research Services, Veterans Affairs Medical Center and Departments of Neurology and Psychology and <sup>2</sup>Department of Psychiatry, University of New Mexico, Albuquerque, and <sup>3</sup>Department of Psychology, University of California, Berkeley, California, USA

Correspondence to: Kathleen Y. Haaland, Psychology Service (116B), Veterans Affairs Medical Center, 1501 San Pedro SE, Albuquerque, NM 87108, USA  
E-mail: khaaland@unm.edu

## Summary

The frontal and parietal cortex are intimately involved in the representation of goal-directed movements, but the crucial neuroanatomical sites are not well established in humans. In order to identify these sites more precisely, we studied stroke patients who had the classic syndrome of ideomotor limb apraxia, which disrupts goal-directed movements, such as writing or brushing teeth. Patients with and without limb apraxia were identified by assessing errors imitating gestures and specifying a cut-off for

apraxia relative to a normal control group. We then used MRI or CT for lesion localization and compared areas of overlap in those patients with and without limb apraxia. Patients with ideomotor limb apraxia had damage lateralized to a left hemispheric network involving the middle frontal gyrus and intraparietal sulcus region. Thus, the results revealed that discrete areas in the left hemisphere of humans are critical for control of complex goal-directed movements.

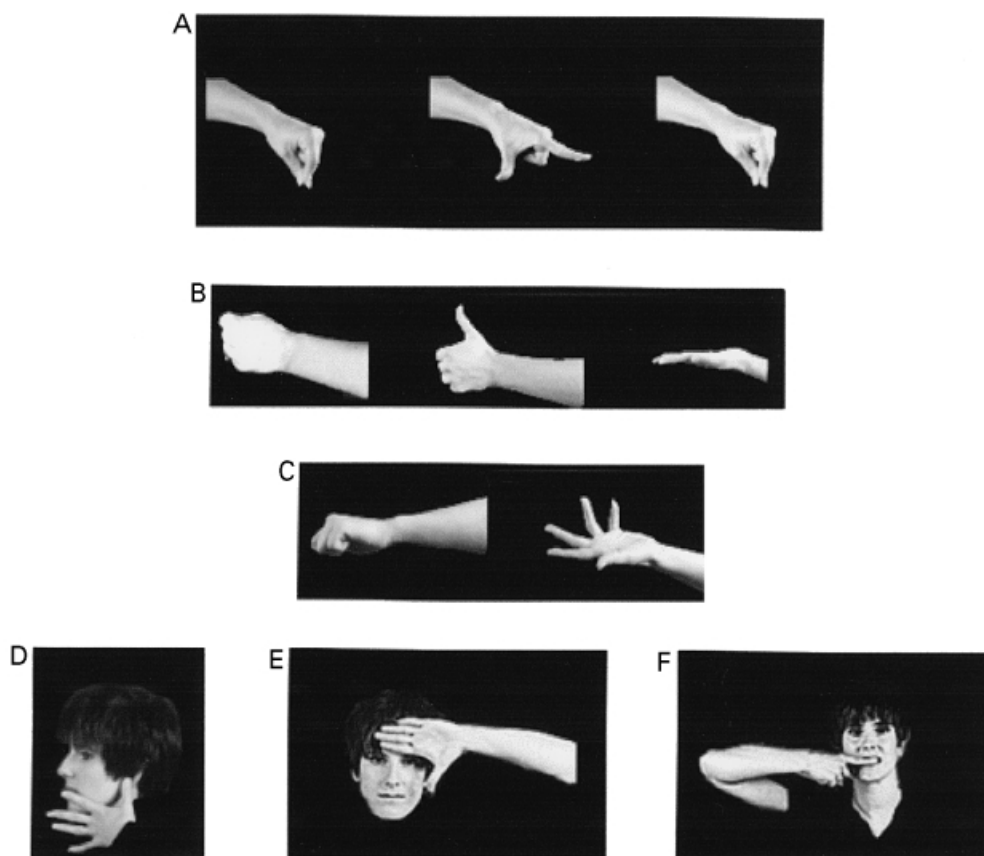
**Keywords:** movement; brain damage; frontal lobes; parietal lobes; limb apraxia

## Introduction

The neural systems essential for representing highly skilled movements in humans are not well understood. Research in monkeys and humans has emphasized the importance of the parietal and frontal cortex in a variety of cognitive-motor functions including the storage and retrieval of representations that specify 'how' a movement is performed (e.g. hand shape, direction, speed) (Goodale and Milner, 1992; Gallese *et al.*, 1994; Jeannerod, 1997; Kalaska *et al.*, 1997; Rizzolatti *et al.*, 1998). Multiple parallel frontoparietal circuits are thought to support the computations necessary for translating an action goal into movement by integrating sensory input with central representations of movement based upon prior experience. However, knowledge of the behavioural and the neural underpinnings of movement representations has been derived largely from investigations of reaching and grasping objects in single human patients and in monkeys. In order to assess more broadly the importance of frontoparietal circuits in skilled movement, it is essential to examine deficits in groups of patients with focal lesions and to examine the role these systems play in representing more complex actions, such as hand gestures, which may depend on both common and distinct, cognitive mechanisms.

We compared the areas of common damage between stroke patients with and without spatiotemporal deficits in gesture imitation, which are characteristic of ideomotor limb apraxia. To identify discrete areas of common damage in each group we used a computerized method (Frey *et al.*, 1987) to

reconstruct lesions traced from MRIs. This method has been shown to identify neural networks underlying other disorders (Harrington *et al.*, 1998). It should be more sensitive to subtle differences in areas of brain damage than methods used previously to examine the neuroanatomical correlates of ideomotor limb apraxia (Basso *et al.*, 1980; De Renzi *et al.*, 1983; Kertesz and Ferro, 1984; Alexander *et al.*, 1992; Roy *et al.*, 1998) because it specifies the degree of common damage quantitatively in very small areas of the brain (e.g. part of premotor cortex on the middle frontal gyrus). We predicted that patients with ideomotor limb apraxia would demonstrate greater damage to the frontal or parietal cortex relative to patients without limb apraxia because the frontal and parietal cortex is involved in reaching and grasping movements, and gesture imitation depends upon some of the same cognitive mechanisms as reaching and grasping movements. This prediction is consistent with other work relating ideomotor limb apraxia to deficits in planning and sequencing responses (Harrington and Haaland, 1992), which are dependent upon the left inferior parietal lobe (Harrington *et al.*, 2000), and to deficits in selecting and retrieving motor representations (Heilman *et al.*, 1982), which have been linked to the left frontal lobe (Schluter *et al.*, 1998). Additionally, the spatiotemporal errors made by patients with ideomotor limb apraxia are similar to those seen with reaching and grasping. For instance, patients pantomiming carving a turkey use jerky vertical movements rather than smooth horizontal movements



**Fig. 1** Examples of errors made by patients with ideomotor limb apraxia. (A) Hand position and movement errors when imitating a writing movement. The patient incorrectly performs sequential oppositions of the thumb and fingers. (B) The examiner's demonstration of how to flip a coin. (C) Hand orientation and hand position errors when the patient imitates flipping a coin. (D) Hand position error characterized by opening hand when movement requires placing the index finger of fist on ear. (E) Hand orientation error when patient imitates a salute. (F) Body-part-as-object substitution error when imitating brushing teeth. The patient uses the index finger as the toothbrush rather than imitating holding the toothbrush.

(Poizner *et al.*, 1998). Examples of the spatial errors made by our apraxic patients when they were asked to imitate movements (e.g. write, brush teeth, salute) are shown in Fig. 1 and include errors in internal hand configuration, hand orientation and body-part-as-object errors.

## Methods

### *Lesion reconstruction*

MRIs (Siemens or Picker 1.5 T machines) were obtained in all stroke patients unless there were medical contraindications. In those cases CTs (Siemens or Picker machines) were obtained at least 3 months after stroke. CT slice thickness was 10 mm with no gap between slices, and MRI slice thickness was 5 mm with a slice gap of 1.5 or 2 mm. The neurologist (R.T.K.), blinded to the apraxic status of the patients, drew the area of damage for each patient on 11 horizontal sections (De Armond *et al.*, 1989). These tracings were retraced into a computer program (Frey *et al.*, 1987), which allowed us to overlap separately the areas of

damage in the apraxic and non-apraxic patients (see Fig. 3) and calculate lesion volume. In order to facilitate localization, patients were separated into three groups based upon whether damage was anterior, posterior, or anterior and posterior to the central sulcus.

### *Subjects and procedures*

We studied 41 stroke patients with damage to the left hemisphere of the brain (38 middle cerebral artery territory and three posterior cerebral artery territory), 37 with damage to the right hemisphere (33 middle cerebral artery territory, three posterior cerebral artery territory, and one anterior cerebral artery territory), and 75 non-brain damaged control subjects. All were right handed, and consent from all subjects was obtained according to the Declaration of Helsinki. The Institutional Review Boards of the Veterans Affairs Medical Center and University of New Mexico approved this research.

Limb apraxia was assessed by asking patients and normal control subjects to imitate five meaningless (e.g. index finger

**Table 1** Characteristics of normal control and left hemisphere apraxic and non-apraxic groups

Groups	Control mean (standard deviation)	Apraxic mean (standard deviation)	Non-apraxic mean (standard deviation)
Number	75	17	24
Age (years)	65 (12)	67 (7)	60 (13)
Education (years)	14 (2)	14 (3)	14 (3)
Years post-stroke		5 (5)	5 (7)
Lesion volume (cc)		93 (66)*	40 (42)
Limb apraxia <sup>†</sup>	1 (1)	6 (2)*	1 (1)
Speech <sup>‡</sup>	20 (2)	10 (7)*	18 (5)
Auditory comprehension <sup>‡</sup>	80 (1)	44 (23)*	75 (13)
Hemiplegia (%)		44%*	8%
Homonymous hemianopia (%)		0%	4%

\*Apraxics had larger lesions [ $F(1,39) = 10.0, P < 0.01$ ], were more apraxic by definition, and performed worse than non-apraxics on speech fluency [ $F(1,39) = 16.7, P < 0.001$ ] and auditory comprehension [ $F(1,39) = 29.7, P < 0.001$ ]. Incidence of hemiplegia was also greater in the apraxics than the non-apraxics ( $\chi^2 = 6.40, P < 0.01$ ). No other group differences were significant. <sup>†</sup>Number of errors on 15-item limb apraxia battery (Haaland and Flaherty, 1984); four or more errors is defined as apraxic ( $-2$  SD from control group mean). <sup>‡</sup>Western Aphasia Battery (Kertesz, 1982); spontaneous speech and sequential commands with maximum of 20 and 80, respectively.

on ear lobe), five intransitive (e.g. salute) and five transitive (e.g. brush teeth) movements. When errors in internal hand position (e.g. fist versus palm flat), orientation (e.g. vertical versus horizontal), target (e.g. brush nose, not teeth) or body-part-as-object (e.g. extend index finger to brush teeth) were made the item was scored incorrect. Thus, more than one type of error could be made on a single gesture, but only one error per gesture was scored. Patients were considered apraxic if they made spatiotemporal errors on four or more of the 15 movements (2 SD greater than the normal control group) (Haaland and Flaherty, 1984). Movement imitations were videotaped for later consensus scoring by two raters. There were no significant differences in the control group whether they performed the movements with their right or left hand, so the cutoff score for apraxia was based upon the overall mean for left and right hand performance. The left hemisphere stroke patients used their left hand and arm, and the right hemisphere stroke patients used their right hand and arm. The control group's mean error score was 1.2 (SD = 1.1), and ideomotor limb apraxia was defined as  $>2$  SD above the control group's mean error rate. Thus, any stroke patient making  $>3.4$  errors was designated as apraxic.

Only three of 37 patients with right hemisphere damage were apraxic (8%), whereas 17 patients with left hemisphere damage were apraxic (41%) and 24 were not apraxic (59%). These results are consistent with previous research showing that ideomotor limb apraxia is far more common after left than right hemisphere damage (Geschwind, 1965; Haaland and Flaherty, 1984). Because of the low incidence of limb apraxia in the right hemisphere stroke patients, only the left hemisphere stroke patients were examined to identify cortical areas critical for praxis.

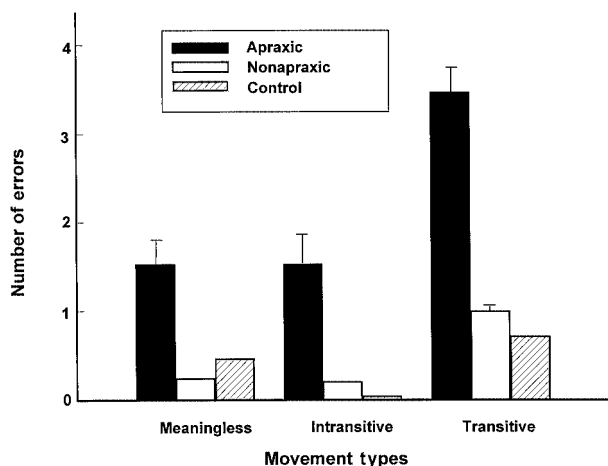
Table 1 shows that the apraxic and non-apraxic left

hemisphere stroke groups and the normal control group were matched in age and education, and the apraxic and non-apraxic stroke groups were similar in years post-stroke and incidence of visual field cut. In contrast, the apraxic group had larger lesions [ $F(1,39) = 10.0, P < 0.01$ ], were more apraxic by definition and performed worse than non-apraxics on speech fluency [ $F(1,39) = 16.7, P < 0.001$ ] and auditory comprehension [ $F(1,39) = 29.7, P < 0.001$ ]. Incidence of hemiplegia was also greater in the apraxics than the non-apraxics ( $\chi^2 = 6.40, P < 0.01$ ). However, when the apraxic and non-apraxic groups were further divided by lesion location (i.e. anterior, posterior, or anterior and posterior to the central sulcus) the incidence of hemiplegia and lesion size was comparable between the anterior apraxic and non-apraxic groups, and between the posterior apraxic and non-apraxic groups, which indicates that any differences in lesion location cannot be attributed to larger lesions in the apraxic groups. The apraxic patients with anterior and posterior damage showed a higher incidence of hemiplegia ( $\chi^2 = 9.0, P < 0.01$ ) and a larger lesion volume (Mann-Whitney,  $P = 0.028$ ) than the non-apraxic group with anterior and posterior damage.

## Results

Figure 2 shows the apraxic group made more errors than the other two groups [ $F(2,113) = 110.5, P < 0.001$ ] for all three movement types with greatest impairment for the transitive movements [ $F(4,226) = 9.5, P < 0.001$ ].

The incidence of apraxia was 36% for both the anterior and posterior groups, suggesting that both areas are of equal importance in controlling gesture imitation. This finding does not preclude different roles for the frontal and parietal cortex,



**Fig. 2** Number of errors with SE bars on the meaningless, intransitive and transitive movements in the control, apraxic and non-apraxic groups. When no SE bars are shown, the SE is very small.

but it is in agreement with our previous work showing that spatial deficits in a simple arm reaching movement are similar in apraxics with frontal or parietal lobe damage (Haaland *et al.*, 1999).

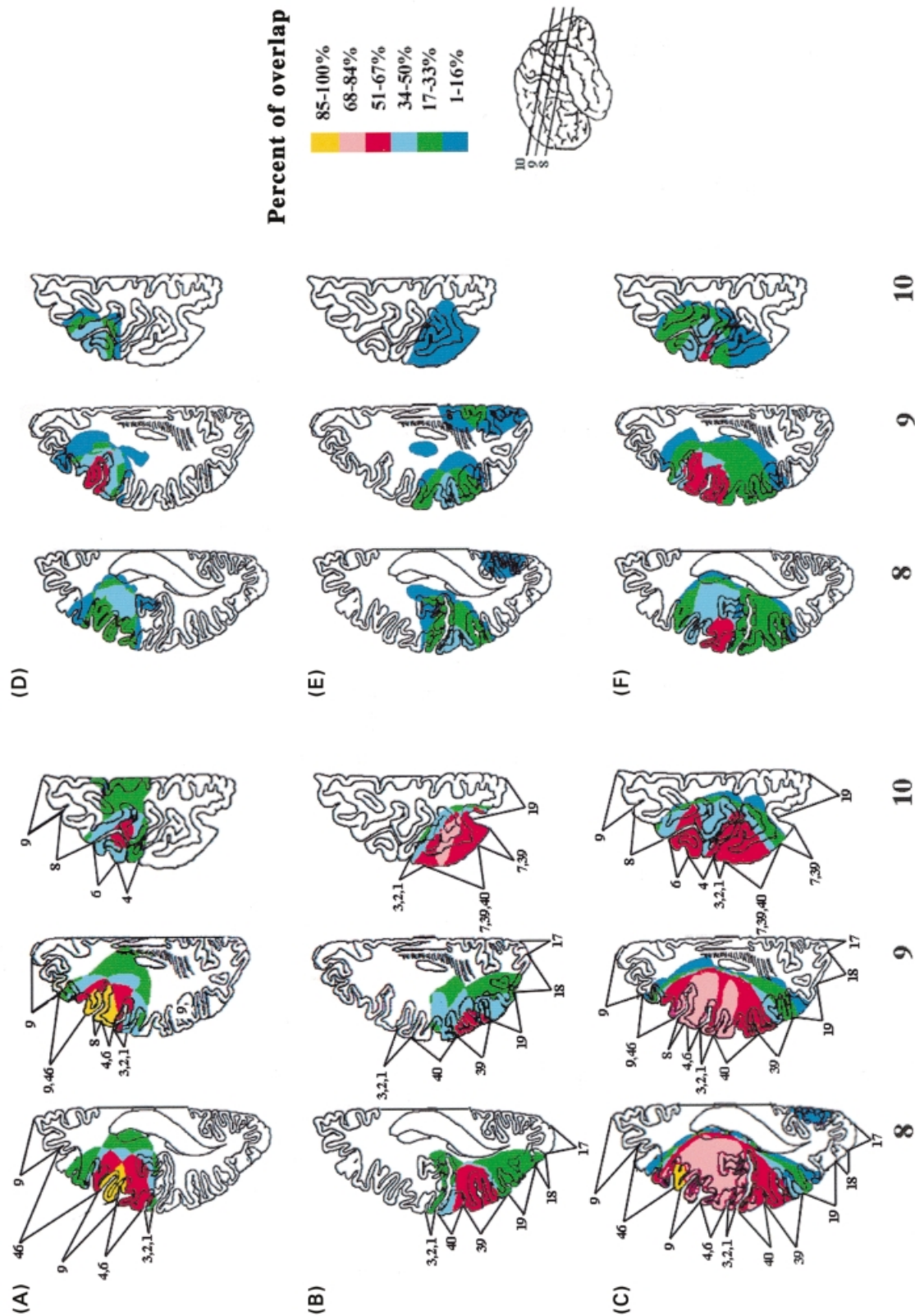
Figure 3 shows that all of the apraxic patients with anterior damage had lesions in the middle frontal gyrus (slice 8, areas 9 and 46; slice 9, areas 46, 9, 8, 6 and 4). In contrast, significantly fewer non-apraxic patients with anterior damage had lesions in areas 9 and 46 on slice 8 (29%,  $\chi^2 = 12.96$ ,  $P < 0.001$ ) and in areas 46, 9, 8, 6 and 4 on slice 9 (57%,  $\chi^2 = 4.84$ ,  $P < 0.05$ ). The majority (80%) of apraxic patients with posterior damage had lesions in the inferior and superior parietal cortex (slice 10, areas 7, 39 and 40) around the intraparietal sulcus whereas only one non-apraxic patient (11%) had damage in these same areas ( $\chi^2 = 19.36$ ,  $P < 0.001$ ). A similar pattern of lesion overlap was found in apraxic patients with large lesions extending into anterior and posterior areas, but these groups are not the best cases for accurate localization due to the large lesion volumes. Nonetheless, all of these apraxic patients had damage to the middle frontal gyrus (slice 8, areas 9 and 46) and 63% also had damage in the superior and inferior parietal lobes (slice 10, areas 7, 39 and 40), whereas similar areas were less frequently damaged in the non-apraxic anterior-posterior group.

Slices 1–7 are not shown because these slices did not differentiate apraxic and non-apraxic patients. Specifically, the anterior and posterior non-apraxic groups demonstrate >50% overlap only on slice 9 and the apraxic groups demonstrated greatest overlap (80–100%) on slices 8, 9 and 10 only. While the anterior and posterior apraxic groups demonstrated >50% overlap in several areas not shown in Fig. 3 (anterior apraxics: slice 7, area 46 in the middle frontal gyrus, 51 to 67% overlap; posterior apraxics: slices 6 and 7, areas 22, 37 and 42 in the superior temporal lobe, 51–67% overlap), the anterior and posterior non-apraxics also

demonstrated considerable overlap in these same areas (anterior non-apraxics: slice 7, area 46, 17–33% overlap; posterior non-apraxics: slice 6, area 22 and 37, 17–50% overlap; slice 7, area 42 and 22, 34–50% overlap), further supporting our contention that those areas are not as important in the control of praxis as the areas emphasized in slices 8, 9 and 10 in Fig. 3.

## Discussion

These results support the role of frontoparietal circuits in controlling complex skilled actions by demonstrating that damage to the left middle frontal gyrus (areas 46, 9, 8 and 6) and the inferior and superior parietal cortex surrounding the intraparietal sulcus (areas 7, 39 and 40) more commonly produce ideomotor limb apraxia than damage to other areas. The findings are consistent with Heilman's model (Heilman *et al.*, 1982), which equally emphasizes the importance of the frontal and parietal cortex in praxis, and are contrary to the view that subcortical parietal lobe damage to the fibres connecting the occipital and frontal cortex is primarily responsible for ideomotor limb apraxia (Geschwind, 1965). Despite the fact that 49% of our patients had subcortical damage that could disconnect pathways between the frontal and occipital cortex, damage to these pathways was not commonly associated with limb apraxia. While two studies reported that damage to fibre pathways produces apraxia more commonly than cortical damage (Kertesz and Ferro, 1984; Roy *et al.*, 1998), another found that subcortical fibre pathways were damaged more frequently in non-apraxics (Basso *et al.*, 1980). The present study's use of a more precise method of measuring common areas of damage and comparison of lesion location in a large group of apraxic and non-apraxic patients to assess directly the regions that are essential for praxis are the most likely explanations for our success in localizing limb apraxia. Other explanations include differences in patients, such as chronicity of damage or aetiology, and differences in limb apraxia assessment. Although our patients were less acute (>15 weeks post-stroke) than some other studies that have examined neuro-anatomical correlates of limb apraxia (Roy and Square-Storer, 1990; Alexander *et al.*, 1992), when time post-stroke was directly assessed it did not influence incidence or anatomical correlates of apraxia (Basso *et al.*, 1980; Kertesz and Ferro, 1984). Differences in aetiology do not explain differences across these papers because the most comprehensive papers that have examined the neuroanatomical correlates of limb apraxia have used stroke patients, just like the current paper. Differences in statistical approach may explain the fact that one paper found no evidence of localization (Alexander *et al.*, 1992), in contrast to the other papers (Basso *et al.*, 1980; Kertesz and Ferro, 1984; Roy and Square-Storer, 1990), because the former study used discriminant analyses, which have low power with small sample sizes. The types of gestures used and scoring criteria vary somewhat across the different studies in terms of the items used, whether command



**Fig. 3** Overlap of lesions in patients who are limb apraxic (A, B and C, numbers 4, 5 and 8, respectively) and patients who are not (D, E and F, numbers 7, 9 and 8). Patients with damage anterior (A and D), posterior (B and E), or both anterior and posterior (C and F) to the central sulcus are shown separately. Overlapping the lesions in the anterior apraxic group (A) produced 100% overlap (yellow) in the middle frontal gyrus including Brodmann areas 46, 9, 8, 6, and 4 on sections 8 and 9. Lesion overlap of the same areas in the non-apraxics (B) was much less, especially for Brodmann areas 46 and 9 on section 8. Overlapping the lesions in the posterior apraxic group (C) produced an area of maximum overlap (pink) in areas 7, 39, and 40 on section 10. Comparison with the non-apraxics with posterior lesions (E) showed much less overlap (dark blue) in that area. Overlapping the lesions in the apraxic patients with anterior and posterior damage (C) showed 100% overlap (yellow) in areas 9 and 46 on section 8 with much less overlap (green) in the non-apraxics (F); areas 7, 39, and 40 on section 10 showed an area of maximum overlap (red) relative to the minimal overlap (blue) in the non-apraxics; area of maximum parietal overlap was in area 40 on section 9 (pink), with less overlap (red and green) in the non-apraxics.

and imitation or imitation alone is used, and the type of errors considered. These differences could certainly influence the neuroanatomical substrates. This is most clearly demonstrated in Roy's study (Roy and Square-Storer, 1990), which found a higher incidence of limb apraxia after right hemisphere damage than was found in the current study or most other studies. This discrepancy suggests that the errors that they identified are more dependent upon the right hemisphere than the errors in other studies. However, exactly how such methodological differences would affect intra-hemispheric neural substrates cannot be answered at this point.

The current results emphasize the role of the dorsolateral frontal and intraparietal cortex, but we cannot rule out the role of the supplementary motor area in the neural control of limb praxis because none of the left hemisphere-damaged patients in our study had damage to the supplementary motor area. Two studies have associated limb apraxia with damage to the supplementary motor area (Masdeu and Schoene, 1978; Watson *et al.*, 1986), but others have not (Damasio and Van Hoesen, 1983; Faglioni and Basso, 1985). Given the low frequency of isolated damage to the supplementary motor area, especially without involvement of the corpus callosum, the influence of this area is difficult to study in brain-damaged patients. However, the recently published fMRI study in normal individuals (Moll *et al.*, 2000) did not find activation of the supplementary area during gesturing, which minimizes its importance. Because our patients demonstrate apraxia without damage to the supplementary area, our results clearly demonstrate that damage to the supplementary motor area is not necessary to produce limb apraxia.

Our findings are compatible with neuroanatomical research delineating multiple interconnections between parietal and frontal cortical areas (Pandya and Yeterian, 1998) and between distinct areas within the frontal lobes (Strick, 1988) as well as behavioural studies showing that both influence reaching and grasping movements in monkeys and in humans with focal lesions (Sakata, 1995; Jeannerod, 1997; Kalaska *et al.*, 1997; Rizzolatti *et al.*, 1998). In addition, a recent functional imaging study (Moll *et al.*, 2000) demonstrated that the same areas in the left dorsolateral prefrontal and intraparietal cortex

were activated when gestures were performed or imagined by normal individuals. Therefore, the current study offers convergent evidence of the importance of these specific areas within the left hemisphere in controlling gestures.

Damage to the parietal cortex disrupts the kinematic or spatiotemporal aspects of movement, including transporting the hand to the vicinity of a target and orienting and positioning the hand to efficiently pick up objects (Taira *et al.*, 1990; Goodale and Milner, 1992; Jeannerod, 1997; Kalaska *et al.*, 1997). Three-dimensional kinematic analyses of gestural performance in limb apraxic patients with parietal lobe damage have also documented spatiotemporal deficits (Poizner *et al.*, 1998). In the monkey, hand manipulation neurons have been identified in the parietal cortex (Sakata, 1995), and focal damage to these neurons produces deficits in grip formation (Gallese *et al.*, 1994). Additionally, deficits in hand posture sequencing are more common after left parietal than frontal damage (Kolb and Milner, 1981), consistent with the purported role of the parietal lobe in encoding relationships among abstract properties of sequential movements (Harrington *et al.*, 2000). Functional imaging studies are compatible with a key role for the left parietal cortex in representing higher order aspects of movement as evidenced by its activation during the performance of learned movements and during mental rotation of the hands (Bonda *et al.*, 1995; Shadmehr and Holcomb, 1997).

While the precise role of the middle frontal gyrus in limb apraxia is not known, it has been associated with two aspects of working memory. Area 6 has been related to short term storage, and areas 9 and 46 have been related to active manipulation of the stored information (Smith and Jonides, 1999). Areas 9 and 46 are also activated when preparing to imitate simple movements (Krams *et al.*, 1998) though the specific cognitive mechanisms have not been identified. Although the role of working memory has not been directly examined in the context of goal-directed movements, maintenance and manipulation of movement representations is likely important for sustaining gestural input and comparing it with retrieved motor representations. Our findings raise the intriguing possibility that working memory requirements for

**Table 2** Percentage of patients in each group with target or internal hand position errors

No. of errors	Target errors (%)			Internal hand position errors (%)		
	Anterior	Posterior*	Anterior-posterior*	Anterior	Posterior	Anterior-posterior*
0	100	20	37	0	40	0
1	0	60	25	25	20	0
2	0	20	13	50	40	25
3	0	0	12	0	0	13
4	0	0	0	25	0	0
≥5	0	0	13	0	0	62

\*Groups with significantly greater errors. Mann-Whitney *U*-tests confirmed that target errors were more common in the posterior ( $P < 0.03$ ) and the anterior-posterior ( $P = 0.058$ ) groups relative to the anterior group. Internal hand position errors were more common in the anterior-posterior group relative to the posterior group ( $P < 0.01$ ) and the anterior group ( $P = 0.056$ ), and there were no significant differences between the anterior and posterior groups ( $P = 0.16$ ).

controlling complex movements are biased for left hemisphere processing.

Areas 6 and 8 have been associated with selection and retrieval of motor representations (Schluter *et al.*, 1998), and ventral area 6 (premotor area), like the inferior parietal lobe, has been linked to the visual-motor transformations necessary to reach and grasp objects. However, in the present study, target errors but not other error types were more common with parietal than frontal lobe damage (see Table 2). In fact, the anterior group made no target errors. This finding extends previous research that has linked the parietal lobe to accurate localization of targets in extrapersonal space (Jeannerod, 1997; Kalaska *et al.*, 1997) by demonstrating that posterior damage is associated with a higher incidence of target errors that are largely in intrapersonal space. Many studies also suggest that the parietal cortex, especially around the intraparietal sulcus, represents pragmatic knowledge about how an action is performed (Goodale and Milner, 1992; Gallese *et al.*, 1994; Sakata, 1995; Jeannerod, 1997), which is probably important when imitating complex gestures that require making a transformation from visual input in extrapersonal space to responses that are dependent upon motor representations in intrapersonal space. However, the frequency of internal hand position errors, an index of these representations, were similar in patients with anterior or posterior damage. Similarly, a recent study found a similar pattern of spatial errors on a reaching task in apraxics with frontal or parietal cortex damage (Haaland *et al.*, 1999). While the independent roles of the frontal and parietal cortex have been difficult to differentiate in other studies (Kalaska *et al.*, 1997; Rizzolatti *et al.*, 1998), the present results suggest different underlying mechanisms may be uncovered by studying movement in contexts other than reaching and grasping.

Our study clearly demonstrates left hemisphere dominance for representing complex movements, consistent with many focal lesion studies of simple goal-directed movements (Haaland and Harrington, 1996). Functional imaging studies in healthy adults also support left hemisphere dominance in the motor or premotor cortex for simple movements (Kim *et al.*, 1993), by showing activation in the left hemisphere when moving either hand and activation in the right hemisphere only when moving the left hand. While the specific processes subserved by the left hemisphere are uncertain, the left premotor cortex appears to be involved in the selection of movements of either hand (Schluter *et al.*, 1998), because choice reaction time was impaired in both hands after left premotor cortex stimulation, but in the left hand only after right premotor cortex stimulation. Importantly, simple reaction times were not affected, demonstrating that the disruption was specific to response selection rather than motor activation. Others have reported greater left than right parietal activation when performing mental rotations of the hands, which are thought to rely upon internal representations, suggesting that the left hemisphere plays a more central role

in the storage and retrieval of motor representations (Bonda *et al.*, 1995).

This is the first study to demonstrate directly the importance of left middle frontal–intraparietal sulcus networks in limb apraxia, consistent with neuroanatomical (Pandya and Yeterian, 1998), electrophysiological (Kalaska *et al.*, 1997; Rizzolatti *et al.*, 1998), and behavioural studies (Kolb and Milner, 1981; Gallese *et al.*, 1994; Jeannerod, 1997) that implicate these areas in the storage and retrieval of movement representations (Bonda *et al.*, 1995; Jeannerod, 1997; Shadmehr and Holcomb, 1997).

### Acknowledgements

We wish to thank Gabrielle Mallory and Lee Stapp for technical assistance and Roland Lee, M.D. and the Department of Radiology at the Albuquerque VAMC for providing MRI and CT scans and their clinical interpretation. This research was funded by grants to K.Y.H. and D.L.H. from Medical Research, Department of Veterans Affairs and the National Foundation for Functional Imaging and to R.T.K. from NINCDS NS21135.

### References

- Alexander MP, Baker E, Naeser MA, Kaplan E, Palumbo C. Neuropsychological and neuroanatomical dimensions of ideomotor apraxia. *Brain* 1992; 115: 87–107.
- Basso A, Luzzatti C, Spinnler H. Is ideomotor apraxia the outcome of damage to well-defined regions of the left hemisphere? *J Neurol Neurosurg Psychiatry* 1980; 43: 118–26.
- Bonda E, Petrides M, Frey S, Evans A. Neural correlates of mental transformations of the body-in-space. *Proc Natl Acad Sci USA* 1995; 92: 11180–4.
- Damasio AR, Van Hoesen GW. Emotional disturbances associated with focal lesions of the limbic frontal lobe. In: Heilman K, Satz P, editors. *Neuropsychology of human emotion*. New York: Guilford Press, 1983. p. 85–110.
- De Armond SJ, Fusco MM, Dewey MM. *Structures of the human brain: a photographic atlas*. New York: Oxford University Press; 1989.
- De Renzi E, Faglioni P, Lodesani M, Vecchi A. Performance of left brain-damaged patients on imitation of single movements and motor sequences. Frontal and parietal-injured patients compared. *Cortex* 1983; 19: 333–43.
- Faglioni P, Basso A. Historical perspectives on neuroanatomical correlates of limb apraxia. In: Roy EA, editor. *Neuropsychological studies of apraxia and related disorders*. Amsterdam: North-Holland; 1985. p. 3–44.
- Frey RT, Woods DL, Knight RT, Scabini D, Clayworth C. Defining functional cortical areas with ‘averaged’ CT scans [abstract]. *Soc Neurosci Abstr* 1987; 13: 1266.



- Gallese V, Murata A, Kaseda M, Niki N, Sakata H. Deficit of hand preshaping after muscimol injection in monkey parietal cortex. *Neuroreport* 1994; 5: 1525–9.
- Geschwind N. Disconnexion syndromes in animals and man. I. [Review]. *Brain* 1965; 88: 237–94.
- Goodale MA, Milner AD. Separate visual pathways for perception and action. *Trends Neurosci* 1992; 15: 20–5.
- Haaland KY, Flaherty D. The different types of limb apraxia errors made by patients with left vs. right hemisphere damage. *Brain Cogn* 1984; 3: 370–84.
- Haaland KY, Harrington DL. Hemispheric asymmetry of movement. [Review]. *Curr Opin Neurobiol* 1996; 6: 796–800.
- Haaland KY, Harrington DL, Knight RT. Spatial deficits in ideomotor limb apraxia: a kinematic analysis of aiming movements. *Brain* 1999; 122: 1169–82.
- Harrington DL, Haaland KY. Motor sequencing with left hemisphere damage: are some cognitive deficits specific to limb apraxia? *Brain* 1992; 115: 857–74.
- Harrington DL, Haaland KY, Knight RT. Cortical networks underlying mechanisms of time perception. *J Neurosci* 1998; 18: 1085–95.
- Harrington DL, Rao SM, Haaland KY, Bobholz JA, Mayer AR, Binder JR, et al. Specialized neural systems underlying representations of sequential movements. *J Cogn Neurosci* 2000; 12: 56–77.
- Heilman KM, Rothi LJ, Valenstein E. Two forms of ideomotor apraxia. *Neurology* 1982; 32: 342–6.
- Jeannerod M. *The cognitive neuroscience of action*. Oxford: Blackwell; 1997.
- Kalaska JF, Scott SH, Cisek P, Sergio LE. Cortical control of reaching movements. [Review]. *Curr Opin Neurobiol* 1997; 7: 849–59.
- Kertesz A. *The Western Aphasia Battery*. New York: Psychological Corporation; 1982.
- Kertesz A, Ferro JM. Lesion size and location in ideomotor apraxia. *Brain* 1984; 107: 921–33.
- Kim SG, Ashe J, Hendrich K, Ellerman JM, Merkle H, Ugurbil K, et al. Functional magnetic resonance imaging of motor cortex: Hemispheric asymmetry and handedness. *Science* 1993; 261: 615–7.
- Kolb B, Milner B. Performance of complex arm and facial movements after focal brain lesions. *Neuropsychologia* 1981; 19: 491–503.
- Krams M, Rushworth MF, Deiber M-P, Frackowiak RS, Passingham R. The preparation, execution and suppression of copied movements in the human brain. *Exp Brain Res* 1998; 120: 386–98.
- Masdeu JC, Schoene WC, Funkenstein H. Aphasia following infarction of the left supplementary motor area. *Neurology* 1978; 28: 1220–3.
- Moll J, de Oliveira-Souza R, Passman LJ, Cimini Cunha F, Souza-Lima F, Andreiuolo PA. Functional MRI correlates of real and imagined tool-use pantomimes. *Neurology* 2000; 54: 1331–6.
- Pandya DN, Yeterian EH. Comparison of prefrontal architecture and connections. In: Roberts AC, Robbins TW, Weiskrantz L, editors. *The prefrontal cortex*. Oxford: Oxford University Press; 1998. p. 51–66.
- Poizner H, Merians AS, Clark MA, Macauley B, Rothi LJ, Heilman KM. Left hemisphere specialization for learned, skilled, and purposeful action. *Neuropsychology* 1998; 12: 163–82.
- Rizzolatti G, Luppino M, Matelli M. The organization of the cortical motor system: new concepts. [Review]. *Electroencephalogr Clin Neurophysiol* 1998; 106: 283–96.
- Roy EA, Square-Storer PA. Evidence for common expressions of apraxia. In: Hammond GR, editor. *Cerebral control of speech and limb movements*. Amsterdam: North-Holland; 1990. p. 477–502.
- Roy EA, Black SE, Blair N, Dimeck PT. Analyses of deficits in gestural pantomime. *J Clin Exp Neuropsychol* 1998; 20: 628–43.
- Sakata H, Taira M, Murata A, Mine S. Neural mechanisms of visual guidance of hand action in the parietal cortex of the monkey. *Cereb Cortex* 1995; 5: 429–38.
- Schluter ND, Rushworth MF, Passingham RE, Mills KR. Temporary interference in human lateral premotor cortex suggests dominance for the selection of movements. *Brain* 1998; 121: 785–99.
- Shadmehr R, Holcomb HH. Neural correlates of motor memory consolidation. *Science* 1997; 277: 821–5.
- Smith EE, Jonides J. Storage and executive processes in the frontal lobes. [Review]. *Science* 1999; 283: 1657–61.
- Strick PL. Anatomical organization of multiple motor areas in the frontal lobe: Implications for recovery of function. [Review]. *Adv Neurol* 1988; 47: 293–312.
- Taira M, Mine S, Georgopoulos AP, Murata A, Sakata H. Parietal cortex neurons of the monkey related to the visual guidance of hand movement. *Exp Brain Res* 1990; 83: 29–36.
- Watson RT, Fleet WS, Gonzalez-Rothi L, Heilman KM. Apraxia and the supplementary motor area. *Arch Neurol* 1986; 43: 787–92.

*Received May 3, 2000. Revised July 19, 2000.*

*Accepted July 25, 2000*