

UC Davis

Dermatology Online Journal

Title

Equestrian perniosis: A case report and review of the literature

Permalink

<https://escholarship.org/uc/item/8qz5w935>

Journal

Dermatology Online Journal, 21(10)

Authors

Dane, Alexander
Rama, Sonam
Sikorski, Lynn

Publication Date

2015

DOI

10.5070/D32110028955

Copyright Information

Copyright 2015 by the author(s). This work is made available under the terms of a Creative Commons Attribution-NonCommercial-NoDerivatives License, available at <https://creativecommons.org/licenses/by-nc-nd/4.0/>

Peer reviewed

Case presentation

Equestrian perniosis: A case report and review of the literature

Alexander Dane¹, Sonam Rama², Lynn Sikorski³

Dermatology Online Journal 21 (10): 13

¹Michigan State University

²Ohio University Heritage College of Osteopathic Medicine

³McLaren Oakland Health

Correspondence:

Alexander Dane
Michigan State University
Botsford Hospital
Farmington Hills, MI
adaneshv@gmail.com

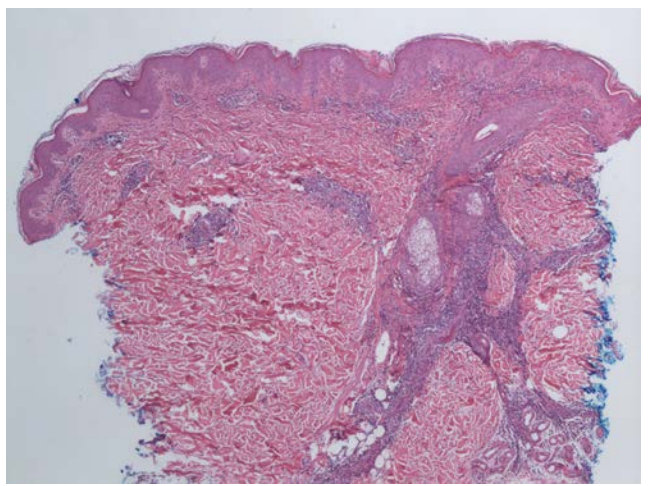
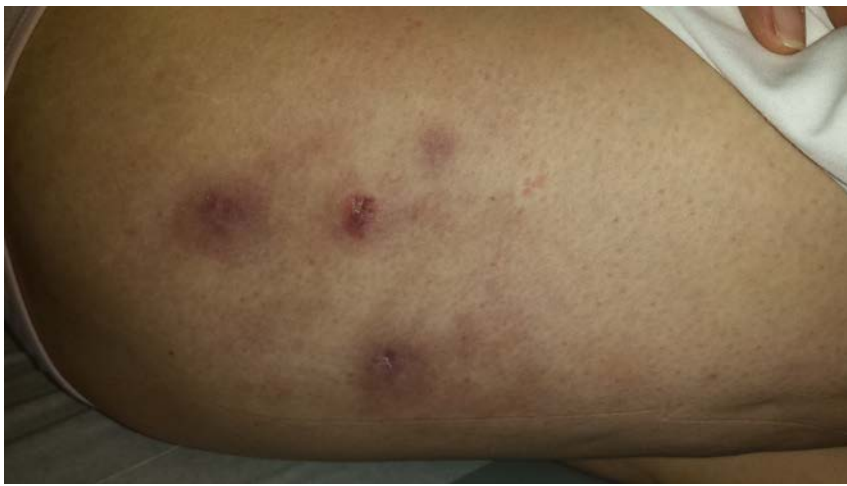Abstract

Equestrian perniosis is a rare form of perniosis that is predominantly seen in young female equestrians who ride in cold temperatures. Tight fitting clothing, age under 35 years, and smoking can contribute to the disease manifestation. The diagnosis can be determined from a thorough history and physical examination. However, a biopsy can be taken to confirm the diagnosis. Although many cases are self-limiting and resolve within a few days to weeks of diagnosis, nifedipine can be considered as a therapeutic measure for persistent cases. Measures such as wearing loose fitting clothing and horseback riding in warmer temperatures and for shorter time periods can prevent recurrence.

Case synopsis

A 25-year-old woman presented to the clinic with a three-year history of a cutaneous eruption on her thighs. The patient described the rash as red to purple bumps on her outer thighs; the eruption had been present off and on for the past five years. She claimed the rash would seem to worsen in the winter and subside in the summer. The patient denied any fevers, chills, joint pains, recent weight loss or any other constitutional symptoms. She denied taking any medications or having any significant medical history. The patient also denied any recent travel or any alcohol or tobacco use. Upon further history, the patient stated that she rode horses year round. She denied having any other skin lesions.

On physical exam, multiple erythematous to violaceous annular plaques and nodules were noted on her proximal lateral thighs (Figure 1). No epithelial disruption or scale was appreciated. Mild pain upon deep palpation was elicited. Laboratory examination including a complete blood count with differential, complete metabolic panel, urinalysis, C3, C4, antinuclear antibody screen, anti-Ro, anti-La, rheumatoid factor, erythrocyte sedimentation rate, c-reactive protein, cold agglutinins, cryoglobulins, and cryofibrinogen were all unremarkable. A punch biopsy was performed on an erythematous plaque on her right lateral thigh and revealed mild epidermal hyperplasia and hyperkeratosis as well as focal areas of vacuolar interface changes. Mild endothelial cell edema and a superficial and deep perivascular infiltrate that extended to the subcutis was noted (Figure 2). Given the histologic features as well as clinical findings, a diagnosis of equestrian perniosis was made.



Figures 1 and 2. *Figure 1:* Multiple erythematous to violaceous annular plaques and nodules on the patient's proximal lateral thigh. *Figure 2:* Mild epidermal hyperplasia and hyperkeratosis as well as focal areas of vacuolar interface changes noted in the epidermis. Dermal vessel edema with a superficial and deep, perivascular lymphocytic infiltrate with peri-eccrine involvement is present in the dermis.

Discussion

Perniosis, or chilblains, is a disease characterized by tender erythematous to violaceous papules and plaques induced by cold exposure, which in severe cases can blister and ulcerate. Patients may not be aware of the development of the lesions in the cold, but often describe a persistent burning or pruritic sensation once warm. The eruption classically involves acral sites, including the dorsum of the fingers, toes, nose, and ears. The pathogenesis of perniosis is not clear, but it may be caused by abnormal vasoconstriction, vasospasm, or hyperviscosity [1]. Most cases of perniosis resolve after a few days; however in some cases, the lesions can persist. Perniosis is mainly idiopathic, although it can be associated with systemic diseases such as cutaneous or systemic lupus erythematosus (SLE). Perniosis can also occur in the setting of elevated cryofibrinogen, cryoglobulins, or cold agglutinins [1]. This condition mostly affects women, although a few reported cases have occurred in men.

Equestrian perniosis is a rare form of perniosis occurring in horseback riders. This variant form of perniosis has a predilection for the lateral thighs unilaterally, or rarely bilaterally, of equestrians who ride for prolonged periods in cold temperatures. This self-limiting inflammatory cutaneous disorder typically has a short course and resolves in a few days to few weeks. However, prolonged cases have been reported. Interestingly, the term equestrian perniosis has been used interchangeably in the literature with terms such as horse rider's pernio and equestrian cold panniculitis [2-4]. Although equestrian perniosis is classified as a dermatitis and as a panniculitis, there are overlapping histopathologic features that occur in these two diseases, which may indicate that they represent ends of a spectrum rather than distinct entities [2].

The rarity of equestrian perniosis makes calculating the incidence and prevalence difficult. This specific type of perniosis has a predilection for female horseback riders and develops in cold and wind-exposed cutaneous areas covered by tight fitting, uninsulated riding pants after several hours of activity [2]. Moreover, some studies report that heavy smoking and age less than 35 years increase one's risk of developing equestrian perniosis. These attributes support the theory, related below, of the pathogenesis of the disease [4-6].

Although the pathogenesis of equestrian perniosis is not well understood, perniosis itself is thought to occur as a result of intermittent or prolonged cold-induced vasoconstriction with the development of hypoxemia [4]. This leads to development of ischemia and vessel wall edema, forming perniosis [3, 6-7]. The thicker subcutaneous layer found on the lateral thigh predispose patients to perniosis. Specifically regarding female equestrian riders, the lateral thighs and buttocks are two areas that are higher in adipose tissue content than other areas of the body. Because of the inherent decreased blood flow in these areas owing to position while riding horses, patients may experience a cold-induced increase in blood viscosity in these regions [3, 6-7].

Clinically, equestrian perniosis appears as multiple indurated, edematous red to violaceous papules, plaques, or nodules located on the lateral thighs and occasionally the buttocks [2-5]. Although this dermatologic manifestation is self-limited most times, in severe cases, blisters and ulcerations can occur [1]. Generally, equestrian perniosis is asymptomatic except for mild to moderate pruritus and tenderness. The cutaneous manifestations occur without systemic manifestations. This local reaction to the cold environment and appears 24-48 hours after exposure. Resolution of these lesions can leave behind postinflammatory hyperpigmentation and rarely permanent depression of the skin or scar formation [3].

Erythematous indurated plaques or nodules located on the lateral thigh that closely resemble equestrian perniosis include systemic lupus erythematosus, autoimmune perniosis, idiopathic perniosis, equestrian cold panniculitis, cold urticaria, acrocyanosis, septic emboli, polycythemia vera, Raynaud phenomenon, trauma, and frostbite [5].

The cardinal histological features observed in equestrian perniosis include extensive dermal vessel edema with a superficial and deep perivascular lymphocytic infiltrate with peri-ecrine reinforcement [2]. Endothelial cell edema and thickened small vessel walls without fibrin deposition are also seen. However, vacuolation of the basal layer is suggestive of an autoimmune perniosis and must be considered when seen on histology exam [2]. This histologic presentation differs from that seen in perniosis of acral distribution. In acral perniosis, dermal vessel edema with prominent perivascular and perifollicular lymphocytic infiltration is seen mainly in the papillary region, rather than extensively throughout the dermis [8]. This lymphocytic infiltration is also reinforced by peri-ecrine inflammation, as seen in equestrian perniosis. However, scattered necrosis of individual keratinocytes within the epidermis and the presence of spongiosis is exhibited more commonly in acral perniosis [8].

Although the diagnosis of equestrian perniosis can be suspected from a thorough clinical history, a biopsy can be performed for confirmation of diagnosis. However, when performing the biopsy, special attention must be taken to include the whole dermis as well as portions of subcutis, because some key histological changes are most marked in deep dermis [6-7]. Laboratory testing is not necessary for diagnosis, however ESR, ANA titer, rheumatoid factor, and serum protein electrophoresis may be useful markers to assess if other systemic conditions are suggested [5]. Abnormal results should raise the suspicion of a secondary cause of the cutaneous findings and prompt a formal rheumatology consultation for possible autoimmune cause. There have also been two reported cases of equestrian perniosis with positive cold agglutinins in the literature [6].

There is no definitive treatment for equestrian cold perniosis and many cases are self-limited. Avoidance of cold temperatures and warmer loose-fitting clothing assists in healing of lesions. Riding for shorter periods of time may also be helpful. However, if therapeutic measures are pursued, the calcium-channel blocker, nifedipine (10 mg three times daily or 20 mg twice daily), has been shown to increase the rate of resolution of this disease and prevent recurrence [7]. The theory behind the use of nifedipine lies in its vasodilatory effects, increasing peripheral circulation to the affected areas. Recommendation for nicotine cessation is also encouraged.

Conclusion

Equestrian perniosis is a rare form of perniosis that is predominantly seen in young female equestrians who ride in cold temperatures. Tight fitting clothing, age under 35 years, and smoking can contribute to the disease manifestation. The diagnosis can be surmised from a thorough history and physical examination. However, a biopsy can be taken to provide confirmation of diagnosis. Although many cases are self-limiting, nifedipine can be considered as a therapeutic measure for persistent cases. Measures such as wearing loose fitting clothing and horseback riding in warmer temperatures and for shorter time periods can prevent recurrence.

References

1. Stewart CL, Adler DJ, Jacobson A, et al. Equestrian perniosis: a report of 2 cases and a review of the literature. *Am J Dermatopathol*. 2013;35(2):237-40. [PMID: 22534636]
2. Boada A, Bielsa, I, Fernandez-Figueras M, Ferrandiz C. Perniosis: Clinical and Histopathological Analysis. *Am J Dermatopathol*. 2010; 32(1): 19-23. [PMID: 20098080]
3. Adler D, Lewars M. Equestrian Perniosis. *LVHN Scholarly Works*. 2011. Retrieved from <http://scholarlyworks.lvhn.org/medicine/19> [PMID: 22221816]
4. Neal A, Jarman A, Bennett T. Perniosis in a Long-Distance Cyclist Crossing Mongolia. *Journal of Travel Medicine*. 2012; 19 (1): 66–68. [PMID: 22221816]
5. Englund, S, Adams B. Winter Sports Dermatology: A Review. *Cutis*. 2009; 83: 42-48. [PMID: 19271570]
6. De Silva B, McLaren K, Doherty V. Equestrian Perniosis Associated with Cold Agglutinins: A Novel Finding. *Clin Exp Dermatol*. 2000; 25(4): 285-8. [PMID: 10971486]
7. Jordaan HF. The Diagnosis and Management of Perniosis (Chilblains). *SA Fam Pract* 2007; 49(6): 28-29.
8. Gordon R, Arikian A, Pakula A. Chilblains in Southern California: Two Case Reports and a Review of the Literature. *J Med Case Rep*. 2014 Nov 22; 8:381. [PMID: 25416648]