

UC Irvine

Western Journal of Emergency Medicine: Integrating Emergency Care with Population Health

Title

A Novel Curriculum for Teaching Emergency Medicine Residents How to Break Bad News

Permalink

<https://escholarship.org/uc/item/8gw08422>

Journal

Western Journal of Emergency Medicine: Integrating Emergency Care with Population Health, 18(5.1)

ISSN

1936-900X

Authors

Hall, M
Dubosh, N
Ullman, E

Publication Date

2017

Copyright Information

Copyright 2017 by the author(s). This work is made available under the terms of a Creative Commons Attribution License, available at <https://creativecommons.org/licenses/by/4.0/>

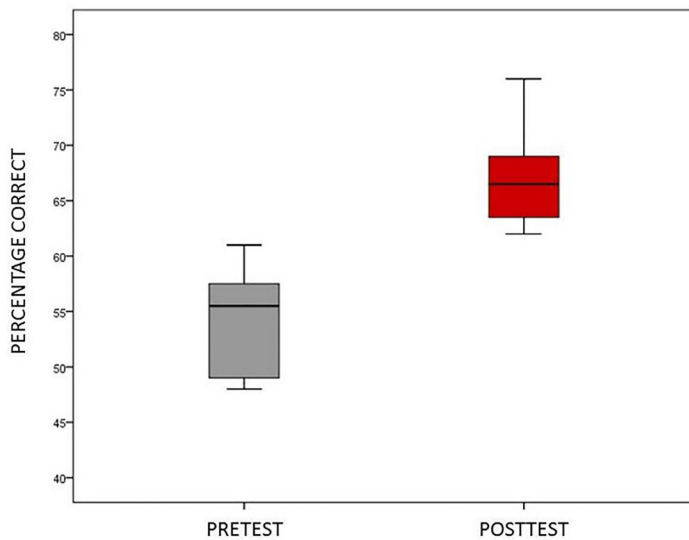


Figure 1. Examination Scores for 12 Interns before (Pre) and after (Post) Orientation Program.

Table 1. Descriptive statistics and paired t-test results for twelve emergency medicine interns on their before (pre) and after (post) orientation examination.

	Mean Scores	Standard Deviation	Mean Difference	t-value	df	p	ES*
Pre-Test	54.33	4.83	-12.58	-6.78	11	.000	-2.73
Post-Test	66.92	4.38					

*ES=Cohen's D effect size

4 A Novel Curriculum for Teaching Emergency Medicine Residents How to Break Bad News

Hall M, Dubosh N, Ullman E/Beth Israel Deaconess Medical Center, Boston, MA

Background: Breaking bad news in the ED is a critical part of Emergency Medicine. Previous research has called for increased teaching of communication skills to EM residents. Recent research has found that few EM providers were trained to deliver bad news during their residency training. There has been previous work describing death notification in the ED and talking with families of critically ill patients in the ICU setting but little has been published describing how to discuss critically ill patient in the ED.

Educational Objectives: To develop a multidisciplinary team approach to teach EM residents how to deliver bad news (both death notification and sudden critical illness) specifically in the ED setting and to study its implementation.

Curricular Design: EM residents participated in a simulation case where a patient became critically ill and

then expired. Twice during this encounter they updated a family member, played by a volunteer actor they had never met, about the case. All cases were videotaped and the interactions was graded by independent reviewers. Residents then participated in a novel curriculum aimed at teaching critical elements of breaking bad news. This session was led by ED attendings and social workers and was comprised of lecture, video presentation, small group roll playing, and discussion. The initial presentation gave an introduction to the topic while the small groups allowed the residents to practice their new skills with real-time feedback. Following the didactic session, residents again participated in a simulation case with hospital volunteer “family members” and their skills discussing the case were again graded. These pre/post evaluations were compared to evaluate the success of the teaching session.

Impact/Effectiveness: Outcome measures are not yet available. Previous projects regarding breaking bad news in the ED have focused on only death notification or used techniques developed in non-ED settings. A recent survey of attendings demonstrated that few received EM specific training in breaking bad news. All EM doctors will unfortunately have to deliver bad news frequently during their careers and increasing training during residency will improve this necessary skill.

5 A Novel Eye Model for Simulation in Slit Lamp Examination, Ultrasound and Foreign Body Removal Using Animal Tissue

Coleman K, Fortuna T, Kuehl D/Virginia tech/Carilion School of Medicine, Roanoke, VA

Background: We sought to develop an inexpensive simulation model that could be used for instruction of the emergency medicine model of practice for ophthalmologic complaints. While synthetic phantoms and models using foodstuffs have been described, animal tissue in a lifelike facsimile has not been fully explored.

Educational Objectives: Gain familiarity and psychomotor skills for competently addressing ocular emergencies to include:

1. Perform Slit lamp examination of both normal anatomy and corneal defects
2. Successfully remove foreign bodies and rust rings
3. Execute an ultrasound examination to include appreciation of normal anatomy, foreign bodies, vitreous hemorrhage and retinal detachment

Curricular Design: Using Styrofoam wig holders and animal tissue, we constructed a model for use with ultrasound and slit lamp examination. For this example, eyes from recently harvested specimens of *Odocoileus virginianus* (Virginia white tailed deer) were used. Each